

# Subthreshold Continuous Wave Autofluorescence-controlled Laser Treatment of Chronic Central Serous Chorioretinopathy

Hossein Ashraf<sup>1</sup>, MD; Mansooreh Jamshidian<sup>2</sup>, MD; Mohammad Reza Khalili<sup>1</sup>, MD; Mousa Zare<sup>3</sup>, MD  
Anis Shamsi<sup>4</sup>, MD

<sup>1</sup>Poostchi Eye Research Center, Ophthalmology Department, Shiraz University of Medical Sciences, Shiraz, Iran

<sup>2</sup>Department of Ophthalmology, Tehran University of Medical Sciences, Tehran, Iran

<sup>3</sup>Department of Ophthalmology, Jahrom University of Medical Sciences, Shiraz, Iran

<sup>4</sup>Department of Ophthalmology, Kerman University of Medical Sciences, Kerman, Iran

## Abstract

**Purpose:** To investigate the therapeutic effect of clinically invisible subthreshold continuous wave autofluorescence-controlled laser treatment on visual acuity and macular status of patients with chronic central serous chorioretinopathy (CSCR).

**Methods:** In this prospective case series, patients with clinical and fluorescein angiographic (FA) findings of CSCR and chronic visual loss (>6 months) were included. Complete ocular examination, FA, and optical coherence tomography (OCT) tests were performed. Each eye was subjected to a direct laser treatment of leakage points by 532 nm continuous wave low energy laser pulses, which were kept invisible by reducing the power to 70% of the threshold test spot. Considering the lack of visible effect on the retinal pigment epithelium (RPE), the laser effect was monitored by pre- and post-treatment infrared and autofluorescence images.

**Results:** A total of 20 patients were included in this study, of whom 12 patients (9 male and 3 female patients) with an average age of 38 years had complete follow-up (Average: 3.5 months). The mean preoperative visual acuity was 20/80, which improved to 20/40 at the final visit. The mean preoperative central macular thickness (CMT) was 330  $\mu\text{m}$  and the average final CMT in the last OCT test was 188  $\mu\text{m}$  ( $P = 0.001$ ).

**Conclusion:** Subthreshold continuous wave autofluorescence-controlled laser treatment may be a good treatment for chronic CSCR to avoid the risks of retinal damage by clinically suprathreshold laser therapy.

**Keywords:** Autofluorescence; Chronic Central Serous Chorioretinopathy; Subthreshold Continuous Wave Laser

*J Ophthalmic Vis Res* 2018; 13 (3): 236-240

## Correspondence to:

Mohammad Reza Khalili, MD, Poostchi Eye Research Center, Khalili Hospital, Department of Ophthalmology, Shiraz University of Medical Sciences, Shiraz 71349, Iran.  
E-mail: Khalilimr57@gmail.com

Received: 18-05-2017

Accepted: 25-11-2017

## Access this article online

Quick Response Code:



Website:

www.jovr.org

DOI:

10.4103/jovr.jovr\_9\_17

## INTRODUCTION

Central serous chorioretinopathy (CSCR) is characterized by development of areas of serous neurosensory detachment at the posterior pole of the eye.<sup>[1]</sup> It is a benign

This is an open access journal, and articles are distributed under the terms of the Creative Commons Attribution-NonCommercial-ShareAlike 4.0 License, which allows others to remix, tweak, and build upon the work non-commercially, as long as appropriate credit is given and the new creations are licensed under the identical terms.

For reprints contact: reprints@medknow.com

**How to cite this article:** Ashraf H, Jamshidian M, Khalili MR, Zare M, Shamsi A. Subthreshold Continuous Wave Autofluorescence-controlled laser treatment of chronic central serous chorioretinopathy. *J Ophthalmic Vis Res* 2018;13:236-40.

and self-limiting disease and the majority of patients have good visual prognosis. It typically affects young and middle-aged men between the ages of 20 to 50 years with no previous medical and family history and no systemic symptoms or signs. However, some cases progress to the phase of chronic CSCR with persistent serous retinal detachment, which is a more severe form occurring particularly in Asians and Hispanics. It is characterized by the widespread distribution of small pigment epithelial detachments associated with areas of RPE atrophy, extensive pigmentary changes, and fluorescein angiographic evidence of uneven hyperfluorescence with subtle leaks. It has a chronic course with exacerbations and remissions and a far more serious long-term visual prognosis.<sup>[2-5]</sup> Patients with this condition might develop progressive vision loss due to cystoid edema of the neurosensory retina or decompensation and degeneration of the retinal pigment epithelium (RPE) and the overlying photoreceptor layer.<sup>[6,7]</sup> The increasing use of indocyanine green angiography (ICGA) has demonstrated that CSCR may primarily affect the choroidal circulation, resulting in multifocal areas of choroidal vascular hyperpermeability.<sup>[8]</sup>

The traditional management options for CSCR include observation or thermal laser photocoagulation.<sup>[9]</sup> The disadvantages associated with the use of thermal laser such as RPE and retinal damage, as well as occasional occurrence of iatrogenic choroidal neovascularization (CNV) especially in chronic CSCR has led clinicians to search for newer, more effective and less harmful treatment modalities. Transpupillary thermotherapy,<sup>[10]</sup> subthreshold micropulsed diode laser treatment,<sup>[11]</sup> photodynamic therapy with verteporfin,<sup>[12,13]</sup> and intravitreal bevacizumab<sup>[14]</sup> are the treatment modalities tried in the treatment of this condition; however, these treatments are not without side effects or may be expensive and not readily available.<sup>[15]</sup>

In this prospective study, we investigated the therapeutic effect of clinically invisible subthreshold continuous wave autofluorescence-controlled green laser treatment on visual acuity and macular status of patients with chronic central serous retinopathy.

## METHODS

This is a prospective nonrandomized interventional case series of patients from university and private clinics of Shiraz, Iran who were referred with signs and symptoms of CSCR for at least 6-month duration.<sup>[16]</sup> All interventions were conducted according to the tenets of the Declaration of Helsinki and the study protocol was approved by our institution's ethics committee. Written informed consents were signed by each patient. All patients were informed about possible side effects of the treatment. Inclusion criteria consisted of presence of serous detachment in the macula involving foveal center documented by clinical

examination and optical coherence tomography (OCT) as the cause of visual symptoms, vision at least 20/200, presence of symptoms for at least 6 months, fluorescein angiographic (FA) finding of active leakages from the retinal pigment epithelium (RPE) typical of CSCR, and absence of any CNV or other maculopathies as a cause of clinical findings. Patients with preexisting retinal diseases and those with systemic diseases including diabetes mellitus, hypertension, and collagen vascular disease were excluded from the study. None of the patients had received any previous laser treatment.

After obtaining informed consent, a complete ocular examination including visual acuity, intraocular pressure measurement, refraction, slit lamp biomicroscopy, and dilated fundus exam was performed. OCT images were acquired using Stratus OCT (Carl-Zeiss, Meditec, Dublin, California, USA), and FA images were obtained using Heidelberg Retinal Angiograph 2 (HRA2; Heidelberg Engineering, Heidelberg, Germany).

Patients who were candidate for this treatment were scheduled for red free (RF) and autofluorescence (AF) imaging using Heidelberg Retinal Angiograph 2 (Spectralis OCT, Heidelberg Engineering, SN: TR-KT-1457, Germany) of the affected eye on the day of laser treatment. The threshold of laser treatment (Nidek MC300 photocoagulator, NIDEK, Co. Ltd., Aichi, Japan) was obtained from one to three test laser spots of 532 nm wavelength 80-100 milliwatt, and 100  $\mu$ m in diameter, out of the vascular arcades. The laser power for subthreshold treatment was set to 70% of threshold spot as a nonvisible 90-100  $\mu$ m spot, usually 50-70 (mean: 60) milliwatt in power applied for 0.15 second. The active leakage points with at least 350  $\mu$ m distance from foveal center were targeted by this laser setting. After treatment, the RF and AF images were repeated to document any changes in the amount of hyperautofluorescence in the treated areas. In this study, autofluorescence was used to evaluate the treatment effect (RPE darkening) in the target tissue. Patients were followed-up monthly for at least 3 months after treatment.

Main outcome measures were changes in best corrected visual acuity (BCVA) and central macular thickness (CMT); secondary outcome measures were absorption of subretinal fluid in clinical exam and OCT images, subjective feeling of improvement in visual performance, and any possible complication from treatment. Follow-up OCT images were performed between 1 to 4 months after treatment and repeated if necessary. To assess the subjective feeling of improvement in visual performance, at the 3-month follow-up examination, patients were asked to choose one of the following statements about improvement in their symptoms: 1, I feel good and I had significant improvement; 2, I had slight improvement; and 3, I had no improvement.

The nonparametric tests of Wilcoxon-signed rank test and two-tailed *t*-test were used for statistical analysis

of data. All statistical analyses were performed using IBM SPSS Statistics software version 19 (SPSS Inc., Chicago, IL). A  $P$  value of less than 0.05 was considered as significant.

## RESULTS

A total of 20 eyes from 20 patients were included in this study. Nine male and three female patients completed the 3-month follow-up and were included in the final analyses. The average age of patients was 38 years. The average follow-up period was 3.8 months (range, 3–7 months).

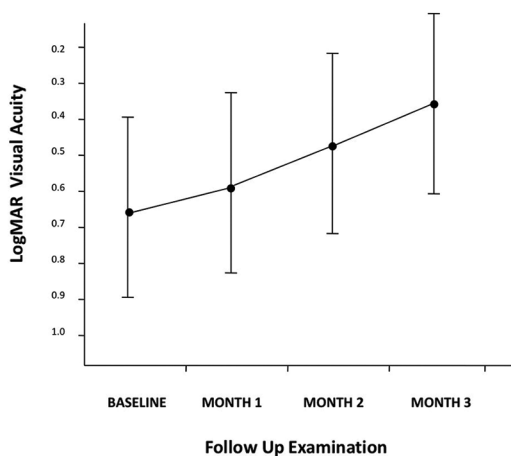
The median preoperative BCVA was 20/80, which improved to 20/40 at the final visit ( $P = 0.001$ ) [Figure 1]. The average number of laser spots per treatment was 28 (range, 12–45). The mean preoperative CMT was 330  $\mu\text{m}$  (range, 250–400) and the average final CMT in the last OCT was 188  $\mu\text{m}$  (range, 110–210) ( $P < 0.01$ ).

There was complete resolution of subretinal fluid in nine (75%) patients and significant reduction in the other three. Subjectively, eight patients felt good or had significant improvement, three reported slight improvement, and one reported no change. None of the patients had any loss of visual acuity, or any signs of macular deterioration or CNV in the follow-up period, and no significant complications attributable to treatment were detected. An example of a typical case in this study is demonstrated in Figures 2 and 3.

## DISCUSSION

Many studies on the treatment of CSCR are reported in the literature; however, finding an effective and safe treatment for CSCR remains an important goal.

Thermal laser treatment has been suggested for selected cases of CSCR,<sup>[17-19]</sup> but thermal laser treatment in chronic



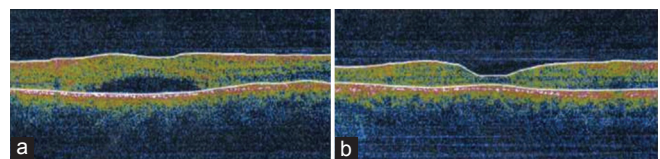
**Figure 1.** Changes in best corrected visual acuity in patients who underwent subthreshold continuous-wave AF-controlled laser treatment for chronic central serous retinopathy.

CSCR is difficult due to the presence of many leakage points, with a high possibility of producing scotoma, macular damage, RPE scar, and subretinal neovascular membrane by an extensive laser treatment.<sup>[13,20,21]</sup>

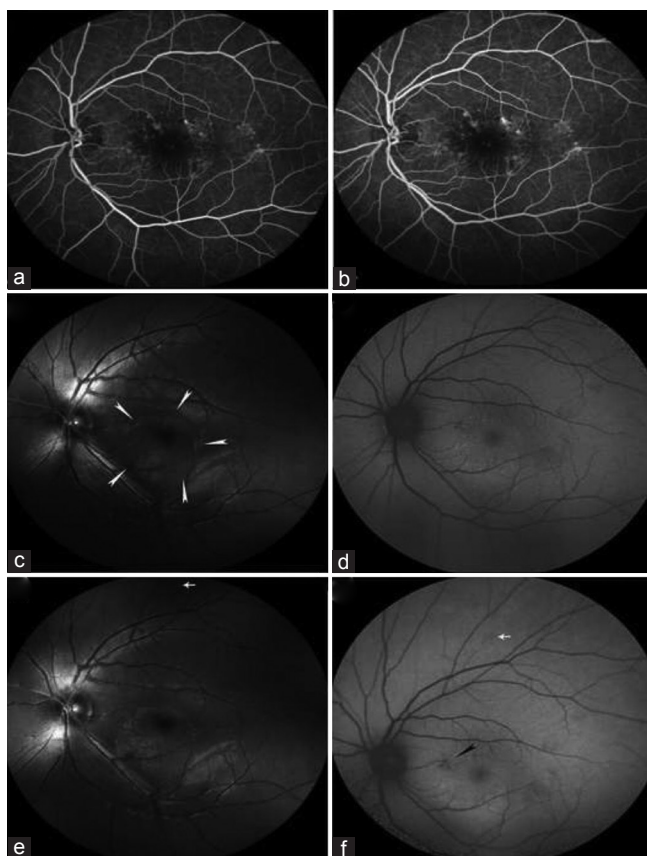
Recent reports advocate the use of photodynamic therapy (PDT) for this condition. Cardillo-Piccolino reported 75% success in reabsorption of subretinal fluid in 16 patients accompanied by one line or more increase in Snellen acuity in 69% after 3 months with PDT; however, 31% of patients showed RPE changes probably due to induced hypoxia in the choroid.<sup>[12]</sup> Similarly, Yannuzzi et al used guidance of ICGA images to avoid the healthier areas of choroidal circulation. He reported 60% fluid absorption and stable or improved vision in all patients.<sup>[16]</sup> The low visual improvement was probably due to long duration of CSCR in his patients. There is evidence of toxic effects with PDT treatment; occurrence of CNV has also been reported in association with use of this modality.<sup>[22,23]</sup> The therapeutic and toxic effects are highly dependent on the dosage of drug and applied laser energy.<sup>[24]</sup> These large laser spots are associated with collateral damage to healthy retinal tissues. Chan et al tried to enhance the safety of PDT in chronic CSCR by reducing the dose of verteporfin; they reported 89.6% resolution of subretinal fluid and stable or improved vision in more than 90% of their patients.<sup>[25]</sup> PDT is a relatively expensive modality and may not be available in many clinics worldwide. For this reason, Hussain et al used transpupillary thermotherapy in the management of 14 eyes with chronic CSCR with 78% success in reabsorption of subretinal fluid and 85% improvement of vision. However, the duration of treatment was arbitrary and the problem of collateral damage may have still been present.<sup>[10]</sup>

Selective RPE treatment by micropulsed diode laser has been used in patients with different macular situations.<sup>[26-28]</sup> This subthreshold laser treatment is aimed to reduce the collateral tissue damage while maintaining the laser effect on the target cells which are usually the RPE cells.<sup>[26,29]</sup> Several studies used a subthreshold micropulsed laser in the treatment of chronic CSCR, which was defined as persistence of disease beyond 3 months from the onset of disease in all of these studies.<sup>[30-32]</sup>

Lanzetta et al showed absorption of subretinal fluid in 75% of his cases and a good visual result, but his patients had better prognosis due to the short duration of disease



**Figure 2.** Optical coherence tomography images before (a) and 4 months after (b) treatment shows complete resolution of subretinal fluid in the macula.



**Figure 3.** Fundus fluorescein angiogram (FA) and retinal images. Early and late-phase FA images (a and b) from a representative patient with chronic central serous retinopathy shows areas of uneven hyperfluorescence with leakage points in the macula (No. 2). Preoperative red free (RF) and autofluorescence (AF) images (c and d), which show area of serous detachment (white arrowheads), and corresponding preoperative AF image from the involved area. Post-operative RF and AF images (e and f) show laser test spot (white arrows) and reduced AF at the treatment site (black arrowhead) with no visible effect in RF image in the treatment area (No. 8).

in many of them.<sup>[11]</sup> Yadav et al reported a 79% average reduction in fluid height and one line improvement in Snellen's visual acuity chart.<sup>[30]</sup>

Özmert et al compared the efficacy and safety of subthreshold micropulse yellow wavelength laser (SMYL) and low-fluence photodynamic therapy (PDT). Mean BCVA improved from  $60.7 \pm 16.3$  to  $64.4 \pm 24.9$  ETDRS letters in the PDT group and from  $67.3 \pm 14.2$  to  $71.5 \pm 21.4$  ETDRS letters in the SMYL group. Mean CMT decreased from  $242.8 \pm 80 \mu\text{m}$  to  $156.9 \pm 60 \mu\text{m}$  in the PDT group and from  $287.3 \pm 126 \mu\text{m}$  to  $138.0 \pm 40 \mu\text{m}$  in the SMYL group. Subretinal fluid (SRF) resolved completely in 72.2% and 80.0% of the eyes in the PDT and SMYL groups, respectively. They concluded that SMYL seems to be effective in the treatment of chronic CSC without any side effects and results in the reabsorption of SRF without causing visible retinal scarring.<sup>[31]</sup>

Medications such as spironolactone, eplerenone, and finasteride have also been reported to be effective in the treatment of chronic or recurrent CSCR.<sup>[17,33-35]</sup> Moisseiev et al used finasteride to treat CSCR. CMT was reduced from  $354 \pm 160 \mu\text{m}$  to  $247 \pm 85 \mu\text{m}$  at the 3-month follow-up.<sup>[33]</sup> Bousquet et al evaluated the effect of spironolactone in patients with non-resolving CSCR. They concluded that spironolactone significantly reduced both the SRF and the subfoveal choroidal thickness.<sup>[34]</sup> In another study, patients treated with eplerenone showed decrease in CMT from 342 to 275  $\mu\text{m}$  after treatment.<sup>[35]</sup>

In our study, we tried to use the most available laser instrument with the minimum amount of energy and minimum collateral damage. We defined chronic CSCR as disease with minimum of 6 months duration as reported by Yannuzzi et al.<sup>[16]</sup> We tried to combine the subthreshold laser energy used in previous studies reporting transpupillary thermotherapy<sup>[10]</sup> and limiting the area of treatment to leakage points as used in micropulsed techniques.<sup>[11]</sup> In addition, to monitor the lack of visible RPE tissue effects from the laser and to balance the possibilities of variable laser penetration through ocular media, variable absorption by RPE cell-heterogeneity, and variability in sensitivity to laser injury,<sup>[29]</sup> we monitored the tissue effect of laser using infrared and AF images and compared the postoperative images with preoperative images. Patients in this study experienced 75% resolution of subretinal fluid and significant improvement of visual acuity, comparable to the results of the above-mentioned more expensive techniques. There were no detectable side effects in the course of follow-up and our technique seems to be at least as safe as the other methods.

The most important shortcoming of our study is the small number of patients, loss of eight patients to follow-up, and lack of a control group. This technique may be a safe and effective treatment for this potentially debilitating eye disorder. Further investigations with an extended follow-up duration and enrollment of a control group is required to clarify the benefits and risks associated with this method in the management of CSCR.

### Financial Support and Sponsorship

Nil.

### Conflicts of Interest

There are no conflicts of interest.

### REFERENCES

- Gemenetzi M, Salvo GD, Lotery AJ. Central serous chorioretinopathy: An update on pathogenesis and treatment. *Eye* 2010;24:1743-1756.
- Nicholson B, Noble J, Forooghian F, Meyerle C. Central serous chorioretinopathy: Update on pathophysiology and treatment.



- Surv Ophthalmol* 2013;58:103-126.
3. Daruich A, Matet A, Dirani A. Central serous chorioretinopathy: Recent findings and new physiopathology hypothesis. *Prog Retin Eye Res* 2015;48:82-118.
  4. Castro-Correia J, Coutinho MF, Rosas V, Maia J. Long-term follow-up of central serous chorioretinopathy in 150 patients. *Doc Ophthalmol* 1992;81:379-386.
  5. Parodi MB, Pozzo SDA, Ravalico G. Photodynamic therapy in chronic central serous chorioretinopathy. *Retina* 2003;23:235-237.
  6. Loo RH, Scott IU, Flynn HW Jr, Gass JD, Murray TG, Lewis ML, et al. Factors associated with reduced visual acuity during long-term follow-up of patients with idiopathic central serous chorioretinopathy. *Retina* 2002;22:19-24.
  7. Malik A, Gupta A, Mithal C, Gupta V, Gupta YK. Central serous chorioretinopathy: Correlation of structural changes on optical coherence tomography with visual outcomes. *Delta J Ophthalmol* 2017;18:37-43.
  8. Smretschmig E, Hagen S, Glittenberg C, Ristl R, Krebs I, Binder S. Intravitreal anti-vascular endothelial growth factor combined with half-fluence photodynamic therapy for choroidal neovascularization in chronic central serous chorioretinopathy. *Eye* 2016;30:805-811.
  9. Samy CN, Gragoudas ES. Laser photocoagulation treatment of central serous chorioretinopathy. *Int Ophthalmol Clin* 1994;34:109-119.
  10. Hussain N, Khanna R, Hussain A, Das T. Transpupillary thermotherapy for chronic central serous chorioretinopathy. *Graefes Arch Clin Exp Ophthalmol* 2006;244:1045-1051.
  11. Lanzetta P, Furlan F, Morgante L, Veritti D, Bandello F. Nonvisible subthreshold micropulse diode laser (810 nm) treatment of central serous chorioretinopathy. A pilot study. *Eur J Ophthalmol* 2008;18:934-940.
  12. Silva RM, Ruiz-Moreno JM, Gomez-Ulla F, Montero JA, Gregório T, Cachulo ML, et al. Photodynamic therapy for chronic central serous chorioretinopathy: A 4-year follow-up study. *Retina* 2013;33:309-315.
  13. Naseripour M, Falavarjani KG, Sedaghat A. Half-dose photodynamic therapy for chronic central serous chorioretinopathy. *J Ophthalmic Vis Res* 2016;11:66-69.
  14. Niegel MF, Schrage NF, Christmann S, Degenring RF. Intravitreal bevacizumab for chronic central serous chorioretinopathy. *Ophthalmologie* 2008;24:232-236.
  15. Yaman A, Arikan G, Saatci AO, Cingil G. Choroidal neovascularization following photodynamic therapy in a patient with chronic central serous chorioretinopathy. *Bull Soc Belge Ophthalmol* 2007;30:69-73.
  16. Yannuzzi LA, Slakter JS, Gross NE, Spaide RF, Costa D, Huang SJ, et al. Indocyanine green angiography-guided photodynamic therapy for treatment of chronic central serous chorioretinopathy: A pilot study. *Retina* 2003;23:288-298.
  17. Abouammoh MA. Advances in the treatment of central serous chorioretinopathy. *Saudi J Ophthalmol* 2015;29:278-286.
  18. Robertson DM. Argon laser photocoagulation treatment in central serous chorioretinopathy. *Ophthalmology* 1986;93:972-974.
  19. Iacono P, Battaglia Parodi M, Falcomatà B, Bandello F. Central serous chorioretinopathy treatments: A mini review. *Ophthalmic Res* 2016;55:76-83.
  20. Khosla PK, Rana SS, Tewari HK, Azad RU, Talwar D. Evaluation of visual function following argon laser photocoagulation in central serous chorioretinopathy. *Ophthalmic Surg Lasers* 1997;28:693-697.
  21. Simon P, Glacet-Bernard A, Binaghi M, Coscas G, Soubrane G. Choroidal neovascularization as a complication following laser treatment of central serous chorioretinopathy. *J Fr Ophthalmol* 2001;24:64-68.
  22. Chan WM, Lam DS, Lai TY, Tam BS, Liu DT, Chan CK. Choroidal vascular remodelling in central serous chorioretinopathy after indocyanine green guided photodynamic therapy with verteporfin: A novel treatment at the primary disease level. *Br J Ophthalmol* 2003;87:1453-1458.
  23. Colucciello M. Choroidal neovascularization complication photodynamic therapy for central serous retinopathy. *Retina* 2006;26:239-242.
  24. Schlotzer-Schrehardt U, Viestenz A, Naumann GO, Laqua H, Michels S, Schmidt-Erfurth U. Dose-related structural effects of photodynamic therapy on choroidal and retinal structures of human eyes. *Graefes Arch Clin Exp Ophthalmol* 2002;240:748-757.
  25. Chan WM, Lai TY, Lai RY, Tang EW, Liu DT, Lam DS. Safety enhanced photodynamic therapy for chronic central serous chorioretinopathy: One-year results of a prospective study. *Retina* 2008;28:85-93.
  26. Dorin G. Subthreshold and micropulse diode laser photocoagulation. *Semin Ophthalmol* 2003;18:147-153.
  27. Laursen ML, Moeller F, Sander B, Sjoelie AK. Subthreshold micropulse diode laser treatment in diabetic macular oedema. *Br J Ophthalmol* 2004;88:1173-1179.
  28. Sivaprasad S, Sandhu R, Tandon A, Sayed-Ahmed K, McHugh DA. Subthreshold micropulse diode laser photocoagulation for clinically significant diabetic macular oedema: A three-year follow up. *Clin Experiment Ophthalmol* 2007;35:640-644.
  29. Pollack JS, Kim JE, Pulido JS, Burke JM. Tissue effects of subclinical diode laser treatment of the retina. *Arch Ophthalmol* 1998;116:1633-1639.
  30. Yadav NK, Jayadev C, Mohan A, Vijayan P, Battu R, Dabir S, et al. Subthreshold micropulse yellow laser (577 nm) in chronic central serous chorioretinopathy: Safety profile and treatment outcome. *Eye (Lond)* 2015;29:258-264.
  31. Özmert E, Demirel S, Yanık Ö, Batioğlu F. Low-fluence photodynamic therapy versus subthreshold micropulse yellow wavelength laser in the treatment of chronic central serous chorioretinopathy. *J Ophthalmol* 2016;2016:3513794.
  32. Abd Elhamid AH. Subthreshold micropulse yellow laser treatment for nonresolving central serous chorioretinopathy. *Clin Ophthalmol* 2015;9:2277-83.
  33. Moisseiev E, Holmes A J, Moshiri A, Morse LS. Finasteride is effective for the treatment of central serous chorioretinopathy. *Eye* 2016;30:850-6.
  34. Bousquet E, Beydoun T, Rothschild PR, Bergin C, Zhao M, Batista R, et al. Spirolactone for nonresolving central serous chorioretinopathy: A randomized controlled crossover study. *Retina* 2015;35:2505-2515.
  35. Cakir B, Fischer F, Ehlken C, Bühler A, Stahl A, Schlunck G, et al. Clinical experience with eplerenone to treat chronic central serous chorioretinopathy. *Graefes Arch Clin Exp Ophthalmol* 2016;254:2151-2157.