

This is an Open Access article licensed under the terms of the Creative Commons Attribution-NonCommercial-NoDerivs 3.0 License (www.karger.com/OA-license), applicable to the online version of the article only. Distribution for non-commercial purposes only.

Advanced Maxillary Sinus Cancer Treated with Concurrent Chemoradiotherapy with Intra-Arterial Cisplatin/Docetaxel and Oral S-1: Own Experience and Literature Review

Torahiko Nakashima^a Ryuji Yasumatsu^a Satoshi Toh^a
Hideki Shiratsuchi^a Takeshi Kamitani^b
Yoshiyuki Shioyama^c Katsumasa Nakamura^b
Shizuo Komune^a

Departments of ^aOtolaryngology-Head and Neck Surgery, ^bClinical Radiology and ^cHeavy Particle Therapy and Radiation Oncology, Graduate School of Medical Sciences, Kyushu University, Fukuoka, Japan

Key Words

Head and neck cancer · Intra-arterial chemoradiotherapy · Cisplatin · Docetaxel · S-1

Abstract

Intra-arterial (IA) chemotherapy for head and neck cancer is effective and multiple IA concurrent chemoradiation (CCRT) protocols have been reported. However, the role of IA CCRT in the multimodality treatment of head and neck cancer is still controversial. We have treated 5 cases of unresectable T4 maxillary sinus squamous cell carcinoma with IA cisplatin (CDDP) and docetaxel (DOC) and CCRT with oral S-1. We report our experience and the effectiveness and feasibility of this combination as an alternative choice of treatment for inoperable head and neck cancer. The patients received an IA infusion of CDDP (50–70 mg/m²) and DOC (50–60 mg/m²) through the femoral artery, followed by CCRT with oral S-1. The IA infusion was repeated up to 3 times and the radiation was dosed at up to 60–70 Gy. Complete response was achieved in 4 patients and partial response in one, giving an overall response rate of 100%. The most common grade 3 or 4 toxicities were anorexia (80%), mucositis (80%) and leukopenia (80%), all of which were manageable. CCRT with IA CDDP/DOC and oral S-1 was effective and tolerated. Although preliminary, the response rate encourages further pursuit and definitive evaluation of this combination for the treatment of inoperable advanced head and neck cancer.

Introduction

Owing to the development of interventional radiological techniques, intra-arterial (IA) chemotherapy for treating head and neck cancer is nowadays widely used and has been studied and evaluated in many institutions. Protocols combining IA chemotherapy with concurrent radiotherapy demonstrated high organ preservation rates in locally advanced head and neck cancer. Multiple trials, particularly those using high-dose cisplatin (CDDP) (RADPLAT) have been reported to show a high response rate [1, 2]. However, the feasibility and the effectiveness of the RADPLAT protocol are still controversial [3, 4].

Docetaxel (DOC) is commonly used in concurrent chemoradiotherapy (CCRT) for head and neck cancer [5–7]. IA chemotherapy combining DOC and CDDP has also previously been reported to be effective in treating head and neck cancer [8, 9].

S-1 is an oral fluorouracil anticancer agent consisting of tegafur, 5-chloro-2,4 dihydropyridine, which inhibits dihydropyrimidine dehydrogenase enzyme activity, and oteracil (potassium oxonate) as an inhibitor of gastrointestinal side effects [10]. In our institution, CCRT using S-1 and retinyl palmitate has been used for treating head and neck cancer to pursue the possibility of organ preservation [11, 12]. In the present study on treating locally advanced unresectable maxillary sinus cancer, IA infusion of CDDP and DOC was added to the regular CCRT with S-1 to maximize the local effect of the CCRT. The aim of this paper is to describe our experience and the effectiveness and feasibility of the combination of IA CDDP, DOC and CCRT with oral S-1 in the treatment of highly advanced maxillary sinus cancer.

Patients and Methods

Between July 2007 and March 2008, 5 patients (3 men, 2 women) with unresectable T4 squamous cell carcinoma of the maxillary sinus (including one patient refusing radical operation) underwent our IA CCRT protocol. Eligible patients were aged <75 years with a performance status of 0 to 1 (table 1). All patients were fully informed about the treatment protocol and written informed consent was obtained.

IA Chemotherapy

The femoral artery was punctured under local anesthesia by Seldinger's method. The tip of the catheter was threaded into the external carotid artery. Fluorography was performed through a micro-catheter to determine the dominant tumor-supplying vessel with digital angiography. Cone-beam computed tomography was also used during angiography to ascertain the stained area. In cases which had multiple tumor-supplying vessels, the dose of CDDP and DOC was divided according to the stained tumor volume.

IA infusion of CDDP (50–70 mg/m²) and DOC (50–60 mg/m²) was administered through the micro-catheter on day 1 (fig. 1). The doses of the agents were determined mainly depending on the patients' residual renal and bone marrow functions. A 5-HT₃-receptor antagonist was also given to all patients to reduce nausea/vomiting. For patients who were judged to need multiple courses of chemotherapy, IA infusion was repeated up to 3 times in intervals of 4–6 weeks. Depending on the general conditions of the 5 patients, 2 patients received an IA infusion once, 2 patients twice and one patient 3 times (table 1).

Radiotherapy with S-1

Three-dimensional conformal radiotherapy was performed to the primary sites and regional cervical lymph node areas through a linear accelerator with a 4-MV X-ray. The start of radiotherapy ranged from day 3 to day 7 depending on the general condition of the patient. Conventional fractionation was used with a daily dose of 1.8–2.0 Gy, 5 times a week up to a total dose of 60–70 Gy (fig. 1). S-1 was concurrently administered to the patients orally twice daily at an initial dose of 65 mg/m²/day [patients with a body surface area (BSA) >1.5 m² received 100 mg/day, patients with 1.25 m² < BSA < 1.5 m² received 80 mg/day, and patients with a BSA <1.25 m² received 50 mg/day]. Patients with renal dysfunction received a 60–80% reduced dose of S-1. Retinyl palmitate (50,000 U/day) was also administered intra-muscularly on each day of radiation as an adjuvant for CCRT. S-1 administration was stopped if grade IV toxicity (leukopenia) due to the IA chemotherapy appeared.

Evaluation of Response and Toxicity

Clinical responses of the CRT were evaluated by inspection, fiberscope examination, CT, and MRI 4 weeks after completion of therapy and FDG-PET was performed 8–10 weeks after completion.

All toxicities due to the protocol were evaluated according to the National Cancer Institute-Common Toxicity Criteria (ver. 4.0).

Results

Clinical Response

Five patients with locally advanced maxillary sinus cancer were treated according to our protocol and were evaluated. All patients required hospitalization for intensive care. Their ages ranged from 37 to 67 years. Four patients were considered to have functionally unresectable disease and 1 patient refused surgery. Histologically, all cases were squamous cell carcinoma. Patients' characteristics and results are listed in table 1. The median follow-up duration was 24 months (range 22–36). Of the 5 patients, 4 had a complete response (fig. 2) and one had a partial response, resulting in an overall response rate of 100%. In one case with partial response in the primary region, systemic chemotherapy was given.

Toxicity (table 2)

Table 2 shows the major adverse events during therapy. The most common grade 3 or 4 toxicities were anorexia, mucositis and leukopenia, all of which were manageable. Treatment was temporarily suspended in 3 cases due to the toxicity (febrile neutropenia); however, all patients recovered within 10 days. There was one case with grade 4 colitis which was suspected to be a side effect of DOC and S-1.

Discussion

IA chemotherapy has been reported to be suitable for head and neck cancer therapy because of its easy access to the arterial system. Multiple IA chemoradiation protocols have been reported for head and neck cancer treatment, among which RADPLAT has

been studied most widely [1, 2]. Robbins et al. [2] reported the feasibility and the effectiveness of the RADPLAT protocol in a multi-institutional setting. However, in 2010, Rasch et al. [3] reported that RADPLAT was not superior to intravenous chemoradiation for advanced head and neck cancer patients regarding locoregional control and survival. The effectiveness of IA chemoradiation in the treatment of locally advanced head and neck cancer is still controversial.

For patients who have unresectable (T4b) disease or who refuse to receive radical operation, CCRT is the current standard therapy. However, it is still difficult to control highly advanced disease by conventional intravenous CCRT protocols. IA infusion allows exposure of the tumor tissue to a high concentration of chemotherapeutic agents. The effectiveness of chemoradiation for highly advanced locoregional disease is maximized if IA CCRT protocols are used in an appropriate patient setting.

Our IA chemoradiation protocol using IA infusion of DOC and CDDP and oral S-1 revealed a high locoregional effect in patients with unresectable head and neck cancer. The combination of DOC and CDDP has been applied to the treatment of multiple cancer types including head and neck cancer [9, 13]. The advantage of this regimen is that the combination of DOC and CDDP has a synergistic anti-cancer effect of the G₂ cell cycle arrest caused by DOC and the G₁ cell cycle arrest caused by CDDP. DOC has also been reported to enhance the cytotoxicity of CDDP to cancer cells by modifying intracellular platinum metabolism [14]. Using a regular dose of CDDP instead of a single high dose, neutralization of the systemic flow of the agents, which is needed in the RADPLAT protocol, becomes superfluous. Additionally, a systemic effect targeting subclinical metastasis can be expected.

Grade 3–4 acute toxicity was observed in 80% of the patients. The incidence of leukopenia and mucositis was high and therefore careful management is necessary. Although not so frequent, colitis due to DOC infusion is an important side effect which should be noted. Kreis et al. [15] first reported on neutropenic enterocolitis. With the combination with S-1, which is another enterotoxic agent, gastroenterological toxicities should be meticulously observed.

Since the report by Rasch et al. [3], the efficacy of IA chemoradiation for head and neck cancer has been questioned. However, we believe that if technical procedures and protocols are improved, IA CCRT is still an effective method for a certain group of patients. Although feasibility was proved, the incidence of toxic events, mainly hematologic, was high and our protocol may not be suitable as a standard therapy. However, the response rate encourages further pursuit and definitive evaluation of this combination for treating locally highly advanced unresectable head and neck malignancies.

Table 1. Patients' characteristics and results

Patient No.	Age/gender	T	N	IA infusions (n)	Results	Treatment followed	Survival period	Alive at present
1	45/F	4b	2b	3	CR	chemotherapy	36 months	yes
2	67/M	4a	2b	2	PR		27 months	unknown
3	37/M	4b	0	1	CR		26 months	yes
4	62/M	4b	2b	2	CR		22 months	yes
5	61/F	4a	0	1	CR		22 months	yes

Table 2. Incidence of major acute toxicity (\geq grade 3)

Mucositis	4 (80%)
Leukopenia	4 (80%)
Nausea/vomiting	1 (20%)
Diarrhea	1 (20%)
Anorexia	3 (60%)

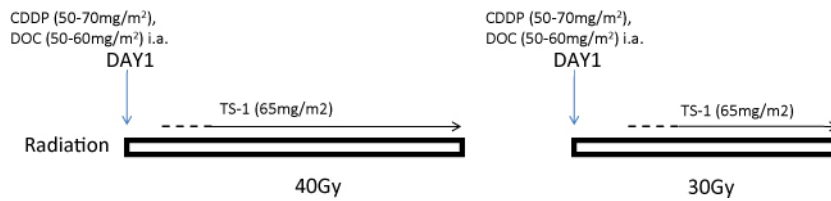


Fig. 1. Treatment schedule for chemoradiotherapy using IA infusion.

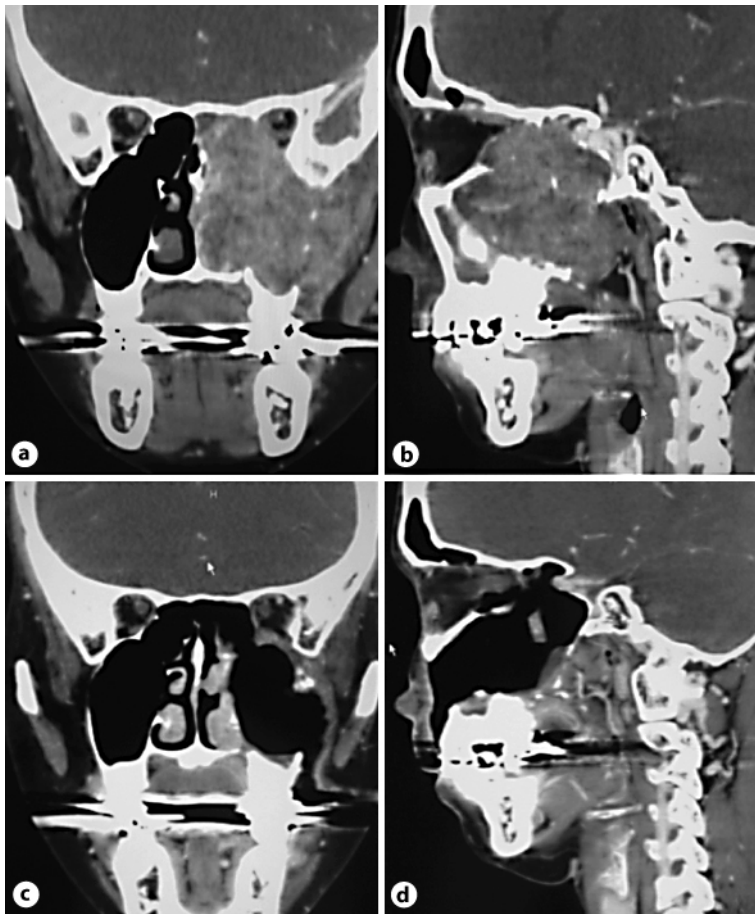


Fig. 2. Squamous cell carcinoma of the left maxillary sinus (case No. 1: T4aN0M0). Enhanced CT scan (**a** coronal view; **b** sagittal view) shows a tumor in the left maxillary sinus extending to the orbital apex. After treatment, clinical CR was obtained (**c** coronal view; **b** sagittal view).

References

- 1 Robbins KT, Storniolo AM, Kerber C, Vicario D, Seagren S, Shea M, Hanchett C, Los G, Howell SB: Phase I study of highly selective supradose cisplatin infusions for advanced head and neck cancer *J Clin Oncol* 1994;12:2113–2120.
- 2 Robbins KT, Kumar P, Harris J, McCulloch T, Cmelak A, Sofferman R, Levine P, Weisman R, Wilson W, Weymuller E, Fu K: Supradose intra-arterial cisplatin and concurrent radiation therapy for the treatment of stage IV head and neck squamous cell carcinoma is feasible and efficacious in a multi-institutional setting: results of Radiation Therapy Oncology Group Trial 9615. *J Clin Oncol* 2005;23:1447–1454.
- 3 Rasch CR, Hauptmann M, Schornagel J, Wijers O, Buter J, Gregor T, Wiggendaad R, de Boer JP, Ackerstaff AH, Kroger R, Hoebbers FJ, Balm AJ, Hilgers FJ: Intra-arterial versus intravenous chemoradiation for advanced head and neck cancer: Results of a randomized phase 3 trial. *Cancer* 2010;116:2159–2165.
- 4 Foote RL, Kasperbauer JL, Okuno SH, Nichols DA, Olsen KD, Brown PD, Garces YI, Sargent DJ, Strome SE: A pilot study of high-dose intraarterial cisplatin chemotherapy with concomitant accelerated radiotherapy for patients with previously untreated T4 and selected patients with T3N0–N3M0 squamous cell carcinoma of the upper aerodigestive tract. *Cancer* 2005;103:559–568.
- 5 Schrijvers D, Vermorken JB: Taxanes in the treatment of head and neck cancer. *Curr Opin Oncol* 2005;17:218–224.

- 6 Fujii M, Tsukuda M, Satake B, Kubota AA, Kida A, Kohno N, Okami K, Inuyama Y: Phase I/II trial of weekly docetaxel and concomitant radiotherapy for squamous cell carcinoma of the head and neck. *Int J Clin Oncol* 2004;9:107–112.
- 7 Calais G, Bardet E, Sire C, Alfonsi M, Bourhis J, Rhein B, Tortochaux J, Man YT, Auvray H, Garaud P: Radiotherapy with concomitant weekly docetaxel for stages III/IV oropharynx carcinoma. Results of the 98–02 GORTEC Phase II trial. *Int J Radiat Oncol Biol Phys* 2004;58:161–166.
- 8 Maruya S, Namba A, Matsubara A, Kakehata S, Takeda I, Shirasaki T, Hatayama Y, Nagahata M, Yokoyama J, Shinkawa H: Salivary gland carcinoma treated with concomitant chemoradiation with intraarterial cisplatin and docetaxel. *Int J Clin Oncol* 2006;11:403–406.
- 9 Mitsudo K, Shigetomi T, Fujimoto Y, Nishiguchi H, Yamamoto N, Furue H, Ueda M, Itoh Y, Fuwa N, Tohnai I: Organ preservation with daily concurrent chemoradiotherapy using superselective intra-arterial infusion via a superficial temporal artery for T3 and T4 head and neck cancer. *Int J Radiat Oncol Biol Phys* 2011;79:1428–1435.
- 10 Shirasaka T, Shimamoto Y, Ohshimo H, Yamaguchi M, Kato T, Yonekura K, Fukushima M: Development of a novel form of an oral 5-fluorouracil derivative (S-1) directed to the potentiation of the tumor selective cytotoxicity of 5-fluorouracil by two biochemical modulators. *Anticancer Drugs* 1996;7:548–557.
- 11 Ohnishi K, Shioyama Y, Nakamura K, Nakashima T, Ohga S, Nonoshita T, Yoshitake T, Terashima K, Komune S, Honda H: Concurrent chemoradiotherapy with S-1 as first-line treatment for patients with oropharyngeal cancer. *J Radiat Res (Tokyo)* 2011;52:47–53.
- 12 Nonoshita T, Shioyama Y, Nakamura K, Nakashima T, Ohga S, Yoshitake T, Ohnishi K, Terashima K, Asai K, Honda H: Concurrent chemoradiotherapy with S-1 for T2N0 glottic squamous cell carcinoma. *J Radiat Res (Tokyo)* 2010;51:481–484.
- 13 Inohara H, Inoue T, Akahani S, Yamamoto Y, Takenaka Y, Nakagawa T, Isohashi F, Kubo T: Concurrent chemoradiotherapy with cisplatin and docetaxel for advanced head and neck cancer. A phase I study. *Anticancer Res* 2004;24:4135–4140.
- 14 Maeda S, Sugiura T, Saikawa Y, Kubota T, Otani Y, Kumai K, Kitajima M: Docetaxel enhances the cytotoxicity of cisplatin to gastric cancer cells by modification of intracellular platinum metabolism. *Cancer Sci* 2004;95:679–684.
- 15 Kreis W, Petrylak D, Savarese D, Budman D: Colitis and docetaxel-based chemotherapy. *Lancet* 2000;355:2164.