



Direct transmesenteric venous interventions in the acute post liver transplant setting



Keshav Anand, MD, MPH, Luis Garza^{*}, Glenn Half, MD, Tarunjeet Klair, MD, Francisco Cigarroa, MD, Rajeev Suri, MD, Jorge Lopera, MD

UT Health San Antonio Long School of Medicine, 7703 Floyd Curl Dr, San Antonio, TX, 78229, USA

ABSTRACT

Introduction: Portal venous thrombosis and stenosis are uncommon but serious causes of liver transplant graft failure. While surgical thrombectomy can be utilized for the treatment of portal steno-occlusive disease, venous interventions with IR have been performed with encouraging results.

Case description: 69-year-old female with non-alcoholic steatohepatitis cirrhosis who received a liver transplant complicated by portal vein thrombus. Efforts between transplant surgery and IR allowed for successful thrombus removal via direct SMV access.

Results: The advantages of direct SMV access with the surgery team include direct approach to accessing thrombus, sparing of liver parenchyma, and significant hemostatic control.

Introduction

Portal venous thrombosis and stenosis are uncommon but serious causes of liver transplant graft failure.^{1–3} While surgical thrombectomy and revision can be utilized for the treatment of portal venous thrombosis or stenosis, interventional transluminal portal thrombolysis, angioplasty, and stent placement have been performed with encouraging results.^{1,3–7} Nevertheless, the liver graft is vulnerable to percutaneous transhepatic procedures in the early post-transplantation period because the graft is not fixed.^{3,4,8} To overcome the problem, direct transmesenteric or splenic venous access has been attempted in patients with early post-transplantation portal venous thrombosis or stenosis.^{3–8} To our knowledge, direct transmesenteric venous access has been described mainly in pediatric patients and little is known about its technical feasibility and efficacy in adult patients. Therefore, the purpose of this study was to retrospectively evaluate the technical feasibility and clinical efficacy of transmesenteric venous access in the early post-operative setting for adult patients with portal venous steno-occlusive disease.

Case series

Case 1

69-year-old female with non-alcoholic steatohepatitis cirrhosis who received a living donor liver transplant. During transplantation, patient was noted to have a large splenorenal shunt which the transplant team

was prepared to ligate, however it was not performed after initial perfusion of transplanted liver showed good hepatic arterial, venous and portal waveforms. Initial post-operative course was unremarkable. Three days after transplantation, patient had US duplex of the liver demonstrating decreasing portal velocities including velocity after the anastomosis of 8.9 cm/s while initial US post transplantation demonstrated velocities greater than 50 cm/s. Patient was taken for exploratory laparotomy to ligate the large splenorenal shunt diverting flow. Post-operative US demonstrated improved portal velocities. The following day, US demonstrated thrombus within the main and right portal vein confirmed by 3-phase CT (Fig. 1), a common occurrence after shunt interventions. Patient was taken for repeat exploratory laparotomy with interventional radiology called for venous interventions. In the operating room, the SMV was exposed by the transplant team. Direct superior mesenteric vein (SMV) access was obtained with a micro puncture set and a 5 Fr sheath (Micropuncture® Access Set, Cook Group, Bloomington, IN 47402) was placed in the SMV. Portal venogram demonstrated nonocclusive thrombus in the distal main portal vein (MPV) (Fig. 2). The 5 Fr sheath was exchanged for an 8 Fr sheath and a CAT8 Indigo suction thrombectomy catheter (Penumbra, Indigo® System Catheters & Separators, Alameda, CA 94502) was placed through the sheath with aspiration of thrombus in MPV being performed. Post thrombectomy venogram demonstrated resolution of the thrombus (Fig. 3). Venotomy closure was performed by the transplant team. The patient had an uneventful course post thrombectomy with subsequent US studies demonstrating no filling defects and CT scan two days later

^{*} Corresponding author.

E-mail address: GarzaL11@livemail.uthscsa.edu (L. Garza).

<https://doi.org/10.1016/j.jimed.2020.09.001>

Received 5 August 2020; Received in revised form 17 August 2020; Accepted 7 September 2020

Available online 8 September 2020

2096-3602/© 2020 Shanghai Journal of Interventional Radiology Press. Publishing services by Elsevier B.V. on behalf of KeAi Communications Co. Ltd.

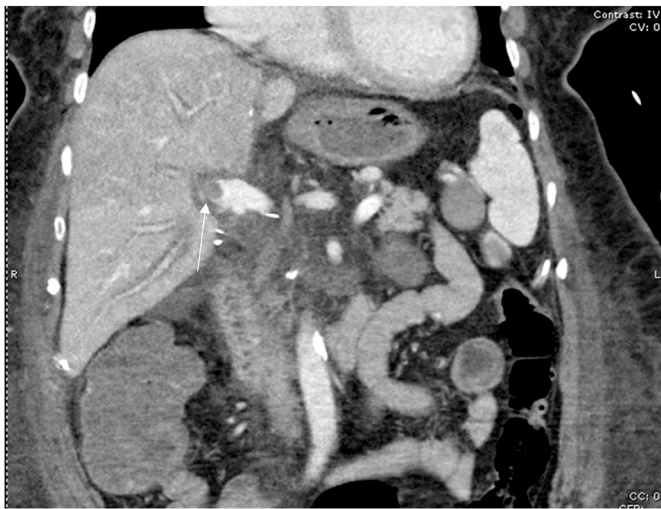

Fig. 1. CT venous phase demonstrating thrombus (white arrow) of the distal MPV.

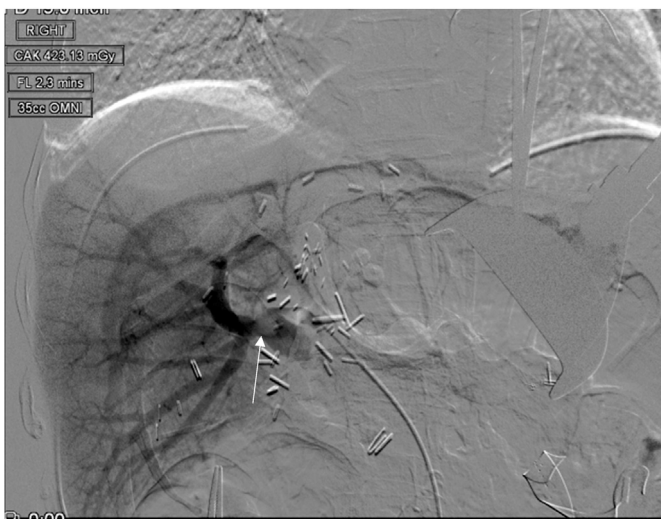

Fig. 2. Pre intervention direct portal venogram demonstrating a filling defect (white arrow) in the distal MPV compatible with a thrombus.

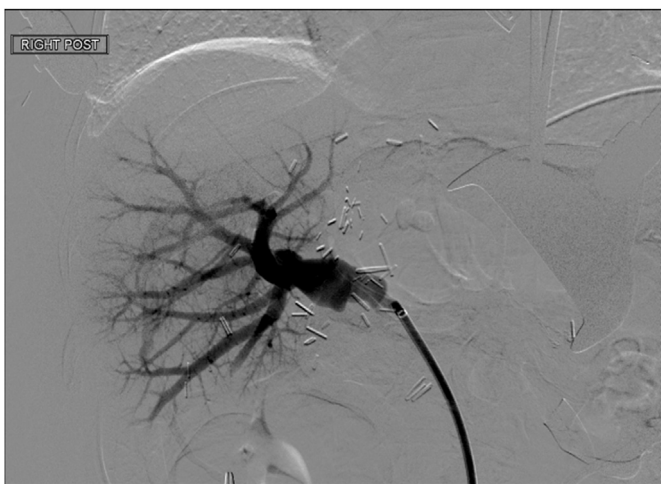

Fig. 3. Post thrombectomy direct portal venogram demonstrating resolution of the thrombus and patent portal veins.

demonstrating patency of the portal vasculature. Patient was discharged home eight days after thrombectomy procedure. Patient was maintained on Lovenox and Aspirin for 3 months after procedure. A contrast enhanced MRI obtained 8 months after transplant demonstrated patency of the portal venous system (Fig. 4). An US at this time demonstrated normal velocities without signs of liver decompensation.

Discussion

Acute portal venous thrombosis and stenosis are uncommon but serious complications seen in post-liver transplantation with an approximated prevalence of 1%–3%.⁶ Acute MPV thrombosis following liver transplantation can lead to liver ischemia, infarction, and even extensive parenchymal necrosis leading to graft failure requiring re-transplantation.⁶ MPV thrombosis has traditionally been treated with surgical thrombectomy and revision, however, surgical treatment has been gradually replaced by interventional transluminal thrombectomy, angioplasty, and stent placement.^{1,3–8} Routes of transluminal treatment included transhepatic,^{1,6,7} transjugular,⁶ transsplenic^{4,6,8} and intraoperative inferior mesenteric vein approaches.^{3,5–7} Kim and his co-workers³ reported that intraoperative portal vein approach via the inferior mesenteric vein in fourteen patients with early post-transplantation portal vein steno-occlusive disease was less injurious to the transplanted liver without any complications and failures.

The incidence of portal vein steno-occlusive disease was noted by transplant surgery to be more common with live-donor liver transplants because of their split incomplete nature. Particularly, there can be size mismatch between the donor and recipient portal veins with high stenosis complications secondary to short donor portal vein stumps. Surgical thrombectomy alone is most successful with deceased-donor liver transplantation as the donor liver anatomy is whole allowing for more surgical manipulation options. Direct access of the superior mesenteric vein is possible as transplant surgeons can easily reveal the vessel secondary to its anterior location, this view is complicated with obese patients owing to excess mesenteric fat and patients with history of multiple abdominal surgeries.

To our knowledge, intraoperative portal vein approach via the SMV has not been described previously and we found that access was technically easy and useful for the treatment of steno-occlusive disease. In contrast to the inferior mesenteric vein and splenic vein approach, the

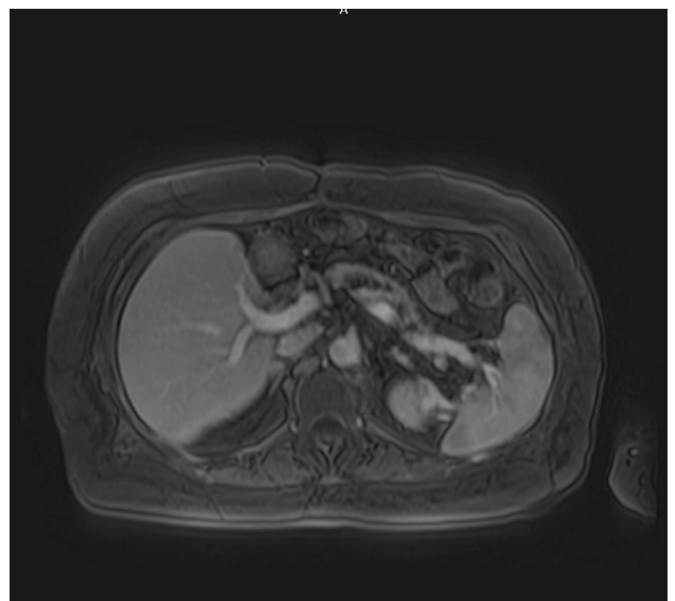


Fig. 4. Post-contrast axial MRI taken 8 months post-venous intervention demonstrating patent portal veins.

path of the SMV to the MPV is straightforward and shorter. We found if the portal thrombus is intrahepatic, then a straight SMV approach is a better option. Intraoperative IMV approach has been successful in treating portal vein thrombosis with balloon angioplasty and stenting, however, its size has been limited to a 5 Fr sheath.⁵ Splenic vein approach has been described as technically challenging requiring careful precision and coordination.⁸ Improved success in ultra-sound guided cannulation was noted in splenomegaly patients secondary to enlarged splenic veins however only up to 6 Fr vascular sheaths were utilized. SMV approach is capable of up to 8 Fr sheath placement to accommodate suction thrombectomy catheters. The advantages of direct SMV access in conjunction with the surgery team include a more direct approach to accessing thrombus, sparing of liver parenchyma, and significant hemostatic control is possible with transverse ligation of puncture sites. Additionally, the use of intraoperative US allows for improved visualization of the portal vein and its' branches of interest to assess for residual clot burden.

Conclusion

Transmesenteric venous interventions for portal vein steno-occlusive disease can be a viable treatment option in the management of these conditions in the acute post-operative setting. Particularly, SMV access has multiple advantages compared to other more conventional approaches. Overall, a multidisciplinary approach in conjunction with the transplant surgery team is recommended to triage and treat patients with these complications.

Funding

This study was not supported by any funding.

Consent

For this type of study formal consent is not required.

Informed consent was obtained from all individual participants included in the study.

Consent for publication was obtained for every individual person's data included in the study.

Declaration of competing interest

The authors declare that they have no conflict of interest.

References

1. Wang J, Yang W, Huang Q, et al. Interventional treatment for portal venous occlusion after liver transplantation: long-term follow-up results. *Medicine (Baltimore)*. 2015;94:e356.
2. Duffy JP, Hong JC, Farmer DG, et al. Vascular complications of orthotopic liver transplantation: experience in more than 4,200 patients. *J Am Coll Surg discussion*. 2009;208:903–905, 896–903.
3. Kim YJ, Ko GY, Yoon HK, et al. Intraoperative stent placement in the portal vein during or after liver transplantation. *Liver Transpl*. 2007;13:1145–1152.
4. Chen CL, Concejero AM, Ou HY, et al. Intraoperative portal vein stent placement in pediatric living donor liver transplantation. *J Vasc Interv Radiol*. 2012;23:724–725.
5. Shim DJ, Ko GY, Sung KB, et al. Long-Term Outcome of Portal Vein Stent Placement in Pediatric Liver Transplant Recipients: A Comparison with Balloon Angioplasty. *J Vasc Interv Radiol*. 2018;29:800–808.
6. Itri JN, Heller MT, Tublin ME. Hepatic transplantation: postoperative complications. *Abdom Imaging*. 2013;38:1300–1333.
7. Czerwonko ME, Pekolj J, Mattera J, et al. Intraoperative stent placement for the treatment of acute portal vein complications in pediatric living donor liver transplantation. *Langenbecks Arch Surg*. 2019;404:123–128.
8. Brown MA, Donahue L, Gueyikian S, et al. Endovascular transsplenic recanalization with angioplasty and stenting of an occluded main portal vein in an adult liver transplant recipient. *Radiol Case Rep*. 2020;15:615–623.