

Scientific Article

Nonuniform Planning Target Volume Margins for Prostate Bed on the Basis of Surgical Clips on Daily Cone Beam Computed Tomography

Haijun Song PhD*, Joseph K. Salama MD, William Robert Lee MD, Qiuwen Wu PhD

Duke University Medical Center, Department of Radiation Oncology, Durham, North Carolina

Received 9 May 2018; revised form 31 August 2018; accepted 27 September 2018



Abstract

Purpose: We hypothesized that the interfraction motions of the superior and inferior prostate beds differ and therefore require different margins. In this study, we used daily cone beam computed tomography (CBCT) to evaluate the motion of postprostatectomy surgical clips (separated to superior and inferior portions) within the planning target volume (PTV) to derive data-driven PTV margins.

Methods and Materials: Our study cohort included consecutive patients with identifiable surgical clips undergoing prostate bed irradiation with daily CBCT image guidance. We identified and contoured the clips within the PTV on the planning computed tomography and CBCT scans. All CBCT scans were registered to the planning computed tomography scan on the basis of pelvic bony structures. The superior border of the pubic symphysis was used to mark the division between the superior and inferior portions.

Results: Eleven patients with 263 CBCT scans were included in the cohort. In the left–right direction, the global mean M , systematic error Σ , and residue error σ were 0.02, 0.03, and 0.16 cm, respectively, for superior clips, and 0.00, 0.03, and 0.03 cm, respectively, for inferior clips. In the anterior–posterior direction, the corresponding values were $M = 0.01$, $\Sigma = 0.25$, and $\sigma = 0.37$, respectively, for superior, and $M = 0.08$, $\Sigma = 0.13$, $\sigma = 0.15$, respectively, for inferior. In the superior–inferior direction, the values were $M = -0.06$, $\Sigma = 0.23$, and $\sigma = 0.27$, respectively, for superior, and $M = -0.01$, $\Sigma = 0.21$, $\sigma = 0.20$, respectively, for inferior. The results of the 2-tailed F tests showed that the anterior–posterior motion is statistically different between the superior and inferior portions in the anterior–posterior direction. There is no statistical difference in the superior–inferior and lateral directions. Therefore, we propose a set of nonuniform PTV margins (based on the formula $2.5 \Sigma + 0.7 \sigma$) as 0.2 cm for all prostate beds in the left–right direction, 0.7 cm for all in superior–inferior, and 0.9 to 0.4 for superior–inferior in the anterior–posterior direction.

Conclusions: The difference in motion between the superior and inferior portions of the prostate bed is statistically insignificant in the left–right and superior–inferior directions, but statistically significant in the anterior–posterior direction, which warrants a nonuniform PTV margin scheme.

© 2018 The Authors. Published by Elsevier Inc. on behalf of American Society for Radiation Oncology. This is an open access article under the CC BY-NC-ND license (<http://creativecommons.org/licenses/by-nc-nd/4.0/>).

Sources of support: This work had no specific funding.

Conflicts of interest: The authors have no conflicts of interest to disclose.

* Corresponding author. Box DUMC 3295, 200 Trent Drive, Durham, NC 27710.

E-mail address: haijun.song@duke.edu (H. Song).

<https://doi.org/10.1016/j.adro.2018.09.014>

2452-1094/© 2018 The Authors. Published by Elsevier Inc. on behalf of American Society for Radiation Oncology. This is an open access article under the CC BY-NC-ND license (<http://creativecommons.org/licenses/by-nc-nd/4.0/>).

Introduction

After a radical prostatectomy, adjuvant or salvage radiation has demonstrated improved biochemical control and survival in patients with high-risk pathologic features or an increasing prostate-specific antigen (PSA) level.^{1–3} However, the specific clinical target volumes used in postprostatectomy randomized trials and consensus guidelines vary widely. The expansions used to form the planning target volume (PTV) also vary. Understanding the movement of the postprostatectomy bed is important to ensure proper coverage because rectal and bladder filling are known to affect its position. Bell et al.⁴ analyzed the motion of the superior and inferior portions of the prostate bed separately and proposed a nonuniform PTV margin owing to the different observed motion between the superior and inferior in the anterior–posterior (AP) direction. However, Verma et al.⁵ concluded that there was no significant difference between the superior and inferior portions in the AP direction.

Prior attempts to analyze the motion of the prostate bed have used either on-board kV imaging, on-board cone beam computed tomography (CBCT), or computed tomography (CT)-on-rails, all with some limitations. Although CT-on-rails provides high-quality CT images, the delineation of the low-contrast soft-tissue target can still be a challenge and carries an inherent large uncertainty.⁵ The delineation of soft-tissue targets should be even more of a challenge with CBCT because of its poor soft tissue contrast.⁶ Huang et al.⁷ identified high-contrast surgical clips on CBCT images but did not separate the prostate bed into superior and inferior portions. Sandhu et al.⁸ and Song et al.⁹ used on-board kV imaging to identify surgical clips. Because of the limitation associated with 2-dimensional imaging, the studies were limited to a small number of surgical clips or clips as one single mass.

Given the uncertainty of prostate bed motion, we decided to examine this motion within our patients. We sought to use a patient cohort with surgical clips to allow for a separate evaluation of the superior and inferior portion of the prostate bed using daily setup CBCT images.

Methods and materials

We identified postprostatectomy patients who received adjuvant or salvage radiation from 2008 to 2014. All patients followed a regimen of full bladder and empty rectum at the time of treatment planning CT and each fraction of radiation delivery. Patients were simulated supine in Combifix (CIVCO Radiation Therapy, Coralville, IA), which is indexed to the treatment table and immobilizes the patient within the device from the pelvis to the feet with indexed positions for the feet and legs.

The planning CT scans were performed on a Philips Brilliance Big Bore CT with 3-mm slices. In general, the clinical target volume was contoured based on the Radiation Therapy Oncology Group consensus definition^{10,11} and expanded 5 mm in each direction to form the PTV. Subsequently, all patients were planned with a prescription dose of 65 Gy in 26 daily fractions of 2.5 Gy.

Each day before treatment, patients were immobilized, and then a CBCT scan was acquired. The CBCT system had a Varian 21EX model linear accelerator using its pelvis mode with half bowtie beam filter and half-fan beam. This mode of CBCT uses projections from a full circle.

The slice thickness was 2.5 mm. The status of the empty rectum and full bladder was verified for each radiation treatment. If not achieved, the patient would be taken off the table to repeat the bladder and rectum preparation.

Patients were deemed to have usable clips based on the following criteria: at least 3 separable surgical clips within the prostate bed PTV, and the clips had to be recognizable and traceable throughout the subsequent CBCT image sets. Some patients' CBCT scans had strong artifacts caused by the metal clips. These patients were excluded owing to poor overall image quality.

For each patient, all daily CBCT sets were registered to the planning CT offline on the basis of the bony structure of the pelvic area. Automatic image coregistration with 6 degrees of freedom (6D matching) was performed using CBCT scans in accordance with the bony pelvic anatomy with an operator-selected shoebox volume that contained the sacrum, symphysis pubis, and both femoral heads. Each selected clip was contoured manually on the radiation planning CT and transferred to each registered CBCT. Each transferred clip was manually verified and refined in each CBCT set. The coordinates of each clip centroid within each image set was recorded in left–right (LR), AP, and superior–inferior (SI) directions. We used the axial slice at the superior border of the pubic bone to separate the superior and inferior portions of the prostate

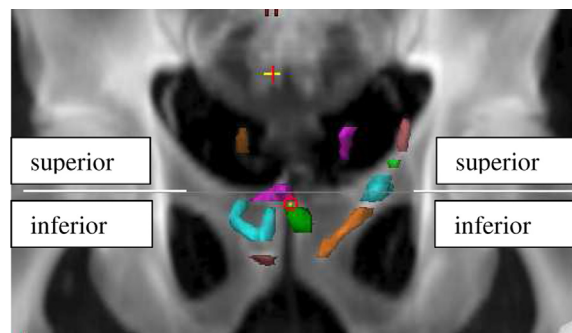


Figure 1 Coronal view of a prostate bed, separated into superior and inferior portions along the superior border of the pubic bone. Also shown are segments of the surgical clips that are identified as trackable through all cone beam computed tomography sets. The position of each clip is represented by its center of mass.

bed as shown in Figure 1. The definition of M (ie, average of mean values per patient), Σ (ie, standard deviation of mean values per patient), and σ (ie, root mean square of standard deviation values per patient) is according to the nomenclature in van Herk.¹² The formula of $2.5\Sigma + 0.7\sigma$ (van Herk et al.¹³) was adopted to calculate the population-based PTV margin.

Results

Sixty-five consecutive prostate bed irradiation patients between the year of 2008 and 2014 were systematically examined, and 11 patients were found to be

suitable for this study based on our criteria of usable surgical clips. Among the 11 eligible patients, a total of 263 CBCT image sets were available, ranging from 17 to 26 CBCT sets per patient. The number of clips ranged from 3 to 11. Among the studied clips, 28 clips were located in the superior portion of the prostate bed, and 56 clips in the inferior portion. Among the 11 patients, 3 patients did not have any clips in the superior portion of the prostate bed (ie, all usable clips in inferior portion), and 1 patient had no clips in the inferior portion (ie, all usable clips in the superior portion). Figure 2 shows a typical segmentation of clips on one slice of CT and the corresponding clips identified on one of the CBCT images.

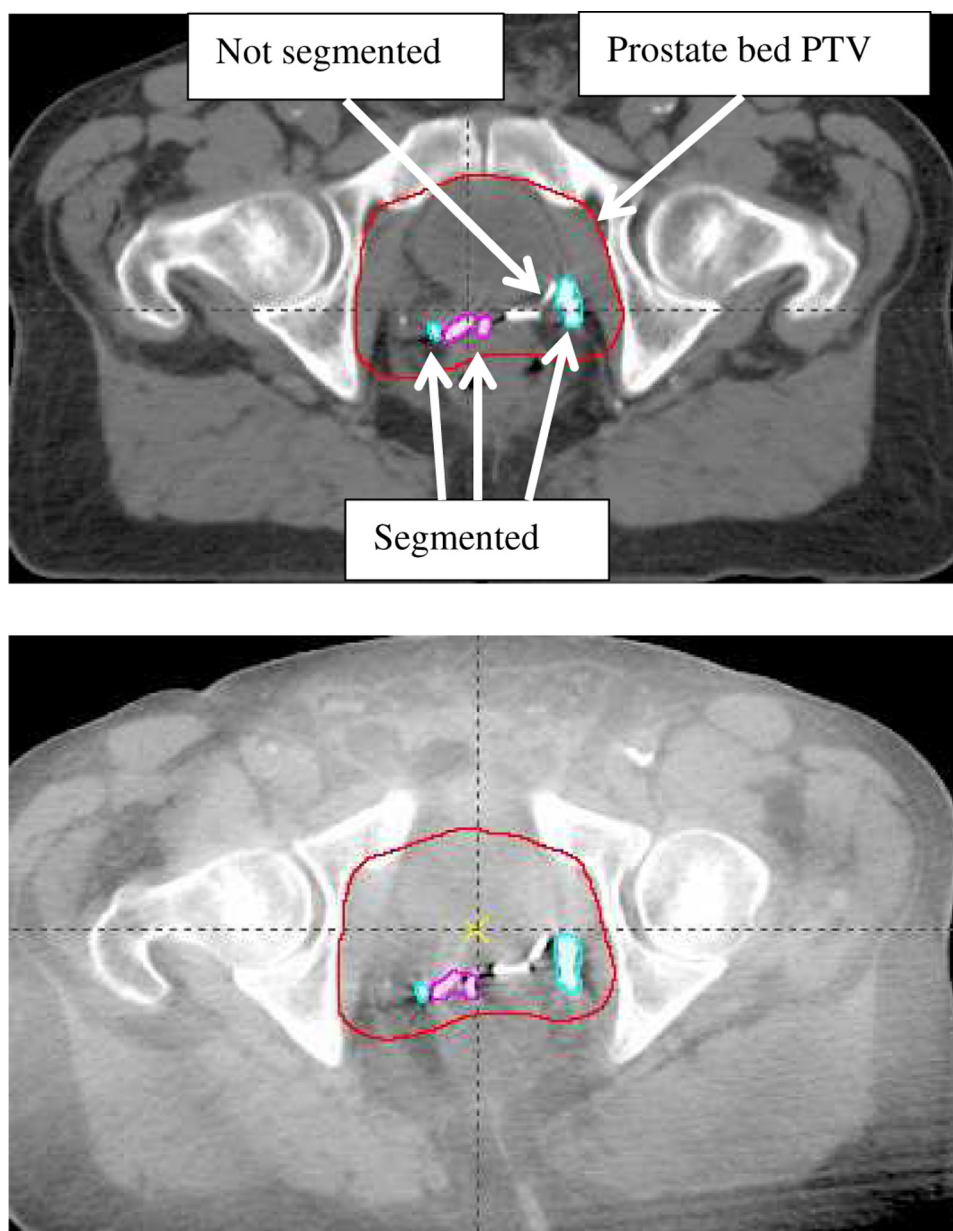


Figure 2 Axial view of one computed tomography slice through the prostate bed, showing the contoured segments of surgical clips on the treatment planning computed tomography scan and 1 cone beam computed tomography scan.

Table 1 Mean and standard deviation of motion of superior and inferior portions of prostate bed in 3 directions of LR, AP, and SI (cm)

Superior prostate bed	Patient No.	Pt 1	Pt 2	Pt 4	Pt 5	Pt 6	Pt 8	Pt 9	Pt 11	Over all patients		
No. of clips/total no. of clips		5/9	5/10	2/10	1/11	6/10	7/7	1/3	1/3			
No. of CBCT sets		25	26	26	21	25	26	17	24			
LR										M 0.02		
	Mean	-0.02	0.01	0.00	-0.02	0.04	0.06	0.00	0.07	Σ 0.03		
	SD	0.13	0.10	0.09	0.05	0.09	0.17	0.04	0.17	σ 0.16		
AP										M 0.01		
	Mean	-0.11	-0.06	0.06	0.04	-0.01	-0.41	0.07	0.50	Σ 0.25		
	SD	0.13	0.25	0.12	0.03	0.15	0.38	0.09	0.51	σ 0.37		
SI										M -0.06		
	Mean	0.11	0.15	-0.02	-0.04	0.15	-0.48	0.01	-0.31	Σ 0.23		
	SD	0.14	0.14	0.13	0.05	0.17	0.28	0.17	0.31	σ 0.27		
Inferior prostate bed	Patient no.	Pt 1	Pt 2	Pt 3	Pt 4	Pt 5	Pt 6	Pt 7	Pt 9	Pt 10	Pt 11	Over all patients
No. of clips/total no. of clips		4/9	5/10	11/11	8/10	10/11	4/10	3/3	2/3	7/7	2/3	
No. of CBCT sets		25	26	26	26	21	25	23	17	24	24	
LR												M 0.00
	Mean	0.02	0.00	-0.02	-0.06	0.06	-0.02	-0.01	0.02	-0.01	0.00	Σ 0.03
	SD	0.10	0.07	0.12	0.08	0.14	0.07	0.07	0.08	0.07	0.09	σ 0.03
AP												M 0.08
	Mean	-0.02	-0.03	-0.03	0.23	-0.04	-0.02	0.02	0.12	0.22	0.32	Σ 0.13
	SD	0.10	0.17	0.16	0.33	0.30	0.07	0.16	0.10	0.28	0.35	σ 0.15
SI												M -0.01
	Mean	-0.04	0.23	-0.18	-0.11	0.35	0.03	0.09	0.06	-0.30	-0.28	Σ 0.21
	SD	0.12	0.12	0.23	0.19	0.43	0.09	0.16	0.08	0.24	0.22	σ 0.20

Abbreviations: AP = anterior–posterior; CBCT = cone beam computed tomography; LR = left–right; pt = patient; SD = standard deviation; SI = superior–inferior.

The overall mean M (average of mean values per patient), systematic error Σ (SD of mean values per patient), and random error σ (root mean square of SD values per patient) are listed. The number of usable surgical clips in the superior and inferior portions of the prostate bed is listed for each patient. For several patients, all the clips are located in one half of the prostate bed planning target volume.

The mean and standard deviation values of the clips per patient are listed in Table 1. The overall mean values (M) are both near 0 for the superior and inferior portions, which indicates the lack of systematic shift of the prostate bed position between the CT simulation and treatment. This also implies that the setup preparation for the simulation and treatment are consistent for all patients. The systematic error (Σ) is small in the LR direction but significantly larger in the AP and SI directions for both the superior and inferior portions, which indicates more variations of the prostate bed motions in the AP and SI directions among patients.

To determine whether the superior and inferior portions move in the same manner, we ran 2-tailed statistical F tests on the mean values of the clip motion per patient. The P values are .72 and .49 (statistically insignificant) in the LR and SI directions, respectively, and .02 (statistically significant) in the AP direction, which indicates that the motion is statistically different between the superior and inferior portions of the prostate bed.

The PTV margins calculated from the observed motion values are listed in Table 2. Given our finding that the

motion difference is statistically insignificant in the LR and SI direction, but significant in the AP direction, we recommend a margin recipe as follows: same margin for the superior and inferior prostate bed, 0.2 cm in the LR and 0.7 cm in the SI direction. In the AP direction, the superior portion needs more margin than the inferior portion: 0.9 cm for superior and 0.4 cm for inferior.

Discussion

In this analysis, we found a statistically different motion between the superior and inferior prostate bed, which is consistent with the findings of Bell et al.,⁴ yet different from that of Verma et al.⁵ The motion data presented by Bell et al.⁴ allow for a direct comparison with this study (Table 3). The high consistency may be due to the fact that Bell et al.⁴ looked at the surgical clips as a surrogate of the prostate bed (same method as this study). In Verma et al.,⁵ accurate motion quantification depends on the consistent contouring of the prostate bed PTV on the treatment planning CT and all daily setup image sets

Table 2 Recommendation of nonuniform PTV margins for prostate bed in 3 directions based on derived error values of superior and inferior portions

PTV margin (cm)	Superior	Inferior	Margin recommendation with simplified rounding off
	$2.5\Sigma + 0.7\sigma$	$2.5\Sigma + 0.7\sigma$	
LR	0.19	0.10	0.2
AP	0.89	0.44	0.9/0.4 (sup/inf)
SI	0.76	0.67	0.7

Abbreviations: AP = anterior–posterior; LR = left–right; PTV = planning target volume; SI = superior–inferior.

obtained with a CT-on-rails. Contouring the whole prostate bed PTV may be the ideal way to characterize the motion of the prostate bed, but, in practice, may carry extra uncertainties in delineating the soft-tissue target on CT and across CT and daily CT image sets. The surgical clips used in this study and the study by Bell et al.⁴ are high-contrast objects and easy to contour. The downside is that these clips tend to concentrate on the posterior portion instead of distributing evenly within the prostate bed. Therefore, the surgical clips may not truly represent the motion of the whole prostate bed. Aside from the difference in data extraction, there is always the possibility to attribute the discrepancy to the different patient pools used in Verma et al.,⁵ Bell et al.,⁴ and this study. However, the agreement between this study and Bell et al.⁴ tends to downplay the patient pool as a factor.

Furthermore, when we average the systematic and random errors over the superior and inferior portions of the prostate bed, we found consistent results compared with those who studied the prostate bed as one volume^{6–9} in each of the LR, AP, and SI directions (Table 4).

Conclusions

The difference in motion between the superior and inferior portions of the prostate bed is statistically significant in the AP direction and statistically insignificant in the LR and SI directions. This aids in the delineation of appropriate PTV margins for postprostatectomy patients with cancer undergoing radiation planning.

Table 3 Comparison of systematic error (Σ) and random error (σ) of prostate bed, separated into superior and inferior portions (cm)

	Superior (Σ/σ)		Inferior (Σ/σ)	
	Bell et al. ⁴	Current study	Bell et al. ⁴	Current study
LR	0.11/0.11	0.03/0.16	0.10/0.08	0.03/0.03
AP	0.50/0.47	0.25/0.37	0.18/0.17	0.13/0.15
SI	0.27/0.28	0.23/0.27	0.19/0.17	0.21/0.20

Abbreviations: AP = anterior–posterior; LR = left–right; SI = superior–inferior.

Table 4 Comparison between systematic error (Σ) and random error (σ) between published data and current study

	Errors (cm)	Ost et al. ⁶	Huang et al. ⁷	Sandhu et al. ⁸	Song et al. ⁹	Current study
LR	Σ	0.04	0.07	0.10	0.17	0.03
	σ	0.10	0.20	0.17	0.28	0.10
AP	Σ	0.25	0.11	0.27	0.26	0.19
	σ	0.23	0.31	0.21	0.39	0.26
SI	Σ	0.09	0.10	0.24	0.24	0.22
	σ	0.14	0.28	0.21	0.29	0.24

Abbreviations: AP = anterior–posterior; LR = left–right; SI = superior–inferior.

References

- Wiegel T, Bottke D, Steiner U, et al. Phase III postoperative adjuvant radiation therapy after radical prostatectomy compared with radical prostatectomy alone in pT3 prostate cancer with postoperative undetectable prostate-specific antigen: ARO 96 to 02/AUO AP 09/95. *J Clin Oncol*. 2009;27:2924-2930.
- Thompson IM, Tangen CM, Paradelo J, et al. Adjuvant radiation therapy for pathologic T3N0M0 prostate cancer significantly reduces risk of metastases and improves survival: Long-term follow-up of a randomized clinical trial. *J Urol*. 2009;181:956-962.
- Bolla M, van Poppel H, Collette L, et al. Postoperative radiation therapy after radical prostatectomy: A randomized controlled trial (EORTC trial 22911). *Lancet*. 2005;366:572-578.
- Bell L, Cox J, Eade T, Rinks M, Kneebone A. Prostate bed motion may cause geographic miss in postprostatectomy image guided intensity modulated radiation therapy. *J Med Imaging Radiat Oncol*. 2013;57:725-732.
- Verma V, Chen S, Zhou S, Enke CA, Wahl AO. Prostate bed target interfractional motion using RTOG consensus definitions and daily CT-on-rails? *Strahlenther Onkol*. 2017;193:38-45.
- Ost P, Meerleer G, Gersem W, Impens A, Neve W. Analysis of prostate bed motion using daily cone beam computed tomography during postprostatectomy radiation therapy. *Int J Radiat Oncol Biol Phys*. 2011;79:188-194.
- Huang K, Palma D, Scott D, et al. Inter- and intrafraction uncertainty in prostate bed image guided radiation therapy. *Int J Radiat Oncol Biol Phys*. 2012;84:402-407.
- Sandhu A, Sethi R, Rice R, et al. Prostate bed localization with image guided approach using on-board imaging: Reporting acute toxicity and implications for radiation therapy planning following prostatectomy. *Radiat Ther Oncol*. 2008;88:20-25.
- Song S, Yenice KM, Kopec M, Liauw SL. Image guided radiation therapy using surgical clips as fiducial markers after prostatectomy: A report of total setup error, required PTV expansion, and dosimetric implications. *Radiat Ther Oncol*. 2012;103:270-274.
- Wiltshire KL, Brock KK, Haider MA, et al. Anatomical boundaries of the clinical target volume (prostate bed) after radical prostatectomy. *Int J Radiat Oncol Biol Phys*. 2007;69:1090-1099.
- Michalski JM, Lawton C, El Naqa I, et al. Development of RTOG consensus guidelines for the definition of the clinical target volume for postoperative conformal radiation therapy for prostate cancer. *Int J Radiat Oncol Biol Phys*. 2010;76:361-368.
- van Herk M. Errors and margins in radiotherapy. *Semin Radiat Oncol*. 2004;14:52-64.
- van Herk M, Remeijer P, Rasch C, Lebesque JV. The probability of correct target dosage: Dose-population histograms for deriving treatment margins in radiation therapy. *Int J Radiat Oncol Biol Phys*. 2000;47:1121-1135.