



# Arthroscopic Iliac Bone Block Augmentation for Glenoid Reconstruction: Transglenoid Fixation Technique Using an All-Suture Anchor

Jeung Yeol Jeong, M.D., Yon-Sik Yoo, M.D., Ph.D., and Taesoung Kim, M.D.

**Abstract:** Arthroscopic Bankart repair of anterior instability has shown relatively good results, but its effectiveness is unclear in cases wherein there is a bone defect in the glenoid bone. The surgical management of recurrent anterior shoulder instability with severe glenoid bone loss has been challenging until now. Therefore the Latarjet procedure was introduced as an alternative that provided good results in cases of full instability with a bone defect. In cases of recurrent anterior shoulder instability, bone defects are often present within the glenoid. To restore glenohumeral stability, a bone augmentation procedure is required, and the Latarjet procedure to use bony transfer from the coracoid is the most popular technique. However, resorption of the bone graft with metal screw protrusion is a serious concern, whereas the relative contribution of the dynamic sling effect of the Latarjet procedure remains controversial. The Latarjet procedure also destroys the normal kinematics, resulting in side effects such as scapular dyskinesia. Here we introduce an arthroscopic anterior bone block procedure for reconstructing anterior glenoid bone defects using an autologous iliac crest graft. This technique enables precise bone block placement and fixation using one all-suture anchor instead of screw fixation.

Recurrent anterior shoulder instability with significant glenoid bone loss is frequently treated with the Latarjet procedure,<sup>1</sup> which uses bony transfer from the coracoid.<sup>2</sup> However, it is associated with a high rate of complications, including metal screw protrusion and graft osteolysis.<sup>3,4</sup> The Latarjet procedure also destroys the normal kinematics, resulting in side effects such as scapular dyskinesia.<sup>2</sup> The arthroscopic Latarjet procedure is gaining popularity but involves a steep learning curve.<sup>5</sup> Other options include the use of a tricortical iliac crest autologous graft. However, few arthroscopic techniques have been described for grafting of the iliac

crest bone.<sup>5,6</sup> These previously described methods have technical difficulties.

Here we introduce an arthroscopic augmentation technique for reconstructing the anterior glenoid using an iliac bone block. We used a specific posterior glenoid guide (Blue-marlin; Conmed, Largo, FL) for precise graft positioning and fixed the iliac bone block using an all-suture anchor (Y-knot; Conmed). This technical note eliminates the use of screws and their potential complications.

## Surgical Technique

Under general anesthesia with an interscalene block, the patient was placed in a lateral decubitus position. The operative arm was placed in 20° to 30° of abduction and 20° of forward flexion (Star Sleeve Traction System; Arthrex, Naples, FL) with 15 pounds of side-arm traction. Vertical traction is additionally applied around the proximal humerus perpendicular to the long axis of the humerus. An axillary roll is then placed.

## Iliac Crest Graft Harvesting

The tricortical iliac crest graft is harvested from the ipsilateral side using the technique described by Warner et al.<sup>6</sup> The size of the block is usually 2 cm long × 1 cm high × 1 cm wide, although the size can be adjusted to match the glenoid size (Fig 1). Three-dimensional printing of the articular surface can help preoperative

From the Department of Orthopedic Surgery (J.Y.J., T.K.), Hallym University Dongtan Sacred Heart Hospital, Medical College of Hallym University, Keunjaebong-gil, Hwaseong-si, Gyeonggi-do, Republic of Korea and Camp 9 Orthopedic Clinic (Y.-S. Y.), Dongtansunhwan-daero, Hwaseong-si, Gyeonggi-do, Republic of Korea.

The authors report that they have no conflicts of interest in the authorship and publication of this article. Full ICMJE author disclosure forms are available for this article online, as [supplementary material](#).

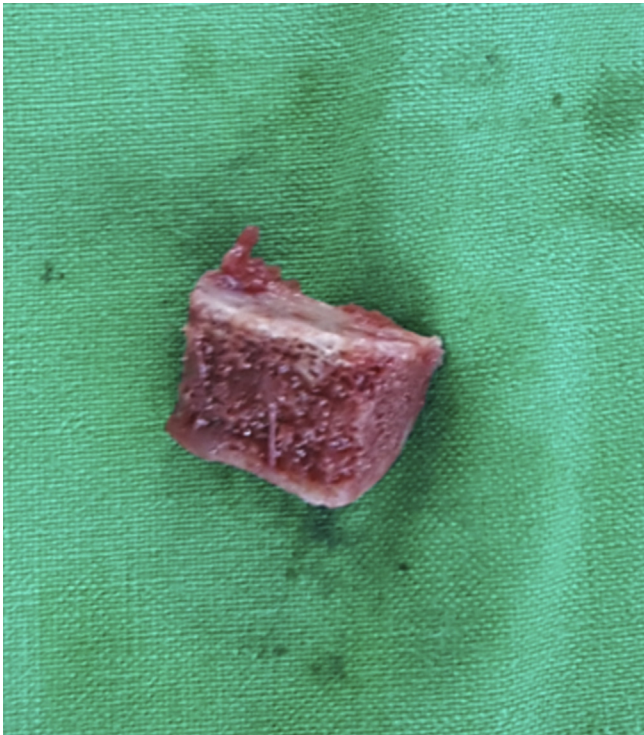
Received August 19, 2019; accepted November 16, 2019.

Address correspondence to Yon-Sik Yoo, M.D., Ph.D., Camp 9 Orthopedic Clinic, 127-5, Dongtansunhwan-daero, Hwaseong-si, Gyeonggi-do, Republic of Korea. E-mail: [ybw1999@gmail.com](mailto:ybw1999@gmail.com)

© 2019 by the Arthroscopy Association of North America. Published by Elsevier. This is an open access article under the CC BY-NC-ND license (<http://creativecommons.org/licenses/by-nc-nd/4.0/>).

2212-6287/191043

<https://doi.org/10.1016/j.eats.2019.11.009>



**Fig 1.** The harvested tricortical iliac crest bone block.

planning to ensure that an adequate amount of iliac bone is harvested for anteroinferior glenoid reconstruction.

### Preparation of Bone Block

The tricortical bone blocks taken from the iliac bone are drilled at the 2/3 point from the cancellous bone surface toward the cortical bone surface with a 1.8-mm drill. First, a four-layer Y-knot (Fig 2) is passed through a predrilled 1.8-mm hole. At this time, the anchor of the Y-knot is placed in the round cortex area. Once the bone block is harvested from the anterosuperior iliac crest, a 1.8-mm drill hole is made at the 3/4 point of the block's length. Afterward, the four limbs of an all-suture anchor (Y-knot; Conmed) shuttle are relayed through this hole. Part of the soft knot is anchored on the cortical surface of the iliac bone block (Fig 3). The bone block will be placed so that the cancellous surface can touch the cliff surface in the anterior bone defect area of glenoid.

### Preparation of Glenoid

An arthroscope is introduced through a standard posterior portal into the glenohumeral joint. A rotator interval portal (anterior portal) is established as the working portal. The trans-cuff portal described by Oh et al.<sup>7</sup> was used as the viewing portal. The anterior capsule and labral remnant that was attached to the periosteal sleeve at the anterior glenoid neck is

sufficiently detached at the 7 o'clock using the arthro-osteotome device. The exposed anterior glenoid neck is prepared as a flat surface using the arthro-osteotome, a round burr, and a shaver introduced through the anterior portal.

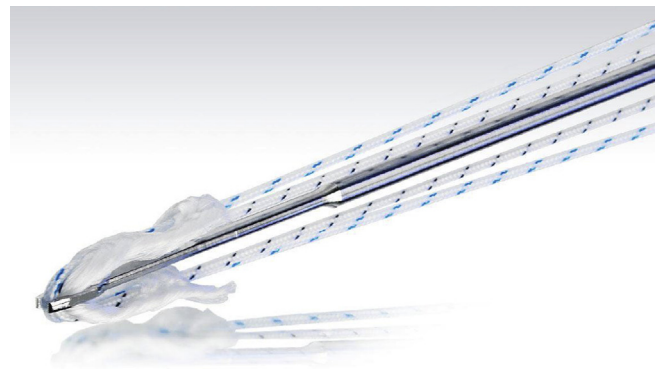
### Posterior Glenoid Guide and Drilling

The posterior glenoid guide (Blue Marlin; Conmed) is introduced through a standard posterior portal. The guide consists of two components (Fig 4). The pin is introduced parallel to the glenoid's surface. The second component positions a drill hole for drilling through the glenoid. A 1.8-mm drill is used for this purpose. The goal is to correctly place the bone block level within the glenoid. The guide provides a 2-mm offset between components considering the 2-mm average cartilage thickness. Its pin is positioned parallel on the glenoid surface at the 4 o'clock position (Fig 5). With the drill guide in close contact with the posterior glenoid neck surface, a 1.8-mm drill is introduced through the guide and advanced until the drill tip is visible through the anterior glenoid neck.

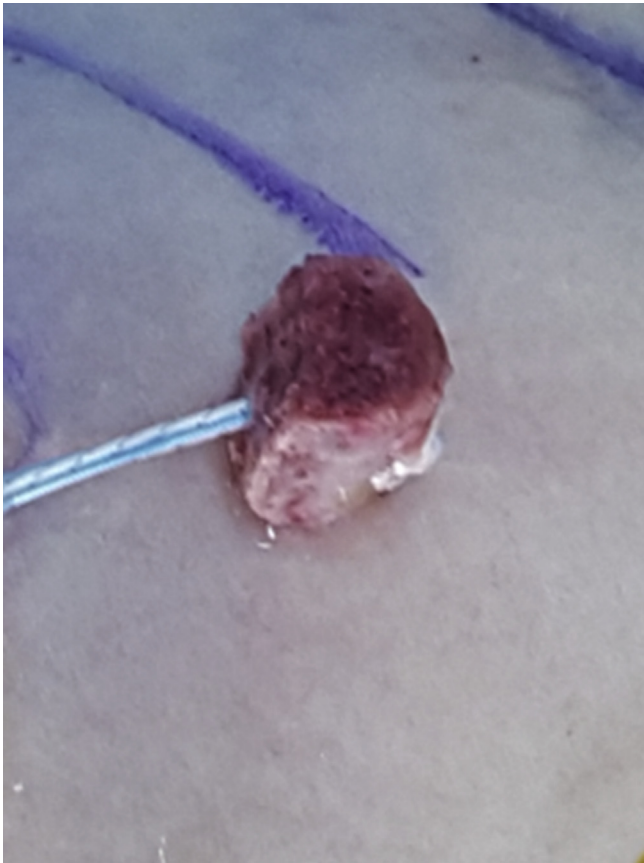### Passage of Bone Block

Afterward, a 1.1-mm nitinol suture passing wire (Arthrex) is inserted through the guide with the looped portion facing backward, and the wire is pulled out through the anterior portal using the retriever (Arthrex) (Fig 6). A FiberWire no. 2-0 suture limb (Arthrex) is passed through the loop part of the nitinol wire and then shuttle-relayed. Next, the four limbs of an all-suture anchor (Y-knot RC; Conmed) previously anchored to the bone block are shuttle-relayed from the anterior portal to the posterior portal using the FiberWire.

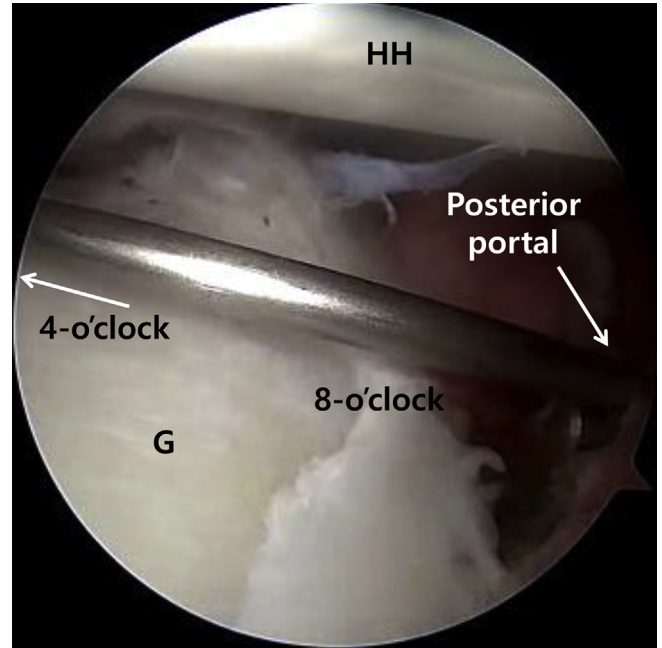
The iliac bone block is introduced into the joint with a clamp through an enlarged anterior portal. The four limbs of an all-suture anchor are pulled posteriorly until



**Fig 2.** A Y-knot Flex anchor (1.8 mm) double-loaded with two strands.



**Fig 3.** Anchoring of the soft knot on the round cortex area of the iliac bone block. A 1.8-mm drill hole (anchoring point) was made at the 3/4 point of the block's length.




**Fig 5.** The posterior glenoid guide positioning parallel on the glenoid surface (right shoulder, lateral decubitus position, 30° arthroscope through the trans-cuff portal). G, glenoid; HH, humeral head.

the bone block sits on the surface of the anterior glenoid neck (Fig 7).

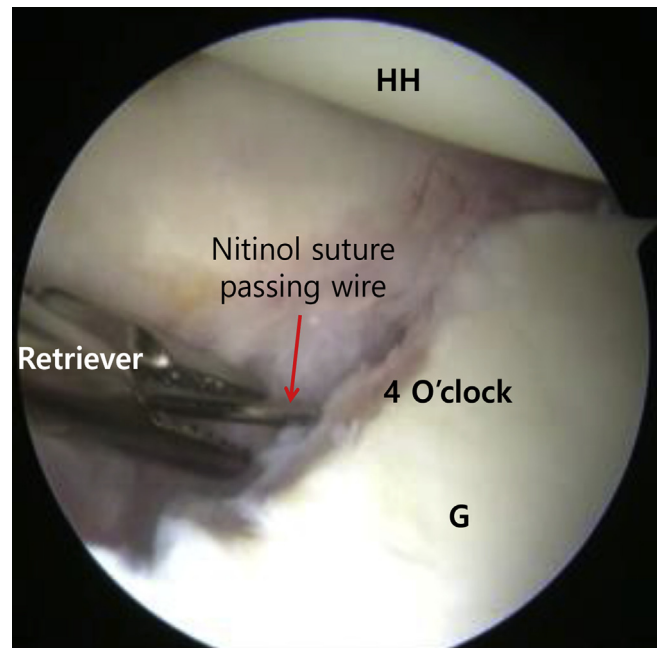
**Positioning and Tensioning of Bone Block**

Next, a 1.4-mm ICONIX anchor (Stryker Endoscopy, San Jose, CA) is inserted at the 3-, 4-, and 5-o'clock positions on the anterior glenoid for capsulolabral reattachment over the bone block. Before capsular labral reattachment, the suture of the screw inserted at the 3-o'clock position was used to wrap the upper portion of the bone block to provide additional stability of the bone block secured by the transglenoid knot.



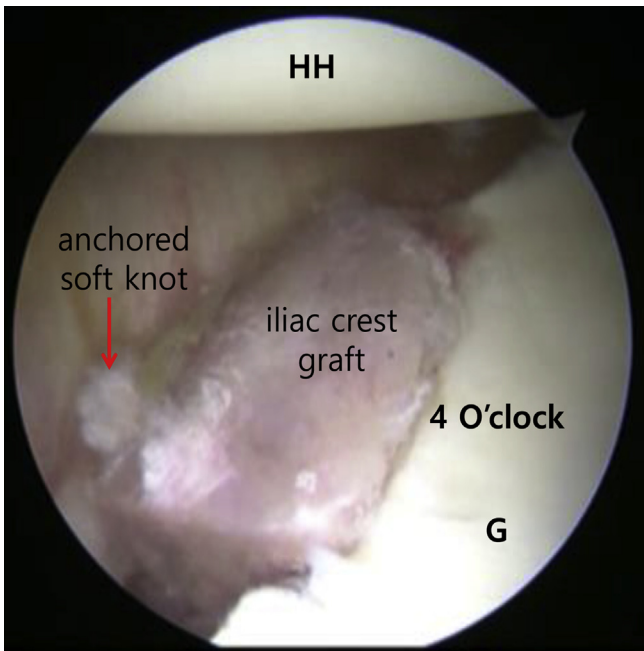
**Fig 4.** The posterior glenoid guide (Blue Marlin; Conmed, Largo, FL) consists of two components (pin and drill guide). The guide provides a 2-mm offset between components considering the 2-mm average cartilage thickness.

Next, firm compression of the graft on the anterior glenoid neck is achieved by a counterforce generated by sliding a giant knot with placing six subsequent half hitches on either side of the existing knots (Fig 8).



**Fig 6.** Passage of nitinol suture passing wire (right shoulder, lateral decubitus position, 30° arthroscope through the trans-cuff portal). G, glenoid; HH, humeral head.

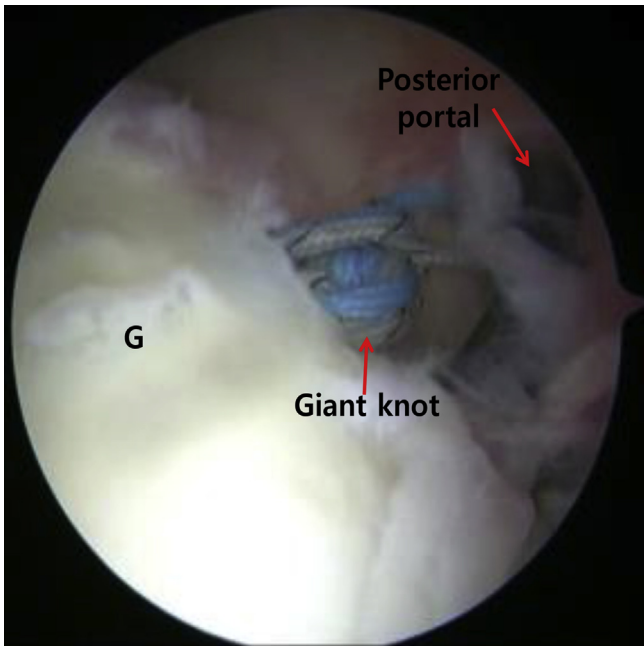




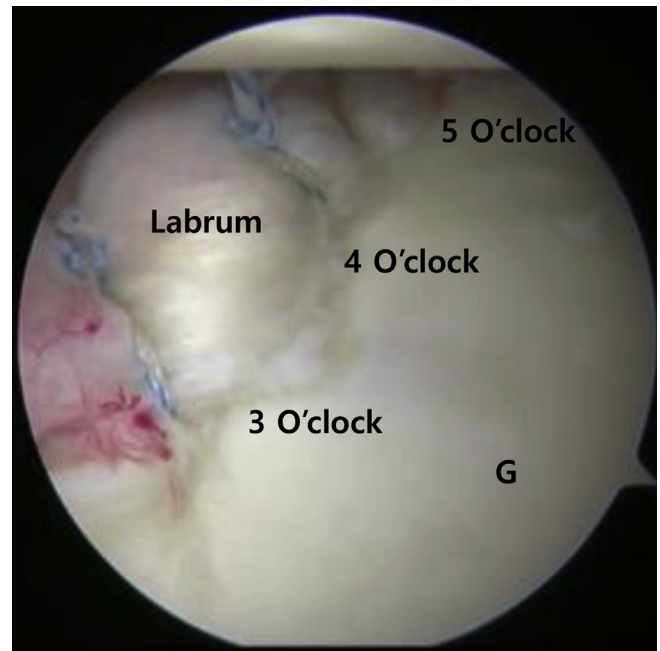
**Fig 7.** Positioning of the iliac crest graft (right shoulder, lateral decubitus position, 30° arthroscope through the trans-cuff portal). The graft is introduced at the anterior glenoid neck and centered at the 4 o'clock position. G, glenoid; HH, humeral head.

### Labral Repair

Subsequent capsulolabral reattachment to anterior glenoid acquires additional compression to compensate



**Fig 8.** Tensioning of the anchored soft knot (right shoulder, lateral decubitus position, 30° arthroscope through the trans-cuff portal). A giant knot is used to strongly tension the anchored soft knot. G, glenoid.



**Fig 9.** Bankart repair (right shoulder, lateral decubitus position, 30° arthroscope through the trans-cuff portal). The ICONIX anchors are inserted at the 3, 4, and 5 o'clock positions on the anterior glenoid to enable additional labrum repair over the bone block.

for the rotational instability of the bone block. Additional anchors can be inserted if necessary (Fig 9). Figure 10 shows a simplified schematic drawing of this process. The entire surgical technique is shown in Video 1, which includes audio narration. Tables 1 and 2 present the tips, pitfalls, and key points of using this technique.

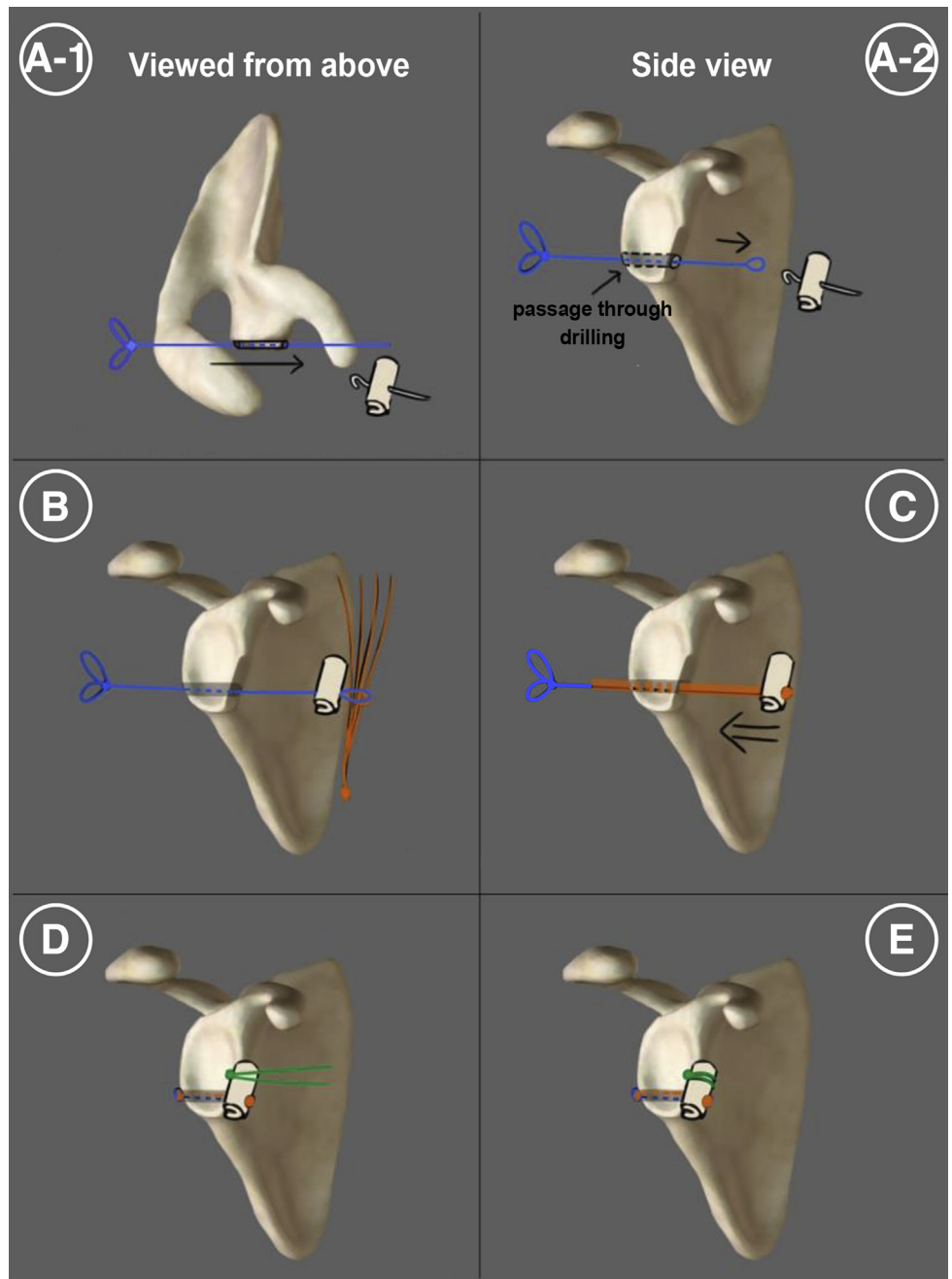
### Rehabilitation

After surgery the patients were immobilized with an abduction brace for 6 weeks. Passive range of motion exercises were started at 6 weeks after surgery. During this period, only isometric muscle strengthening was permitted. Gentle isokinetic muscle training was initiated 3 months after fully active range of motion was achieved. Contact sports were not permitted until 12 months after surgery.

### Discussion

Recurrent anterior shoulder instability is associated with significant glenoid bone loss in 90% of cases.<sup>5</sup> The Latarjet procedure has been proven reliable to manage recurrent anterior shoulder instability with these bone defects.<sup>1,8</sup> Despite this, there was concern because of the high incidence of surgical complications associated with this procedure. Carbone et al.<sup>2</sup> reported that scapular dyskinesia was found in 25% of patients who underwent a Latarjet procedure. It is associated with nonanatomic reconstruction. Metal screw-related

**Fig 10.** Schematic drawing of all procedure process. (A) Drilling the tunnel of the glenoid from the 8 o'clock to the 4 o'clock positions and then passage through FiberWire no. 2. (B) To anchor four limbs of the all-suture anchor (orange color) on the iliac bone block, create the loop end of the FiberWire thread. (C) The four limbs anchored to the bone block are shuttle-relayed from the anterior portal to the posterior portal using the FiberWire. (D) The suture of the screw inserted at the 3 o'clock position (green color) was used to wrap the upper portion of the bone block. Later, using a giant knot, the anchored soft knot creates strong tension. (E) The transglenoid knot (green color).



complications (screw migration, loosening, breakage, or irritation) occur in 6.5% of cases.<sup>3</sup> In addition, common complications include coracoid graft nonunion.<sup>8</sup>

Thus some arthroscopic techniques using iliac crest bone grafts have been described that challenge these complications and produce good clinical outcomes.<sup>5,9-11</sup> All-arthroscopic iliac crest graft augmentation techniques have been reported, including those of Scheibel et al.<sup>10</sup> using bio-compression screws, Taverna et al.<sup>11</sup> using EndoButton devices, and Kalogrianitis et al.<sup>5</sup> using tightrope devices. Most of these arthroscopic

bone block procedures are technically demanding complex procedures involving a long learning curve.

We introduced an arthroscopic iliac bone block augmentation technique using an all-suture anchor. We believe that the described technique has several advantages (Table 2). The proper placement of the glenoid guide is important because this technique also carries the risk of graft malposition. The risk of nerve injury is minimized by the use of a minimal incision in the anterior portal of the shoulder, as well as the omission of traction procedures. However, this

**Table 1.** Procedural pearls and pitfalls

## Pearls

- Adequate preparation of the anterior glenoid neck involves the preparation of a flat surface.
- The posterior glenoid guide must be introduced parallel to the glenoid surface to avoid bone graft misplacement.
- The sutured limb of the anchor inserted at the 3 o'clock for the transglenoid knot should wrap the upper part of the bone block before tensioning the anchored soft knot using a giant knot.

## Pitfalls

- The surgeon should consider discontinuing cannula use to introduce the iliac bone graft through the rotator interval portal and avoid the soft tissues.
- Care should be taken to ensure that the iliac bone drilling point is not at the center of the bone.

technique has some limitations. Bone block is fixed using multiple soft giant knots on the bone defect surface of the glenoid. Therefore, there is a risk that the fixation force may be relatively weak. Harvest site morbidity may be a concern, but compared with allografts, the autologous iliac crest tricortical graft is the gold standard.<sup>5</sup> In conclusion, this arthroscopic iliac bone block augmentation using an all-suture anchor combined with soft tissue repair enables anatomical repair of recurrent anterior shoulder instability with significant glenoid bone loss. It can also enable the straightforward reconstruction of glenoid bone defects and avoid the complications of metal fixation screws.

**Table 2.** Procedural advantages and disadvantages

## Advantages

- This procedure allows anatomical reconstruction of the glenoid bone.
- This procedure is easier and quicker than other arthroscopic procedures as well as the Latarjet procedure.
- The all-arthroscopic approach provides more cosmetic results and leads to sooner rehabilitation exercises.
- This procedure does not injure the subscapularis muscle.

## Disadvantages

- Relatively weak fixation force by multiple soft giant knots.
- Donor-site morbidity is possible.

**References**

1. An VV, Sivakumar BS, Phan K, Trantalis J. A systematic review and meta-analysis of clinical and patient-reported outcomes following two procedures for recurrent traumatic anterior instability of the shoulder: Latarjet procedure vs. Bankart repair. *J Shoulder Elbow Surg* 2016;25:853-863.
2. Carbone S, Moroder P, Runer A, Resch H, Gumina S, Hertel R. Scapular dyskinesia after Latarjet procedure. *J Shoulder Elbow Surg* 2016;25:422-427.
3. Butt U, Charalambous CP. Complications associated with open coracoid transfer procedures for shoulder instability. *J Shoulder Elbow Surg* 2012;21:1110-1119.
4. Balestro JC, Young A, Maccioni C, Walch G. Graft osteolysis and recurrent instability after the Latarjet procedure performed with bioabsorbable screw fixation. *J Shoulder Elbow Surg* 2015;24:711-718.
5. Kalogrianitis S, Tsouparopoulos V. Arthroscopic iliac crest bone block for reconstruction of the glenoid: A fixation technique using an adjustable-length loop cortical suspensory fixation device. *Arthrosc Tech* 2016;5:e1197-e1202.
6. Warner JJ, Gill TJ, O'Hollerhan JD, Pathare N, Millett PJ. Anatomical glenoid reconstruction for recurrent anterior glenohumeral instability with glenoid deficiency using an autogenous tricortical iliac crest bone graft. *Am J Sports Med* 2006;34:205-212.
7. Oh JH, Kim SH, Lee HK, Jo KH, Bae KJ. Trans-rotator cuff portal is safe for arthroscopic superior labral anterior and posterior lesion repair: Clinical and radiological analysis of 58 SLAP lesions. *Am J Sports Med* 2008;36:1913-1921.
8. Ranalletta M, Bertona A, Tanoira I, Maignon G, Bongiovanni S, Rossi LA. Modified Latarjet procedure without capsulolabral repair for failed previous operative stabilizations. *Arthrosc Tech* 2018;7:e711-e716.
9. Anderl W, Kriegleder B, Heuberger PR. All-arthroscopic implant-free iliac crest bone grafting: New technique and case report. *Arthroscopy* 2012;28:131-137.
10. Scheibel M, Kraus N, Diederichs G, Haas NP. Arthroscopic reconstruction of chronic antero-inferior glenoid defect using an autologous tricortical iliac crest bone grafting technique. *Arch Orthop Trauma Surg* 2008;128:1295-1300.
11. Taverna E, D'Ambrosi R, Perfetti C, Garavaglia G. Arthroscopic bone graft procedure for anterior inferior glenohumeral instability. *Arthrosc Tech* 2014;3:e653-e660.