



Contents lists available at ScienceDirect

International Journal of Surgery Case Reports

journal homepage: www.casereports.com

Successful primary repair of late diagnosed spontaneous esophageal rupture: A case report



Diana Y. Kircheva¹, Wickii T. Vigneswaran*

Section of Cardiac and Thoracic Surgery, Department of Surgery, University of Chicago Medicine, 5841 South Maryland Avenue, Chicago, IL 60637-1470, United States

ARTICLE INFO

Article history:

Received 29 December 2016
Received in revised form 26 March 2017
Accepted 28 March 2017
Available online 1 April 2017

Keywords:

Case report
Esophageal perforation
Primary repair
Boerhaave's syndrome
over the scope clip
OTSC

ABSTRACT

INTRODUCTION: Spontaneous esophageal rupture is rare, roughly 300 cases reported annually. Diagnosis is often delayed or missed. Overall mortality is about 20%. This feared high mortality rate has led to the misconception that primary esophageal repair should be avoided in late diagnosed patients. We report a successful primary repair of spontaneous esophageal rupture which was delayed for more than two weeks.

METHODS: A 53 year-old male presented to our medical service after falsely having been treated for pneumonia at an outside hospital. He was subsequently diagnosed with spontaneous esophageal rupture and treated with over the scope clips followed by stenting. Persistent leak into mediastinum made surgical exploration necessary. At exploration a primary repair could be performed successfully.

RESULTS: Unsuccessful endoscopic management of esophageal perforation that was delayed for two weeks underwent primary surgical repair without complications.

CONCLUSION: Primary closure of late diagnosed spontaneous esophageal rupture can be successful, even when it is complicated by a prolonged delay in treatment and failed endoscopic procedures. We conclude that primary surgical repair should be attempted in patients with spontaneous esophageal rupture if tissues are viable.

© 2017 The Author(s). Published by Elsevier Ltd on behalf of IJS Publishing Group Ltd. This is an open access article under the CC BY-NC-ND license (<http://creativecommons.org/licenses/by-nc-nd/4.0/>).

1. Introduction

Spontaneous esophageal rupture (Boerhaave's syndrome) is a longitudinal full-thickness tear of the esophagus, which leads to leakage of air, saliva and gastric contents into the mediastinum. This results in mediastinitis, pneumomediastinum, empyema, respiratory failure, sepsis and shock. Patients may present with subcutaneous emphysema and severe lower thoracic pain aggravated by swallowing. On the other hand they may only have non-specific findings such as hypotension, abdominal rigidity, tachycardia, tachypnea, shortness of breath, leukocytosis and fever. This wide range of manifestations can lead to a delayed diagnosis or misdiagnosis, resulting in increased morbidity and mortality [1]. Historically mortality is high with overall mortality raging between 18 and 22%. This feared high mortality rate has led to the misconception that primary esophageal repair should be avoided in late diagnosed patients.

Advanced endoscopic techniques utilizing novel materials and devices, such as over the scope clips, have become popular in treating esophageal pathology. However their use needs to be critically evaluated. Regardless of the length of delay from the time of perforation primary repair of esophageal perforation should be considered. We report a case of successful primary repair of late diagnosed spontaneous esophageal rupture. The patient presented below was managed at an academic center.

2. Materials and methods

A 53 year-old male presented to an outside hospital with vomiting, shortness of breath and left-sided chest pain and was started on treatment for pneumonia. The course was complicated by sepsis and respiratory failure, requiring ventilation and vasopressors. Computer tomography scan (CT scan) one week later showed fluid and air collection in the mediastinum and bilateral pleural effusions.

Diagnosis of esophageal perforation was suspected and the patient was transferred to our Medical Center, where endoscopic closure of the esophageal tear with two over the scope clips (OTSC) was attempted (Fig. 1a). Contrast study done the following day showed persistent esophageal leak (Fig. 1b). A covered stent was placed to seal the leak. Despite an additional OTSC to hold the

* Corresponding author. Present address: Loyola University Medical Center, 2160 S. First Ave, Maywood, IL 60153, United States.

E-mail address: Wickii.Vigneswaran@lumc.edu (W.T. Vigneswaran).

¹ Centegra Health System, 4309 Medical Center Drive, McHenry, IL 60050, United States.

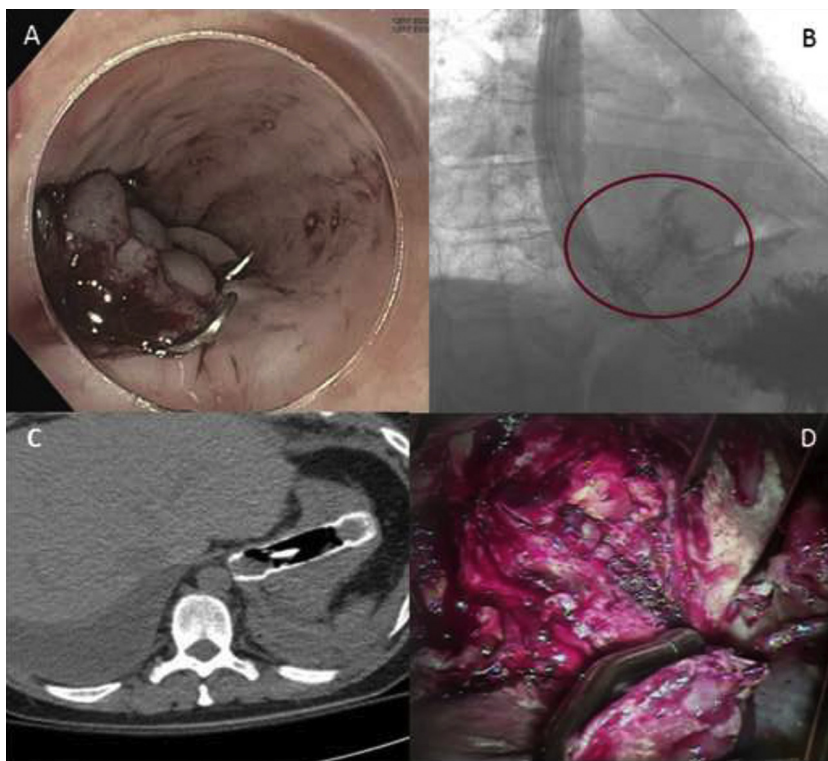


Fig. 1. Pre-operative endoscopic and radiological findings. 1A: Endoscopic image demonstrating esophageal tear with two over the scope clips (OTSC). 1B: Esophagram showing persistent esophageal leak. Fig. 1C: CT scan showing esophageal stent migration into the stomach 1D: Primary repair of mucosal and muscular esophageal layers.

stent in position, the stent migrated into the stomach (Fig. 1c). The patient continued to require ventilatory support and remained on vasopressors.

At this point, two weeks after the onset of symptoms, the patient was transferred to thoracic surgery. He underwent esophagogastroduodenoscopy showing the distal esophageal tear with OTSCs partially obstructing the esophagus. The esophageal stent, which had migrated into the stomach, was appreciated. Left thoracotomy was performed, revealing multiple loculated abscess cavities in the mediastinal and pleural spaces, trapped left lower lobe and lingular segment. After debridement of the mediastinum, the esophageal perforation was identified and OTSCs were removed (Fig. 2a). Necrotic tissue on mucosal and muscle edges was debrided; followed by primary closure with interrupted 4.0 polyglyconate, absorbable sutures (Maxon, Covidien, USA) closing both mucosal and muscular layers (Fig. 2b). Pulmonary decortication was completed. A gastrotomy was created through a mini laparotomy to extract stent and was subsequently converted to a tube gastrotomy. A feeding jejunostomy and a tracheostomy were performed before completion of the operation.

3. Results

Patient was rapidly weaned off the ventilator to spontaneous breathing. An esophagram 12 days post-op confirmed healed esophageal leak. He was started on clear oral liquids, advanced to soft diet and discharged home. An outpatient esophagram done two months post-operatively demonstrated normal appearing distal esophagus without stricture.

4. Discussion

Operative and non-operative management of esophageal rupture remains controversial. To date there is no clear treatment

algorithm. Early recognition and treatment correlates with better survival. It is not uncommon however for patients with spontaneous esophageal rupture to present late with non-specific symptoms, resembling a wide variety of diseases, delaying diagnosis.

Many therapeutic approaches are reported to treat spontaneous rupture of the esophagus, including usage of self-expandable covered metal stents and endo-clips [2]. Although stents and endo-clips are becoming increasingly popular, this therapeutic option has limitations and the use should be considered carefully. Successful esophageal repair outcome with stent and/or endo-clips is often observed in iatrogenic perforations or leaks after bariatric surgery [2,3]. The good results in those studies can be attributed to low level of contamination due to fasting prior to offending intervention and rapid diagnosis of perforation after the procedure. In these select cases endoscopic techniques of repair appear promising. However, in spontaneous esophageal rupture the mediastinum and pleural space is contaminated and therefore requires drainage/decortication in addition to repair. Endoscopic therapy is less successful in these circumstances than primary surgical therapy [4].

In our case, the long delay in diagnosis made endoscopic repair unsuitable. Nevertheless, an endoscopic attempt was made, which resulted in further delay of surgical treatment. In our patient it was possible to perform a successful primary repair, despite the long delay and sepsis. In some instances, primary repair may not be possible due to extensive necrosis and an esophagectomy may be required for salvage [5]. Traditionally, in esophageal perforation that was diagnosed late, diversion fistula is considered as the procedure of choice with the belief that reconstruction will be unsuccessful in a contaminated environment. As observed in our case, as well as in the literature, primary repair is possible with low morbidity and mortality even in presence of delayed diagnosis and

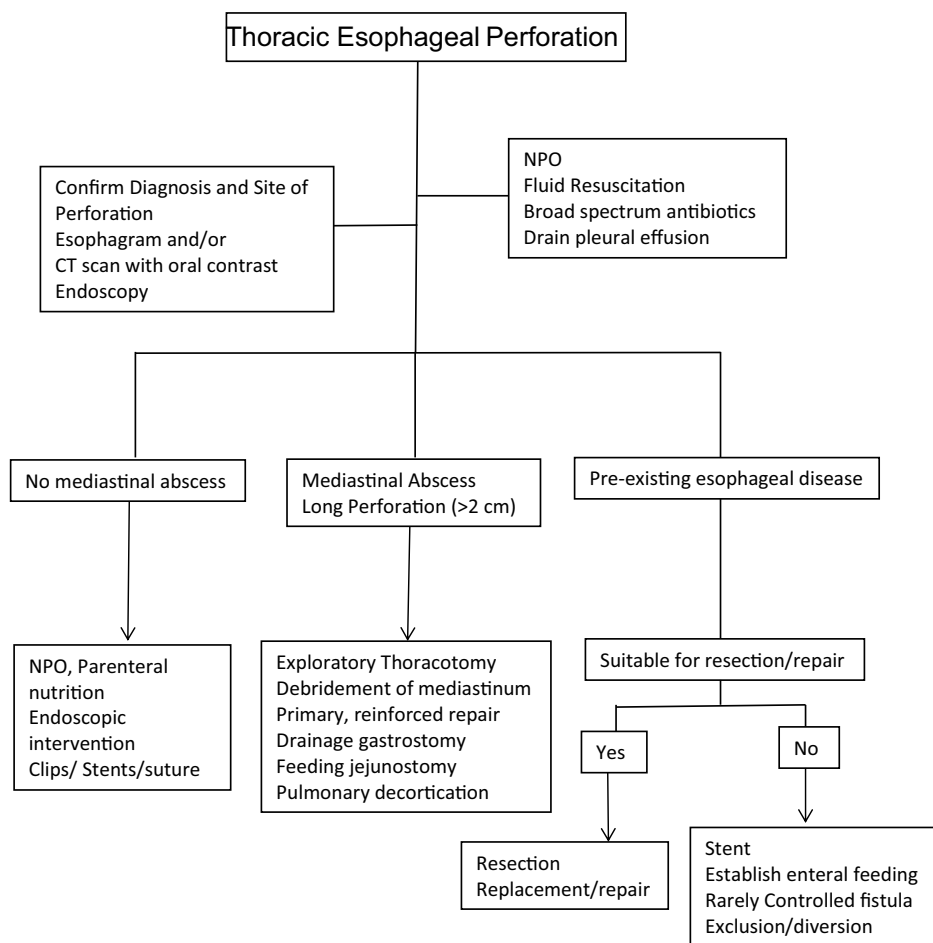


Fig. 2. Simplified decision tree for management of thoracic esophageal perforation.

mediastinal abscess [4,5]. The manuscript was prepared according to the SCARE guidelines [6].

In conclusion, early diagnosis and repair decreases the mortality morbidity of patients with spontaneous esophageal rupture. There is still no established algorithm to guide endoscopic vs. surgical repair of esophageal perforation. Endoscopic closure should be attempted only in cases where there is absence of significant mediastinal contamination such as in early diagnosed iatrogenic rupture. Primary closure of late diagnosed Boerhaave's syndrome can be successful and it should always be attempted initially regardless of the time lapsed from rupture.

Current practice shy away from primary repair of late diagnosed esophageal rupture, leading to increased morbidity and mortality in this patient population.

The learning point in this case report is that primary repair can be successful in patient presenting late even after two weeks of an esophageal rupture. It is critical to debride necrotic tissue, drain mediastinal space and close the esophageal defect to control continuous contamination to achieve success.

Conflict of interest

None declared.

The work has been reported in line with the SCARE guidelines.²

² Agha RA, Fowler AJ, Saetta A, Barai I, Rajmohan S, Orgill DP and the SCARE Group. The SCARE Statement: Consensus-based surgical case report guidelines. International Journal of Surgery 2016;34:180–186.

Funding resources

None declared.

Consent

Consent was obtained for recording operative procedure, presenting and publishing non identifiable information for educational purposes, both verbal and written.

Author contributions

Dr. Diana Kircheva performed literature review and manuscript preparation of this case report. Dr. Wickii Vigneswaran performed procedure, follow-up of patient, assisted in the preparation and Proof reading of the report.

Guarantor

Wickii T. Vigneswaran, MD, FACS.

References

- [1] C.J. Brinster, S. Singhal, L. Lee, M.B. Marshall, L.R. Keiser, J.C. Kucharczuk, Evolving options in the management of esophageal perforation, *Ann. Thorac. Surg.* 77 (2004) 1475–1483.
- [2] R.K. Freeman, A.J. Ascoti, T. Giannini, R.J. Mahidhara, Analysis of unsuccessful esophageal stent placements for esophageal perforation, fistula, or anastomotic leak, *Ann. Thorac. Surg.* 94 (2012) 959–964.

- [3] R.P. Voermans, O. Le Moine, D. von Renteln, T. Ponchon, M. Giovannini, M. Bruno, et al., Efficacy of endoscopic closure of acute perforations of the gastrointestinal tract, *Clin. Gastroenterol. Hepatol.* 10 (2012) 603–608.
- [4] M. Schweigert, R. Beattie, N. Solymosi, K. Booth, A. Dubecz, A. Muir, et al., Endoscopic stent insertion versus primary operative management for spontaneous rupture of the esophagus (Boerhaave syndrome): an international study comparing the outcome, *Am. Surg.* 79 (2013) 634–640.
- [5] Y.D. Seo, J. Lin, A.C. Chang, M.B. Orringer, W.R. Lynch, R.M. Reddy, Emergent esophagectomy for esophageal perforations: a safe option, *Ann. Thorac. Surg.* 100 (2015) 905–909.
- [6] R.A. Agha, A.J. Fowler, A. Saetta, I. Barai, S. Rajmohan, D.P. Orgill, the SCARE Group, The SCARE statement: consensus-based surgical case report guidelines, *Int. J. Surg.* 34 (2016) 180–186.

Open Access

This article is published Open Access at sciedirect.com. It is distributed under the [IJSCR Supplemental terms and conditions](#), which permits unrestricted non commercial use, distribution, and reproduction in any medium, provided the original authors and source are credited.