

Original Article

## The efficacy of retreatment and new reciprocating systems in removing a gutta-percha-based filling material

Ahmad A. Madarati, PhD<sup>a,\*</sup>, Ahmad A. Al-Nazzawi, PhD<sup>b</sup>, Aya M.N. Sammani, MDs<sup>b</sup> and Mahmod A. Alkayyal, DDS<sup>c</sup>

<sup>a</sup> Restorative Dental Sciences Department, College of Dentistry, Taibah University, Almadinah Almunawwarah, KSA

<sup>b</sup> Substitutive Dental Sciences Department, College of Dentistry, Taibah University, Almadinah Almunawwarah, KSA

<sup>c</sup> College of Dentistry, Taibah University, Almadinah Almunawwarah, KSA

Received 22 January 2018; revised 27 March 2018; accepted 29 March 2018; Available online 27 June 2018



### المخلص

**أهداف البحث:** يهدف البحث للتحقق من فعالية أنظمة إعادة معالجة الآلية والأنظمة الآلية ذات الحركة التبادلية في إزالة حشوات الأقفنية الجزرية ذات الأساس المكون من الكوتابيركا.

**طرق البحث:** تم تحضير الأقفنية لـ ٩٠ سن سليمة باستخدام نظام البروتيبير الآلي حتى قياس إف ٣. وحشيت الأقفنية المضرة بالكوتابيركا ومغلق من نوع نيوبلسيل باستخدام تقنية التكتيف الجانبي. وقسمت الأسنان إلى ٥ مجموعات حسب أنظمة إعادة المعالجة الآلية المستخدمة كالتالي: مجموعة الريسبروك التي استخدمت فيها مبادر الريسبروك قياس ٢٥، ومجموعة الويف ون التي استخدمت فيها مبادر الويف ون الأساسية، ومجموعة أس ون التي استخدمت فيها مبادر أس ون ذات القياس ٢٥ والاستقاق بمقدار ٠.٠٦. ومجموعة نظام إعادة المعالجة من نوع البروتيبير، ومجموعة نظام إعادة المعالجة من نوع ام تو. كما تم تسجيل الوقت اللازم لإزالة المادة الحاشية (دقيقة) وحوادث انكسار المبادر كاختلاط مرافق لإعادة المعالجة إن وجد. وبعد إعادة المعالجة، تم شطر كل سن طولياً إلى نصفين وصور كل نصف بكاميرا ذات دقة عالية. وأدخلت الصور إلى برنامج أوتو كاد من أجل قياس كمية المادة الحاشية المتبقية ضمن القناة بعد إعادة المعالجة. ثم خضعت البيانات لتحليل احصائي باستخدام اختبارات ون وي انوفا وكاي سكوير.

**النتائج:** أظهرت مجموعة ام تو لإعادة المعالجة أعلى متوسط من المادة الحاشية المتبقية بعد إعادة المعالجة (٥١٪) ولم يكن هناك فرق احصائي بين المجموعات الأخرى. واحتاجت مجموعة البروتيبير أقل وقت لإزالة المادة الحاشية (٥.٨٣ دقيقة). بشكل عام، حدث انكسار المبادر ١٣ مرة خلال إعادة المعالجة، حيث كانت نسبة الانكسار ضمن مجموعة ام تو هي الأعلى احصائياً (٣٣.٣٪).

**الاستنتاجات:** ضمن محددات هذه الدراسة في المختبر، كانت الأنظمة الدوارة ذات الحركة التبادلية فعالة مثل أنظمة إعادة المعالجة الآلية في إزالة حشوة الأقفنية الجزرية. وأظهر نظام ام تو لإعادة المعالجة أسوأ النتائج من حيث قلة الفعالية في إزالة حشوة الأقفنية ومن حيث ارتفاع نسبة انكسار المبادر خلال إعادة المعالجة.

**الكلمات المفتاحية:** إعادة علاج جذور الأسنان؛ كوتابيركا؛ أنظمة التحضير القوي

### Abstract

**Objectives:** To investigate the efficacy of retreatment and reciprocating rotary systems in removing gutta-percha filling material from root-canal systems.

**Methods:** A total of 90 single-canal human teeth were instrumented using a F3 ProTaper file and obturated with gutta-percha and the Tubliseal sealer using the lateral-compaction technique. They were divided into five groups according to the rotary system used to remove the filling material: Reciproc, which used the Reciproc-R25 file; WaveOne, which used the WaveOne-Primary file; S1, which used the S1 (25/.06) file; ProTaper-R, which used the ProTaper-Retreatment system; and Mtwo-R, which used the Mtwo®-Retreatment system. The time required to remove the filling material (min) and the associated instrument separation, if any, were recorded. Teeth were cleaved longitudinally and photographed with a high-resolution camera. Images were imported to the AutoCAD application to measure the remaining filling material and the root-canal space. Data were analysed using the one-way analysis of variance and Chi-squared tests.

\* Corresponding address: College of Dentistry, Taibah University, Almadinah Almunawwarah 43353, KSA.

E-mail: [ahmad.madarati@hotmail.co.uk](mailto:ahmad.madarati@hotmail.co.uk) (A.A. Madarati)

Peer review under responsibility of Taibah University.



Production and hosting by Elsevier

**Results:** The Mtwo-R group showed the highest mean remaining filling material (51%) ( $p < 0.001$ ), with no significant differences among the other groups. The ProTaper group required the least time for filling-material removal (4.95 min), with significant differences compared to the other groups ( $p < 0.05$ ), except the WaveOne group (5.83 min;  $p = 1.000$ ). Overall, 13 instruments (15.9%) were used for filling-material removal, with a significantly greater proportion in the Mtwo-R group (33.3%) compared to the other groups ( $p = 0.009$ ).

**Conclusions:** Within the limitations of this in vitro study, reciprocating rotary systems were as effective as retreatment rotary systems in removing root-canal filling material. The Mtwo-R system showed the poorest performance with respect to removal effectiveness and instrument separation.

**Keywords:** Mtwo-R; Reciproc; Removal; Retreatment; S1; WaveOne

© 2018 The Authors.

Production and hosting by Elsevier Ltd on behalf of Taibah University. This is an open access article under the CC BY-NC-ND license (<http://creativecommons.org/licenses/by-nc-nd/4.0/>).

## Introduction

There has been an increased emphasis on preservation of teeth, including those with failed root-canal treatments (RCTs). Nonsurgical RCT is usually preferred for such cases, especially that the survival rate of teeth receiving nonsurgical root-canal retreatment is similar to that associated with primary treatments.<sup>1</sup> The main objective of nonsurgical RCT is to completely remove the root-canal filling materials (RCFMs) to allow effective disinfection and shaping of the root-canal system. This is essential for successful RCT.<sup>2</sup>

Several tools have been employed for removal of RCFMs from the root-canal system, including chemical solvents,<sup>3</sup> hand instruments,<sup>4</sup> NiTi rotary instruments,<sup>5</sup> Gates–Glidden drills,<sup>6</sup> heat-transferring instruments and ultrasonics,<sup>4</sup> and laser irradiation.<sup>7</sup> Traditionally, RCFMs were removed using hand-files with/without solvents.<sup>4</sup> However, this procedure can be tedious and time-consuming, especially if the RCFM is well-compacted.<sup>8</sup> Moreover, solvents may damage the periapical tissues when extruded and their toxicity cannot be overlooked,<sup>3</sup> jeopardising the prognosis of the RCT. Retreatment rotary instruments, which rotate in continuous motion and are especially designed for retreatment, are practical options in such scenarios<sup>9,10</sup> and may decrease patient and operator fatigue. However, their superior efficacy over hand instruments has been a matter of debate, with some studies showing that retreatment rotary instruments are not better than hand instruments.<sup>11</sup> Furthermore, to this date, there is no rotary or hand file that can completely remove the entire RCFM, regardless of the technique used,<sup>10</sup> especially from the apical third of the root canal.<sup>12</sup>

Therefore, research is warranted to identify rapid, safe, and efficient method(s). The WaveOne (Dentsply Maillefer, Ballaigues, Switzerland) and Reciproc (VDW, Munich, Germany) are new single-file rotary systems that are designed for cleaning and shaping root-canal systems using reciprocating motion. They have shown better mechanical behaviour in comparison with conventional rotary files.<sup>13</sup> However, conflicting results were reported regarding their effectiveness in root-canal retreatment.<sup>5,9</sup> The S1 (Sendoline AB, Täby, Sweden) system is a new reciprocating single-file system that was recently introduced in the market and is designed for cleaning and shaping. Unlike the WaveOne and Reciproc systems, this system has not received any research attention, neither for cleaning and shaping nor for retreatment. Therefore, there is a need to investigate its potential in root-canal retreatment.

The aim of this in vitro study was to investigate the effectiveness of two retreatment rotary systems rotating in continuous motion and three systems rotating in reciprocating motion in removing a gutta-percha-based filling material from the root-canal system.

## Materials and Methods

### Root-canal treatment

Single-canal sound human teeth with curvatures less than 10°, which were determined by the Schneider technique,<sup>14</sup> were obtained from a pool of extracted teeth at College of Dentistry, Taqibah University. The teeth were extracted due to periodontal diseases or orthodontic considerations, but not specifically for the purpose of this study. Teeth with immature apices, previous treatments, or cracks or restorations were excluded. This resulted in a 90-teeth sample, with the sample size of each group within the range of those in previous studies adopting the same methodology. After standard access cavity preparation, the working lengths for cleaning and shaping as well as retreatment procedures were established and recorded. ProTaper-Universal rotary files (Dentsply, Maillefer, Switzerland) were used to clean and shape root canals to size F3. The irrigation protocol employed 2.5% sodium hypochlorite (NaOCl) between each file, followed by treatment with a 17% EDTA solution for one minute, and a final rinse with 2.5% NaOCl. The root canals were obturated with a gutta-percha core and Tubliseal sealer (SybronEndo, Orange, CA) using the lateral-compaction technique. Mesiodistal and buccolingual radiographs were obtained to check the quality of the root-canal filling. After insertion of temporary restorations, the teeth were stored at 37 °C with 100% humidity for one month to allow setting of the sealer.

### Root-canal-filling removal

Teeth were randomly divided into five groups (18 teeth in each group) using the random number table method. There were no significant intergroup differences in the means of teeth dimensions (teeth lengths and minimum and maximum root widths). The groups were as follows:

*Reciproc group*

The Reciproc-R25 file (VDW, Munich, Germany) was used with the VDW.Silver motor in an in–out pecking motion using the preset ‘Reciproc All’ parameters. The process was repeated until the file reached the working length.

*WaveOne group*

The WaveOne-Primary file (Dentsply) was used with the VDW.Silver motor in an in–out repeated pecking motion using the preset ‘WaveOne All’ parameters until the file reached the working length.

*S1-group*

The S1 (25/.06) file (Sendoline AB, Täby, Sweden) was used with the Sendoline S1 handpiece (Sendoline) in a pecking movement until the working length was reached.

*ProTaper-R-group*

The D1, D2, and D3 ProTaper-Retreatment files (Dentsply) were used in a crown-down manner with the VDW.Silver motor. The D1 (30/0.09) and D2 (25/0.08) files were used at 500 rpm and a 2-N·cm torque in the cervical and middle-thirds of the root canal, respectively. The D3 (20/0.07) file was used at 300 rpm and a 1.5-N·cm torque until the working length was reached. To complete shaping, an F2 ProTaper-Universal file was used until the working length was reached.

*Mtwo-R-group*

Mtwo®-Retreatment files (R25/.05 and R15/.05) (VDW) were used in a crown-down manner, both at 280 rpm and 1.2- and 1-N·cm torque, respectively, with the VDW.Silver motor. To complete shaping, the Mtwo-R 25/.06 file was used until the working length was reached.

Each file was used for two root canals. Retreatment completion was deemed when no RCFM was found on the last file. The time required for removal of the filling materials (min) and the associated complications (i.e. file fracture) were recorded (samples were discarded in such cases). After removal attempts, root canals were irrigated with 2.5% NaOCl and dried with paper points. Retreatments were performed by one operator.

*Measurement of the remaining filling material*

Two grooves were made on the buccal and lingual aspects of each tooth using a low-speed diamond disc. Then, the tooth was carefully cleaved with a sharpened spatula to obtain two halves, which were photographed using a high-resolution camera (Nikon D90; Nikon, Tokyo, Japan). Images were imported to the AutoCAD application (AutoDesk Corporation, San Rafael, CA) to measure the root-canal space and the remaining filling material (RFM) area; the latter was calculated as a percentage.

*Statistical analysis*

Data were analysed using the Shapiro–Wilk, one-way analysis of variance, and Chi-squared tests at  $p = 0.05$  using the SPSS software version 20 (SPSS Inc, Chicago, IL).

**Results**

Data were normally distributed ( $p > 0.05$ ). The results for the RFM, time required to remove the filling materials, and associated complications are presented in Table 1. The Mtwo-R group showed the highest mean RFM (51%), which was significantly higher than those in the other groups ( $p < 0.001$ ). There were no significant differences among the other groups ( $p > 0.05$ ). The ProTaper-R group required the least time for filling-material removal (4.95 min), which was significantly lower than those in the other groups ( $p < 0.05$ ) except the WaveOne group (5.83 min;  $p = 1.000$ ). Overall, 13 instruments (15.9%) separated during removal of the filling material. The proportion of instrument fracture in the Mtwo-R group (33.3%) was significantly greater than those in the WaveOne, Reciproc, and S1 groups (17.6%, 13.3%, and 12.5%, respectively,  $p = 0.009$ ).

**Discussion**

Removal of inadequate RCFMs is an essential step for disinfection of the root-canal system, which, in turn, is a prerequisite for successful retreatment.<sup>2</sup> This study investigated the effectiveness of retreatment and reciprocating rotary systems in removing gutta-percha-based RCFM. Different methods have been used for

**Table 1: Mean & standard deviation of teeth dimensions (length and the maximum width at the cemento-enamel junction, the remaining filling material (%), the time required for removal attempt (min) and proportion of Instruments' Separation during removal attempt.**

Groups (N = 90) [No of separated files]	Teeth' dimensions (mm)		Remaining filling materials (%)	Time required for filling removal	Instruments fracture filling removal attempt	
	Length	Roots' maximum width				
Reciprocating	Reciproc (13) [3]	23.1 ± 1.3	6.7 ± .5	32.6 ± 17.6 <sup>a</sup>	6.86 ± 1.58 <sup>a</sup>	2 (13.3%) <sup>a</sup>
	WaveOne (14) [1]	22.7 ± 1	6.4 ± .6	28.8 ± 17.1 <sup>b</sup>	5.83 ± 1.57 <sup>b</sup>	3 (17.6%) <sup>b</sup>
	S1 (14) [2]	22.3 ± 1.3	6.2 ± .3	26.1 ± 19.6 <sup>c</sup>	6.97 ± 1.86 <sup>c</sup>	2 (12.5) <sup>c</sup>
Conventional	ProTaper (16) [2]	22.9 ± 1.5	6.8 ± .7	22.2 ± 15.7 <sup>d</sup>	4.95 ± 1.37 <sup>a,c,d</sup>	0 (0%) <sup>d</sup>
	Mtwo (12) [0]	22.5 ± 1.2	6.6 ± .4	50.3 ± 20.9 <sup>a,b,c,d</sup>	7.81 ± 1.61 <sup>b,d</sup>	6 (33.3%) <sup>a,b,c,d</sup>
Total (69) [8]		22.7 ± 1.3	6.63 ± .55	31.2 ± 20.2	6.39 ± 1.85	13 (15.9%)

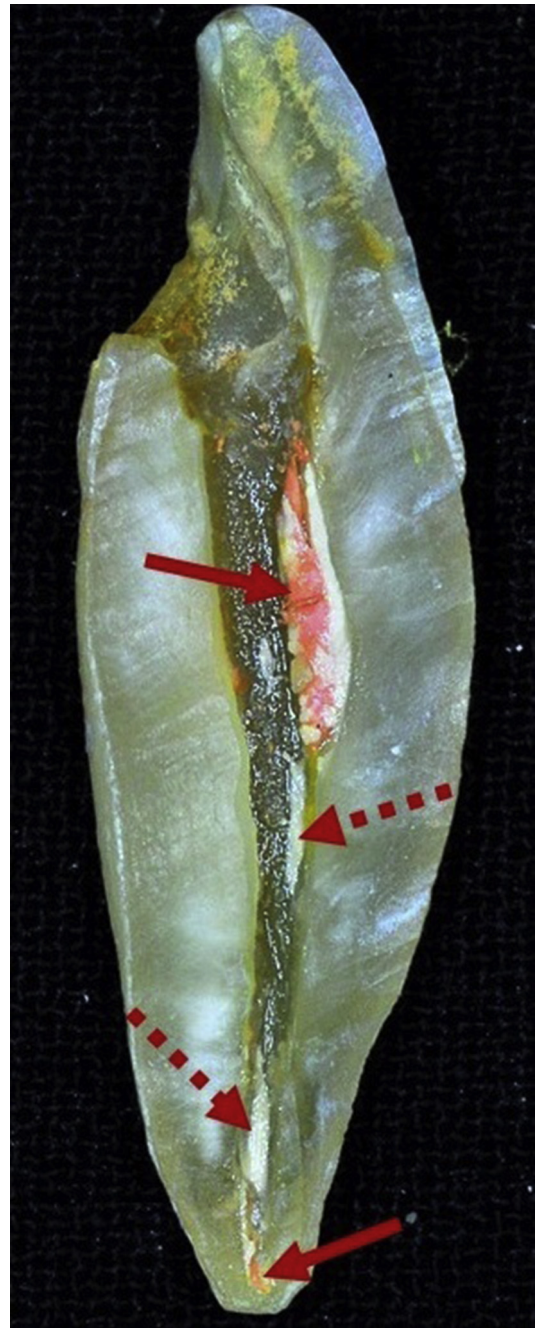
Symmetrical letters indicate a significant different between paired groups ( $p > 0.05$ ).



measurement of RFMs, including 3-dimensional analysis of cone-beam computed tomography or micro-computed tomography (micro-CT) images,<sup>6,15</sup> scanning electron microscopy,<sup>16</sup> 2-dimensional radiographic analysis,<sup>17</sup> tooth clearing,<sup>18</sup> and 2-dimensional analysis of split teeth images.<sup>9</sup> Each method has its advantages and drawbacks. For example, micro-CT is a non-destructive method that enables accurate 3-D measurements with different interventions.<sup>6</sup> However, it is time-consuming and costly, especially for assessments with a large number of samples, such as the current study. 2-D radiographs provide only 2-D information for 3-D structures, may show magnification distortions, and cannot visualize small volumes of debris.<sup>17</sup> The vertical split tooth method was used in the current study. Although this method is destructive, it provides direct visualization and hence better detection of RFMs, especially with good magnification. Moreover, it is more effective than 2-D radiographs.<sup>19</sup> Although some of the RFM may be lost during the splitting procedures, this can be avoided, as in the current study, if the samples are cleaved carefully without dislodging the filling materials.<sup>9,20</sup>

Removal of tooth crowns, as adopted in previous studies, has been claimed to result in better standardization of the working length and filling-material removal,<sup>9,20</sup> and can eliminate the limitations of the access cavity to root canals.<sup>9</sup> However, in clinical practice, many teeth undergoing retreatments have crowns. Therefore, the influence of the limited access to root canals on the effectiveness of retreatment instruments should be evaluated, especially with respect to the associated complications like instrument separation. In addition, standardization of the working length can be achieved even with the crown, because it depends on the root dimensions. Accordingly, teeth in our study were not decoronated, but this did not affect standardization of the root-canal space because standard access cavities were prepared. In addition, there were no significant intergroup differences in the mean teeth dimensions (teeth lengths and the minimum and maximum root widths). We also ensured standardization of the number of times each rotary system was used (each file was used for two root-canal procedures). In contrast, previous studies were inconsistent in this regard.<sup>21,22</sup> While Colombo et al. used the ProTaper-R and WaveOne files for five and four canals, respectively,<sup>21</sup> Zuolo et al. used the ProTaper-R and Mtwo-R files for three canals and the Reciproc files for a single canal.<sup>22</sup> Rios et al. used ProTaper-R and reciprocating systems for five and one canals, respectively.<sup>9</sup> Clinically, retreatment is usually performed in multiple canals; therefore, using reciprocating files for a single canal is impractical. Moreover, comparisons between files that are used for one canal with those used for many canals are neither standardized nor reliable. Nevertheless, further research to address this aspect is essential.

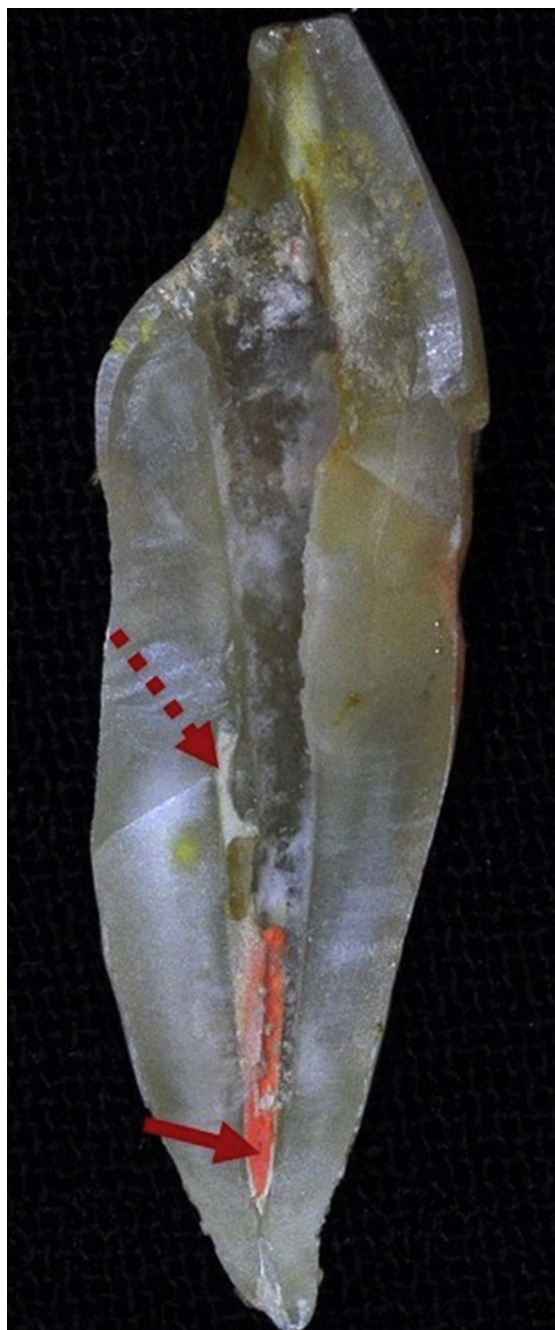
Solvents were not used in the current study, which can be a limitation. Although solvents facilitate penetration into RCFMs,<sup>19,21</sup> there is no agreement regarding their effectiveness.<sup>19–24</sup> Solvents were reported to increase the retreatment time as they form a slurry that sticks to canal walls and is hard to remove.<sup>21,22</sup> Horvath et al. found RCFM remnants inside dentinal tubules when solvents were used.<sup>24</sup> However, they advised against using solvents unless the working length could not be reached. A recent



**Figure 1:** A sample of the S1 Group showing 30.33% remaining filling material; a gutta-percha core (solid arrow) and a sealer (dashed arrow).

systematic review showed that solvents only enhance the files' penetration into the filling material but hinder the cleaning of the root-canal walls.<sup>10</sup> Nevertheless, solvents should be used carefully when needed, given their cytotoxic potential.<sup>25</sup>

Previous studies have shown some RFM after retreatments using advanced tools such as dental operating microscopes (DOMs) and ultrasonics.<sup>9,10</sup> The current study is not an exception, as all samples showed some RFM (Figures 1 and 2). The root-canal anatomy may limit the effectiveness of the instruments used. It is well established that no file, including the recently introduced files like TRUShaper



**Figure 2:** A sample of the WaveOne Group showing 28.79% remaining filling material; a gutta-percha core (solid arrow) and a sealer (dashed arrow).

(Dentsply-Tulsa, Tulsa, OK), can prepare the entire root-canal walls.<sup>26</sup> Therefore, instrument(s) that can completely remove the RCFMs are yet to be developed. Nevertheless, a combination of armamentaria, especially using DOM magnification, can increase RCFM removal.<sup>9,18,27</sup>

Apical size preparation for all samples was performed till the F3 file's size, which has a #30 apical size, although apical preparation with the retreatment files was up to size 25. It could be argued that this approach would always lead to remnant RCFM in the canal. This could be considered one of the study's limitations. However, as mentioned earlier, some RFM after retreatment procedures is inevitable even with

advanced tools such as DOMs and ultrasonics.<sup>9,10</sup> Therefore, using file size 25 for retreatment allowed better standardization of the majority of the study samples and negated the impact of file size, allowing a good comparison of different files in retreatment procedures.

The current study is the first to investigate the effectiveness of the S1 reciprocating system in retreatment. It is a single .06-taper file with an S-shaped cross-section and an ISO-25 non-cutting tip. It was as efficient as the Reciproc and WaveOne systems (Figures 1 and 2). Moreover, and in agreement with previous studies,<sup>9,21</sup> reciprocating systems were as effective overall as retreatment rotary systems, promoting their use for root-canal retreatment. A previous study showed that reciprocating systems were more efficient than retreatment or conventional rotary systems.<sup>22</sup> Rios et al. stated that the greater file taper increases the contact area with the RCFMs, facilitating their removal.<sup>9</sup> They also added that the broader counter-clockwise motion compared to the shorter clockwise motion contributes to better removal. However, the S1 files were as effective as the Reciproc and WaveOne files in the current study, even though they rotate 180° clockwise and 30° anti-clockwise. Thus, the good effectiveness of the reciprocating systems is most likely attributable to the reciprocating motion itself and not the rotation angle(s). The alternating motion of the file dislodged the filling material from the root-canal walls, facilitating its removal out of the canal as long as the instrument design (cross-sectional shape and the helical angle) allowed such removal. Moreover, the reciprocating motion kept the file centred in the canal,<sup>28</sup> which could be an additional reason.<sup>9</sup>

Contradicting results have been reported regarding the effectiveness of the Mtwo-R system. While most studies have reported poor effectiveness,<sup>22</sup> only two reported better performance of Mtwo-R compared to the ProTaper-R and Reciproc systems.<sup>24,31</sup> A recent study showed that Mtwo files (Mtwo-R combined with the Mtwo primary system) were better than the Reciproc system (R25 and R40).<sup>29</sup> However, the root canals in both groups were prepared to an ISO-50 apical size. The authors of that study claimed that while the reciprocating motion pushes the dislodged filling material apically, the continuous rotation tends to pull it coronally. In our study, the Mtwo-R samples were additionally prepared with the Mtwo-25/.06 file for standardization with the samples in the other groups. However, the Mtwo-R group's samples showed significantly more RFM. Therefore, the latter study's argument is questionable, making our results more consistent with those obtained in other studies.<sup>22</sup> Arguably, the poor efficacy of these files could be due to their low speed of rotation (280 rpm). However, the rotation speed of the ProTaper-R D3 file was almost similar in our study (300 rpm). While the ProTaper-R system consists of three files, the Mtwo-R has two files. This could contribute to the poor efficacy of the Mtwo-R files, considering that they have smaller tapers (.05) than the ProTaper-R files (.07, .08, and .09). Moreover, the smaller tip size of the Mtwo-R file in the apical part (R15/.05) could be an additional reason. This may also explain the high incidence of instrument separation within the Mtwo-R group, especially since all separated instruments were 15/.05. These findings were partially consistent with those obtained in two previous studies (all separations occurred with small instruments that are designed to remove filling materials from the apical third of the root canal).<sup>5,8</sup> However, no



instrument separation was noted in the ProTaper-R group in our study, which contradicts the findings of the latter two studies. This can be explained in the light of root-canal anatomy; while retreatments in our study were performed on single-canal teeth, those in the previous studies were conducted on the mesial root canals of lower molars.<sup>5,8</sup> The ProTaper-R system consists of three files, which distributes the stresses generated during retreatment on three files. The greater tapers of the ProTaper-R files (.07, .08, and .09) compared to that of the Mtwo-R files (.05) may be an additional reason. The greater the taper of the file, the greater the resistance to fracture.<sup>30</sup> This may also explain the good efficacy of reciprocating systems in the current study; considering that they are single-file systems. These files are made of NiTi M-Wire which significantly enhances their fracture resistance in comparison with files made of conventional NiTi alloys.<sup>31</sup>

Reciprocating systems prepare root canals faster than systems that rotate in continuous motion.<sup>32,33</sup> The instrumentation of root canals during retreatment may require more time, but reciprocating systems are still expected to be faster because they are single-file systems. However, previous studies have reported conflicting results, which could be mainly attributed to methodological differences.<sup>5,22,34</sup> Our results showed no significant difference in the overall time required to remove RCFMs between reciprocating and retreatment systems. However, the ProTaper-R system required the least time among all systems, except the WaveOne system. A recent study reported that the ProTaper-R system was significantly faster than the WaveOne system.<sup>5</sup> The working tip of the ProTaper-D1 file facilitates penetration and dislodging of the RCFMs, which could explain these results. Nevertheless, the time required for RCFM removal should not be separately overestimated as a critical factor for choosing files rather than being correlated with the cleaning effectiveness during retreatment.<sup>35</sup>

## Conclusions

Within the limitations of this in vitro study, it can be concluded that reciprocating rotary systems were as effective as retreatment rotary systems in removing RCFMs. While the ProTaper-Retreatment rotary system The Mtwo-R system showed the poorest efficacy and exhibited more instrument separations.

## Conflict of interest

The authors have no conflict of interest to declare.

## Ethical approval

This study was carried out in accordance with the Code of Ethics of the World Medical Association (Declaration of Helsinki).

## Authors' contributions

AAM developed the research project, performed the statistical analysis, and monitored the conduct and progress of the project. He performed the root-canal treatment and

retreatment. Wrote the discussion and revised the manuscript. AAAN searched the literature and wrote the first draft of the introduction and methodology. Revised the manuscript. AMNS searched the literature, finalised the introduction and methodology, performed data entry, and revised the manuscript. MAA performed the root sectioning, took photographs of teeth sections and manipulated images, and measured the remaining filling materials. All authors have critically reviewed and approved the final draft and are responsible for the content and similarity index of the manuscript.

## Acknowledgments

This work was funded by the Scientific Research Deanship, Taibah University (4207/1434), KSA.

## References

1. Ng Y-L, Mann V, Gulabivala K. A prospective study of the factors affecting outcomes of non-surgical root canal treatment: part 2: tooth survival. *Int Endod J* 2011; 44: 610–625.
2. Gorni F, Gagliani M. The outcome of endodontic retreatment: a 2-yr follow-up. *J Endod* 2004; 30: 1–4.
3. Chutich MJ, Kaminski EJ, Miller DA, et al. Risk assessment of the toxicity of solvents of Gutta-Percha used in endodontic retreatment. *J Endod* 1998; 24: 213–216.
4. Ladley RW, Campbell AD, Hicks ML, et al. Effectiveness of halothane used with ultrasonic or hand instrumentation to remove gutta-percha from the root canal. *J Endod* 1991; 17: 221–224.
5. Jorgensen B, Williamson A, Chu R, et al. The efficacy of the WaveOne reciprocating file system versus the ProTaper retreatment system in endodontic retreatment of two different obturating techniques. *J Endod* 2017; 43: 1011–1013.
6. Rodrigues CT, Duarte MAH, de Almeida MM, et al. Efficacy of CM-wire, M-wire, and nickel-titanium instruments for removing filling material from curved root canals: a micro-computed tomography study. *J Endod* 2016; 42: 1651–1655.
7. Keleş A, Arslan H, Kamalak A, et al. Removal of filling materials from oval-shaped canals using laser irradiation: a micro-computed tomographic study. *J Endod* 2015; 41: 219–224.
8. Beasley RT, Williamson AE, Justman BC, et al. Time required to remove guttacore, thermafil plus, and thermoplasticized gutta-percha from moderately curved root canals with protaper files. *J Endod* 2013; 39: 125–128.
9. De Azevedo Rios M, Villela AM, Cunha RS, et al. Efficacy of 2 reciprocating systems compared with a rotary retreatment system for gutta-percha removal. *J Endod* 2014; 40: 543–546.
10. Rossi-Fedele G, Ahmed HMA. Assessment of root canal filling removal effectiveness using micro-computed tomography: a systematic review. *J Endod* 2017; 43: 520–526.
11. Rödiger T, Kupis J, Konietzschke F, et al. Comparison of hand and rotary instrumentation for removing gutta-percha from previously treated curved root canals: a microcomputed tomography study. *Int Endod J* 2014; 47: 173–182.
12. Gergi R, Sabbagh C. Effectiveness of two nickel-titanium rotary instruments and a hand file for removing guttapercha in severely curved root canals during retreatment: an ex vivo study. *Int Endod J* 2007; 40: 532–537.
13. Pedullà E, Grande NM, Plotino G, Gambarini G, Rapisarda E. Influence of continuous or reciprocating motion on cyclic fatigue resistance of 4 different nickel-titanium rotary instruments. *J Endod* 2013; 39: 258–261.
14. Schneider SW. A comparison of canal preparations in straight and curved root canals. *Oral Surg Oral Med Oral Pathol* 1971; 32: 271–275.

15. Brooks JK, Kleinman JW. Retrieval of extensive gutta-percha extruded into the maxillary sinus: use of 3-dimensional cone-beam computed tomography. *J Endod* **2013**; 39: 1189–1193.
16. Pirani C, Pelliccioni GA, Marchionni S, et al. Effectiveness of three different retreatment techniques in canals filled with compacted gutta-percha or thermafil: a scanning electron microscope study. *J Endod* **2009**; 35: 1433–1440.
17. Colaco AS, Pai VAR. Comparative evaluation of the efficiency of manual and rotary gutta-percha removal techniques. *J Endod* **2015**; 41: 1871–1874.
18. Schirrmeister JF, Wrbas KT, Meyer KM, et al. Efficacy of different rotary instruments for gutta-percha removal in root canal retreatment. *J Endod* **2006**; 32: 469–472.
19. Kfir A, Tsesis I, Yakirevich E, et al. The efficacy of five techniques for removing root filling material: microscopic versus radiographic evaluation. *Int Endod J* **2012**; 45: 35–41.
20. Takahashi CM, Cunha RS, De Martin AS, et al. In vitro evaluation of the effectiveness of ProTaper universal rotary retreatment system for gutta-percha removal with or without a solvent. *J Endod* **2009**; 35: 1580–1583.
21. Colombo AP, Fontana CE, Godoy A, et al. Effectiveness of the waveone and ProTaper D systems for removing gutta-percha with or without a solvent. *Acta Odontol Latinoam* **2016**; 29: 262–267.
22. Zuolo AS, Mello JE, Cunha RS, et al. Efficacy of reciprocating and rotary techniques for removing filling material during root canal retreatment. *Int Endod J* **2013**; 46: 947–953.
23. Sae-Lim V, Rajamanickam I, Lim BK, et al. Effectiveness of ProFile.04 taper rotary instruments in endodontic retreatment. *J Endod* **2000**; 26: 100–104.
24. Horvath SD, Altenburger MJ, Naumann M, et al. Cleanliness of dentinal tubules following gutta-percha removal with and without solvents: a scanning electron microscopic study. *Int Endod J* **2009**; 42: 1032–1038.
25. Barbosa SV, Burkard DH, Spångberg LSW. Cytotoxic effects of gutta-percha solvents. *J Endod* **1994**; 20: 6–8.
26. Peters OA, Arias A, Paqué F. A micro-computed tomographic assessment of root canal preparation with a novel instrument, TRUShape, in mesial roots of mandibular molars. *J Endod* **2015**; 41: 1545–1550.
27. Yürüker S, Görduysus M, Küçükkaya S, et al. Efficacy of combined use of different nickel-titanium files on removing root canal filling materials. *J Endod* **2016**; 42: 487–492.
28. Franco V, Fabiani C, Taschieri S, et al. Investigation on the shaping ability of nickel-titanium files when used with a reciprocating motion. *J Endod* **2011**; 37: 1398–1401.
29. Alves FRF, Marceliano-Alves MF, Sousa JCN, et al. Removal of root canal fillings in curved canals using either reciprocating single- or rotary multi-instrument systems and a supplementary step with the XP-Endo finisher. *J Endod* **2016**; 42: 1114–1119.
30. Guilford WL, Lemons JE, Eleazer PD. A comparison of torque required to fracture rotary files with tips bound in simulated curved canal. *J Endod* **2005**; 31: 468–470.
31. Ye J, Gao Y. Metallurgical characterization of M-wire nickel-titanium shape memory alloy used for endodontic rotary instruments during low-cycle fatigue. *J Endod* **2012**; 38: 105–107.
32. Bürklein S, Schäfer E. Apically extruded debris with reciprocating single-file and full-sequence rotary instrumentation systems. *J Endod* **2012**; 38: 850–852.
33. Paqué F, Zehnder M, De-Deus G. Microtomography-based comparison of reciprocating single-file F2 ProTaper technique versus rotary full sequence. *J Endod* **2011**; 37: 1394–1397.
34. Bramante CM, Fidelis NS, Assumpção TS, et al. Heat release, time required, and cleaning ability of Mtwo R and ProTaper universal retreatment systems in the removal of filling material. *J Endod* **2010**; 36: 1870–1873.
35. Plotino G, Ahmed HMA, Grande NM, et al. Current assessment of reciprocation in endodontic preparation: a comprehensive review – part II: properties and effectiveness. *J Endod* **2015**; 41: 1939–1950.

**How to cite this article:** Madarati AA, Al-Nazzawi AA, Sammani AMN, Alkayyal MA. The efficacy of retreatment and new reciprocating systems in removing a gutta-percha-based filling material. *J Taibah Univ Med Sc* **2018**;13(5):452–458.