

Arthroscopic Removal of the Polyethylene Glenoid Component After Total Shoulder Arthroplasty: A Systematic Review

Journal of Shoulder and Elbow
Arthroplasty
Volume 6: 1–9
© The Author(s) 2022
Article reuse guidelines:
sagepub.com/journals-permissions
DOI: 10.1177/24715492221142967
journals.sagepub.com/home/sea



Yagiz Ozdag, MD¹, Jessica Baylor, BS¹, Daniel Hayes, BS¹
and Louis C Grandizio, DO¹ 

Abstract

Purpose: To identify prior studies of arthroscopic glenoid component removal after total shoulder arthroplasty (TSA) and understand indications, techniques and patient outcomes.

Methods: A search of the English language literature on arthroscopic removal of the glenoid component (ARGC) after TSA published between 2005 and 2021 was performed from MEDLINE and EMBASE databases. Articles with ARGC after TSA were identified and we recorded article characteristics as well as patient demographics and outcomes contained within the studies.

Results: A total of six publications (two case reports and four retrospective case series) detailing the outcome of ARGC performed on twenty-five shoulders were identified. The average time from index procedure to glenoid removal was 117 months and mean age at time of ARGC was 75 years. Although patient reported outcomes measures (PROMs) varied in type and reporting style, all articles reported improvements in PROMs. Twenty patients in this systematic review were evaluated for post-operative complications and the complication rate was found to be 15% (n = 3). There were 2 cases (18%) of superior migration of the humeral head relative to the glenoid and no reported cases of anterior or posterior humeral head subluxation. Two of 25 patients (8%) underwent subsequent open revision procedures.

Conclusions: The limited number of publications in this systematic review demonstrates that ARGC after TSA can result in improvements in both pain and PROMs. This less-invasive arthroscopic technique may be an alternative to open revision for lower demand patients; however, future prospective, comparative studies are necessary to better define indications.

Keywords

Total shoulder arthroplasty, glenoid loosening, arthroscopic removal, aseptic loosening, glenoid component

Date received 16 June 2022; revised received 9 September 2022; accepted 13 November 2022

Introduction

Loosening of the glenoid component is the most common reason for revision after total shoulder arthroplasty (TSA) and may be responsible for 30% of revision procedures.^{1–3} While TSA continues to be a frequently performed and effective treatment option for pain relief and improvement of function for degenerative shoulder conditions there remains concerns regarding implant longevity.^{4–7} A recent population-based cohort study has estimated the lifetime revision rate for a failed primary TSA to be as high as 25%.⁸ International joint replacement registries also have shown a rapidly growing number of shoulder arthroplasty procedures and future revision rates for TSA will likely be affected by this increase in primary volume.^{9,10}

Several treatment options have been proposed for glenoid loosening, including glenoid bone grafting, open conversion to a hemiarthroplasty, revision glenoid implantation and conversion to reverse total shoulder arthroplasty (RTSA).¹¹ However there is currently no consensus on the optimal

¹Department of Orthopaedic Surgery, Geisinger Commonwealth School of Medicine, Geisinger Musculoskeletal Institute, Danville, PA, USA

Corresponding Author:

Louis C Grandizio, Geisinger Commonwealth School of Medicine, Geisinger Musculoskeletal Institute, Department of Orthopaedic Surgery, 16 Woodbine Lane, Danville, PA 17821, USA.
Email: lgrandizio@geisinger.edu



surgical technique, as all of these proposed methods have been shown to have varying complication and reoperation rates.^{1,12–15} Arthroscopic removal of the glenoid component (ARGC) after TSA has been proposed as an option for presumed aseptic polyethylene loosening (Figures 1 and 2).¹⁶ Proposed advantages of this technique include a less-invasive arthroscopic approach, which may be beneficial in older patients with multiple medical comorbidities due to the potential to avoid some complications associated with open revision.^{17–19} Although open revision TSA techniques have been well studied, there remains a paucity of literature related to indications, outcomes and complications related to ARGC after TSA.

The purpose of this systematic review was to identify prior clinical series related to ARGC after TSA to better define indications, complications, and outcomes related to the procedure. We aimed to describe the clinical and PROMs that were previously published on this technique. We hypothesized that ARGC can be a useful operative technique for the revision of a failed primary TSA due to aseptic osteolysis of the polyethylene glenoid component.

Materials and Methods

Institutional Review Board exemption was obtained for this study. The paper follows the transparent reporting guidelines outlined in the Preferred Reporting Items for Systematic Reviews and Meta-Analyses checklist.

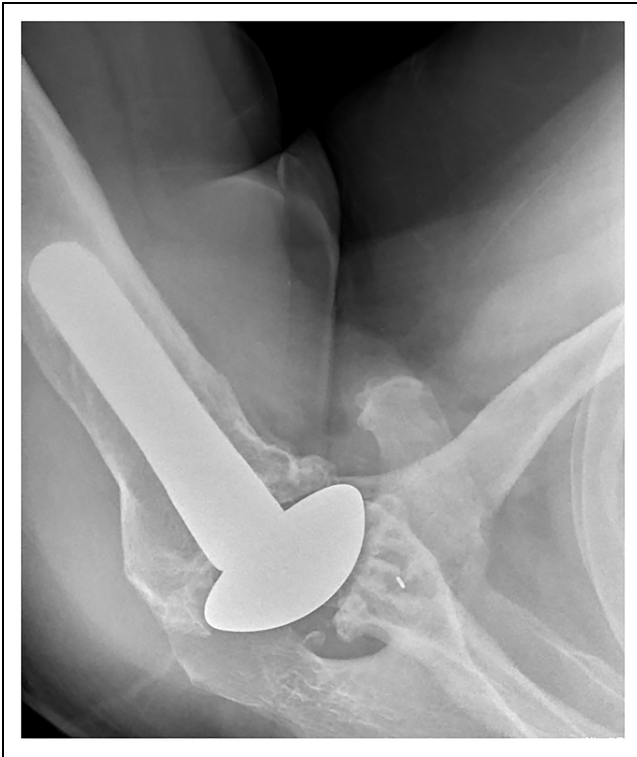

Figure 1. Preoperative (figure 1) and postoperative (figure 2) axillary radiographs for a case of ARGC after TSA.

Literature Search

On 07 September 2021, a search of the English language literature on ARGC after TSA published between 2005 and 2021 was performed from MEDLINE and EMBASE databases. A systematic review librarian from our institution's Health Science Library assisted with search strategy development. Search strategies are detailed in Table 1. We used 2005 as the start date as the first paper to describe this surgical technique was published that year.¹⁶ All article formats, including case reports, expert opinions, retrospective reviews, and others, were included in the index search. Non-human research, cadaveric studies, articles not available in English, and surgical techniques not related to arthroscopic glenoid component removal were excluded. To ensure all instances of this technique were captured, there was no article exclusion based on sample size, follow-up length, reported complications, or study design.

Study Selection and Data Extraction

Titles and citations were screened for duplicates in Mendeley (Elsevier, London, UK) and Microsoft Excel (Microsoft Corp, Redmond, WA). Remaining titles and abstracts were screened for eligibility independently by two authors, with any discrepancy being resolved through discussion and consultation with a third author. Eligible full-text articles were assessed against the inclusion and exclusion criteria and data extracted.

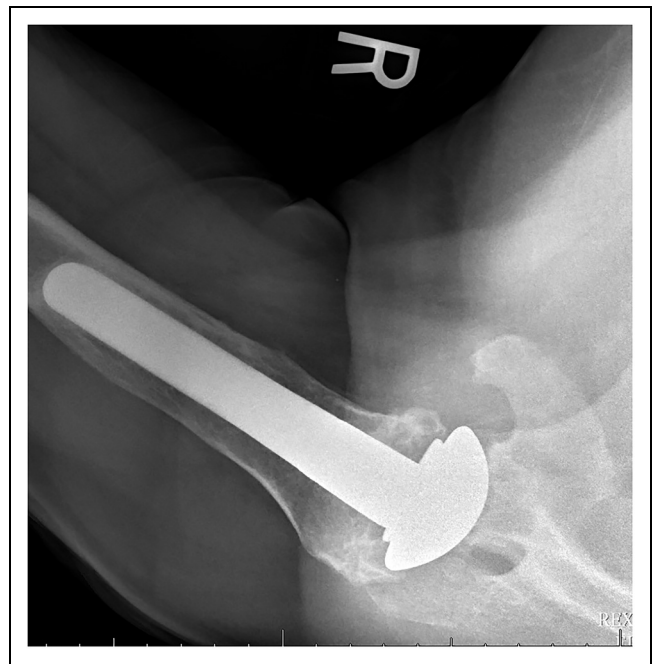


Figure 2. Preoperative (figure 1) and postoperative (figure 2) axillary radiographs for a case of ARGC after TSA.

Table 1. Demonstrates the search strategies (mesh terms) used in our systematic review.

MEDLINE	EMBASE
1 arthroscopic glenoid removal.mp.	1 arthroscopic glenoid removal.mp.
2 arthroscopic glenoid excision.mp.	2 arthroscopic glenoid excision.mp.
3 exp Postoperative Complications/ or exp Reoperation/ or revision.mp.	3 revision.mp.
4 revis*.mp.	4 revis*.mp.
5 exp Glenoid Cavity/ or glenoid.mp.	5 glenoid.mp.
6 exp Shoulder Joint/	6 total shoulder arthroplasty.mp.
7 exp Arthroplasty, Replacement/	7 exp arthroscopic surgery/ or exp arthroscopy/ or arthroscop*.mp.
8 exp Arthroscopy/ or arthroscop*.mp.	8 6 or 7
9 exp Prosthesis Failure/ or revision arthroplast*.mp.	9 5 and 8
10 device removal.mp. or exp Device Removal/	10 exp glenoid cavity/ or exp glenoid liner/ or exp glenoid baseplate/ or exp glenoid fossa prosthesis/ or exp "glenoid component of shoulder prosthesis"/ or exp glenoid sphere/
11 excis*.mp.	11 exp revision arthroplasty/ or revision.mp.
12 exp Arthroplasty, Replacement, Shoulder/ or total shoulder arthroplasty.mp.	12 exp device removal/
13 5 and 12	13 exp prosthesis failure/ or prosthesis fail*.mp.
14 3 or 4 or 9 or 10 or 11	14 10 and 13
15 13 and 14	15 10 and 12
16 limit 15 to (english language and yr = "2005 -Current")	16 7 and 10
	17 5 or 10
	18 7 and 17
	19 exp excision/ or excis*.mp.
	20 3 or 4 or 11 or 12 or 13 or 19
	21 18 and 20
	22 limit 21 to (english language and yr = "2005 -Current")

Data extracted from studies includes patient demographic information, index surgery and revision treatment technique, implant type, time to revision, revision surgical technique, functional outcomes, radiographic parameters, and complications. All data was extracted in duplicate and differences resolved through discussion and consultation with a third author. A risk of bias assessment and data synthesis was not performed due to the small volume of articles available on this topic.

Results

There was a total of 768 articles identified for review. Figure 3 illustrates article inclusion and exclusion for this investigation (Figure 3). After review of abstract and title, 50 articles were included for full text review. After applying exclusion criteria, a total of 6 articles were included in the final review (Figure 3). Of the 6 included articles, 2 were case reports, 3 were retrospective case series and 1 was a retrospective cohort study. A total of 25 cases of ARGC after TSA were identified across the included articles, the largest of which included 12 cases. An overview of information available within the clinical articles is presented in Table 2 (Table 2).

Case Characteristics

Demographic information was inconsistently reported, with 5/6 articles included either patient sex, age, or laterality. The mean age was 75 years (range 50–86). The indications for index TSA were commonly osteoarthritis, rheumatoid arthritis, and humeral head osteonecrosis. Average time from index TSA to ARGC was 117 months (range 12–240) (Table 2).

Outcomes

The patient reported outcome measures (PROMs) varied across articles, including American Shoulder and Elbow Surgeons Score (ASES), visual analog pain scale (VAS), Simple Shoulder Test (SST), UCLA Shoulder Score, and the Constant-Murley score (CMS) as noted in Table 3 (Table 3). Improvement from preoperative baseline was reported across all functional outcome measures, when available.

Range of Motion

Reported change in range of motion was also variable. Forward elevation was reported in 16 patients preoperatively

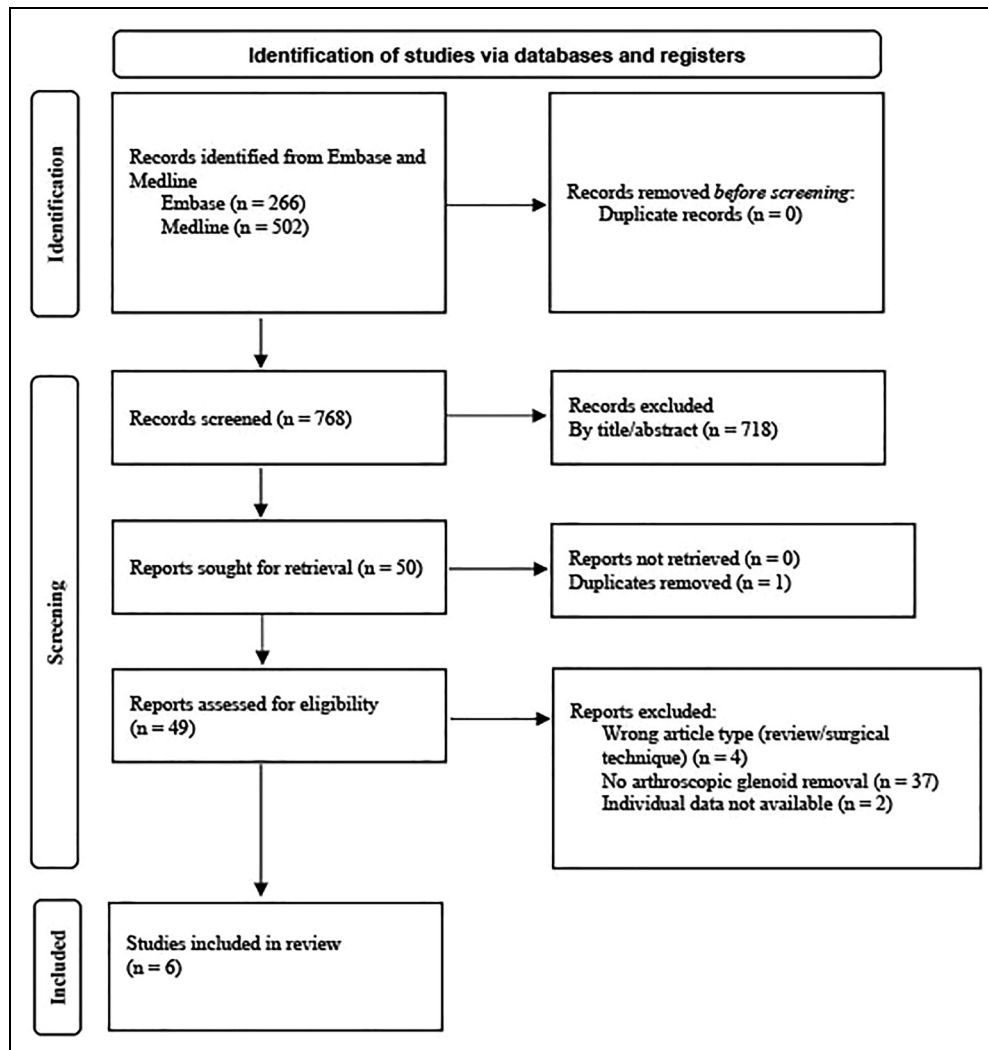


Figure 3. PRISMA flow chart for systemic review of arthroscopically removed glenoid components.

Table 2. Characteristics overview of articles with any arthroscopically removed glenoid component.

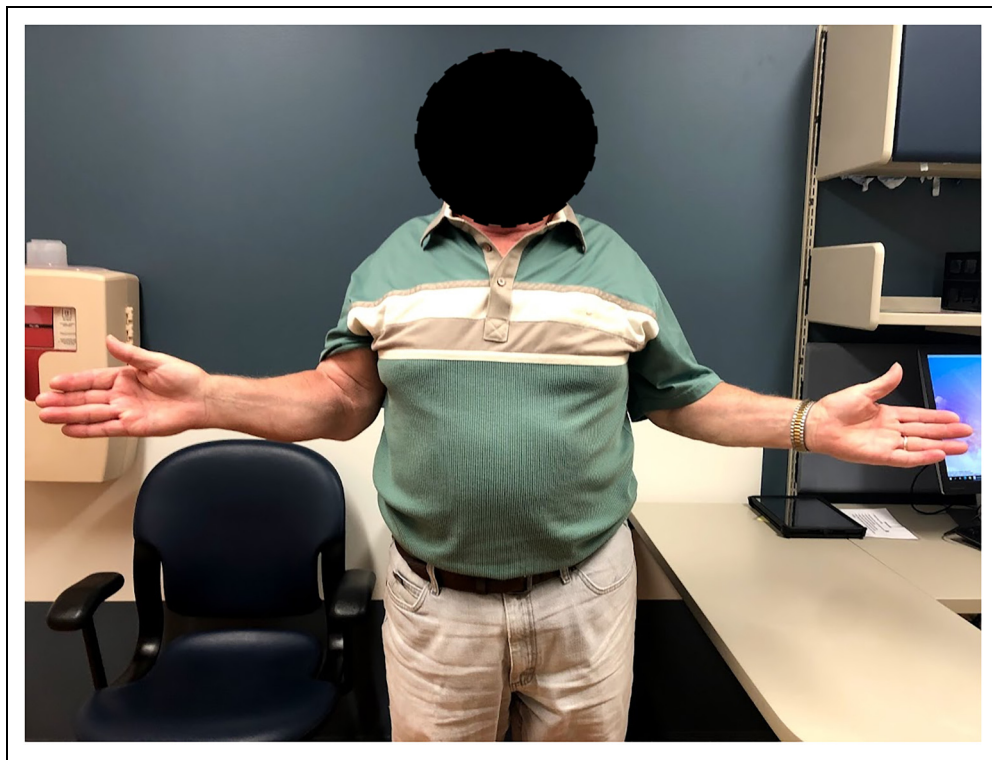Author, Year	Venjakob et al, 2015	Moen et al, 2012	Duetsch et al, 2007	Brochin et al, 2021	O'Driscoll et al, 2005	Raphael et al, 2010
Study Design	Case Report	Case Report	Case Series	Case Series	Case Series	Retrospective Cohort
Level of Evidence	V	V	IV	IV	IV	III
No. of Shoulders	1	1	1	12	5	5
Female Sex (%)	0 (0%)	1 (100%)	NR	7 (58%)	NR	NR
Age, Mean (range), Years	73	74	NR	76.2 (70-86)	72.6 (n/a)	64.3 (n/a)
Reason for AGR	Loosening, pain	Loosening, pain	NR	Loosening, pain (n = 12)	NR	NR
Average time between TSA and AGR, Mean (range), Months	26.1	15	NR	138.7 (12-240)	44.4 (n/a)	NR
Follow-up Time after AGR, Mean (range), Months	NR	2	NR	55.8 (20-172)	49 (n/a)	NR

NR = Not Reported

Table 3. Pre and post-surgical patient reported outcome data for arthroscopic glenoid removal.

Author, Year	Pre-Op PROM			Post-Op PROM					Pain/Satisfaction Scale
	ASES (Range)	VAS (Range)	SST (Range)	ASES (Range)	VAS (Range)	SST (Range)	UCLA	CMS	
Venjakob et al, 2015	NR	NR	NR	NR	NR	NR	NR	NR	NR
Moen et al, 2012	NR	NR	NR	NR	NR	NR	NR	NR	NR
Duetsch et al, 2007	47	2.5	NR	91	4.1	NR	NR	NR	“much better”
Brochin et al, 2021	0–72	0–10	0–10	10–88	1–8	0–12	NR	NR	NR
O’Driscoll et al, 2005	NR	NR	NR	NR	NR	NR	NR	NR	NR
Raphael et al, 2010	NR	NR	NR	NR	NR	NR	25.5*	82*	“better”

NR = Not Reported; * = Reported as Mean.

**Figure 4.** Clinical photograph demonstrating postop ROM after bilateral ARGC.

and 17 patients postoperatively with means of 117.5° and 117.4° respectively. External rotation was also reported in 16 patients with a mean of 32.5° pre-operatively and 34.7° post-operatively (Figures 4 and 5)

Imaging

Post-operatively imaging was not routinely reported in series of ARGC (Table 4). Of the 11 patients with detailed postoperative imaging, 0 (0%) had any indication of subluxation and 2 (18%) had some evidence of superior migration of the humeral head relative to the glenoid. The average lateral offset of these 10 patients was –1.7 mm compared to 6.4 mm pre-operatively.

Complications

Complications were reported in 4/6 articles (Table 5). The overall complication rate was 15% (3/20 cases). The most common complication that was reported was reoperation, which involved open revision. This was reported in 2/25 (8%) patients identified in our review due to continued pain.

Discussion

Our systematic review identified six clinical articles (25 cases) reporting on outcomes after ARGC after TSA (Figures 6 to 8). At the time of final follow-up (56 months)

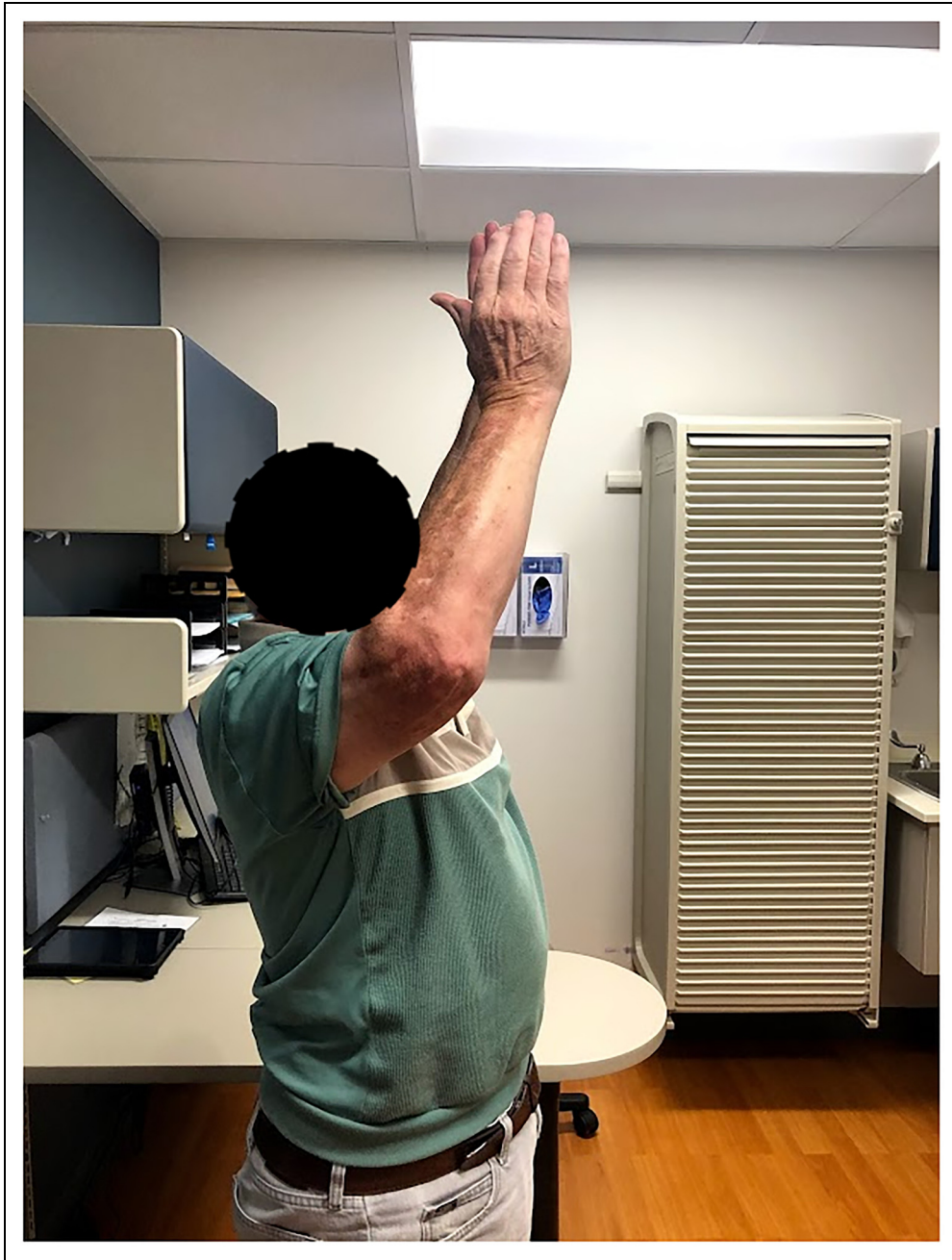


Figure 5. Clinical photograph demonstrating postop ROM after bilateral ARGC.

Brochin et al reported a decrease in VAS pain scale and an increase in ASES score.¹⁷ Raphael et al retrospectively compared outcomes of glenoid open and arthroscopic glenoid removal to revision reimplantation procedures.²⁰ They reported improved Constant and UCLA scores for 5 of their patients that underwent ARGC and there were no statistically significant differences between resection and reimplantation.²⁰ Additionally, O'Driscoll et al reported that all five patients in their series had improved pain after ARGC and stated that all the patients in their study would choose the

same procedure again.¹⁶ The outcomes of different revision techniques to address glenoid component loosening have also been reported on in previous studies. In their study comparing the outcomes of open conversion glenoid resection to reimplantation, Aibinder et al reported no significant differences in the outcomes between the two groups.²¹ Cheung et al reached a similar conclusion in their comparative study but additionally reported a slight improvement in active elevation for the reimplantation group.²² A previous systematic review has also identified improved PROMs,

Table 4. Details of the imaging modalities used in the publications in our review.

Author, Year	Post-operative Imaging	Subluxation	Superior Migration	Lateral Humeral Offset (mean, mm)	Other
Venjakob et al, 2015	NR	NR	NR	NR	NR
Moen et al, 2012	Yes (n = 1)	NR	NR	NR	“stable aligned humeral stem with reduced glenohumeral joint”
Duetsch et al, 2007	NR	NR	NR	NR	NR
Brochin et al, 2021	Yes (n = 10)	0/10	1/10	-1/7	NR
O'Driscoll et al, 2005	Yes (n = 1)	NR	1	NR	“concentric remodeling”
Raphael et al, 2010	NR	NR	NR	NR	NR

NR = Not Reported.

Table 5. Pre and post-surgical range of motion and complications for arthroscopic glenoid removal.

Author, Year	Pre-Operative ROM			Post-Operative ROM			Complications
	Forward Elevation	External Rotation	Internal Rotation	Forward Elevation	External Rotation	Internal Rotation	
Venjakob et al, 2015	NR	NR	NR	NR	NR	NR	NR
Moen et al, 2012	NR	NR	NR	“full”	“full”	“full”	None
Duetsch et al, 2007	150 (n = 1)	45 (n = 1)	NR	140 (n = 1)	45 (n = 1)	NR	NA
Brochin et al, 2021	147 (n = 10)	43.5 (n = 10)	Gluteal (4), T9 (2), L3 (1), T12 (1)	127 (n = 10)	43 (n = 10)	Gluteal (2), L2 (2), L5 (1), L1 (1)	Revision (2)
O'Driscoll et al, 2005	52 (n = 5)	8 (n = 5)	Buttock (3), Sacrum (1), L5 (1)	93	16	Buttock (2), L4 (1), T12 (1), L5 (1)	Exacerbation of lymphedema (1)
Raphael et al, 2010	NR	NR	NR	NR	NR	NR	NR

NA = Unable to Determine, NR = Not Reported.

mainly in pain scale, ASES and Constant scores, for both revision TSA and conversion to RTSA after a failed index TSA.¹ Findings from this current systemic review indicate similar improvement in pain relief and PROMs after ARGC.

A proposed benefit of ARGC after TSA is that it may be less invasive (and potentially less morbid than open revision). This systematic review found that in primary clinical articles related to ARGC after TSA, complications were infrequently reported. Twenty patients were evaluated for postoperative complications. One patient (5%) had exacerbation of their pre-existing lymphedema.^{16,17} Two patients 2 patients (10%) had persistent pain postoperatively and underwent conversion to RTSA.^{16,17} None of the publications in our review reported any intraoperative complications for these reoperations. In addition to ARGC after TSA, several revision options such as conversion to

RTSA, open conversion to hemiarthroplasty, and component re-implantation for aseptic glenoid component loosening exist. Previous publications on these revision options have shown variable rates of complications and reoperations. Additionally, a larger retrospective series with 127 shoulders focusing on conversions to RTSA reported a 29% rate of intraoperative complication and 20% reoperation rate.¹³ A complication rate of 35% and a 29% reoperation rate was reported by another retrospective study that outlined outcomes of open revision hemiarthroplasty for aseptic glenoid component loosening.¹⁴ A higher reoperation rate of 67% for glenoid component revision has also been reported.¹⁵ Additionally, a systematic review of 3843 failed index TSAs undergoing either revision TSA or conversion to RTSA reported a 20% postoperative complication and a 13% re-operation rate.¹ It is worth noting that the leading cause for re-operation in these studies was recurrent loosening of

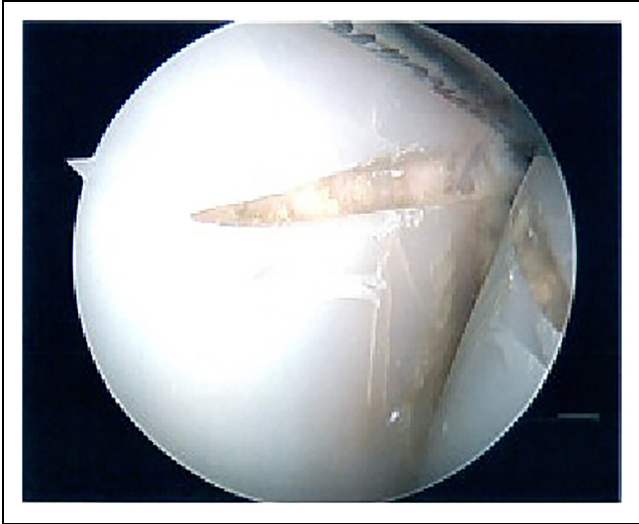

Figure 6. Intraoperative (6, 7) photographs depicting ARGC after TSA. Figure 8 depicts the resected polyethylene glenoid component and cement.




Figure 8. Intraoperative (6, 7) photographs depicting ARGC after TSA. Figure 8 depicts the resected polyethylene glenoid component and cement.

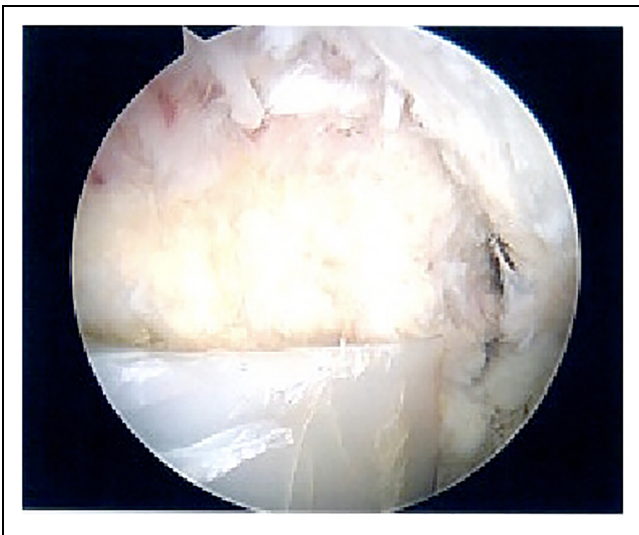

Figure 7. Intraoperative (6, 7) photographs depicting ARGC after TSA. Figure 8 depicts the resected polyethylene glenoid component and cement.

prosthetic components and instability.^{1,12-15} Our review shows lower reported complications and revision rates for ARGC when compared to other operative modalities for treating aseptic glenoid component loosening.

The findings in this systematic review indicate that ARGC has historically been performed for older patients (mean age of 75). A plethora of factors such as infection, instability, loosening and the status of the rotator cuff can impact the management of a failed primary TSA.²³ Even though re-implantation of the glenoid component may have potential advantages, open revision procedures can introduce substantial risk particularly for

elderly patients with multiple medical co-morbidities.²⁴ Prior studies have indicated that patients undergoing re-implantation and conversion to RTSA may have less-advanced arthritic disease and higher baseline levels of function than those undergoing ARGC.²⁰ Several examples from our findings support this trend. O'Driscoll performed this procedure in patients with morbidity obesity, difficult index procedure exposure, large rotator cuff tears, and other those with severe medical co-morbidities.¹⁶ In their series, Raphael et al indicated that the resection group had more prior surgeries and lower functional demands.²⁰ Additionally, they stated that ARGC was performed in patients with insufficient glenoid bone stock.²⁰ In this context, ARGC might be better reserved for patients who have a lower baseline functional demands or may be at higher risk for surgical morbidity with open revision procedures in patients with co-morbidities. In addition, considering that ROM does not appear to substantially change postoperatively, ideal candidates for this procedure would have pain as a main complaint and should be satisfied with their preoperative ROM.

This study has a number of limitations which should be considered. Overall, there were a limited number of articles (6) and included patients (25). Patient baseline demographics and PROMs were inconsistently reported, making comparisons across clinical series difficult. Furthermore, the included articles overall contained lower levels of evidence, and in the absence of large comparative series, making comparisons between different revision techniques can be difficult.

Conclusions

Our systematic review identified 6 articles that reported on the outcomes of ARGC for aseptic loosening after TSA.

The included clinical series indicate that ARGC can improve pain and functional outcomes in appropriately selected patients. At present, patients undergoing ARGC appear to be older, have lower functional demands and may be at risk for medical complications with open revision. ARGC after TSA has a low rate of subsequent reoperation (8%) and has the potential to avoid some of the complications associated with open revision arthroplasty procedures. As a less-invasive arthroscopic technique, ARGC after TSA may be an alternative to open revision for lower demand patients; however, future prospective, comparative studies are necessary to better define indications and outcomes.

Declaration of Conflicting Interests

The authors declare that there is no conflict of interest.

Declaration of Conflicting Interests

The author(s) declared no potential conflicts of interest with respect to the research, authorship, and/or publication of this article.

Funding

The author(s) received no financial support for the research, authorship, and/or publication of this article

ORCID iD

Louis C Grandizio  <https://orcid.org/0000-0002-3551-3266>

References

- Ravi V, Murphy RJ, Moverley R, Derias M, Phadnis J. Outcome and complications following revision shoulder arthroplasty : a systematic review and meta-analysis. *Bone Jt Open*. 2021;2(8):618–630.
- Matsen FA, 3rd, Clinton J, Lynch J, Bertelsen A, Richardson ML. Glenoid component failure in total shoulder arthroplasty. *J Bone Joint Surg Am*. 2008;90(4):885–896.
- Rojas J, Choi K, Joseph J, Srikumaran U, McFarland EG. Aseptic glenoid baseplate loosening after reverse total shoulder arthroplasty: a systematic review and meta-analysis. *JBJS Rev*. 2019;7(5):e7.
- Wright TW, Flurin PH, Crosby L, Struk AM, Zuckerman JD. Total shoulder arthroplasty outcome for treatment of osteoarthritis: a multicenter study using a contemporary implant. *Am J Orthop. (Belle Mead NJ)* 2015;44(11):523–526.
- Zarkadas PC, Throckmorton TQ, Dahm DL, Sperling J, Schleck CD, Cofield R. Patient reported activities after shoulder replacement: total and hemiarthroplasty. *J Shoulder Elbow Surg*. 2011;20(2):273–280.
- Magosch P, Lichtenberg S, Habermeyer P. Survival of stemless humeral head replacement in anatomic shoulder arthroplasty: a prospective study. *J Shoulder Elbow Surg*. 2021;30(7):e343–e355.
- Rasmussen JV, Hole R, Metlie T, et al. Anatomical total shoulder arthroplasty used for glenohumeral osteoarthritis has higher survival rates than hemiarthroplasty: a nordic registry-based study. *Osteoarthritis Cartilage*. 2018;26(5):659–665.
- Craig RS, Lane JCE, Carr AJ, Furniss D, Collins GS, Rees JL. Serious adverse events and lifetime risk of reoperation after elective shoulder replacement: population based cohort study using hospital episode statistics for England. *Br Med J*. 2019;364:l298.
- Boorman RS, Kopjar B, Fehringer E, Churchill RS, Smith K, Matsen FA, 3rd. The effect of total shoulder arthroplasty on self-assessed health status is comparable to that of total hip arthroplasty and coronary artery bypass grafting. *J Shoulder Elbow Surg*. 2003;12(2):158–163.
- Lübbecke A, Rees JL, Barea C, Combesure C, Carr AJ, Silman AJ. International variation in shoulder arthroplasty. *Acta Orthop*. 2017;88(6):592–599.
- Pinkas D, Wiater B, Wiater JM. The glenoid component in anatomic shoulder arthroplasty. *J Am Acad Orthop Surg*. 2015;23(5):317–326.
- Melis B, Bonneville N, Neyton L, et al. Glenoid loosening and failure in anatomical total shoulder arthroplasty: is revision with a reverse shoulder arthroplasty a reliable option? *J Shoulder Elbow Surg*. 2012;21(3):342–349.
- Bartels DW, Marigi E, Sperling JW, Sanchez-Sotelo J. Revision reverse shoulder arthroplasty for anatomical glenoid component loosening was not universally successful: a detailed analysis of 127 consecutive shoulders. *J Bone Joint Surg Am*. 2021;103(10):879–886.
- Sheth M, Sholder D, Padegimas EM, et al. Failure of anatomic total shoulder arthroplasty with revision to another anatomic total shoulder arthroplasty. *Arch Bone Jt Surg*. 2019;7(1):19–23.
- Bonneville N, Melis B, Neyton L, et al. Aseptic glenoid loosening or failure in total shoulder plasty: revision with glenoid reimplantation. *J Shoulder Elbow Surg*. 2013;22(6):745–751.
- O'Driscoll SW, Petrie RS, Torchia ME. Arthroscopic removal of the glenoid component for failed total shoulder arthroplasty. A report of five cases. *J Bone Joint Surg Am*. 2005;87(4):858–863.
- Brochin RL, Zastrow RK, Patel AV, Parsons BO, Flatow EL, Cagle PJ. Arthroscopic glenoid removal for aseptic loosening in total shoulder arthroplasty. *In Seminars in Arthroplasty: J Shoulder Elbow Surg*. 2021;31(7):197–201.
- Venjakob AJ, Reichwein F, Nebelung W. Arthroscopic removal of a polyethylene glenoid component in total shoulder arthroplasty. *Arthrosc Tech*. 2015;4(2):e149–e152.
- Deutsch A, Abboud JA, Kelly J, et al. Clinical results of revision shoulder arthroplasty for glenoid component loosening. *J Shoulder Elbow Surg*. 2007;16(6):706–716.
- Raphael BS, Dines JS, Warren RF, et al. Symptomatic glenoid loosening complicating total shoulder arthroplasty. *HSS J*. 2010;6(1):52–56.
- Aibinder WR, Schoch B, Schleck C, Sperling JW, Cofield RH. Revisions for aseptic glenoid component loosening after anatomic shoulder arthroplasty. *J Shoulder Elbow Surg*. 2017;26(3):443–449.
- Cheung EV, Sperling JW, Cofield RH. Revision shoulder arthroplasty for glenoid component loosening. *J Shoulder Elbow Surg*. 2008;17(3):371–375
- Favard L. Revision of total shoulder arthroplasty. *Orthop Traumatol Surg Res*. 2013;99(1 Suppl):S12–S21.
- Dillon MT, Prentice HA, Burfeind WE, Singh A. Risk factors for Re-revision surgery in shoulder arthroplasty. *J Am Acad Orthop Surg*. 2020;28(23):e1049–e1058.