

Left Side Appendicitis with Midgut Malrotation in an Adult

David Jérémie Birnbaum, Yann Geffroy¹, Géraldine Goin, Paul Balandraud

Departments of Visceral and Thoracic Surgery, ¹Radiology, Hôpital d'Instruction des Armées A. Laveran, Marseille Armées, France

INTRODUCTION

Midgut malrotation (MMR) is a congenital nonrotation or incomplete rotation of the primitive intestinal loop around the axis of superior mesenteric artery (SMA) during fetal development. MMR is more known by pediatrics than adult surgeons because it occurs at a rate of about 1 in 500 live births.^[1]

Up to now, surgical treatment has been guided by the experience from pediatric surgery and Ladd's procedure has been the treatment of choice in adults. However, a dilemma arises when patients are asymptomatic and incidentally diagnosed with MMR during another abdominal affection such as appendicitis. Volvulus is the main complication of MMR, but the occurrence of acute midgut volvulus of clinical significance in the absence of surgical treatment is unknown. Therefore, practicing Ladd's procedure on asymptomatic patients may put them at risk of complications. Here, we report the case of a 37-year-old patient with acute left side appendicitis and asymptomatic MMR.

CASE REPORT

A 37-year-old man was admitted at the emergency unit of our hospital with acute abdominal pain, which started the previous night. Patient's history revealed no previous illness or surgery. Pain was diffused, with tenderness mainly in upper left quadrant, and the temperature was

ABSTRACT

Midgut malrotation (MMR) is a congenital anomaly referring to either nonrotation or incomplete rotation of the primitive intestinal loop around the axis of the superior mesenteric artery during fetal development. Adult MMR is rare and majority of MMR in adults remains asymptomatic throughout life. The increasing use of diagnostic imaging for acute abdominal pain will lead to more incidental recognitions of MMR. Up to now, surgical treatment has been guided by the experience from pediatric surgery, and Ladd's procedure has been the treatment of choice in adults with MMR. However, a major dilemma arises when patients are essentially asymptomatic and incidentally diagnosed with MMR during another abdominal affection like acute appendicitis. The surgeon has to decide whether it is necessary to also treat the MMR. Here, we report a rare case of a 37-year-old patient with acute left side appendicitis in association with asymptomatic MMR. We discuss whether correction of the asymptomatic malrotation was indicated.

Key words: Bowel obstruction, Ladd's procedure, left side appendicitis, midgut malrotation, volvulus

37.5°C. Laboratory tests showed an elevated blood cell count (15,000) with normal C-reactive protein. A diagnosis of peritonitis was suspected, either by perforated gastroduodenal ulcer or diverticulitis. Contrast-enhanced abdominal computed tomography showed acute left side appendicitis with midgut malrotation [Figure 1a-c]. Appendix was enlarged, with a transverse diameter measured to 13 mm, associated with four stercoliths visualized in the plane of the left renal vein. The entire small bowel was found in the left half of the abdomen and the entire colon was found in the right half. The superior mesenteric vein (SMV) was to the left of the SMA rather than in the normal right ventral position. The patient was planned for surgery and a laparotomy was performed. Surgical findings confirmed the severe inflammation of the appendix and the ileocecal region(s) located in the left quadrant. A Ladd's procedure was performed, including derotation of the bowel, appendectomy, division of the mesenteric bands lying across the duodenum from cecum to right upper quadrant, widening of the base of the mesentery, taking down the ligament of Treitz, moving the duodenum to the right, and finally returning the bowel to a position of nonrotation with the cecum placed into the left upper quadrant [Figure 1d]. The patient was discharged on the seventh postoperative day with no complication.

Access this article online

Quick Response Code:



Website:
www.jstcr.org

DOI:
10.4103/2006-8808.118627

Address for correspondence: Dr. David Jérémie Birnbaum, Department of Digestive Surgery, Hôpital Nord, Marseille, France. E-mail: david.birnbaum10@gmail.com

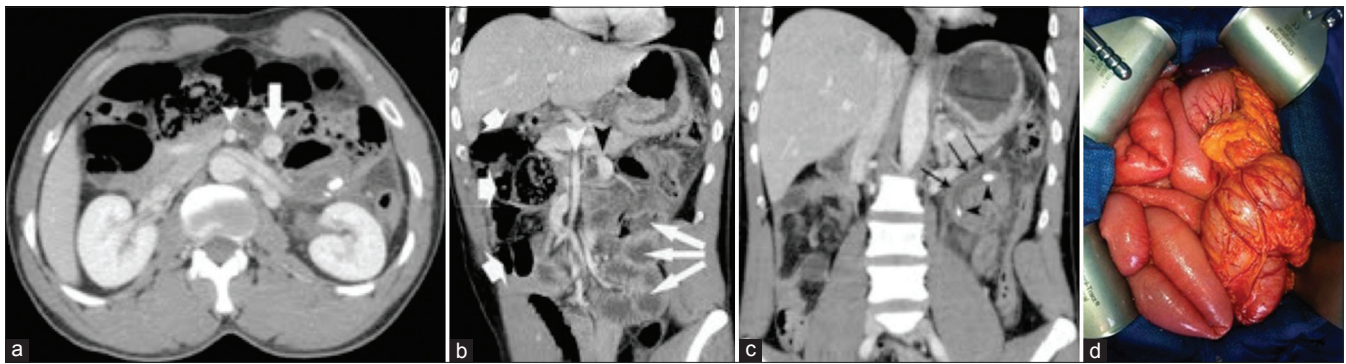


Figure 1: (a) Portal-venous phase computed tomography (CT) image. Superior mesenteric vein (arrow) is on the left side of the superior mesenteric artery (arrowhead); (b) Coronal multiplanar reformation (MPR) from portal-venous phase CT demonstrates a midgut malrotation. Superior mesenteric vein (black arrowhead) is on the left side of the superior mesenteric artery (white arrowhead). The entire small bowel (thin arrows) is in the left half of the abdomen and colon (thick arrows) is in the right half; (c) Coronal MPR from portal-venous phase CT demonstrates a acute upper left side appendicitis (arrows) with two stercoliths (arrowheads) and (d) Operative view with the entire small bowel in the right half of the abdomen and colon in the left half

DISCUSSION

Left side acute appendicitis is extremely rare but can occur with congenital abnormalities with true left-sided appendix such as situs inversus totalis and MMR or as an atypical presentation of a long right-sided appendix, which is thus projected into the left lower quadrant.^[2]

MMR is a congenital anomaly referring to either nonrotation or incomplete rotation of the primitive intestinal loop around the axis of the SMA during fetal development. Adult MMR is rare because the diagnosis is usually made before the age of 1 year.^[1,3] The most dreaded complication of MMR is volvulus, which occurs in 60-70% of neonates diagnosed with MMR^[3,4] and delay in diagnosis may lead to extended intestinal necrosis.^[5] Diagnosis is made in the adult in the presence of chronic abdominal symptoms, during surgery for acute abdomen, or incidentally during an imaging exam for no specific symptoms. In the case of our patient, ultrasonography was not performed. This exam should show the whirlpool sign, which is wrapping of SMV and bowel around the SMA. The majority of MMR in adults remains asymptomatic throughout life.^[6] Adult MMR is rare with an incidence ranging from 0.0001 to 0.19% in asymptomatic adults.^[6] There is no consensus on the management of asymptomatic MMR in adults. The problem is to know whether it is necessary or not to treat asymptomatic MMR. There are several possibilities:

- a) First, performing appendectomy only. Some authors have advocated operative management only in patients with MMR symptoms because they found that patients had a low risk of complication and elective surgery was not necessary with close follow-up^[7]
- b) Second, performing appendectomy and Ladd's procedure in the same time, to treat MMR and avoid complications. For some authors the risk of volvulus,

even if low, warrants operative intervention especially since the risk for volvulus is lifelong and do not diminish with age.^[5] Actually, the current literature supports surgical correction of MMR for patients with minor symptoms or incidentally found MMR because very few of these patients are truly asymptomatic if careful history is obtained.^[8] In our case, this attitude is supported because of a difficult follow-up.

The complication of surgical management of MMR is bowel obstruction secondary to adhesion after Ladd's procedure. In a pediatric series, this complication occurred between 10-15% of cases after Ladd's procedure.^[5]

Finally, the choice of surgical approach could be discussed. Several studies of retrospective series have shown that laparoscopic treatment of MMR is feasible in most cases, with good perioperative outcome,^[9] but there is still a lack of long-term follow-up with this method. Benefits of laparoscopic surgery were: Less pain, early return of bowel function, and shorter hospital stay with a decrease in the incidence of postoperative adhesion possibly translating into a lower incidence of postoperative bowel obstruction. According to literature, most patients are operated by laparotomy and only a few by a laparoscopic approach.^[10]

We chose laparotomy because of the absence of experienced pediatric surgeons.

CONCLUSION

Management of incidentally MMR diagnosis during another abdominal affection can be either conservative or not. The "watch and wait" attitude could be proposed if the patient could be followed, otherwise the surgical attitude should definitively be proposed.

REFERENCES

1. Filston HC, Kirks DR. Malrotation-the ubiquitous anomaly. *J Pediatr Surg* 1981;16(4 Suppl 1):614-20.
2. Hou SK, Chern CH, How CK, Kao WF, Chen JD, Wang LM, *et al.* Diagnosis of appendicitis with left lower quadrant pain. *J Chin Med Assoc* 2005;68:599-603.
3. Torres AM, Ziegler MM. Malrotation of the intestine. *World J Surg* 1993;17:326-31.
4. Millar AJ, Rode H, Cywes S. Malrotation and volvulus in infancy and childhood. *Semin Pediatr Surg* 2003;12:229-36.
5. Murphy FL, Sparnon AL. Long-term complications following intestinal malrotation and the Ladd's procedure: A 15 year review. *Pediatr Surg Int* 2006;22:326-9.
6. von Flüe M, Herzog U, Ackermann C, Tondelli P, Harder F. Acute and chronic presentation of intestinal nonrotation in adults. *Dis Colon Rectum* 1994;37: 192-8.
7. Choi M, Borenstein SH, Hornberger L, Langer JC. Heterotaxia syndrome: The role of screening for intestinal rotation abnormalities. *Arch Dis Child* 2005;90:813-5.
8. Moldrem AW, Papaconstantinou H, Broker H, Megison S, Jeyarajah DR. Late presentation of intestinal malrotation: An argument for elective repair. *World J Surg* 2008;32:1426-31.
9. Fraser JD, Aguayo P, Sharp SW, Ostlie DJ, St Peter SD. The role of laparoscopy in the management of malrotation. *J Surg Res* 2009;156:80-2.
10. Akbulut S, Ulku A, Senol A, Tas M, Yagmur Y. Left-sided appendicitis: Review of 95 published cases and a case report. *World J Gastroenterol* 2010;16:5588-602.

How to cite this article: Birnbaum DJ, Geffroy Y, Goin G, Balandraud P. Left side appendicitis with midgut malrotation in an adult. *J Surg Tech Case Report* 2013;5:38-40.

Source of Support: Nil, **Conflict of Interest:** None declared.

Author Help: Reference checking facility

The manuscript system (www.journalonweb.com) allows the authors to check and verify the accuracy and style of references. The tool checks the references with PubMed as per a predefined style. Authors are encouraged to use this facility, before submitting articles to the journal.

- The style as well as bibliographic elements should be 100% accurate, to help get the references verified from the system. Even a single spelling error or addition of issue number/month of publication will lead to an error when verifying the reference.
- Example of a correct style
Sheahan P, O'leary G, Lee G, Fitzgibbon J. Cystic cervical metastases: Incidence and diagnosis using fine needle aspiration biopsy. *Otolaryngol Head Neck Surg* 2002;127:294-8.
- Only the references from journals indexed in PubMed will be checked.
- Enter each reference in new line, without a serial number.
- Add up to a maximum of 15 references at a time.
- If the reference is correct for its bibliographic elements and punctuations, it will be shown as CORRECT and a link to the correct article in PubMed will be given.
- If any of the bibliographic elements are missing, incorrect or extra (such as issue number), it will be shown as INCORRECT and link to possible articles in PubMed will be given.