

A Case of Bladder Cancer after Radiation Therapy for Prostate Cancer

Naoto Kaburaki Takeo Kosaka Satoshi Yazawa Mototsugu Oya

Department of Urology, Keio University School of Medicine, Tokyo, Japan

Key Words

Bladder cancer · Hematuria · Radiation therapy · Prostate cancer

Abstract

An 86-year-old male who presented with the chief complaint of clot retention and had a history of prostate cancer treated with external beam radiation therapy 11 years previously is described. Cystoscopy revealed radiation cystitis in coexistence with bladder cancer. Since bladder cancer may be present in patients with macroscopic hematuria who have a history of radiation therapy, referral to an urologist is recommended.

© 2014 S. Karger AG, Basel

Introduction

Hematuria and following clot retention after radiation therapy for prostate cancer suggests the presence of radiation-induced cystitis, and coexisting bladder cancer should also be considered. Here, we report a case of bladder cancer, indicated by clot retention due to gross hematuria, which occurred 11 years after radiation therapy for prostate cancer.

Case Presentation

An 86-year-old Japanese male with a history of prostate cancer and cerebral infarction presented to our urology outpatient clinic. He was taking an oral anticoagulant (100 mg of cilostazol) once a day. He received external beam radiation therapy (EBRT) by means of a 4-field technique. A cumulative dose of 60 Gy in 30 fractions was delivered over a period of 5 weeks. There was no neoadjuvant and adjuvant maximum androgen blockade or chemotherapy (prostate specific antigen 8.7, Gleason score 4 + 4, cT2a) in 2001. Neither recurrence

Takeo Kosaka, MD, PhD
Department of Urology, Keio University School of Medicine
35 Shinanomachi
Shinjuku-ku, Tokyo 160-8582 (Japan)
E-Mail takemduro@gmail.com

nor metastasis was detected in the following 11-year period. In the follow-up period, his PSA level was about 0.10 ng/dl.

The patient presented to a local outpatient clinic with the chief complaint of intermittent gross hematuria that had lasted for 2 months. Bladder irrigation was performed, and his urine became clear. However, 5 days later, he presented to our hospital complaining of gross hematuria and clot retention.

He did not have lower urinary tract symptoms, fever, nausea, chills, flank pain, or weight loss. However, lower abdominal distention was noted at this time. On physical examination, his eyes were anemic, but otherwise, the examination was unremarkable. Laboratory data showed marked anemia with a hemoglobin level of 7.1 mg/dl. Other data, including liver function tests and coagulation studies, were within normal limits. Abdominal ultrasonography showed clots in the bladder. He was immediately admitted to our hospital and taken off cilostazol. After insertion of a transurethral catheter, bladder irrigation was performed to remove the clots. Continuous bladder irrigation was then started, and 4 units of component blood transfusion were administered. The findings suggested the presence of bladder cancer and radiation cystitis or stone-related disease as a differential diagnosis. Cystoscopic examination was performed to determine the cause of the hematuria and revealed irregularity of the mucosa on the posterior wall and a papillary tumor with active bleeding on the left side of the posterior wall. MRI revealed non-muscle invasive bladder cancer (fig. 1).

We performed transurethral resection of the bladder tumor (TURBT). A nodular tumor was found on the posterior wall (fig. 2). The trigon, neck and two lesions in the posterior wall were reddish, which was compatible with radiation-induced cystitis. Bilateral orifices were not involved and had clear efflux of urine. There were no other notable lesions. The tumor along the posterior wall and the reddish lesion were resected and coagulated. Urine cytology was negative for bladder cancer before and after TURBT. Pathological diagnosis revealed urothelial carcinoma, G2, pTa (fig. 3).

After TURBT, the patient's gross hematuria resolved. The Foley catheter was removed on postoperative day 6. The patient was discharged and cilostazol administration was resumed. He is still being followed-up and there has been no recurrence of the hematuria or bladder cancer in the 12 months since TURBT.

Discussion

Hematuria that is not explained by an obvious underlying condition is fairly common. In such patients, particularly young adult patients, the hematuria is transient and of no consequence. On the other hand, there is an appreciable risk of malignancy in older patients with hematuria, even if it is only transient. The presence of gross hematuria suggests bladder cancer, a urinary tract infection or urinary stones.

One retrospective study of 1,804 patients with macroscopic hematuria who visited an urology outpatient clinic revealed that urological cancer was found in 21.4% of the patients, of whom 18.4% had bladder cancer. Cystitis and urinary tract infection were found in 2.0% of those patients [1].

Another retrospective study using the records of 11 patients with new-onset urothelial carcinoma who underwent EBRT reported that macroscopic hematuria was present in all 11 cases [2].

The incidence of bladder cancer after radiation therapy for prostate cancer has been reported to be 1–3%. One previous report in patients with prostate cancer treated with

radiation showed a 2-fold increased risk of bladder cancer development in addition to prostate cancer treated with radical prostatectomy, suggesting an increased risk of bladder cancer after radiation for prostate cancer. The latency period to bladder cancer development in relation to completion of radiation varied from 6 months to 7 years in a previous report [3]. Previous studies on secondary bladder cancer risk after radiation therapy for prostate cancer are summarized in table 1. Previous studies showed an increased risk for secondary cancer after radiation therapy for prostate cancer [3–7]. Boorjian et al. [4] analyzed the incidence of bladder cancer after various prostate cancer treatments from the CaPSURE database. The risk for secondary bladder cancer in the surgery group was approximately half that of the radiotherapy patients (HR 2.0). Moon et al. [5] reported an elevated risk for secondary bladder cancer after radiotherapy for prostate cancer and evaluated all secondary cancer sites. According to their findings, overall secondary cancer risk was increased in the patients who received EBRT as their only form of radiation therapy. On the other hand, the bladder was the only organ showing a trend of increased risk of secondary cancer after brachytherapy [5]. Liauw et al. [6] compared brachytherapy and EBRT in a study population that included 125 patients treated with seeds only and EBRT. All 11 bladder cancers occurred in the combination group, suggesting a role for EBRT in increasing the risk of secondary cancers. Huang et al. [7] compared patients treated with radiotherapy and surgery and reported that the risk of secondary malignancies became significant >5 and >10 years after radiotherapy (HR 1.86 and 4.94, respectively). Histology in these cases shows an undifferentiated malignant tumor, which does not resemble prostate adenocarcinoma. Radiation has been shown to be associated with the in vitro progression of low-grade urothelial tumors to high-grade tumors and a high rate of p38 and mitogen-activated protein kinase accumulation [8].

On the other hand, a previous study by a group from the Mayo clinic showed that the risk of secondary cancer after radiation therapy for prostate cancer was not elevated. They included adjuvant radiotherapy in the analyses of secondary bladder cancer risk after prostate cancer treatment. The overall bladder cancer risk was not increased after radiation therapy. The authors speculated that the radiation dose received by the urinary bladder might differ in the adjuvant setting as compared to primary radiotherapy [3].

Increased secondary cancer risk after radiation therapy is still controversial. However, these studies suggest that general practitioners should be more aware of the risk of secondary cancer after radiation therapy for prostate cancer.

For the differential diagnosis of macroscopic hematuria, radiation cystitis should also be considered. Acute or chronic radiation cystitis occurs either during or after radiation treatment. Symptoms of radiation cystitis include lower urinary tract symptoms, increased urinary frequency and urgency, and hematuria. Late radiation cystitis following radiation therapy for prostate cancer has an incidence of 18% [9]. Late radiation cystitis can develop at least 6 months to as long as 20 years after radiation treatment, with the mean latent period being 35 months [10]. The evidence base is currently limited for the various treatment methods used to prevent and/or treat radiation cystitis. Hyperbaric oxygen therapy and sodium hyaluronate are the best available evidence. Severe manifestations of the condition can result in the need for a surgical procedure, e.g. urinary diversion, with or without cystectomy [11]. Therefore, to rule out bladder cancer, cystoscopy is recommended.

Radiation for prostate cancer can be currently applied by a variety of modalities and it enables targeting of the prostate only with high doses of radiation. One study based on data from the Surveillance Epidemiology and End Results (SEER) trial shows that the risk of secondary primary cancer was lowest in the group that underwent brachytherapy and

greatest in the group that underwent EBRT [12]. These results suggest a different ratio for the late onset of secondary tumors in relation to radiation therapies.

It is sometimes too difficult to differentiate secondary bladder cancer from radiation cystitis. The first reason is that the incidence of secondary bladder cancer is much lower than that of radiation cystitis (18 and 1–3%, respectively) [8]. The second reason is the limited sensitivity of urine cytology, US and CT for bladder cancer, which is 40–60, 47 and 55%, respectively [13]. The sensitivity and specificity of these examinations are limited. However, we cannot perform cystoscopy at the initial visit due to gross hematuria even though it is effective for detecting bladder tumors. Moreover, physicians sometimes have to ask an urologist to perform cystoscopy after gross hematuria has improved.

In conclusion, patients with macroscopic hematuria who had undergone radiation therapy may have radiation cystitis and/or bladder cancer. Therefore, it is recommended that urologists be consulted when treating these patients.

References

- Mishriki SF, Vint R, Somani BK: Half of visible and half of recurrent visible hematuria cases have underlying pathology: prospective large cohort study with long-term follow-up. *J Urol* 2012;187:1561–1565.
- Shah SK, Lui PD, Baldwin DD, Ruckle HC: Urothelial carcinoma after external beam radiation therapy for prostate cancer. *J Urol* 2006;175:2063–2066.
- Chrouser K, Leibovich B, Bergstralh E, Zincke H, Blute M: Bladder cancer risk following primary and adjuvant external beam radiation for prostate cancer. *J Urol* 2005;174:107–110; discussion 110–101.
- Boorjian S, Cowan JE, Konety BR: Bladder cancer incidence and risk factors in men with prostate cancer: results from Cancer of the Prostate Strategic Urologic Research Endeavor. *J Urol* 2007;177:883–887; discussion 887–888.
- Moon K, Stukenborg GJ, Keim J, Theodorescu D: Cancer incidence after localized therapy for prostate cancer. *Cancer* 2006;107:991–998.
- Liauw SL, Sylvester JE, Morris CG, Blasko JC: Second malignancies after prostate brachytherapy: incidence of bladder and colorectal cancers in patients with 15 years of potential follow-up. *Int J Radiat Oncol Biol Phys* 2006;66:669–673.
- Huang J, Kestin LL, Ye H, Wallace M, Martinez AA, Vicini FA: Analysis of second malignancies after modern radiotherapy versus prostatectomy for localized prostate cancer. *Radiother Oncol* 2011;98:81–86.
- Romanenko A, Morimura K, et al: Urinary bladder lesions induced by persistent chronic low-dose ionizing radiation. *Cancer Sci* 2003;94:328–333.
- Smit SG, Heyns CF: Management of radiation cystitis. *Nat Rev Urol* 2010;7:206–214.
- Levenback C, Eifel PJ, Burke TW, Morris M, Gershenson DM: Hemorrhagic cystitis following radiotherapy for stage Ib cancer of the cervix. *Gynecol Oncol* 1994;55:206–210.
- Heather P, Andrew A, Amit B, et al: Chemical- and radiation-induced haemorrhagic cystitis: current treatments and challenges. *BJU Int* 2013;112:885–897.
- Abdel-Wahab M, Reis IM, Hamilton K: Second primary cancer after radiotherapy for prostate cancer – a seer analysis of brachytherapy versus external beam radiotherapy. *Int J Radiat Oncol Biol Phys* 2008;72:58–68.
- Tatsugami K, Kuroiwa K, Kamoto T: Evaluation of narrow-band imaging as a complementary method for the detection of bladder cancer. *J Endourol* 2010;24:1807–1811.

Table 1. Secondary bladder cancer risk after radiation therapy for prostate cancer

First author	No. of patients	Study design	Patients	Comparison	Mean duration of follow-up, years	HR of secondary bladder cancer	Summary of the results
Chrouser et al. [3]	1,743	retrospective cohort study	patients with bladder cancer who received EBRT for prostate cancer	adjuvant EBRT (+) group vs. adjuvant EBRT (-) group	7.1	n.s.	nonsignificant increase associated with adjuvant EBRT
Boorjian et al. [4]	9,780	retrospective cohort study	patients with prostate cancer plus bladder cancer	EBRT group vs. radical prostatectomy group	4.3	2.0	HR 2.0 for radiation group
Moon et al. [5]	29,529	retrospective cohort study	patients who received no prostate cancer-directed radiation and who received EBRT	radiation group vs. no radiation group	7.0	1.6	RR 1.60 for radiotherapy group
Liauw et al. [6]	348	retrospective cohort study	patients treated with brachytherapy alone and with brachytherapy and supplemental EBRT	adjuvant EBRT (+) group vs. adjuvant EBRT (-) group	11.4 vs. 10.2	2.3	all 11 bladder cancers occurred in the combination group
Huang et al. [7]	2,120	retrospective cohort study	patients treated with radiotherapy and with surgery	radiation therapy group vs. surgery group	7.2 vs. 9.7	4.9	HR 4.94 for patients 10 years after radiotherapy

HR = Hazard ratio; n.s. = not significant; RR = risk ratio.

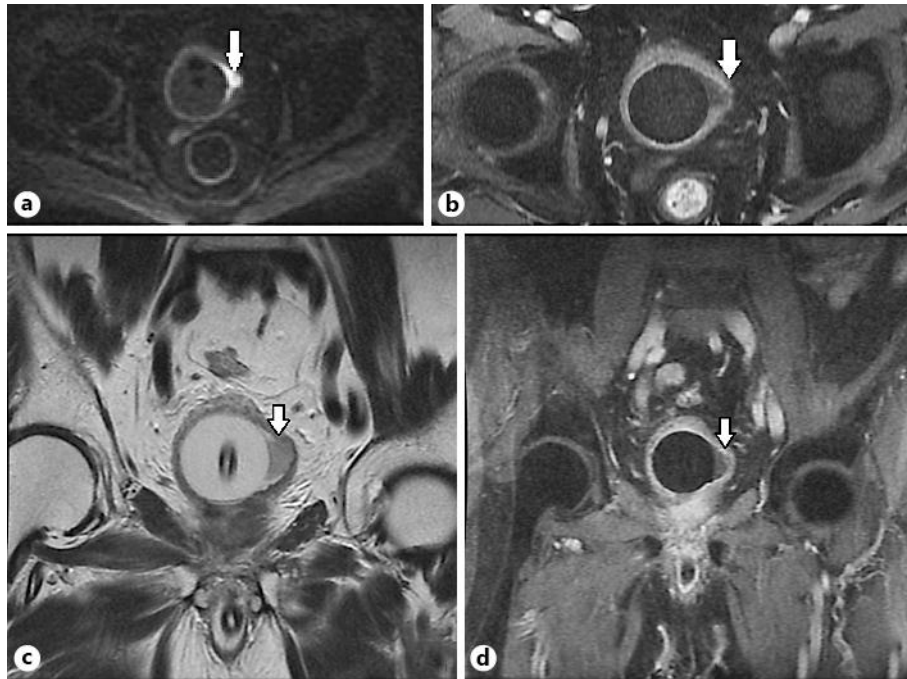


Fig. 1. MRI (diffusion weighted image) shows less signal attenuation with the size of 11 × 14 mm that was observed on the left wall (a). Gd dynamic study shows the thin bladder wall (b). Coronal view of T2 imaging (c). Coronal view of Gd dynamic study (d). Arrows indicate the tumor.

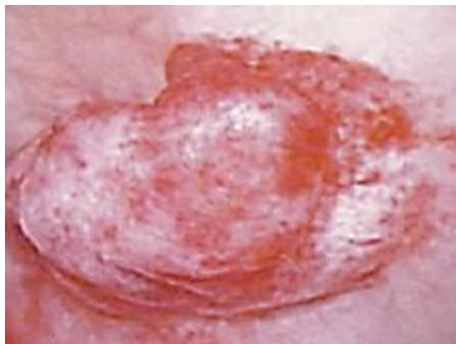

Fig. 2. Image obtained by cystoscopy.

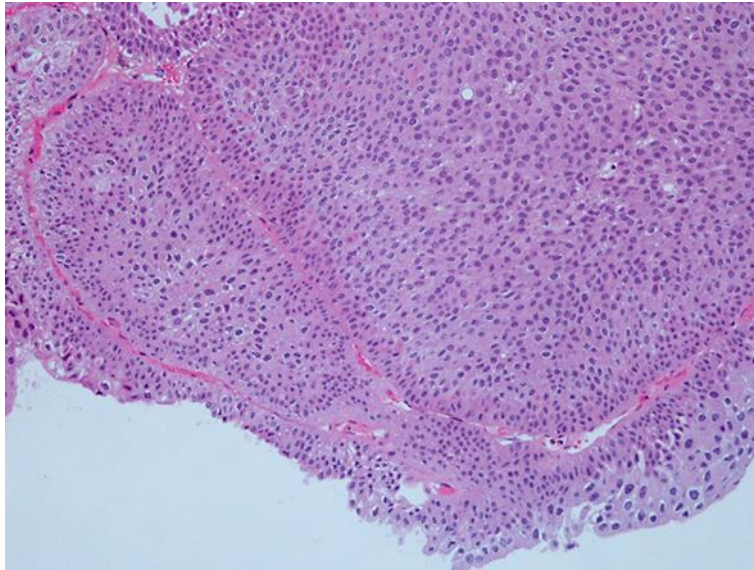


Fig. 3. Noninvasive urothelial carcinoma, G2 (HE stain, high-power view).