



# Multiple Primary Bilateral Cerebral Echinococcosis in an Adult: A Neurological Rarity

Manish Garg<sup>1</sup> Pragyan Sarma<sup>1</sup> Sujata Chaturvedi<sup>2</sup> Ishita Pant<sup>2</sup>

<sup>1</sup>Department of Neurosurgery, University College of Medical Sciences (UCMS) and Guru Teg Bahadur (GTB) Hospital, Delhi, India

<sup>2</sup>Department of Pathology, Institute of Human Behaviour and Allied Sciences, Delhi, India

Address for correspondence Pragyan Sarma, Mch, Associate Professor of Neurosurgery, UCMS and GTB Hospital, Delhi, 110096, India

(e-mail: pragyansarma@yahoo.com; pragyannimhans@gmail.com).

AJNS 2022;17:647–650.

## Abstract

Although cases of intracranial hydatid cysts are commonly encountered, majority of them are secondary and are seen in children. Primary bilateral multiple intracranial hydatid cysts in adults are a neurological rarity. Intracranial involvement usually occurs following infestation of the other organs in the body by the pathogen. Multiple lesions in brain can manifest either following rupture of a single parent cyst in brain or by systemic dissemination from other organs. Here, we are presenting an adult patient who underwent successful surgical removal of multiple primary hydatid cysts of brain. A 47-year-old male patient presented with features of raised intracranial pressure and other focal deficits. Magnetic resonance imaging showed multiple cystic lesions on both sides of the cerebrum. Similar primary lesions elsewhere in the body were ruled out by other investigations. He underwent successful surgical removal of all the lesions. Intraoperative picture and histology were suggestive of hydatid cyst. In published literature, there are very few cases similar to ours. *Echinococcosis* should be considered as a differential diagnosis in multiple cystic lesions of the brain in endemic areas. Early diagnosis, proper surgical technique, and standard antihelminthic drug regimen are the key to achieve good outcome in these patients.

## Keywords

- ▶ *echinococcosis*
- ▶ hydatid cyst
- ▶ MRI
- ▶ brain
- ▶ multiple

## Introduction

Multiple bilateral cerebral cystic *echinococcosis* is uncommon and often causes a diagnostic dilemma due to its rarity. It is caused by the larva of *Echinococcus* species and humans act only as intermediate hosts. They are infected either by food contaminated with eggs of the pathogen or via direct contact with dogs, the usual definitive host of the pathogen. *Echinococcus* infection is widely prevalent in Mediterranean, South American, Middle Eastern, Central Asia, East Africa countries, and Australia.<sup>1</sup> The reported incidence of primary *echinococcosis* of brain is 2%.<sup>2</sup> Brain is usually involved secondary to

infestation in other organs, commonly liver and lung. Multiple lesions can manifest either following rupture of a single parent cyst in brain or by systemic dissemination from another primary source of infection. Here, we are presenting a very rare case of multiple primary adult hydatid cysts of brain that underwent successful surgical excision.

## Case Report

A 47-year-old patient presented to emergency department with a history of intermittent headache along with occasional episodes of vomiting for 6 months. He also had

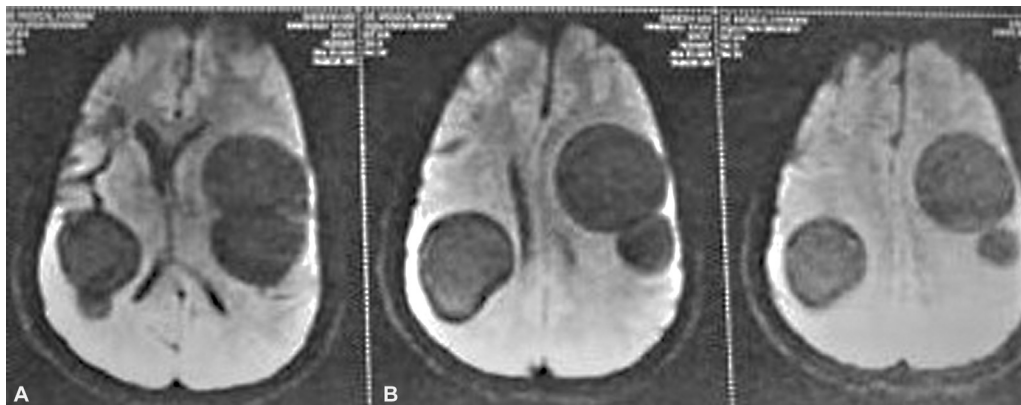
article published online  
October 18, 2022

DOI <https://doi.org/10.1055/s-0042-1757725>.  
ISSN 2248-9614.

© 2022. Asian Congress of Neurological Surgeons. All rights reserved.

This is an open access article published by Thieme under the terms of the Creative Commons Attribution-NonDerivative-NonCommercial-License, permitting copying and reproduction so long as the original work is given appropriate credit. Contents may not be used for commercial purposes, or adapted, remixed, transformed or built upon. (<https://creativecommons.org/licenses/by-nc-nd/4.0/>)

Thieme Medical and Scientific Publishers Pvt. Ltd., A-12, 2nd Floor, Sector 2, Noida-201301 UP, India



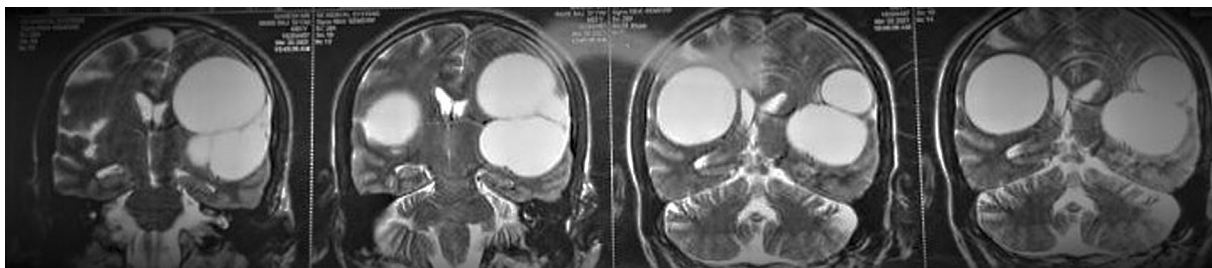
**Fig. 1** (A, B) Preoperative magnetic resonance imaging showing multiple cystic lesions on both sides of brain.

weakness of right half of body with decreased verbal output for the past 3 months. There was no history of any seizures. Glasgow Coma Scale at presentation was E3V(A)M6. Right hemiparesis and Broca's aphasia were present. Blood tests revealed mild leucocytosis with eosinophilia. Magnetic resonance imaging (MRI) brain showed multiple cystic lesions on both sides of midline. Cysts were of larger size on left side with significant compression over the brain parenchyma and midline shift to right (→ **Fig. 1A, B**). Lesions were hypo on T1-weighted (T1W) and hyperintense on T2W MRI. Contents of the cysts had cerebrospinal fluid (CSF) like signal intensity. Based on MRI findings, possibilities of hydatid cyst, multiple abscess, and cystic astrocytoma were considered. Abdominal ultrasound and chest computed tomographic were performed to rule out involvement of other organs and were found to be normal. With hydatid cyst as the most probable diagnosis in mind, Albendazole was started before surgery to neutralize protoscolices and continued in postoperative period. Patient was taken up for surgery. Since the sizes of the cysts were bigger on left side and mass effect too was more on the left, initially surgery was planned on that side. Patient was positioned supine and head was fixed with Mayfield clamp system with head rotated to right. Skin incision was placed and a left frontotemporoparietal craniotomy was done. All possible precautions to avoid rupture of the cysts were taken. The drill vibration was set at minimum required level for craniotomy as vibration of the drill itself can cause rupture of the superficial cysts. Particular care was also taken to avoid dural breach during craniotomy. Following craniotomy, dura mater was found to be stretched out by the underlying cysts. It was very challenging to open the dura

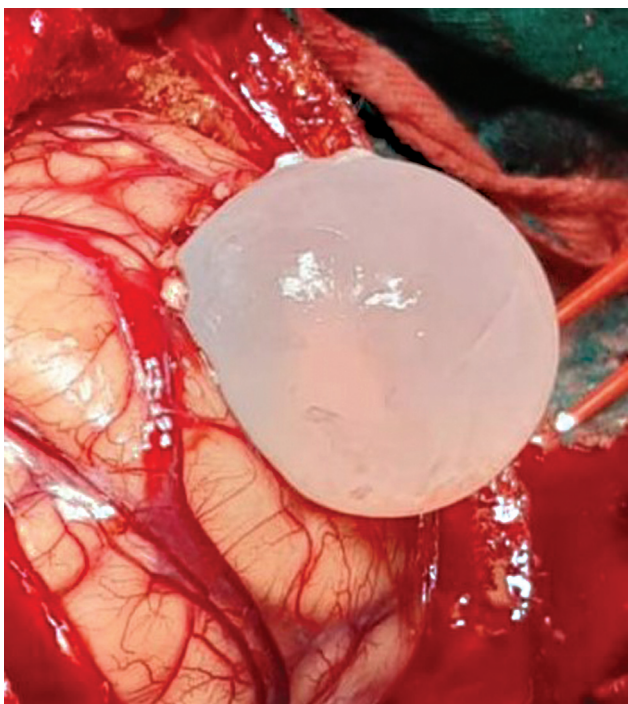
over the cysts without rupturing them. Therefore, dural incision was placed at an area where thinning was not apparent and dura was lifted carefully over the thinned part with copious irrigation of saline. Following durotomy, one of the cysts was surfacing. Careful dissection was performed with placement of wet cottonoids at the interface of cyst and cortex. Adhesiolysis all around the cyst were done and once the whole cyst was visualized, saline irrigation through the infant feeding tube was done for hydrodissection of the cysts (→ **Fig. 2**). On the left side, two large and three small cysts were dissected out. The operative cavity was washed with saline and closure was done in layers. After that the Mayfield three pin fixation system was rotated to the left and same steps were repeated on the opposite side. Following similar operative steps, two cysts were removed (→ **Fig. 3**). One of the cysts was buried in the cortex and hence cortical incision was placed to expose it before careful excision (→ **Fig. 4**). None of the cysts ruptured during surgery. Following surgery, patient showed significant improvement in raised intracranial pressure features. He was placed on a regimen of albendazole. The hemiparesis improved significantly but speech difficulty did not show any satisfactory improvement. Total duration of the surgery was 194 minutes. Histopathology was suggestive of *Echinococcus* (→ **Fig. 5**). The enzyme-linked immunosorbent assay for *Echinococcus granulosus* antibody was positive.

## Discussion

There are few published reports of primary cerebral *Echinococcus* in adults compared with other sites.<sup>3,4</sup> Moreover,



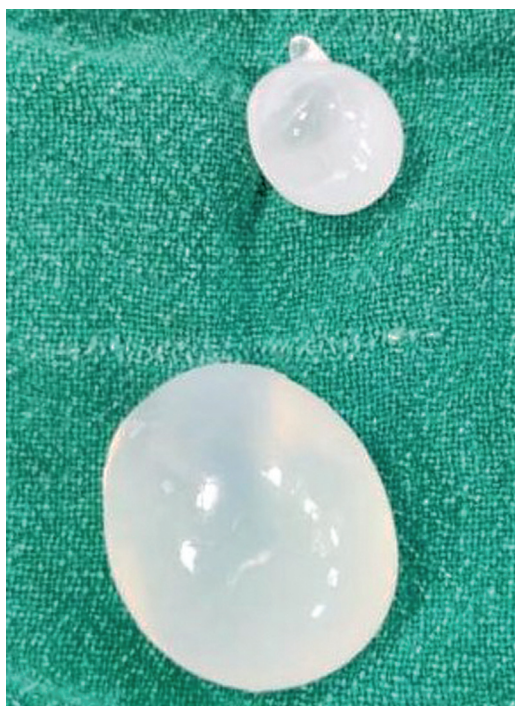**Fig. 2** Microphotograph showing the layers of the cyst wall with scolex (hematoxylin and eosin 100x).



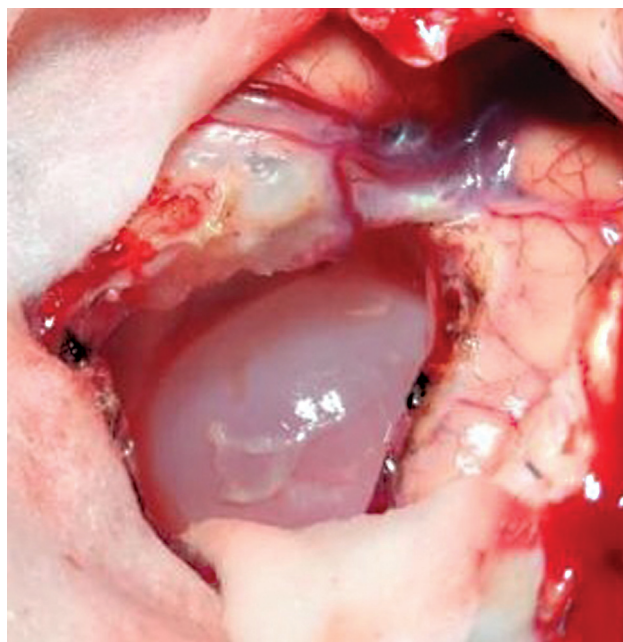
**Fig. 3** One of the cysts being delivered unruptured.

they are more commonly seen in children. Presence of a patent ductus arteriosus allowing blood to shunt from right to left bypassing the lungs may be a predisposing factor for it. Al Zain et al<sup>5</sup> proposed following ways by which multiple hydatid cysts in brain can be caused:

1. Multiple *echinococcal* eggs ingestion resulting in multiple individual primary lesions.



**Fig. 4** Multiple cysts following surgery.



**Fig. 5** One of the deep-seated cysts seen following corticotomy.

2. Rupture of a primary cyst.
3. Multiple cysts emanating from other organs like liver and lungs.

In addition, lung *echinococcosis* resulting in capillary invasion<sup>6</sup> and pre-existing left ventricular pathology in a patient of hydatid cyst<sup>6,7</sup> are already reported in literature as possible mechanisms for multiple *echinococcosis*.

In reported literature, there are no large series studying the management, complications, and outcome of surgery in multiple primary hydatid cysts of brain in adults. Most of them are case reports of single or few cases.<sup>3,4,8,9</sup> Svrckova et al in their report of three cases mentioned that such cases usually present with raised intracranial pressure or focal deficits but sometimes may present with unusual features like embolic stroke.<sup>4</sup> However, Ramosaço et al reported that these cases may be asymptomatic for a long duration with only vague symptoms and can suddenly deteriorate.<sup>9</sup> In our case too, the patient had symptoms for a long duration without focal deficits till the cysts attained very large sizes.

The differential diagnosis between primary and secondary cysts can be complicated at times but can be made by detailed examination of the cysts. In our case, there was presence of myriad of scolices along with capsule inside the cysts. Since there was no evidence of hydatid in other organs too, it can be categorically stated that it was a case of primary *echinococcosis*.

In all the reported cases of multiple hydatids of brain, the mainstay of treatment is antihelminthic therapy along with surgical removal of cysts. However, surgical removal may pose challenges in selected cases where the cysts are deep seated, located inside the ventricles or in presence of calcification<sup>8,9</sup> Svrckova et al in their case emphasized the need for prolonged follow-up and continuing antihelminthic therapy for a long duration in cases where incomplete excision of the



cysts was done.<sup>4</sup> Such cases are prone to relapse as was seen in one of their cases.<sup>4</sup> Compared with all these reported cases, our case had some unique characteristics. In none of the published cases, large cysts were located on both sides of the midline. Also, the serological studies confirmed the diagnosis as *E. granulosus* that unlike *E. multilocularis* is not prone to cause multiple cysts.

The surgical technique employed for cyst removal in our case was the Dowling technique,<sup>10</sup> which was subsequently modified by Arana-Iniguez and San Julian.<sup>11</sup> In our opinion, the key to successful outcome in such cases are wide exposure, copious hydro-dissection at the brain cyst interphase, and utilizing the effect of gravity while delivering cysts. However, sudden bursts of saline injection should be avoided. Meticulous hemostasis is also important as blood can be a hindrance to cyst separation from brain. In one of our cysts as already mentioned, corticectomy and meticulous adhesiolysis were required to expose the cyst. An alternate strategy in such scenarios that we feel can help is prior aspiration of the cyst contents followed by dissection of the cyst wall. Another challenging aspect in our case was the decompression of one side of the brain following removal of large cysts carried the risk of cortical collapse and subdural hematoma. Considering that cortical collapse has a high mortality rate,<sup>12</sup> staged approach in two sittings can also be done in such scenarios to be on the safer side.

Complications of surgical procedure are largely limited to rupture of the cyst during the surgery. Also, in intraventricular cysts, rupture can cause cyst contents to mix up with the CSF causing dissemination to other areas. Antihelminthic therapy is another important aspect to neutralize scolices before surgery and also to prevent future recurrence after surgery.

## Conclusion

Primary multiple bilateral cerebral hydatid cysts in an adult are very rare and our literature search showed very few such cases as already mentioned. This entity should be considered

in large cystic lesions of brain in people from endemic areas. Early detection is important as these lesions can increase to large sizes with minimal symptoms. Key to optimal outcome is meticulous surgical technique with proper regimen of antihelminthic drugs.

## Conflict of Interest

None declared.

## References

- Gabriele F, Bortoletti G, Conchedda M, Palmas C, Ecça AR. Epidemiology of hydatid disease in the Mediterranean basin with special reference to Italy. *Parassitologia* 1997;39(01):47–52
- Kovoor JM, Thomas RD, Chandrashekhhar HS, Jayakumar PN, Pillai S, Shankar SK. Neurohydatidosis. *Australas Radiol* 2007;51(05):406–411
- Cataltepe O, Tahta K, Colak A, Erben A. Primary multiple cerebral hydatid cysts. *Neurosurg Rev* 1991;14:231–234
- Svrckova P, Nabarro L, Chiodini PL, et al. *Pract Neurol* Epub ahead of print: [14th October 2018]. . Doi: 10.1136/practneurol-2018-001954
- Al Zain TJ, Al-Witry SH, Khalili HM, Aboud SH, Al Zain FT Jr. Multiple intracranial hydatidosis. *Acta Neurochir (Wien)* 2002; 144(11):1179–1185
- Griponissiotis B. Hydatid cyst of the brain and its treatment. *Neurology* 1957;7(11):789–792
- Darwazah AK, Zaghari M, Eida M, Batrawy M. Left ventricular endocardial echinococcosis associated with multiple intracranial hydatid cysts. *J Cardiothorac Surg* 2013;8:104
- Lakhdar F, Benzagmout M, Chakour K, el faiz Chaoui M. Multiple and infected cerebral hydatid cysts mimicking brain tumor: unusual presentation of hydatid cyst. *Interdiscip Neurosurg* 2020;22:100802 ISSN 2214–7519
- Ramosaço E, Kolovani E, Ranxha E, Vyshka G. Primary multiple cerebral hydatid cysts in an immunocompetent, low-risk patient. *IDCases* 2020;21:e00882
- Carrea R, Dowling E Jr, Guevara JA. Surgical treatment of hydatid cysts of the central nervous system in the pediatric age (Dowling's technique). *Childs Brain* 1975;1(01):4–21
- Arana-Iniguez R, San Julian J. Hydatid cysts of the brain. *J Neurosurg* 1955;12(04):323–335
- Tumer B, Yolas C, Konte H, et al. *Intrakranial kisthidaltikler. Atartuk Universitesi Tip Fakultesi Bulteni.* 1983;15:73–82