

Received: 2013.10.08
Accepted: 2013.11.05
Published: 2014.01.28

Amyand's hernia: A review

Authors' Contribution:
Study Design A
Data Collection B
Statistical Analysis C
Data Interpretation D
Manuscript Preparation E
Literature Search F
Funds Collection G

ABCDEF 1 **Galyna Ivashchuk**
ABCDEF 1 **Alper Cesmebasi**
ABCEF 1 **Edward P. Sorenson**
ABCDEF 1 **Christa Blaak**
ABCDEF 1,2 **Shane R. Tubbs**
ABCDEFG 1,3 **Marios Loukas**





1 Department of Anatomical Sciences, School of Medicine, St George's University, Grenada, West Indies
2 Children's Hospital, Pediatric Neurosurgery, Birmingham, AL, U.S.A.
3 Department of Anatomy, Varmia and Mazuria University, Medical School, Olsztyn, Poland

Corresponding Author: Marios Loukas, e-mail: mloukas@sgu.edu
Source of support: Self financing

Amyand's hernia is defined as when the appendix is trapped within an inguinal hernia. While the incidence of this type of hernia is rare, the appendix may become incarcerated within Amyand's hernia and lead to further complications such as strangulation and perforation. Incarceration of the appendix most commonly occurs within inguinal and femoral hernias, but may arise to a lesser extent in incisional and umbilical hernias. Incarcerated appendix has been reported in a variety of ventral abdominal and inguinal locations, yet its indistinct clinical presentation represents a diagnostic challenge. This paper reviews the literature on incarceration of the appendix within inguinal hernias and discusses current approaches to diagnosis and treatment of Amyand's hernia and complications that may arise from incarceration of the appendix within the hernia.

MeSH Keywords: **Appendicitis • incarceration • Hernia, Inguinal • Laparoscopy**

Full-text PDF: <http://www.medscimonit.com/download/index/idArt/889873>

 3022  —  3  51

Background

A hernia is the protrusion of an organ or its fascia through the wall of a containing cavity [1]. When an organ is contained within a non-reducible hernia, it is termed an incarcerated hernia. A strangulated hernia may result if the blood supply to the edematous, incarcerated bowel is compromised secondary to venous and lymphatic obstruction. Strangulated bowel is susceptible to necrosis, which can lead to perforation, rupture, and spillage of bowel contents, and eventually, a catastrophic peritonitis. Ventral abdominal and inguinal hernias typically contain bowel or omentum; only rarely is the appendix discovered, often incidentally, within the herniated region [1]. A thorough literature review indicates that only about 1% of all hernias contain portions of the appendix. Incarceration of the appendix within an inguinal hernia is termed Amyand's hernia (Figure 1). An Amyand's hernia may become inflamed, infected, or perforated. The appendix may also be incarcerated and entirely healthy [2–4]. Definitive preoperative diagnosis presents a clinical challenge due to indistinct clinical signs and symptoms and a lack of clear radiological diagnostic features. Incarcerated appendix or appendicitis, for example, is often misdiagnosed as a strangulated hernia [5]. Diagnosis of Amyand's hernia remains primarily an incidental finding during surgery, and there remains no true consensus on the optimal operative management approach. Surgeons and residents need to become familiar with incarcerated appendixes within hernias, and the scant literature makes it a rather time-consuming process for physicians to educate themselves on Amyand's hernia and incarcerated appendixes. Thus, it is the aim of this paper to review the literature with regards to Amyand's hernia and provide new insight in the diagnosis and treatment of Amyand's hernia and its complications.

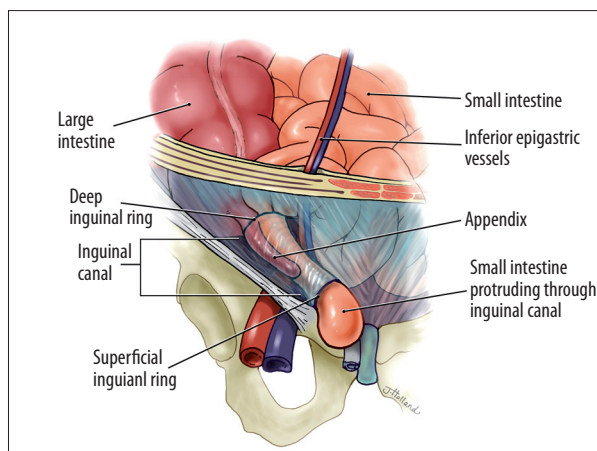


Figure 1. This illustration depicts an Amyand's hernia. The appendix is shown within an indirect inguinal hernia, passing through both the deep and superficial inguinal rings and passing lateral to the inferior epigastric vessels.

History

Amyand's hernia is named after Claudius Amyand, who, on December 6, 1735, performed the first successful appendectomy during the treatment of an 11-year-old boy who presented with a right inguinal hernia. During the surgery, Amyand found a pin within the appendix, which was encrusted with stone; the appendix was found within the inguinal hernia sac [6]. The term Amyand's hernia therefore refers to an incarcerated hernia containing appendix, which may be normal or inflamed [1]. Because of the rarity of the condition, the term "Amyand's hernia" been recently adopted as an eponymous description of an incarcerated appendix within an inguinal hernia [7].

Epidemiology

Amyand's hernia has been reported in patients ranging in age from 3 weeks to 92 years [4,8]. The incidence of Amyand's hernia has varied in the literature, ranging from 0.19% to 1.7% of reported hernia cases. Amyand's hernia is 3 times more likely to be diagnosed in children than in adults, due to the patency of the processus vaginalis in the pediatric population [9].

The incidence of appendicitis within an inguinal hernia is even rarer; with an estimated rate at 0.07–0.13% [10]. The incidence of perforated appendix incarcerated within an inguinal hernia is rare as well, at 0.1% of all cases of appendicitis [11,12]. A 2003 study by D'Alia et al. examined 1341 inguinal hernias and determined the incidence of Amyand's hernia to be 0.6%, always on the right side, and exclusively in males [4]. Sharma et al. reported that, according to their study and that of Ofili et al., when cases of hernial appendicitis were found in females, they tended to be found in postmenopausal women [10].

Mortality of Amyand's hernia has been reported to range from 14–30% and was linked to peritoneal spread of sepsis [4]. Sharma et al. reported a postoperative wound infection rate of only 5.5% following their surgeries [10]. However, they reported discovering infection rates as high as 50% in the literature [10]. They also reported a mortality rate of only 5.5%, in comparison to the 14–30% range noted in the literature. They attributed this to early appropriate treatment and good postoperative care [10].

Clinical Presentation

An appendix incarcerated within an inguinal hernia may become inflamed, infected, or perforated. Although incarcerated, the appendix may also present as being entirely healthy [2,4]. Inguinal herniations are found superior to the inguinal ligament, and superolateral to the pubic tubercle. They may

be either direct or indirect. Direct inguinal hernias are found anteromedial and inferior to the inferior epigastric vessels; whereas indirect hernias protrude posterolateral and superior to the vessels [13]. The appendix may be found in either of these as an Amyand's hernia.

Preoperative diagnosis of Amyand's hernia is not straightforward, and is generally an incidental finding during surgery [1,10,14,15]. Abdominal exam, physical signs, lab results, and imaging are not always helpful in differential diagnosis [14,16]. Common complaints include sudden-onset epigastric or periumbilical pain with localized tenderness in the right lower quadrant, combined with a tender irreducible mass in the inguinal or inguino-scrotal region [10,17]. This presentation however, often gives the clinical impression of a strangulated hernia, making clinical diagnosis of Amyand's hernia difficult [10,15].

Although incarceration of the appendix within an inguinal hernia does not always lead to appendicitis, this is not an uncommon finding. Ash et al. suggested a relationship between incarceration of the appendix in the inguinal canal and the development of inflammation [18]. They provided an account of appendiceal migration into the inguinal canal, leading to increased vulnerability to trauma and compromised blood supply, followed by generalized inflammation and bacterial overgrowth.

Various complications of Amyand's hernia have been reported in the literature. Lyass et al. described abdominal abscess secondary to a perforated appendix in an inguinal hernia [15]. Kueper et al. reported Amyand's hernia containing a perforated appendix and complicated with periappendicular abscess [19]. Serrano and Ackerman reported an incarcerated right inguinal hernia that contained a perforated appendix along with an inflamed right testicle and spermatic cord; all of which had to be removed [20]. Amyand's hernia with perforated appendix can present with testicular ischemia in neonates as well [21]. Strangulated Amyand's hernia has been reported with hyperemia and hemorrhagic infiltration within the hernial sac [22]. Franko et al. reported a variation in which the appendix had protruded through the internal inguinal ring, but remained outside the hernia sac [23]. A severe complication, first reported by Marron et al., is necrotizing fasciitis of the anterior abdominal wall secondary to bowel perforation [24]. A particularly dire case was reported by Osorio et al., in which a 91-year-old woman presented with Amyand's hernia complicated by necrotizing fasciitis of the inguinal region, and additional ipsilateral Richter's hernia [25]. Although not reported in the literature, the perforation of an inflamed appendix within the hernia may lead to thrombotic complications such as seen in a case reported by Wilson et al. in 2012, in which an intra-abdominal abscess resulted in the formation of an *in situ* arterial thrombosis [26]. An extremely rare presentation of a foreign body etiology of appendicitis has been reported roughly

once per century. In addition to the initial report by Amyand, a second report of a pin causing appendicitis after being swallowed by a child was reported by Lullaku et al. in 2010 [27]. Amyand's hernia can also present with appendiceal adenocarcinoid tumor [28].

Although less common, incarcerated appendix may appear within a left-sided inguinal hernia. To date, 7 such patients with left-sided Amyand's hernia been described in the English literature in both males and females, ranging in age from 9 months to 81 years [29–33]. Although the location is atypical, the potentially serious sequelae of a missed diagnosis of incarcerated appendix warrant its inclusion on the list of differentials when a patient presents with left-sided inguinal pain [29]. Similar to the right-sided presentation of Amyand's hernia, those which arise on the left side are very difficult to distinguish from incarcerated or strangulated hernia preoperatively. Khan et al. reported a case in which a 10-month-old infant was diagnosed with left testicular torsion, but was found to have a perforated appendix incarcerated within a left inguinal hernia [32].

The unusual left-sided presentation may be associated with situs inversus, intestinal malrotation, or with a mobile cecum [34]. In these instances, appendectomy is performed if the base of the cecum is accessible through the hernial sac; if it is not, surgeons may opt to perform an open appendectomy through a low-midline laparotomy incision. Johari et al. suggested performing an appendectomy in cases of left sided Amyand's hernia, even if the appendix is normal, since potential appendicitis in the future would have an atypical presentation, which may delay its diagnosis [31].

Preoperative Diagnosis

Cases of definitive preoperative diagnosis are rare, and diagnosis is generally made during surgery [1,10,14,15,35]. Abdominal exam, physical signs, lab results, and imaging are not always helpful in differential diagnosis [14,16,35].

Computed tomography (CT) is the most commonly used imaging modality for evaluation of acute abdomen and abdominal hernias [13]. However, inguinal hernias are typically diagnosed clinically. The lack of distinct presenting signs and symptoms in Amyand's hernia, even when complicated, means that imaging is commonly not ordered if a simpler diagnosis is made clinically. When imaging is ordered, it is often for the purpose of ruling out a more serious pathology.

The first case we found of a successful preoperative diagnosis of Amyand's hernia using CT was by Vermillion et al., in which they had ordered an abdomino-pelvic CT scan to rule out bowel

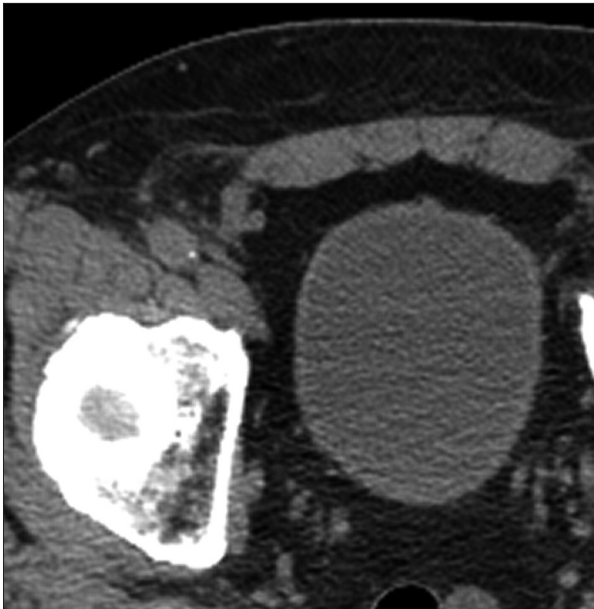

Figure 2. Amyand hernia. CT image shows the appendix within an Amyand's hernia. The indirect hernia originates superolateral to the course of the inferior epigastric artery. Reproduced from Burkhardt et al. [13] with permission from Radiographics. Copyright 2011.

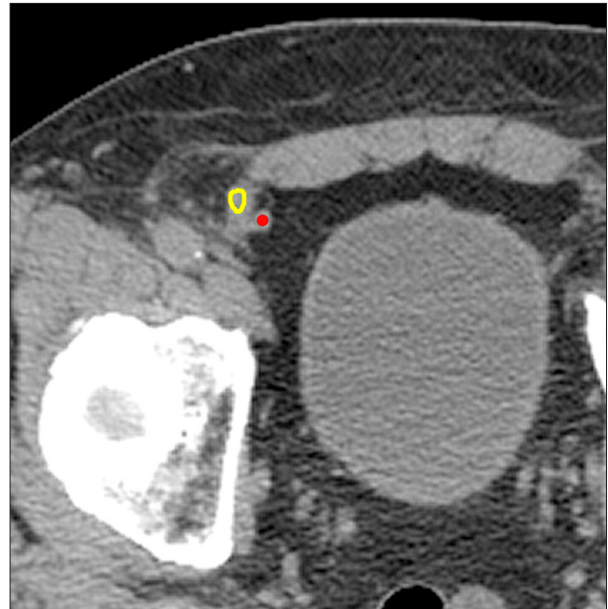


Figure 3. Amyand hernia. Color-coded CT image shows the appendix (yellow) within an Amyand's hernia. The indirect hernia originates superolateral to the course of the inferior epigastric artery (red). Reproduced from Burkhardt et al. [13] with permission from Radiographics. Copyright 2011.

incarceration or strangulation. In the report, they were able to visualize an inflamed appendix within the right inguinal canal [17]. Ash et al. reported a similar case, in which they successfully diagnosed the pathology by a CT that had been ordered to rule out a strangulated omentocele [18].

Successful preoperative diagnosis has increased recently in the literature [34], particularly studies emphasizing the value of sagittal-cut CT [35]. However, axial CT images are typically examined first, prior to sagittal-cut images. Burkhardt et al. therefore reported some helpful diagnostic signs to distinguish indirect and direct inguinal hernias on axial CT imaging [13]. They proposed a lateral crescent sign to assist with diagnosis of early direct inguinal hernias. This sign is indicative of fat within the inguinal canal being pushed into a semicircle of tissue by the encroaching hernia, but indirect inguinal hernias will not produce such a lateral crescent of fatty tissue and may be more difficult to identify [13]. The report by Burkhardt et al. demonstrated useful images of how Amyand's hernia may appear on CT (Figure 2) and clarified the structures using color-coded highlighting (Figure 3) [13].

Although CT scanning may be helpful in reaching a correct diagnosis, it is usually not part of the standard diagnostic work-up when simple inguinal hernia is suspected [31]. Sonography has been reported to be valuable in the preoperative diagnosis of Amyand's hernia [37,38]. Coulier et al. presented the first known case of Amyand's hernia successfully diagnosed using

sonography [37]. They confirmed the diagnosis using CT, which was also performed to rule out potential intra-abdominal complications. Sonography could be a useful imaging modality for Amyand's hernia, as it is often a cheaper and safer option, and positive findings can be confirmed using CT if necessary [37]. However, preoperative diagnosis based on ultrasound alone is heavily dependent upon the technical skill of the operator, and as such remains a relatively unreliable modality [39].

Tycast et al. proposed the use of laparoscopic surgery as not only therapeutic, but as a diagnostic tool as well [41]. In their case report of a 12-year-old male with Amyand's hernia involving appendicitis, laparoscopic surgery allowed for visualization of the entire abdomen, a decrease in post-operative pain, and earlier discharge. This conclusion is supported by Baldassarre et al. who argued that the difficulty in obtaining imaging in emergency situations overwhelms its diagnostic value [44]. They supported the use of laparoscopic surgery, both diagnostically and therapeutically, for those patients in which diagnosis of Amyand's hernia was unclear.

Surgical Approach

Incision

The most common choice of treatment for Amyand's hernia is appendectomy via herniotomy, with primary hernia repair

[15,18,35]. Lower midline laparotomy is recommended for cases of suspected perforation or pelvic abscess, as this approach provides excellent control and technical ease [10,42]. Solecki et al. recommended midline inferior laparotomy, and Shouldice's herniorrhaphy in cases of gangrenous acute appendicitis in Amyand's hernia [42].

Recently, more varied methods have begun to appear in the literature. Vermillion et al. reported the first instance of laparoscopic appendectomy in a case of Amyand's hernia with appendicitis [17]. Reports now indicate that the incidence of laparoscopic surgery is on the rise [38,41,43,45]. However, discovery of complications may necessitate a transition from laparoscopic to open hernia repair. Salemis et al. reported a case in which a laparoscopic approach on an indirect inguinal hernia repair revealed a gangrenous perforated appendix with peritonitis, necessitating a midline laparotomy [40].

More recently, extraperitoneal management of Amyand's hernia has become more common [16]. Saggar et al. reported total extraperitoneal management, including appendectomy and hernioplasty using synthetic mesh [46]. Burgess et al. reported that the surgical approach should be guided by suspected diagnosis, such as laparotomy for suspected bowel obstruction or appendicitis, and anterior groin incision for suspected incarcerated inguinal hernia [36]. This may seem intuitive, yet techniques vary because preoperative diagnosis still remains a challenge.

State of the appendix

There is no consensus in the literature regarding the best course of action in treating an appendix in Amyand's hernia. Acute appendicitis is the most frequent cause of acute right iliac fossa pain. However, such pain does not necessitate presence of an inflamed appendix [39]. This often leaves an intraoperative decision of whether or not to remove the appendix. While some argue for appendectomy only if the appendix is inflamed [34,36,39], others support appendectomy even when the appendix is non-inflamed, in an effort to avoid future complications [34,36,39,47]. A potential pathophysiological process was proposed by Ofili et al., who suggested that mere manipulation of a healthy appendix during surgery may incite inflammation and may provoke secondary appendicitis [47]. However, studies have shown that current laparoscopic procedures involving manipulation of the appendix do not increase the incidence of appendicitis [10].

Hutchinson argued that appendectomy of a healthy appendix is not necessarily beneficial, and may actually be detrimental; transection of a fecal-containing organ in an otherwise clean procedure may increase morbidity and mortality from septic complications [14]. However, he argued both sides and

concluded that the decision to remove the appendix or not will most likely remain the surgeon's personal choice [14]. Baldassarre et al. recommended leaving the appendix if it is not inflamed, since removal of appendiceal lymphoid tissue may compromise the immune development of pediatric patients [9]. The appendix may also be useful in the future for urinary diversion, antegrade bowel enemas, or biliary tract reconstruction.

Ali et al. reported performing appendectomies in all of their patients, regardless of the status of the appendix, but recommended that decisions should be made on a case-by-case basis [1]. In some instances the differentiation between normal and inflamed appendix is done solely through intraoperative palpation by the surgeon.

Milanchi et al. recommended mesh hernia repair without appendectomy if the appendix is normal, and laparoscopic appendectomy followed by open hernia repair in cases of appendicitis [48]. Use of mesh repair is contraindicated in cases of an inflamed or perforated appendix, as this increases the risk of septic complications [10,30]. Saggar et al. recommended thorough wound drainage and an antibiotic course of second generation cephalosporin and metronidazole for a minimum of 5 days following laparoscopic surgery with prosthetic mesh hernia repair [46].

Repair of hernia

Most often, hernia repair is completed during primary surgery. In a few cases, hernia repair is delayed due to complications and inflammation [15]. Hernia repair with prosthetic mesh has been shown to decrease the incidence of recurrence when compared to deficit reinforcement using native tissue, but there are contraindications for its use in some cases [36]. Because prosthetic mesh material can elicit an increased inflammatory response, it is generally contraindicated in the closure of contaminated abdominal wall defects [10,31]. Prosthetic mesh is typically contraindicated in patients with an inflamed or perforated appendix, due to the risk of wound and mesh infection [10]. The treatment of choice in these cases is appendectomy using Bassini's repair, along with thorough abdominal and pelvic washouts to reduce septic complications [10]. A lower midline laparotomy is an excellent choice when there are clear signs of peritonitis but diagnosis is in doubt [10].

In contrast, Chatzimavroudis et al. reported that synthetic mesh may be used successfully in cases of Amyand's hernia, even when inflamed or perforated, with no post-operative complications, and that a septic environment is not an absolute contraindication for use of prosthetic mesh [50]. Torino et al. supported the use of synthetic mesh if the inguinal area is adequately irrigated with antibiotics intraoperatively; a drain is

placed under the aponeurosis, and the procedure is followed by a post-operative course of antibiotics [49].

Losanoff et al. proposed a classification of Amyand's hernia to improve treatment. Type I is a normal appendix: perform reduction or appendectomy with mesh hernioplasty [51]. Type II is acute appendicitis localized in a hernial sac: perform appendectomy through hernia, with mesh hernia repair; associated with higher risk of mesh infection. Type III is acute appendicitis complicated by peritonitis: perform appendectomy through laparotomy; hernioplasty decision should be made based upon the spread of sepsis. Type IV is acute appendicitis accompanied by other abnormal pathology: hernioplasty may be contraindicated if damage is too extensive.

Conclusions

Amyand's hernia is a rare presentation of inguinal hernia, in which the appendix is incarcerated within the hernia sac. Amyand's hernia is a diagnostic challenge due to its

low incidence, indistinct clinical presentation, and ambiguous appearance on imaging such as CT. Surgery is therefore frequently diagnostic as well as therapeutic. Since the appendix may be non-inflamed when found within the inguinal hernia sac, removal is not always necessary; this is a decision currently dictated primarily by the surgeon's preference. Due to the rarity of Amyand's hernia, and the wide variance of its presentation, each case study and review article brings new and useful information to light regarding its treatment and diagnosis.

Conflict of interest

Authors declares no conflict of interest.

Acknowledgments

The authors wish to thank Jessica Holland, MS, Medical Illustrator in the Department of Anatomical Sciences, St Georges University, Grenada, West Indies, for the creation of her illustrations used in this publication.

References:

1. Ali SM, Malik KA, Al-Qadhi H: Amyand's hernia: study of four cases and literature review. *SQU Medical Journal*, 2012; 12: 232–36
2. House MG, Goldin SB, Chen H: Perforated Amyand's hernia. *South Med J*, 2001; 94: 496–98
3. Logan MT, Nottingham JM: Amyand's hernia: a case report of an incarcerated and perforated appendix within an inguinal hernia and review of the literature. *Am Surg*, 2001; 67: 628–29
4. D'Alia C, Lo Schiavo MG, Tonante A et al: Amyand's hernia: case report and review of the literature. *Hernia*, 2003; 7: 89–91
5. Thomas WEG, Vowles KDJ, Williamson RCN: Appendicitis in external hernia. *Ann R Coll Surg Engl*, 1982; 64: 121–22
6. Amyand C: Of an inguinal rupture, with a pin in the appendix caeci, incrusted with stone; and some observations on wounds in the guts. *Phil Trans R Soc Lond*, 1793; 39: 329
7. Hiatt JR, Hiatt N: Amyand's hernia [Letter to the Editor]. *N Engl J Med*, 1988; 318: 1402
8. Anagnostopoulou S, Dimitroulis D, Troupis TG: Amyand's hernia: A case report. *World J Gastroenterol*, 2006; 12: 4761–63
9. Baldassarre E, Centozza A, Mazzei A et al: Amyand's hernia in premature twins. *Hernia*, 2009; 13: 229–30
10. Sharma H, Gupta A, Shekhawat NS: Amyand's hernia: a report of 18 consecutive patients over a 15-year period. *Hernia*, 2007; 11: 31–35
11. Hauser U, Merkle P: Differential diagnosis of incarcerated inguinal hernias in infancy. Acute appendicitis in the hernial sac. *Z Kinderchir*, 1984; 39: 72–73
12. Pelligrino JM, Feldman SD: Case report: Acute appendicitis in an inguinal hernia. *N J Med*, 1992; 89: 225–26
13. Burkhardt JH, Arshanskiy Y, Munson JL et al: Diagnosis of inguinal region hernias with axial CT: the lateral crescent sign and other key findings. *Radiographics*, 2011; 31: E1–12
14. Hutchinson R: Amyand's hernia. *J R Soc Med*, 1993; 86: 104–5
15. Lyass S, Kim A, Bauer J: Perforated appendicitis within an inguinal hernia: Case report and review of the literature. *Am J Gastroenterol*, 1997; 92: 700–2
16. Sarker SK, Jackson K: Laparoscopic extraperitoneal repair of Amyand's inguinal hernia. *JLS*, 2006; 10: 528–30
17. Vermillion JM, Abernathy SW, Snyder SK: Laparoscopic reduction of Amyand's hernia. *Hernia*, 1999; 3: 159–60
18. Ash L, Hatem S, Alberto G et al: Amyand's hernia: a case report of prospective CT diagnosis in the emergency department. *Emerg Radiol*, 2005; 11: 231–32
19. Kueper MA, Kirschniak A, Ladurner R: Incarcerated recurrent inguinal hernia with covered and perforated appendicitis and periappendicular abscess: case report and review of the literature. *Hernia*, 2007; 11: 189–91
20. Serrano A, Ackerman NB: Perforated appendix in an incarcerated inguinal hernia. *Arch Surg*, 1979; 114: 968
21. Milburn JA, Youngson GG: Amyand's hernia presenting as neonatal testicular ischaemia. *Pediatr Surg Int*, 2006; 22: 390–92
22. Ioannidis O, Styliani P, Kakoutis E et al: Strangulation of the vermiform appendix within a right inguinal hernia: A rare variation of Amyand's hernia [Letter to the Editor]. *Am Surg*, 2010; 76: 1305–6
23. Francko J, Raftopoulos J, Sulkowski R: A rare variation of Amyand's hernia. *Am J Gastroenterol*, 2002; 97: 2684–85
24. Marron CD, Khadim M, McKay D et al: Amyand's hernia causing necrotizing fasciitis of the anterior abdominal wall. *Hernia*, 2005; 9: 381–83
25. Osorio JK, Guzman-Valdivia GG: Ipsilateral Amyand's and Richter's hernia, complicated by necrotizing fasciitis. *Hernia*, 2006; 10: 443–46
26. Wilson TD, Rao V, Podbielski FJ, Blecha MJ: *In situ* aortic thrombosis secondary to intra-abdominal abscesses. *Am J Case Rep*, 2012; 13: 149–52
27. Lullaku SS, Hyseni NS, Kelmendi BZ et al: A pin in appendix within Amyand's hernia in a six-years-old boy: case report and review of literature. *World J Emerg Surg*, 2010; 5: 1–3
28. Wu CI, Yu CC: Amyand's hernia with adenocarcinoid tumor. *Hernia*, 2010; 14: 423–35
29. Breitenstein S, Eisenbach C, Wille G et al: Incarcerated vermiform appendix in a left-sided inguinal hernia. *Hernia*, 2005; 9: 100–2
30. Gupta S, Sharma R, Kaushik R: Left-sided Amyand's hernia. *Singapore Med J*, 2005; 46: 424–25
31. Johari HG, Paydar S, Zeraatian S et al: Left-sided Amyand hernia. *Ann Saudi Med*, 2009; 4: 321–22
32. Khan RA, Wahib S, Ghani I: Left-sided strangulated Amyand's hernia presenting as testicular torsion in an infant. *Hernia*, 2011; 15: 83–84

33. Singh K, Singh RR, Kuar S: Amyand's hernia. *J Indian Assoc of Pediatr Surg*, 2011; 16: 171-72
34. Cankorkmaz L, Ozer H, Guney C et al: Amyand's hernia in the children: a single center experience. *Surgery*, 2010; 147: 140-43
35. Inan I, Myers PO, Hagen ME et al: Amyand's hernia: 10 years' experience. *Surgeon*, 2009; 7: 198-202
36. Burgess P, Brockmeyer JR, Johnson EK: Amyand hernia repaired with Bio-A: a case report and review. *J Surg Educ*, 2001; 68: 62-66
37. Coulier B, Pacary J, Broze B: Sonographic diagnosis of appendicitis within a right inguinal hernia (Amyand's hernia). *J Clin Ultrasound*, 2006; 34: 454-57
38. Elias B, Chelala E, Alle JL: Transabdominal laparoscopic repair of Amyand's hernia: A case report. *Case Reports in Surgery*, 2011; 2011: 823936
39. Singal R, Mittal A, Gupta A et al: An incarcerated appendix: report of three cases and a review of the literature. *Hernia*, 2012; 16: 91-97
40. Salemis NS, Nisotakis K, Nazos K: Perforated appendix and periappendicular abscess within an inguinal hernia. *Hernia*, 2006; 10: 528-30
41. Tycast JF, Kumpf AL, Schwartz TL et al: Amyand's hernia: a case report describing laparoscopic repair in a pediatric patient. *J Pediatr Surg*, 2008; 43: 2112-14
42. Solecki R, Matyja A, Milanowski W: Amyand's hernia: a report of two cases. *Hernia*, 2003; 7: 50-51
43. Mullinax JE, Allins A, Avital I: Laparoscopic appendectomy for Amyand's hernia: A modern approach to a historic diagnosis. *J Gastrointest Surg*, 2011; 15: 533-35
44. Baldassarre E, Ferrero C, Da Costa Duarte D et al: Amyand's hernia in infancy: why laparoscopy? *J Pediatr Surg*, 2009; 44: 1673-74
45. Rehman MR, Panteli C, Tsang T: Laparoscopic repair of Amyand's hernia in an 8-week-old infant. *Hernia*, 2010; 14: 443-45
46. Saggarr VR, Singh K, Sarangi R: Endoscopic total extraperitoneal management of Amyand's hernia. *Hernia*, 2004; 8: 164-65
47. Upadhyaya VD, Kumar V, Srivastava P, Gangopadhyaya AN: Amyand's hernia in infant: A rare entity. *Kathmandu Univ Med J (KUMJ)*, 2009; 7: 143-44
48. Milanchi S, Allins AD: Amyand's hernia: history, imaging, and management. *Hernia*, 2008; 12: 321-22
49. Torino G, Campisi C, Testa A et al: Prosthetic repair of a perforated Amyand's hernia: hazardous or feasible? *Hernia*, 2007; 11: 551-52
50. Chatzimavroudis G, Papaziogas B, Koutelidakis I et al: The role of prosthetic repair in the treatment of an incarcerated recurrent inguinal hernia with acute appendicitis (inflamed Amyand's hernia). *Hernia*, 2009; 13: 335-36
51. Losanoff JE, Basson MD: Amyand hernia: What lies beneath – a proposed classification scheme to determine management. *Am Surg*, 2007; 73: 1288-90