

# A Case of Persistence of Normal Tissue Oxygenation Monitored by Near-Infrared Spectroscopy (NIRS) Values Despite Prolonged Perioperative Cardiac Arrest

Authors' Contribution:  
Study Design A  
Data Collection B  
Statistical Analysis C  
Data Interpretation D  
Manuscript Preparation E  
Literature Search F  
Funds Collection G

EF 1 **Julien Maillard**  
F 2 **Tornike Sologashvili**  
BD 1 **John Diaper**  
F 1 **Marc-Joseph Licker**  
EF 1 **Gleicy Keli Barcelos**

1 Department of Anesthesiology, University Hospitals of Geneva, Geneva, Switzerland  
2 Department of Surgery, Division Cardiovascular Surgery, University Hospitals of Geneva, Geneva, Switzerland

**Corresponding Author:** Julien Maillard, e-mail: [julien.maillard@hcuge.ch](mailto:julien.maillard@hcuge.ch)  
**Conflict of interest:** None declared  
**Source of support:** This work was supported by the Division of Anesthesiology, University Hospitals of Geneva, Geneva, Switzerland

**Patient:** Male, 65  
**Final Diagnosis:** Aortic dissection  
**Symptoms:** Hemiplegia • hypotension  
**Medication:** —  
**Clinical Procedure:** Emergent surgery  
**Specialty:** Surgery





**Objective:** Mistake in diagnosis  
**Background:** Patients undergoing cardiac surgery are at risk of adverse perioperative neurological complications. Cerebral oximetry monitoring is increasingly used in these patients to detect intraoperative cerebral hypoxia or ischemic events. Near-infrared spectroscopy (NIRS) uses the near-infrared region of the electromagnetic spectrum for oximetry imaging. A case is reported of the persistence of normal tissue oxygenation monitored by NIRS values despite a prolonged perioperative cardiac arrest.

**Case Report:** A 65-year-old man was admitted to the Emergency Department with dysarthria, left facial ptosis, left hemiplegia, and arterial hypotension of 75/50 mmHg. Computed tomography (CT) angiography showed a Stanford type A aortic dissection extending to the right common carotid artery. Shortly after arrival in the operating room, his hemodynamic condition rapidly deteriorated resulting in cardiac arrest. Despite the rapid onset of extracorporeal circulation, adequate systemic blood flow could not be restored. Cerebral NIRS values remained within the normal range (70–80%) from the start of emergency resuscitation, during a prolonged period of extremely low global blood perfusion values, and until all resuscitation ceased.

**Conclusions:** Cerebral oximetry values reflect a balance between cerebral oxygen delivery and consumption. This case demonstrated the persistence of normal tissue oxygenation monitored by NIRS values despite a prolonged perioperative cardiac arrest.

**MeSH Keywords:** Artifacts • Hypoxia-Ischemia, Brain • Spectroscopy, Near-Infrared

**Full-text PDF:** <https://www.amjcaserep.com/abstract/index/idArt/911399>

 2112   1  42



## Background

Cerebral oximetry is a non-invasive monitoring method that can include the use of near-infrared spectroscopy (NIRS) technology to provide an estimation of the regional cerebral tissue oxygen saturation (rSO<sub>2</sub>). NIRS is simple to use and is not operator-dependent when compared with other brain monitoring devices, although an understanding of the technology behind the measurements is essential for clinicians to correctly interpret NIRS values. Extensive reviews of NIRS technology and the limitations of these devices in estimating cerebral oxygenation have previously been published [1–3].

Infrared radiation (IR) is electromagnetic radiation (EMR) and has longer wavelengths than visible light (700–950 nm) and passes through tissue due to the relative transparency to light in this range of wavelengths. Once emitted, the light is absorbed by surrounding tissues according to their molecular properties, each having distinct absorption spectra in the NIRS. These absorbing molecules, called chromophores, include oxyhemoglobin (HbO<sub>2</sub>) and deoxyhemoglobin, with a maximal absorption spectrum between 700–850 nm [4]. All NIRS-based monitoring techniques rely on a measure of optical attenuation, caused by light absorption and scattering. Using complex algorithms, NIRS monitors convert the measured changes of light attenuation into a numerical and trend display signal of rSO<sub>2</sub>.

One of the main challenges in using NIRS technology is the elimination of artifacts originating from the extra-cranial tissue. Two photodetectors are positioned at two different distances from the light source to differentiate the contribution of superficial tissue from brain tissue to the rSO<sub>2</sub> value. Assuming that photons transmitted through a sphere (the skull) will follow an elliptical path, the near detector measures the photons from the superficial tissues and the far detector measures the photons that come from the brain. Ideally, the subtraction between the two detectors allows an accurate measurement of brain tissue oxygenation [5].

Also, as between 70–80% of the blood in the brain is in the venous compartment, NIRS values mainly reflect venous blood oxygenation [6]. Also, there is an important intra-individual and inter-individual baseline variability. Normal values for NIRS values are between 60–75% but physiological values of 55–60% have been reported in some cardiac patients [7]. Therefore, trends in values are considered more important in clinical practice than the absolute values [8].

The use of NIRS, especially in vascular and cardiac surgery, has been extensively described [9]. While the current evidence does not show that the use of NIRS improves neurological outcomes after cardiac surgery [10], it has been shown that NIRS allows for the intraoperative assessment of the limits of cerebral

autoregulation [11], and might predict postoperative cognitive dysfunction [12] and neurological complications [13,14].

Most recently, attention has been given to the use of NIRS during cardiopulmonary resuscitation (CPR) and the post-cardiac arrest period, as an indirect indicator of impaired cerebral perfusion or low arterial oxygen content. There is evidence in the literature that rSO<sub>2</sub> has potential as a neuro-monitoring tool during cardiopulmonary resuscitation (CPR) and can also be used to guide neuroprotective therapeutic strategies during cardiac arrest [15–21]. Several studies have documented the feasibility of cerebral saturation measurements using NIRS during CPR [16]. These previous studies have supported the use of NIRS values as a guide to the quality of CPR maneuvers [15,17] as a predictor of the return of spontaneous cardiopulmonary circulation [16,18,21], for monitoring brain oxygenation during patient transport [21] and as an indicator to post-arrest neurologic outcome [18–20]. The reliability of continuous cerebral oximetry to reflect the real-world clinical situations is important for informed clinical decision-making. The influence of certain clinical situations that may distort values must be taken into account by the practitioner [22].

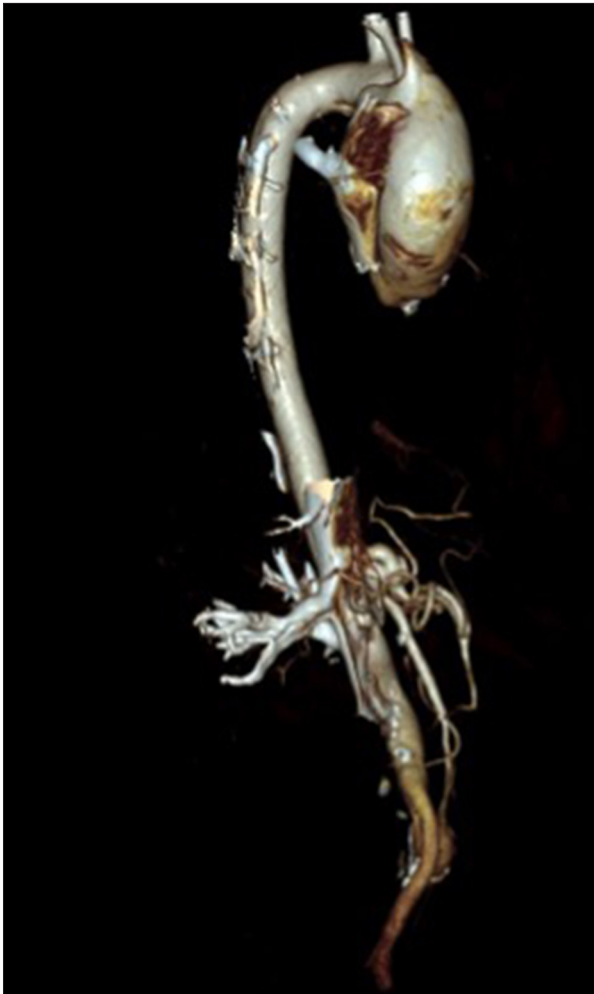A case report is presented that demonstrates the persistence of normal tissue oxygenation monitored by NIRS values despite a prolonged perioperative cardiac arrest with normal continuous cerebral oximetry values based on NIRS monitoring despite the prolonged absence of systemic blood flow.

## Case Report

A 65-year-old man, with peripheral artery disease, presented with sudden onset of jaw and neck pain followed by facial seizures and a 5-minute loss of consciousness, which was witnessed by his wife. On the arrival of the emergency services to his home, the patient was noted to have dysarthria, left facial ptosis, left hemiplegia, and hypotension of 75/50 mmHg (measured in both arms). After fluid administration and treatment with an adrenaline bolus of 30 µg, the patient was rapidly transferred to the Emergency Department at the University Hospital.

On initial arrival at the Emergency Department, the patient's blood pressure was 60/40 mmHg. Computed tomography (CT) angiography showed a Stanford type A aortic dissection, beginning at the coronary artery level and extending to the brachiocephalic trunk and the right common carotid artery with a 16 mm hemopericardium (Figure 1). The patient was immediately transferred to the operating room.

During preparation for anesthesia the patient had a second seizure followed by cardiac arrest with pulseless electrical activity



**Figure 1.** Computed tomography (CT) angiography on hospital admission. Stanford type A aortic dissection, beginning at the level of the coronary arteries and extending to the brachiocephalic trunk and right common carotid artery, with a 16 mm hemopericardium.

(PEA). Cardiopulmonary resuscitation (CPR) was immediately begun and the trachea was intubated. The patient was transferred to the operating room. The femoral artery and vein were cannulated to initiate an extracorporeal circulation, with a delay of 20 mins. A median sternotomy was performed to allow the pericardium to be opened. The surgeons observed a large ascending aortic tear of 5 cm associated with approximately 3 liters of blood pooled in the left pleural space. Continuous intra-thoracic hemorrhage with the absence of sufficient venous return to the extracorporeal pump, despite aggressive transfusion of fluids, led to a decreased mean arterial pressure (MAP) (<30 mmHg), anemia (Hb of 63 g/l), reduced blood oxygen saturation (SpO<sub>2</sub> of 65.9%), and hypocapnia (PaCO<sub>2</sub> of 2.82 kPa). After 21 minutes of inefficient extracorporeal circulation, and a total of 44 minutes of extremely low systemic blood perfusion values assessed clinically and with concomitant

monitoring devices, the attending physicians made a decision to discontinue therapeutic interventions. The patient died in the operating room soon afterward.

In this case, the near-infrared spectroscopy (NIRS) sensor, the FORE-SIGHT ELITE Absolute Tissue Oximeter (Fore-Sight, London, UK) was applied to the forehead shortly after the initiation of CPR. The initial rSO<sub>2</sub> value was 60% and rose to 70% at the initiation of the extracorporeal circulation. After the termination of resuscitation and extracorporeal circulation, with no systemic blood flow, and a clearly cyanotic patient, rSO<sub>2</sub> values remained above 68%. Patient oxygen saturation (SpO<sub>2</sub>) during the period of extracorporeal circulation and at the time of the decision to withhold any further therapeutic action was approximately 75%. The paradoxical NIRS values, although confusing, did not influence the final decision to end treatment.

## Discussion

Near-infrared spectroscopy (NIRS) has been used to acquire real-time information on the cerebral circulation and metabolism in various clinical conditions of cerebral ischemia-reperfusion [23–26]. Adequate cerebral oxygenation depends upon sufficient cerebral blood flow and oxygen content. Any factors disturbing either of these will result in a reduction in cerebral oxygenation and a reduction in cerebral oximetry values. We report a case of normal continuous cerebral oximetry values based on NIRS monitoring despite the prolonged perioperative cardiac arrest.

Any factors disturbing either of these will result in a reduction in cerebral oxygenation and a reduction in cerebral oximetry values. Low cerebral regional oxygen saturation has been reported in clinical conditions associated with compromised cerebral perfusion such as unstable hemodynamics, inadvertent carotid compression, displacement of the extracorporeal membrane oxygenation or extracorporeal circulation (ECMO/ECC) cannula, surgical procedures such as deep hypothermic circulatory arrest or aortic/carotid cross-clamping [27–32]. Also, low rSO<sub>2</sub> values were also found in a patient with global hypoxia or increased cerebral oxygen consumption [22,33].

In the case described, the impaired return flow to the venous cannula of extracorporeal circulation was associated with decreased arterial pressure, major hemorrhage, anemia, reduced blood oxygen saturation and hypocapnia. These different events should have been followed by a significant decrease in cerebral oximetry since cerebral saturation values are a representation of oxygenation in the cerebral microcirculation. Factors impairing oxygen delivery to the brain associated with extracorporeal circulation have been described during cardiac surgical procedures. Among others, impaired flow through the

arterial or venous cannula of extracorporeal circulation, as well as micro-embolism and macro-embolism, hemodilution and severe anemia, can all affect NIRS values [34,35].

Hypotheses that might explain the situation of normal NIRS values despite prolonged perioperative cardiac arrest include the absence of cerebral metabolism during the event, preservation of the extracranial circulation, or a maintained residual cerebral perfusion. The non-metabolizing tissue hypothesis is based on the lack of oxygen required by ischemic or necrotic cerebral tissue. It would be expected that if there is reduced systemic and cerebral blood flow, a rapid decrease in arterial and central venous blood oxygenation would automatically occur. Blood oxygenation would be compromised and oxygen extraction would rise. Therefore, NIRS monitoring would then measure a concomitant reduction in cerebral blood oxygenation. In the case presented in this report, the seizures experienced by the patient might have been symptoms of impaired cerebral circulation as these were among the first symptoms that occurred when at home. The potential rapid development of altered brain tissue failing to extract oxygen from the cerebral blood could be a contributing factor, as the NIRS correctly measures fully oxygenated blood pooled in a non-metabolizing and non-extracting altered brain tissue areas, despite the absence of cerebral blood flow.

Forensic research groups have worked on HbO<sub>2</sub> in cadavers showing that a non-metabolizing brain can have a high oxygen content because of sequestered cerebral venous blood in capillaries and venous capacitance vessels [36]. This was confirmed by oximetry on blood samples of 214 forensic autopsy cases, including blood from the sagittal venous sinus of the dura (cerebral venous blood), where HbO<sub>2</sub> values up to 95.1% were reported. HbO<sub>2</sub> values in these cases depended on total hemoglobin content, cause of death, and cadaver storage conditions [37]. A case report on a living patient with a right internal carotid artery occlusion and an infarct in the middle cerebral artery territory with confirmed absence of perfusion to the infarct showed rSO<sub>2</sub> values between 60–65%. This non-metabolizing tissue hypothesis may offer a plausible explanation for the normal rSO<sub>2</sub> values in this case [38].

An alternative explanation in this patient's case was the persistence of an extracranial circulation. This phenomenon was first described on a brain-dead patient without blood flow to the proximal or middle cerebral arteries using transcranial Doppler (TCD), but with normal rSO<sub>2</sub> values [39]. As the SpO<sub>2</sub> in this patient was 98–99% throughout the study, it was concluded that the discrepancies occurred because the NIRS device was significantly influenced by the oxygenation of the scalp and skull [39]. This explanation was confirmed in a similar study, which also showed a concomitant decrease in rSO<sub>2</sub> with the SpO<sub>2</sub> after discontinuation of mechanical ventilation [40].

Ultrasound-tagged near-infrared spectroscopy (UT-NIRS) was also unable to differentiate signals from extracranial structures [41]. This explanation may be helpful in our case, as the patient had a SpO<sub>2</sub> of approximately 75% during extracorporeal circulation and after its discontinuation, when the NIRS value was still 68%, suggesting that some residual perfusion was maintained in cerebral circulation or that there was no cerebral circulation, and the NIRS values originated solely from extracerebral tissue.

The presence of residual global circulation is a possible explanation in the present case. However, extracorporeal circulation was unable to achieve adequate systemic blood flow, and cardiopulmonary resuscitation (CPR) was not feasible once the chest was opened for surgery. It might be hypothesized that the low degree of metabolism by the brain enabled minimal oxygenated blood circulation or possible pooling of blood in the brain even though, with inadequate perfusion, there were normal values from cerebral oximetry. It should be noted that in the context of resuscitation, massive hemorrhage, and emergency surgery, it would be extremely complex to obtain a direct measurement of cerebral blood flow to exclude this possibility.

Despite the limitations of the use of NIRS in situations where there may be brain death [41], Weigl et al. recently reported a promising technique for the confirmation of cerebral circulation cessation using bolus tracking of an optical contrast agent, indocyanine green, and time-resolved NIRS [42]. As this case report has shown, NIRS is a promising method that opens a new era of research in the assessment of the cerebral circulation in critical situations.

## Conclusions

Near-infrared spectroscopy (NIRS) is a powerful non-invasive technology that has an established role in perioperative care. However, an understanding of the underlying technology is essential, as specific clinical circumstances could lead to confusing values that do not match the clinical context. Further research using optical contrast agents could enhance the ability of NIRS devices to assess cerebral circulation in complex clinical situations.

## Acknowledgments

The authors acknowledge Professor Martin Tramer, Head of the Anesthesiology Department.

## Conflict of interest

None declared.



## References:

1. Calderon-Arnulphi M, Alaraj A, Slavin KV: Near-infrared technology in neuroscience: Past, present and future. *Neurol Res*, 2009; 31(6): 605-14
2. Ghosh A, Elwell C, Smith M: Cerebral near-infrared spectroscopy in adults: A work in progress. *Anesth Analg*, 2012; 115: 1373-83
3. Murkin JM, Arango M: Near-infrared spectroscopy as an index of brain and tissue oxygenation. *Br J Anaesth*, 2009; 103: 3-13
4. Jobsis F: Noninvasive, infrared monitoring of cerebral and myocardial oxygen sufficiency and circulatory parameters. *Science*, 1977; 198: 1264-67
5. Germon TJ, Evans PD, Barnett NJ et al: Cerebral near-infrared spectroscopy: Emitter-detector separation must be increased. *Br J Anaesth*, 1999; 82: 831-37
6. Brawanski A, Faltermeier R, Rothoerl RD, Woertgen C: Comparison of near-infrared spectroscopy and tissue p(O<sub>2</sub>) time series in patients after severe head injury and aneurysmal subarachnoid hemorrhage. *J Cereb Blood Flow Metab*, 2002; 22: 605-11
7. Vretzakis G, Georgopoulou S, Stamoulis K et al: Cerebral oximetry in cardiac anesthesia. *J Thorac Dis*, 2014; 6(Suppl. 1): S60-69
8. Highton D, Elwell C, Smith M: Noninvasive cerebral oximetry: Is there light at the end of the tunnel? *Curr Opin Anaesthesiol*, 2010; 23: 576-81
9. Pennekamp CWA, Bots ML, Kappelle LJ et al: The value of near-infrared spectroscopy measured cerebral oximetry during carotid endarterectomy in perioperative stroke prevention. A review. *Eur J Vasc Endovasc Surg*, 2009; 38: 539-45
10. Bevan PJW: Should cerebral near-infrared spectroscopy be standard of care in adult cardiac surgery? *Heart Lung Circ*, 2015; 24: 544-50
11. Joshi B, Ono M, Brown C et al: Predicting the limits of cerebral autoregulation during cardiopulmonary bypass. *Anesth Analg*, 2012; 114: 503-10
12. Zheng F, Sheinberg R, Yee M-S et al: Cerebral near-infrared spectroscopy monitoring and neurologic outcomes in adult cardiac surgery patients. *Anesth Analg*, 2013; 116: 663-76
13. Olsson C, Thelin S: Regional cerebral saturation monitoring with near-infrared spectroscopy during selective antegrade cerebral perfusion: Diagnostic performance and relationship to postoperative stroke. *J Thorac Cardiovasc Surg*, 2006; 131: 6-8
14. Orihashi K, Sueda T, Okada K, Imai K: Near-infrared spectroscopy for monitoring cerebral ischemia during selective cerebral perfusion. *Eur J Cardiothoracic Surg*, 2004; 26: 907-11
15. Kämäräinen A, Sainio M, Olkkola KT et al: Quality controlled manual chest compressions and cerebral oxygenation during in-hospital cardiac arrest. *Resuscitation*, 2012; 83: 138-42
16. Parnia S, Nasir A, Shah C et al: A feasibility study evaluating the role of cerebral oximetry in predicting return of spontaneous circulation in cardiac arrest. *Resuscitation*, 2012; 83: 982-85
17. Newman DH, Callaway CW, Greenwald IB, Freed J: Cerebral oximetry in out-of-hospital cardiac arrest: Standard CPR rarely provides detectable hemoglobin-oxygen saturation to the frontal cortex. *Resuscitation*, 2004; 63: 189-94
18. Ahn A, Nasir A, Malik H et al: A pilot study examining the role of regional cerebral oxygen saturation monitoring as a marker of return of spontaneous circulation in shockable (VF/VT) and non-shockable (PEA/Asystole) causes of cardiac arrest. *Resuscitation*, 2013; 84: 1713-16
19. Ito N, Nishiyama K, Callaway CW et al: Noninvasive regional cerebral oxygen saturation for neurological prognostication of patients with out-of-hospital cardiac arrest: A prospective multicenter observational study. *Resuscitation*, 2014; 85: 778-84
20. Ito N, Nanto S, Nagao K et al: Regional cerebral oxygen saturation on hospital arrival is a potential novel predictor of neurological outcomes at hospital discharge in patients with out-of-hospital cardiac arrest. *Resuscitation*, 2012; 83: 46-50
21. Asim K, Gokhan E, Ozlem B et al: Near-infrared spectrophotometry (cerebral oximetry) in predicting the return of spontaneous circulation in out-of-hospital cardiac arrest. *Am J Emerg Med*, 2014; 32: 14-17
22. Murkin JM, Arango M: Near-infrared spectroscopy as an index of brain and tissue oxygenation. *Br J Anaesth*, 2009; 103(Suppl. 1): i3-13
23. Xiao F, Rodriguez J, Arnold TC et al: Near-infrared spectroscopy: A tool to monitor cerebral hemodynamic and metabolic changes after cardiac arrest in rats. *Resuscitation*, 2004; 63: 213-20
24. Wyatt JS, Cope M, Delpy DT et al: Quantitation of cerebral blood volume in human infants by near-infrared spectroscopy. *J Appl Physiol*, 1990; 68: 1086-91
25. Jöbsis FF: Noninvasive, infrared monitoring of cerebral and myocardial oxygen sufficiency and circulatory parameters. *Science*, 1977; 198: 1264-67
26. Genbrugge C, De Deyne C, Eertmans W et al: Cerebral saturation in cardiac arrest patients measured with near-infrared technology during pre-hospital advanced life support. Results from Copernicus I cohort study. *Resuscitation*, 2018; 129: 107-13
27. Morimoto Y, Niida Y, Hisano K et al: Changes in cerebral oxygenation in children undergoing surgical repair of ventricular septal defects. *Anaesthesia*, 2003; 58: 77-83
28. Hoffman GM, Stuth EA, Jaquiss RD et al: Changes in cerebral and somatic oxygenation during stage 1 palliation of hypoplastic left heart syndrome using continuous regional cerebral perfusion. *J Thorac Cardiovasc Surg*, 2004; 127: 223-33
29. Meng L, Mantulin WW, Alexander BS et al: Head-up tilt and hyperventilation produce similar changes in cerebral oxygenation and blood volume: An observational comparison study using frequency-domain near-infrared spectroscopy. *Can J Anesth*, 2012; 59: 357-65
30. Moerman AT, De Hert SG, Jacobs TF et al: Cerebral oxygen desaturation during beach chair position. *Eur J Anaesthesiol*, 2012; 29: 82-87
31. Schramm P, Treiber AH, Berres M et al: Time course of cerebrovascular autoregulation during extreme Trendelenburg position for robotic-assisted prosthetic surgery. *Anaesthesia*, 2013; 69: 58-63
32. Harilall Y, Adam JK, Biccard BM, Reddi A: The effect of optimising cerebral tissue oxygen saturation on markers of neurological injury during coronary artery bypass graft surgery. *Heart Lung Circ*, 2014; 23: 68-74
33. Deschamps A, Lambert J, Couture P et al: Reversal of decreases in cerebral saturation in high-risk cardiac surgery. *J Cardiothorac Vasc Anesth*, 2013; 27: 1260-66
34. Yao FSF, Tseng CCA, Ho CYA et al: Cerebral oxygen desaturation is associated with early postoperative neuropsychological dysfunction in patients undergoing cardiac surgery. *J Cardiothorac Vasc Anesth*, 2004; 18: 552-58
35. Lassnigg A, Hiesmayr M, Keznickl P et al: Cerebral oxygenation during cardiopulmonary bypass measured by near-infrared spectroscopy: Effects of hemodilution, temperature, and flow. *J Cardiothorac Vasc Anesth*, 1999; 13: 544-48
36. Schwarz G, Litscher G, Kleinert R, Jobstmann R: Cerebral oximetry in dead subjects. *J Neurosurg Anesthesiol*, 1996; 8: 189-93
37. Maeda H, Fukita K, Oritani S et al: Evaluation of post-mortem oximetry with reference to the causes of death. *Forensic Sci Int*, 1997; 87: 201-10
38. Nemoto EM, Yonas H, Kassam A: Clinical experience with cerebral oximetry in stroke and cardiac arrest. *Crit Care Med*, 2000; 28: 1052-54
39. Germon TJ, Manara AR, Kane NM, Nielson RJ: Possible limitations of cerebral oximetric monitoring in adults. *Anaesthesia*, 1994; 49: 639-40
40. Kyttä J, Öhman J, Tanskanen P, Randell T: Extracranial contribution to cerebral oximetry in brain dead patients: A report of six cases. *J Neurosurg Anesthesiol*, 1999; 11: 252-54
41. Caccioppola A, Carbonara M, Macrì M et al: Ultrasound-tagged near-infrared spectroscopy does not disclose absent cerebral circulation in brain-dead adults. *Br J Anaesth*, 2018; 7: 1-7
42. Weigl W, Milej D, Gerega A et al: Confirmation of brain death using optical methods based on tracking of an optical contrast agent: Assessment of diagnostic feasibility. *Sci Rep*, 2018; 8: 2-12.