



Published in final edited form as:

Am J Med Case Rep. 2019 ; 7(1): 5–8. doi:10.12691/ajmcr-7-1-2.

A Rare Case of HIV-Induced Inflammatory Demyelinating Polyneuropathy

Abin Sajan, BS¹, Soombal Zahid, DO², Jordan Stumph, MD², Daniel Griep, BE¹, Sami Saba, MD², Nazish Ilyas, MD², and Isabel M. McFarlane, MD^{1,*}

¹Department of Medicine, SUNY Downstate Medical Center, 450 Clarkson Avenue Brooklyn, NY 11203 (718) 270-2030

²Department of Medicine, Lenox Hill Hospital, Department of Medicine, 100 E 77th Street New York, NY 10075 (212) 434-2000

Abstract

Background: Acute inflammatory demyelinating polyneuropathy (AIDP) is an uncommon form of neuropathy in HIV-infected patients that can cause pain, sensory disturbance, and motor weakness.

Case presentation: A 23-year-old African American male with past medical history of Guillain-Barre Syndrome (GBS), Lyme disease, and sexually transmitted infections including syphilis and chlamydia presented with acute back pain radiating to bilateral lower extremities with worsening right foot weakness for four days. Cerebrospinal fluid (CSF) studies including meningoencephalitis panel were negative as well as blood tests for Lyme disease and HIV antibody testing. Patient was initially treated with penicillin for positive treponemal serology but without improvement in lower extremity weakness. Electromyogram showed evidence of early demyelinating motor polyneuropathy. Four days after presentation, repeat HIV antibody testing returned positive. Recurrent AIDP in this case was suspected to be secondary to acute HIV infection, and highly active antiretroviral therapy (HAART) was administered along with intravenous immunoglobulin (IVIG). Muscle strength improved with therapy and patient was expected to have continued improvement with intensive rehabilitation after discharge.

Conclusion: Acute inflammatory demyelinating polyneuropathy (AIDP) tends to present early in course of HIV infection. Therefore, HIV testing should be obtained in individuals presenting with new neurological deficits. Our patient received HAART therapy, in addition to the traditional modalities to manage AIDP, which led to a substantial recovery of his sensorimotor function.

Keywords

human immunodeficiency virus; acute inflammatory demyelinating polyneuropathy; Guillain-Barre syndrome; intravenous immunoglobulin; peripheral neuropathy; chronic inflammatory demyelinating polyneuropathy; highly active antiretroviral therapy

1. Introduction

The advent of highly active antiretroviral therapy (HAART) has resulted in massive improvement in the quality of life of people infected with human immunodeficiency virus (HIV) [1]. Despite this progress, about seventy percent of HIV patients develop neurological complications that originate in the central or peripheral nervous system as a primary or secondary disorders [1,2]. Primary disorders occur from the direct effects of the virus on the immune system leading to HIV-associated neurocognitive disorders (HAND), HIV-associated vascular myelopathy, and a number of neuropathies [2,3,4]. In turn, secondary disorders result from marked immunosuppression and include primary central nervous system lymphoma and opportunistic infections [4,5].

Peripheral nervous system disorders in HIV-infected patients can cause pain, sensory disturbance, and motor weakness [2,3,6]. The peripheral disorders are categorized into distal symmetric polyneuropathy, inflammatory demyelinating polyneuropathy (IDP), mononeuropathy/mononeuropathy-multiplex, and radiculopathies [6,7]. Of the above, inflammatory demyelinating polyneuropathy is an uncommon form of neuropathy in HIV-infected patients with a handful of data available [6,8]. Along with the rarity of the association between HIV and GBS, we described resolution of inflammatory polyneuropathy upon initiation of HAART. We present the case of a young patient who had suffered GBS three years prior and developed new right lower extremity weakness. Work-up revealed HIV seroconversion, negative Epstein Barr Virus in CSF and early demyelinating motor polyneuropathy on electromyogram leading to the diagnosis of inflammatory demyelinating polyneuropathy in the setting of newly diagnosed HIV.

2. Case Presentation

A 23-year-old male presented with lumbar back pain radiating to the lower extremities and worsening right foot weakness that began four days before. Patient also reported unintentional fifteen-pound weight loss over the past four months. Past medical history included treatment for sexually transmitted infections (syphilis and chlamydia) and three years prior, and episode of Guillan-Barre syndrome (GBS), presumed to be secondary to Lyme disease from which he had recovered completely. Social history was significant for high-risk sexual behavior and a long-term HIV-positive partner with undetectable viral load. Neurological exam revealed normal tone throughout but reduced strength (3/5) in the right lower extremity with reduced sensation distal to the right patellofemoral joint. The right patellar reflex was absent with 2+ reflexes elsewhere. The rest of the clinical examination was normal.

On examination, temperature was 36.7C, pulse of 43 beats per minute, blood pressure 112/73 mmHg, respiratory rate 17 breaths per minute, and oxygen saturation was 100% on ambient air. Initial blood tests showed: white blood cell count 3.1×10^9 and platelet count 147,000. CSF examination was unremarkable: no mononuclear cells or polymorphonuclear leukocytes, protein level of 32 mg/dL, and a glucose level of 53 mg/dL. Further blood tests revealed negative immunoglobulins M/G for Lyme disease, negative HIV antibody testing, positive IgG for Epstein Barr Virus, and positive treponemal serology with a rapid plasma

reagin (RPR) of 1:8. An MRI of the lumbar spine was remarkable for abnormal enhancement of the cauda equina roots (Figure 1). MRI of the head, cardiac MRI, and transthoracic echocardiogram were all within normal limits. Cardiology was consulted for bradycardia and recommended outpatient follow-up in the background of an otherwise normal EKG with bradycardia and normal ejection fraction on echocardiogram.

The suspected diagnosis was neurosyphilis and CSF treponemal antibodies were ordered. The patient received intravenous penicillin G with frequent neurological examinations however, the right lower extremity sensory deficit did not show any improvement. Electromyogram revealed an early demyelinating predominantly motor polyneuropathy. Patient had been successfully treated for syphilis two years ago with RPR titers that had reduced from 1:128 to 1:2. CSF studies including polymerase chain reaction analyses, and antibody testing were negative for Lyme disease, syphilis, herpes simplex virus, herpes zoster virus, Epstein-bar virus, and cytomegalovirus.

Screening for other blood-borne viruses, opportunistic infections, and MRI of the brain were all negative. In view of the established risk factors and new findings, a repeat HIV test was done on hospital day 4 and resulted positive. The HIV viral load was >500,000 copies/ml and the CD4 count was 574 cells/mm³. There was a high clinical suspicion for inflammatory demyelinating polyneuropathy secondary to an acute HIV infection and patient was started on highly active antiretroviral therapy (HAART) along with intravenous immunoglobulin (IVIG). His strength improved (4/5) with therapy and physical therapy recommended acute rehabilitation. On hospital day 12, patient was discharged with close follow-up.

3. Discussion

Acute inflammatory demyelinating polyneuropathy (AIDP) is rarely reported in HIV patients but it is one of the most common variants of Guillain Barre Syndrome [9,10,11]. When it occurs, AIDP would be expected early in course of HIV infection or seroconversion [9,13,14]. Patients often present asymptotically, and it is important to consider HIV testing in otherwise healthy individuals with newfound neurological presentation. The pathogenesis is an HIV triggered inflammatory or autoimmune process that targets the myelin sheath, causing demyelination. Antibodies against peripheral myelin glycolipids have been identified in HIV patients presenting with AIDP [15]. The presentation is a rapid, symmetric, ascending motor weakness with generalized areflexia and sparing of sensation [12,13]. Our patient's presentation is atypical of AIDP: presenting acutely with an asymmetric ascending motor weakness limited to the right lower extremity and in addition, this patient had GBS in the past, prior to having the diagnosis of HIV.

Recurrent GBS has been reported in the literature with an incidence of three to six percent [23]. Unlike chronic inflammatory demyelinating neuropathy (CIDP), patients with recurrent GBS are generally under thirty with shorter intervals between recurrences and accumulating neurologic deficits with each recurrence [24]. Recurrent GBS in HIV patients has not been well studied but multiple cases have reported GBS initially with seroconversion and later recurrences with immune reconstitution following HAART therapy [24,25]. Our patient had a previous history of GBS three years before, an initial negative HIV test and

neurological deficits compatible with recurrent GBS; repeat HIV test revealed seroconversion.

The diagnosis of AIDP is based on clinical features, CSF analysis, and electrophysiological studies [7,17,18]. CSF analysis typically shows an elevated protein and mild lymphocytic pleocytosis. Elevated protein has been reported in 80% of all cases while CSF white cells are not seen in HIV seronegative patients [7,19]. Our patient had a normal CSF with a protein and glucose levels.

AIDP following HIV seroconversion has been shown to present with clinical features that are unlike characteristic findings. In existing literature, one patient presented with quadriparesis, while two other patients presented with progressive upper or lower extremity weakness along with dyspnea, dysarthria, and facial palsy [8,13,14]. Patients can also have symptoms of autonomic and respiratory dysfunction [8,16]. Although our patient's symptoms were isolated to the right lower extremity, he presented with new onset bradycardia, possibly secondary to autonomic dysfunction.

Treatment of AIDP is directed at the antibodies targeting the myelin sheath. Generally, AIDP in HIV patients is treated with IVIG 400 mg/kg/day for five days [11,16,20]. Plasma exchange can also be used in patients with contraindications or lack of response to therapy. Although less common, prednisone 1 mg/kg/day can be used. While IVIG and plasma transfusion target antibodies, there has been increasing research about the role of HAART therapy for AIDP [1,4,16,21]. It has been reported that early introduction of HAART can improve disease course and prove beneficial [11,14,22]. Our patient was treated with IVIG for five days along with initiation of HAART therapy.

4. Conclusion

AIDP is a GBS variant and rarely reported among HIV patients. AIDP have a wide spectrum of clinical presentations that range from asymptomatic to rapidly ascending motor weakness with generalized areflexia and signs of autonomic dysfunction. Our patient with recurrent AIDP who presented with bradycardia and an asymmetric ascending motor weakness of the RLE. This time, the patient presented in the setting of acute HIV seroconversion and symptoms improved with the initiation of appropriate therapy for HIV and AIDP. In a young person with acute neurologic symptoms, not all findings may be clear and a unifying diagnosis requires careful analysis. The diagnosis of AIDP in our patient was based on a combination of clinical features, serologic testing, and electrophysiological studies. It is important to consider HIV testing in high-risk individuals with newly found neurological presentation. Traditional treatment for AIDP involves IVIG however, we observed a significant clinical improvement of AIDP upon the initiation of HAART therapy, suggesting that targeted therapy for HIV infection addressed the underlying pathogenesis of AIDP in this patient. Further studies are needed to confirm our hypothesis.

Acknowledgements

This work is supported in part by Dr. Moro O. Salifu's efforts through NIH Grant # S21MD012474.

References

- [1]. Arts EJ and Hazuda DJ, HIV-1 antiretroviral drug therapy. *Cold Spring Harbor perspectives in medicine*, 2012 2(4): p. a007161–a007161. [PubMed: 22474613]
- [2]. Bilgrami M and O'Keefe P, Neurologic diseases in HIV-infected patients. *Handb Clin Neurol*, 2014 121: p. 1321–44. [PubMed: 24365422]
- [3]. Gelman BB, Neuropathology of HAND With Suppressive Antiretroviral Therapy: Encephalitis and Neurodegeneration Reconsidered. *Current HIV/AIDS reports*, 2015 12(2): p. 272–279. [PubMed: 25860316]
- [4]. Kolson D, Neurologic Complications in Persons With HIV Infection in the Era of Antiretroviral Therapy. *Topics in antiviral medicine*, 2017 25(3): p. 97–101. [PubMed: 28820724]
- [5]. Saylor D, et al., HIV-associated neurocognitive disorder - pathogenesis and prospects for treatment. *Nature reviews. Neurology*, 2016 12(5): p. 309–309.
- [6]. Wulff EA, Wang AK, and Simpson DM, HIV-Associated Peripheral Neuropathy. *Drugs*, 2000 59(6): p. 1251–1260. [PubMed: 10882161]
- [7]. Moodley K, Bill PLA, and Patel VB, A comparative study of CIDP in a cohort of HIV-infected and HIV-uninfected patients. *Neurology(R) neuroimmunology & neuroinflammation*, 2016 4(2): p. e315–e315. [PubMed: 28054000]
- [8]. Shepherd SJ, et al., HIV positive patient with GBS-like syndrome. *JMM Case Rep*, 2017 4(8): p. e005107. [PubMed: 29026634]
- [9]. Hagberg L, et al., Guillain-Barre Syndrome as an Early Manifestation of HIV Central Nervous System Infection. *Scandinavian Journal of Infectious Diseases*, 1986 18(6): p. 591–592. [PubMed: 3468607]
- [10]. Parry GJ, Peripheral neuropathies associated with human immunodeficiency virus infection. *Annals of Neurology*, 1988 23(S1): p. S49–S53. [PubMed: 2831803]
- [11]. Willison HJ, Jacobs BC, and van Doorn PA, Guillain-Barre syndrome. *The Lancet*, 2016 388(10045): p. 717–727.
- [12]. Dimachkie MM and Barohn RJ, Guillain-Barre syndrome and variants. *Neurologic clinics*, 2013 31(2): p. 491–510. [PubMed: 23642721]
- [13]. Pontali E, et al., Guillain-Barre Syndrome with Fatal Outcome during HIV-1-Seroconversion: A Case Report. *Case Reports in Infectious Diseases*, 2011 2011: p. 4.
- [14]. Sloan DJ, et al., Human immunodeficiency virus seroconversion presenting with acute inflammatory demyelinating polyneuropathy: a case report. *J Med Case Rep*, 2008 2: p. 370. [PubMed: 19055816]
- [15]. Petratos S, et al., Antibodies against peripheral myelin glycolipids in people with HIV infection. *Immunol Cell Biol*, 1998 76(6): p. 535–41. [PubMed: 9893031]
- [16]. Rosca EC, Rosca O, and Simu M, Intravenous immunoglobulin treatment in a HIV-1 positive patient with Guillain-Barre syndrome. *International Immunopharmacology*, 2015 29(2): p. 964–965. [PubMed: 26428850]
- [17]. Koller H, et al., Chronic Inflammatory Demyelinating Polyneuropathy. *New England Journal of Medicine*, 2005 352(13): p. 1343–1356. [PubMed: 15800230]
- [18]. Mathey EK, et al., Chronic inflammatory demyelinating polyradiculoneuropathy: from pathology to phenotype. *Journal of neurology, neurosurgery, and psychiatry*, 2015 86(9): p. 973–985.
- [19]. Ramos Tito AP, et al., Chronic inflammatory demyelinating polyneuropathy associated with HIV and Neurosyphilis coinfection. *Journal of the Neurological Sciences*, 2017 381: p. 830.
- [20]. Hiraga A, et al., Recovery patterns and long term prognosis for axonal Guillain-Barre syndrome. *Journal of Neurology, Neurosurgery & Psychiatry*, 2005 76(5): p. 719.
- [21]. Meena AK, Khadilkar SV, and Murthy JMK, Treatment guidelines for Guillain-Barre Syndrome. *Annals of Indian Academy of Neurology*, 2011 14(Suppl 1): p. S73–S81. [PubMed: 21847334]
- [22]. Harms M, Inpatient management of guillain-barre syndrome. *The Neurohospitalist*, 2011 1(2): p. 78–84. [PubMed: 23983841]
- [23]. Brannagan TH 3rd and Zhou Y, HIV-associated Guillain-Barre syndrome. *J Neurol Sci*, 2003 208(1-2): p. 39–42. [PubMed: 12639723]

- [24]. Kuitwaard K, et al., Recurrent Guillain-Barre syndrome. *J Neurol Neurosurg Psychiatry*, 2009 80(1): p. 56–9. [PubMed: 18931012]
- [25]. Makela P, et al., Recurrent Guillain-Barre syndrome as a complication of immune reconstitution in HIV. *J Infect*, 2002 44(1): p. 47–9. [PubMed: 11972420]

Author Manuscript

Author Manuscript

Author Manuscript

Author Manuscript

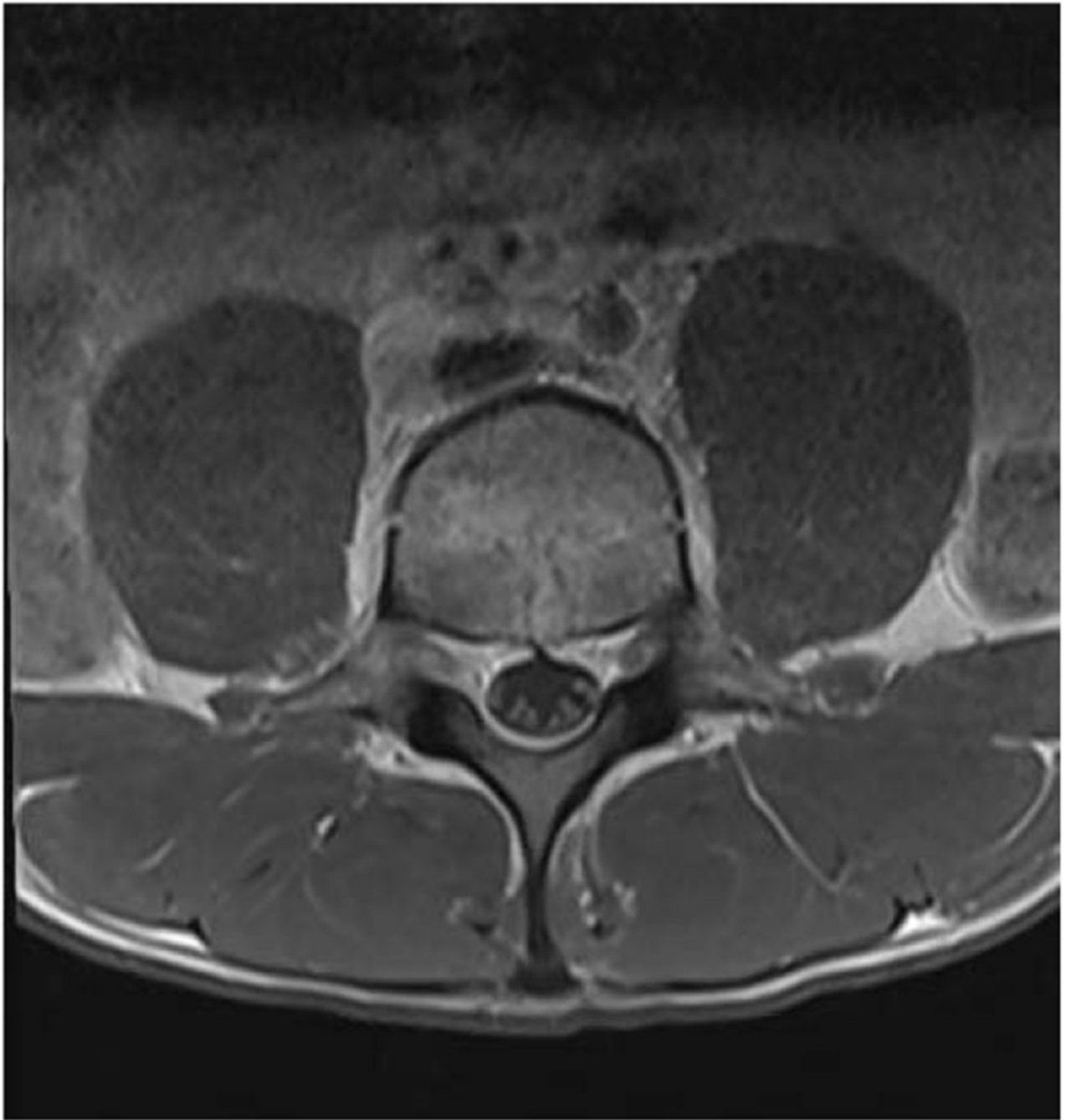


Figure 1.
MRI of the lumbar spine demonstrating abnormal enhancement of the cauda equina roots