

## A comparative analysis of patients with mesiodens: a clinical and radiological study

Sung-Suk Lee<sup>1</sup>, Su-Gwan Kim<sup>1</sup>, Ji-Su Oh<sup>1</sup>, Jae-Seek You<sup>1</sup>, Kyung-In Jeong<sup>1</sup>,  
 Young-Kyun Kim<sup>2</sup>, Sang-Ho Lee<sup>3</sup>, Nan-Young Lee<sup>3</sup>

<sup>1</sup>Department of Oral and Maxillofacial Surgery, School of Dentistry, Chosun University, Gwangju,

<sup>2</sup>Department of Oral and Maxillofacial Surgery, Section of Dentistry, Seoul National University Bundang Hospital, Seongnam,

<sup>3</sup>Department of Pediatric Dentistry, School of Dentistry, Chosun University, Gwangju, Korea

**Abstract** (J Korean Assoc Oral Maxillofac Surg 2015;41:190-193)

**Objectives:** A mesiodens appears most commonly as a supernumerary tooth impacted in the anterior maxilla. The purpose of this study is analyze mesiodens clinically.

**Materials and Methods:** Gender, crown form, direction of impaction, relation to permanent incisors, and chief complaints of patients with extracted mesiodens were analyzed.

**Results:** Patients were analyzed for motivation to visit the hospital; 85.4% of the patients were referred from other hospitals. Mesiodens was more common in males than in females (3.7:1), and 70.1% of patients had only one mesiodens, while 29.6% had two mesiodens. Of the mesiodens, 61.4% were of the aconical form, and the most common direction was upward (62.4%), followed by the normal position (26.0%) and the horizontal position (11.6%). The mesiodens caused orthodontic problems with the permanent incisors in 46.3% of cases. Mesiodens associated with dentigerous cyst was rarely observed in our patient group.

**Conclusion:** Mesiodens is more common in males than in females and often affects the permanent incisors. Thus, careful clinical and radiological evaluations of mesiodens are important.

**Key words:** Supernumerary tooth, Tooth abnormalities

[paper submitted 2015. 3. 11 / revised 1st 2015. 5. 7, 2nd 2015. 5. 26 / accepted 2015. 5. 27]

### I. Introduction

The etiology of supernumerary teeth is unclear. The most frequent type of supernumerary tooth is the mesiodens, located between the central incisors in the anterior maxilla<sup>1,2</sup>.

Mesiodens are more common in males than in females. A mesiodens, which is often located on the palatal side of the root of a deciduous tooth, can interfere with the eruption of the permanent incisor or can cause malocclusion such as

rotation of a permanent incisor and diastema. Rarely, it is associated with a dentigerous cyst<sup>3</sup>.

In this study, we investigated the characteristics of recent mesiodens cases and compared them with mesiodens research by Kim and Lee<sup>4</sup> in 2003.

### II. Materials and Methods

This research was conducted on patients who underwent mesiodens extraction at Chosun University Dental Hospital between January 2009 and September 2013. All patients were examined clinically and radiologically and were assessed in terms of gender, age, main reason for the visit to the hospital, effects on permanent incisors, shape of the supernumerary tooth, and presence of dentigerous cysts. In all patients, mesiodens were extracted surgically. A comparative analysis was carried out between these data and the results of research published in 2003<sup>4</sup>.

#### *Su-Gwan Kim*

Department of Oral and Maxillofacial Surgery, School of Dentistry, Chosun University, 303 Pilmun-daero, Dong-gu, Gwangju 61452, Korea

TEL: +82-62-220-3815 FAX: +82-62-228-7316

E-mail: sgckim@chosun.ac.kr

ORCID: <http://orcid.org/0000-0002-0424-9984>

©This is an open-access article distributed under the terms of the Creative Commons Attribution Non-Commercial License (<http://creativecommons.org/licenses/by-nc/4.0/>), which permits unrestricted non-commercial use, distribution, and reproduction in any medium, provided the original work is properly cited.

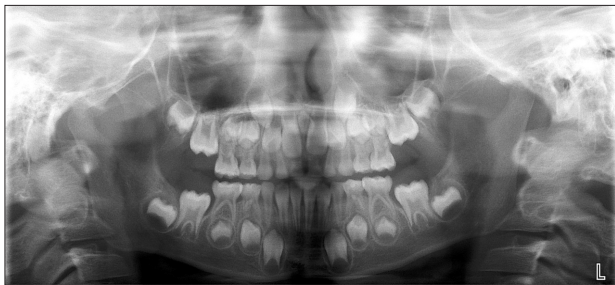Copyright © 2015 The Korean Association of Oral and Maxillofacial Surgeons. All rights reserved.

### III. Results

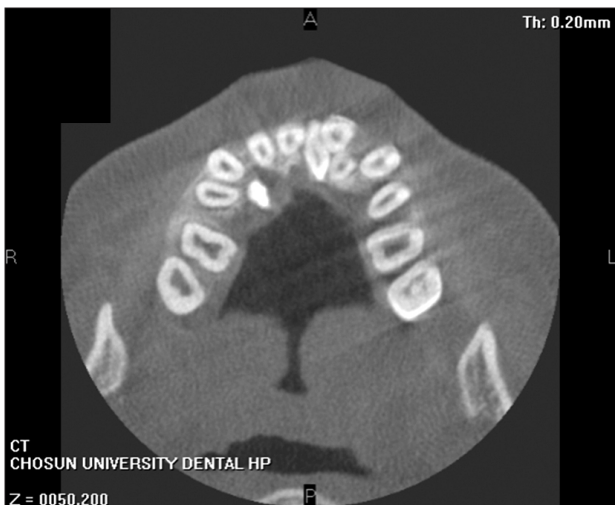In total, 378 patients visited the hospital with mesiodens between January 2009 and September 2013.(Fig. 1-5) There were 298 males and 80 females, showing a male-to-female ratio of 3.7:1. Their ages varied from 3 to 75 years, with a mean age of 8.4 years.

Of the patients, 265 patients (70.1%) had one supernumerary tooth, 112 patients (29.6%) had two supernumerary teeth, and one patient (0.3%) had three supernumerary teeth. In patients with more than one supernumerary tooth, all supernumerary teeth were extracted at the same visit.

Patients were analyzed for motivation to visit to the hospital. Of the 378 enrolled patients, 323 patients (85.4%) were referred from other hospitals specifically for removal of the supernumerary tooth. In 15 patients (4.0%) cases, an orthodontic problem was caused by the mesiodens; in 40 patients (10.6%) cases, the mesiodens was found by chance during



**Fig. 1.** A mesiodens found in an oral panoramic X-ray.  
*Sung-Suk Lee et al: A comparative analysis of patients with mesiodens: a clinical and radiological study. J Korean Assoc Oral Maxillofac Surg 2015*

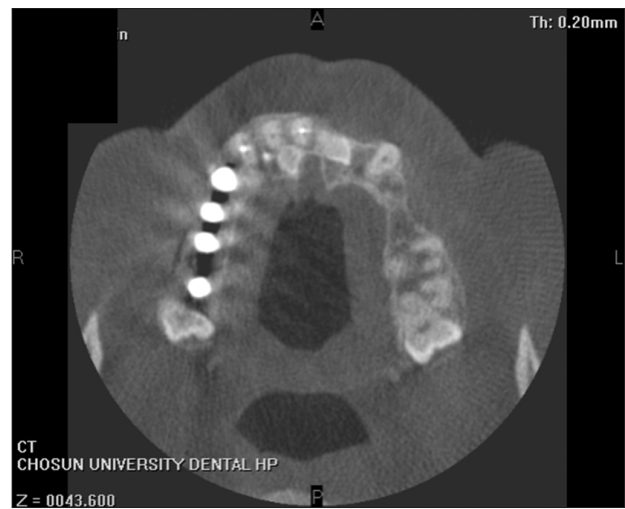


**Fig. 2.** An impacted conical-shaped mesiodens.  
*Sung-Suk Lee et al: A comparative analysis of patients with mesiodens: a clinical and radiological study. J Korean Assoc Oral Maxillofac Surg 2015*

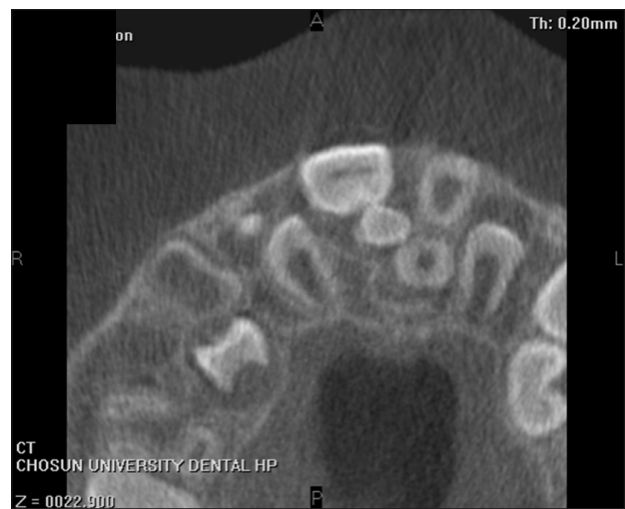their visit to the hospital for another treatment.(Table 1)

We radiologically examined 492 supernumerary teeth for impaction type and found that 307 teeth (62.4%) were impacted in the opposite direction, 128 teeth (26.0%) were impacted in the normal direction, and 57 teeth (11.6%) were impacted horizontally.(Table 2)

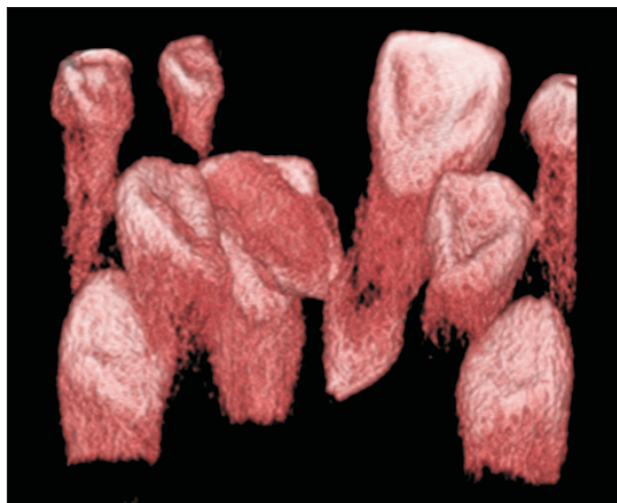
On the basis of clinical examinations, 200 patients (52.9%) had no specific symptoms due to the presence of mesiodens, 94 patients (24.9%) had diastema, 59 patients (15.6%) had delayed eruption of a permanent incisor, and 22 patients (5.8%) had an angled incisor due to the mesiodens. Inflammation caused by the mesiodens was observed in three (0.8%)



**Fig. 3.** Two horizontally impacted mesiodens.  
*Sung-Suk Lee et al: A comparative analysis of patients with mesiodens: a clinical and radiological study. J Korean Assoc Oral Maxillofac Surg 2015*



**Fig. 4.** A mesiodens impacted on the palatal side of the central incisor.  
*Sung-Suk Lee et al: A comparative analysis of patients with mesiodens: a clinical and radiological study. J Korean Assoc Oral Maxillofac Surg 2015*



**Fig. 5.** A mesiodens impacted in the opposite direction.  
*Sung-Suk Lee et al: A comparative analysis of patients with mesiodens: a clinical and radiological study. J Korean Assoc Oral Maxillofac Surg 2015*

**Table 1.** Chief complaint (n=378)

Chief complaint	Number (%) of cases
Referred from another clinic	323 (85.4)
Orthodontic problem	15 (4.0)
Other treatment	40 (10.6)

*Sung-Suk Lee et al: A comparative analysis of patients with mesiodens: a clinical and radiological study. J Korean Assoc Oral Maxillofac Surg 2015*

**Table 2.** Position of mesiodens according to year

Position	2003 (n=50)	2013 (n=492)
Upward	26 (52.0)	307 (62.4)
Downward	19 (38.0)	128 (26.0)
Horizontal	5 (10.0)	57 (11.6)

Values are presented as number (%).  
*Sung-Suk Lee et al: A comparative analysis of patients with mesiodens: a clinical and radiological study. J Korean Assoc Oral Maxillofac Surg 2015*

patients.(Table 3)

Following extraction, the crown shape was analyzed. A conical shape was found in 302 crowns (61.4%), a round shape in 62 crowns (12.6%), a tubercular type in 53 crowns (10.8%), a shape similar to a canine in 40 crowns (8.1%), and a shape similar to an incisor in 35 crowns (7.1%).(Table 4) In two patients (0.5%), dentigerous cyst was found radiologically.

#### IV. Discussion

In many cases, a mesiodens is a single impacted tooth. Comparing results of our previous study with the present study, we found that 75.0% and 70.1% patients had only one mesiodens, and 25.0% and 29.6%, respectively<sup>4</sup>, had two me-

**Table 3.** Effects on permanent maxillary incisors according to year

Effect	2003 (n=50)	2013 (n=378)
Non-specific	32 (64.0)	200 (52.9)
Delayed eruption	10 (20.0)	59 (15.6)
Axial rotation or inclination of erupted permanent incisors	4 (8.0)	22 (5.8)
Diastema	2 (4.0)	94 (24.9)
Intraoral infection	2 (4.0)	3 (0.8)

Values are presented as number (%).  
*Sung-Suk Lee et al: A comparative analysis of patients with mesiodens: a clinical and radiological study. J Korean Assoc Oral Maxillofac Surg 2015*

**Table 4.** Shapes of mesiodens according to year

Shape	2003 (n=50)	2013 (n=492)
Conical	33 (66.0)	302 (61.4)
Canine-like	9 (18.0)	40 (8.1)
Incisor-like	4 (8.0)	35 (7.1)
Tuberculated	2 (4.0)	53 (10.8)
Round	2 (4.0)	62 (12.6)

Values are presented as number (%).  
*Sung-Suk Lee et al: A comparative analysis of patients with mesiodens: a clinical and radiological study. J Korean Assoc Oral Maxillofac Surg 2015*

siodens. Orhan et al.<sup>5</sup> reported that 76% to 86% of patients had only one mesiodens, 12% to 23% had two, and fewer than 1% had three or more.

Ray et al.<sup>6</sup> observed that mesiodens appeared twice as frequently in males than females, and Rajab and Hamdan<sup>7</sup> reported a male-to-female ratio of 2.2:1 in Jordanian children. Both our previous and present results suggest a higher male-to-female ratio. We found 4:1 in our previous study and 3.7:1 in this study.

Morphologically, mesiodens can have various shapes<sup>8</sup>. The most common shapes are conical, incisor-like, and tubercular types. The conical type was seen in both our previous study and in the present study, at frequencies of 66.0% and 61.4%, respectively<sup>4</sup>.

In some patients, the mesiodens erupts ‘normally’ but is mostly impacted or is pointed in the opposite direction. This is probably because the supernumerary tooth has an abnormal eruption path or erupts ectopically<sup>9,10</sup>. An impacted mesiodens can interfere with the eruption of the adjacent permanent teeth or can cause malocclusion<sup>11</sup>. Comparing impaction direction between our previous study and this study showed that 52.0% and 62.4% were impacted in the opposite direction, 38.0% and 26.0% were in the normal direction, and 10.0% and 11.6% were impacted horizontally, respectively<sup>4</sup>. No specific effect on permanent incisors was consistently found in either the previous study or in this study (64.0% and 52.9%, respectively). Delayed eruption was found in 20.0%

and 15.6% of cases, diastema in 4% and 24.9%, and rotation of a permanent incisor in 8.0% and 5.8% between the previous study and this study, respectively. Malocclusion of a permanent incisor was found in 32.0% and 46.3% of previous and current patients, respectively, and inflammation was observed in 4% and 0.8% of cases<sup>4</sup>.

Only two patients (0.5%) in the present study were radiologically observed to have dentigerous cyst associated with a mesiodens, and Dinkar et al.<sup>3</sup> have reported a correlation between dentigerous cyst and a mesiodens, although such a finding is rare.

## V. Conclusion

It is important to determine both the number and location of mesiodens in a patient. It is also necessary to carefully examine the impaction direction, the effects on adjacent teeth, and the formation of dentigerous cyst. When a pathologic condition is found related to the presence of a mesiodens, extraction of the mesiodens should be considered.

## Conflict of Interest

No potential conflict of interest relevant to this article was reported.

## ORCID

Sung-Suk Lee, <http://orcid.org/0000-0002-4564-6302>

Su-Gwan Kim, <http://orcid.org/0000-0002-0424-9984>

Ji-Su Oh, <http://orcid.org/0000-0002-8369-5025>

Jae-Seek You, <http://orcid.org/0000-0001-7638-9583>

Kyung-In Jeong, <http://orcid.org/0000-0002-8922-0290>

Young-Kyun Kim, <http://orcid.org/0000-0002-7268-3870>

Sang-Ho Lee, <http://orcid.org/0000-0003-2513-6871>

Nan-Young Lee, <http://orcid.org/0000-0002-4738-9389>

## References

1. von Arx T. Anterior maxillary supernumerary teeth: a clinical and radiographic study. *Aust Dent J* 1992;37:189-95.
2. Lustmann J, Bodner L. Dentigerous cysts associated with supernumerary teeth. *Int J Oral Maxillofac Surg* 1988;17:100-2.
3. Dinkar AD, Dawasaz AA, Shenoy S. Dentigerous cyst associated with multiple mesiodens: a case report. *J Indian Soc Pedod Prev Dent* 2007;25:56-9.
4. Kim SG, Lee SH. Mesiodens: a clinical and radiographic study. *J Dent Child (Chic)* 2003;70:58-60.
5. Orhan AI, Ozer L, Orhan K. Familial occurrence of nonsyndromal multiple supernumerary teeth. A rare condition. *Angle Orthod* 2006;76:891-7.
6. Ray D, Bhattacharya B, Sarkar S, Das G. Erupted maxillary conical mesiodens in deciduous dentition in a Bengali girl--a case report. *J Indian Soc Pedod Prev Dent* 2005;23:153-5.
7. Rajab LD, Hamdan MA. Supernumerary teeth: review of the literature and a survey of 152 cases. *Int J Paediatr Dent* 2002;12:244-54.
8. Gallas MM, García A. Retention of permanent incisors by mesiodens: a family affair. *Br Dent J* 2000;188:63-4.
9. Fernández Montenegro P, Valmaseda Castellón E, Berini Aytés L, Gay Escoda C. Retrospective study of 145 supernumerary teeth. *Med Oral Patol Oral Cir Bucal* 2006;11:E339-44.
10. Meighani G, Pakdaman A. Diagnosis and management of supernumerary (mesiodens): a review of the literature. *J Dent (Tehran)* 2010;7:41-9.
11. Asaumi JI, Shibata Y, Yanagi Y, Hisatomi M, Matsuzaki H, Konouchi H, et al. Radiographic examination of mesiodens and their associated complications. *Dentomaxillofac Radiol* 2004;33:125-7.