

## Chest Wall Monophasic Synovial Sarcoma in a 12-Year-Old Boy: A Case Report

Fatma Bchini , Malek Boughdir , Souha Laarif , Aida Daib, Rim Kchaou, Sameh Tlili, Rabiaa Ben Abdallah, Youssef Hellal, Nejib Kaabar

Pediatric Surgery Department, Hospital Habib Thameur, Tunis, Tunisia

### ABSTRACT

We report a rare case of synovial sarcoma of the chest wall in a child. A 12-year-old male presented to our pediatric surgery department with chief complaint of swelling accompanied by slight pain of the upper right side of the anterior chest wall since approximately 5 months. Firstly, we performed an ultrasound (US)-mass biopsy. Histopathological examination showed fibromatosis. After that, we underwent surgical resection. Pathological examination revealed a monophasic type synovial sarcoma. Immediately post-operation, the patient manifested a loss of the extension of the forearm, hand, and fingers on the right side. Physical therapy was performed with good results. On the basis of our diagnosis, we performed 6 cycles of multi-drug adjuvant chemotherapy and then radiotherapy. After 3 years of surgery, there was no evidence of recurrence. However, careful observation may be required.

**Keywords:** Chest wall, child, monophasic type, sarcoma

### INTRODUCTION

Synovial sarcoma is a distinct subtype of soft tissue sarcomas (STS). It is reportedly the most frequent non-rhabdomyosarcomatous STS in children and adolescents, with around 30% of cases occurring in patients under 20 years old.<sup>1</sup> The disease is unique in its differentiation into 2 elements: epithelial cells with glandular components and spindle cells.<sup>2</sup>

Synovial sarcoma arises in the para-articular regions, mainly in the tendons, tendon sheaths, bursal structures, and less frequently in the fascial structures and ligaments.<sup>1</sup> Thoracic synovial sarcoma is more rare than its extra thoracic counterpart and may arise in the chest wall, pleura, mediastinum, heart, or lung.<sup>2</sup>

Long history of symptoms and heterogeneous clinical presentation sometimes delays diagnosis.

This article discusses the case of an adolescent who presented to the hospital with palpable mass of the upper right side of the anterior chest wall that appeared 5 months ago.

To our knowledge, there are limited publications about synovial sarcoma of the chest, even less in children. Misdiagnosis may have serious repercussions on therapeutic strategy.

A 12-year-old male presented to our pediatric surgery department with chief complaint of swelling accompanied by slight pain of the upper right side of the anterior chest wall since approximately 5 months. There was no context of prior trauma or previous injury. The patient had no history of fever, malaise, or weight loss. The patient had no family history of the disease.

On examination, the patient was conscious and oriented with no evidence of acute distress.

#### Corresponding author:

Fatma Bchini

✉fatma.bchini@etudiant-fmt.utm.tn

Received: July 8, 2021

Accepted: August 24, 2021

Content of this journal is licensed under a Creative Commons Attribution-NonCommercial 4.0 International License.



**Cite this article as:** Bchini F, Boughdir M, Laarif S, et al. Chest wall monophasic synovial sarcoma in a 12-year-old boy: A case report. *Turk Arch Pediatr.* 2022;57(1):111-113.

On physical examination, there was a noticeable asymmetric chest wall expansion with swelling noted at the upper right side of the anterior chest wall. This mass was well-constrained and extended from the right clavicle to the axillary region. The mass size was 6 cm. The rest of the examination was unremarkable.

Soft tissue US showed a retropectoral tissue mass that may suggest adenomegaly. The mass size was 50 × 30 mm (Figure 1).

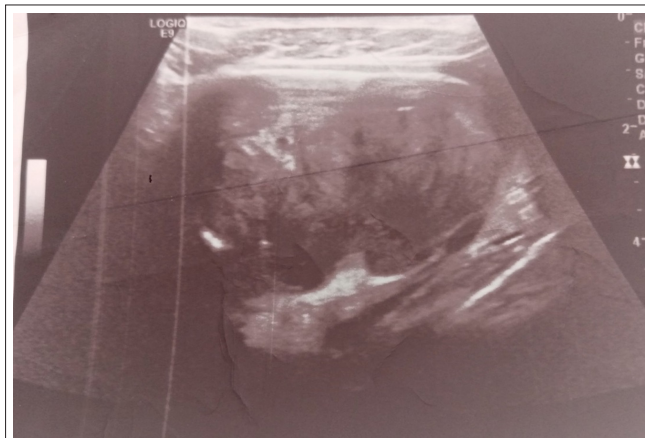
Thoracic computed tomography (CT), done 1 month later, showed a well-defined under right clavicle mass extended to the axillary region with heterogeneous enhancement. The mass size was 7 × 5 cm. Calcifications were detected.

The mass had close contact with the axillary artery and vein without any compression (Figures 2 and 3).

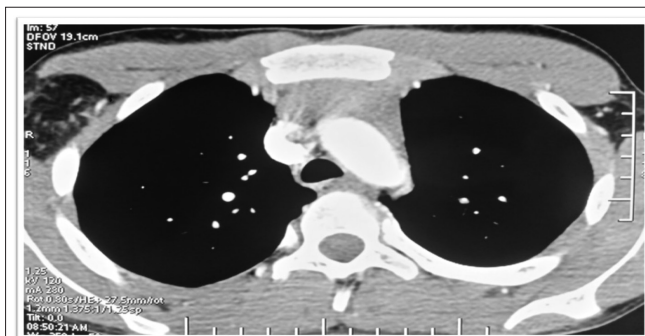An US-mass biopsy was performed.

Histopathological examination showed spindle cells with hyperchromatic nuclei.

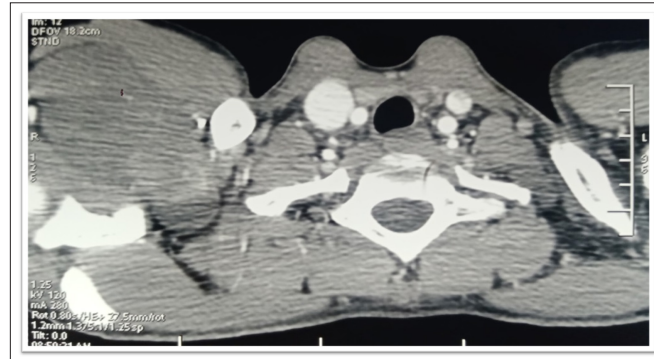The tumor cells showed immunoreactivity for beta-catenin. Other markers were also tested like epithelial membrane antigen (EMA), smooth muscle actin (SMA), cell antigen CD34 (CD34), and Panck. They were negative. This profile was suggesting fibromatosis .



**Figure 1.** Soft tissue ultrasound: a rectopectoral tissue mass.



**Figure 2.** Thoracic CT: showing a well-defined under right clavicle mass extended to the axillary region. The mass size was 7 × 5 cm. CT, computed tomography.



**Figure 3.** Thoracic CT: showing a well-defined under right clavicle mass extended to the axillary region. The mass size was 7 × 5 cm. CT, computed tomography.

We performed surgical resection. On surgical exploration, large mass was identified immediately on retropectoral. The mass was strongly adhered to several branches of the brachial plexus.

The tumor size was about 12 cm. It was a laborious task to retrieve such a mass. We believed that some tumor cells still remained in contact with the brachial plexus, but we could not remove them completely to save neurological function.

Macroscopic examination of the specimen (measuring 11 × 7 × 4 cm) revealed that it was firm and whitish in color. Histological examination showed proliferation of malignant spindle cells with no particular features. We observed positive immunostaining for beta-catenin, b cell lymphoma 2 (bcl-2), EMA, CD99, and panCK . The tumor was negative for Protein S100 (PS100) and caldesmone. The margin was free from tumor cells and no re-excision was needed.

This histological exam confirmed the diagnosis of synovial sarcoma monophasic type, grade 2 according to French Federation of Cancer Centers Sarcoma Group (FNCLCC).

Postoperatively, the patient had a rapidly developing loss of extension on the right side of the forearm, hand and fingers. Physical therapy was performed with good results.

On the basis of our diagnosis, we performed 6 cycles of multi-drug adjuvant chemotherapy with ifosfamide, and mesna. We administered, also, radiotherapy (total 54 Gy with a boost of 61 Gy which allowed a better local control).

Currently, (3 years after the operation), the patient is alive. He is followed-up regularly, and no local recurrence or metastasis is detected.

Last positron emission tomography (PET) scan in February 2021 showed no relapse.

## DISCUSSION

Synovial sarcoma is a STS subtype, which accounts for approximately 6% of all STS.<sup>3</sup> Synovial sarcomas occur at all ages, and primary tumors are localized throughout the body, with a predilection for the extremities of young adults.<sup>4</sup> Primary synovial sarcomas of the chest wall are extremely rare.

Synovial sarcomas cause a wide range of symptoms, including palpable lumps, painful masses, motor or sensory disturbance, indolent swellings, or pain without any identifiable bump.<sup>5</sup>

Baseline imaging encompasses US, magnetic resonance imaging, computed tomography, and in some instances, plain film radiographs. About half of radiographs, and particularly those associated with smaller lesions, can appear normal.<sup>6</sup>

In children, the therapeutic strategy is complex. But we think there is a correlation between the quality of surgery and overall survival and local recurrence.

Treatment of choice for synovial sarcoma of the chest wall as in all soft tissue sarcomas is multimodal combination of wide-to-radical resection, radiation therapy, and adjuvant chemotherapy following resection, and since synovial sarcoma is known to recur, a careful follow up is mandatory.<sup>7</sup>

Synovial sarcomas might metastasize to bone, liver, skin, the central nervous system, and even breast tissue.<sup>8</sup>

The main surgical principle is a bloc resection of the tumor and the biopsy tract. Adjuvant radiotherapy may be considered for patients with tumors exceeding 5 cm in size.<sup>9</sup>

Administration of adjuvant ifosfamide/doxorubicin-based Chemotherapy combination with cyclophosphamide (CTX) is recommended in children with synovial sarcoma, as these tumors rather resemble pediatric rhabdomyosarcoma than other STS-subtypes regarding response to CTX.<sup>10</sup>

In a cohort of 248 patients presenting synovial sarcoma, younger patients were associated with a significantly better cancer-specific survival (CSS) in the univariate setting. Likewise in the multivariate analysis, the significance prevailed, together with tumor size as independent prognostic factors regarding CSS.<sup>11</sup>

## CONCLUSION

We have reported our experience with a rare case of monophasic-type synovial sarcoma from the chest wall. This pathology requires multidisciplinary management. Radical surgery, if feasible and not mutilating, seems to improve prognosis.

**Informed Consent:** Written informed consent was obtained from the patient and his parents who agreed to take part in the study.

**Peer Review:** Externally peer-reviewed.

**Author Contributions:** Concept – F.B., M.B.; Design – A.D., R.K.; Supervision – N.K., Y.H.; Materials – R.B.A.; Data Collection and/or Processing – S.L.; Literature Search – S.T.; Writing Manuscript – F.B.; Critical Review – M.B.

**Conflict of Interest:** The authors have no conflict of interest to declare.

**Financial Disclosure:** The authors declared that this study has received no financial support.

## REFERENCES

- Okcu MF, Munsell M, Treuner J, et al. Synovial sarcoma of childhood and adolescence: a multicenter, multivariate analysis of outcome. *J Clin Oncol.* 2003;21(8):1602-1611. [CrossRef]
- Kelly AM, Frauenfelder T. Diseases of the Chest Wall, Pleura, and Diaphragm. In: Hodler J, Kubik-Huch RA, von Schulthess GK, éditeurs. *Diseases of the Chest, Breast, Heart and Vessels 2019-2022: Diagnostic and Interventional Imaging.* Springer; 2019. Disponible sur: Available at: <http://www.ncbi.nlm.nih.gov/books/NBK553862/>.
- Corey RM, Swett K, Ward WG. Epidemiology and survivorship of soft tissue sarcomas in adults: a national cancer database report. *Cancer Med.* 2014;3(5):1404-1415. [CrossRef]
- Vlenterie M, Litière S, Rizzo E, et al. Outcome of chemotherapy in advanced synovial sarcoma patients: review of 15 clinical trials from the European Organisation for Research and Treatment of Cancer Soft Tissue and Bone Sarcoma Group; setting a new landmark for studies in this entity. *Eur J Cancer.* 2016;58:62-72. [CrossRef]
- Chandrasekar CR, Wafa H, Grimer RJ, Carter SR, Tillman RM, Abudu A. The effect of an unplanned excision of a soft-tissue sarcoma on prognosis. *J Bone Joint Surg Br.* 2008;90(2):203-208. [CrossRef]
- Hickson M, McHugh K, McCarville B. Primary synovial sarcomas in the paediatric and young adult population: a pictorial review. *Eur J Rad.* 2020;133:109376. [CrossRef]
- Braham E, Aloui S, Aouadi S, Drira I, Kilani T, El Mezni F. Synovial sarcoma of the chest wall: a case report and literature review. *Ann Transl Med.* 2013;1(1):9. [CrossRef]
- Zeren H, Moran CA, Suster S, Fishback NF, Koss MN. Primary pulmonary sarcomas with features of monophasic synovial sarcoma: a clinicopathological, immunohistochemical, and ultrastructural study of 25 cases. *Hum Pathol.* 1995;26(5):474-480. [CrossRef]
- Hundahl S, Fahy B. Diagnosis and management of soft tissue sarcoma. *Ann Surg.* 2003;237(6):894. [CrossRef]
- Pappo AS, Fontanesi J, Luo X, et al. Synovial sarcoma in children and adolescents: the St Jude Children's Research Hospital experience. *J Clin Oncol.* 1994;12(11):2360-2366. [CrossRef]
- Smolle MA, Parry M, Jeys L, Abudu S, Grimer R. Synovial sarcoma: do children do better? *Eur J Surg Oncol.* 2019;45(2):254-260. [CrossRef]