

# FOLR1 Gene Variation With Adult-Onset Cerebral Folate Deficiency and Stable Clinical and MRI Features up to 2 Years

Carlo Manco, MD, Rosa Cortese, MD, PhD, Manfredi Alberti, Dr, Silvia Bianchi, PhD, Lucia Monti, MD, Nicola De Stefano, MD, PhD, and Carla Battisti, MD, PhD

**Correspondence**  
Dr. Cortese  
rosa.cortese@unisi.it

*Neurol Genet* 2023;9:e200104. doi:10.1212/NXG.0000000000200104

## Abstract

### Objectives

The objective of this case report was to describe the first report of *FOLR1* variants associated with adult-onset paucisymptomatic leukoencephalopathy associated with cerebral folate deficiency (CFD).

### Methods

Considering the patient's symptoms, a nonprogressive leukoencephalopathy was suspected. CSF 5-methyltetrahydrofolate levels were low (10 nmol/L, normal range 41–117). With no other identifiable causes, a genetic analysis was conducted, revealing a compound heterozygous *FOLR1* variation (c.45G>T and c. 493+2T>C).

### Results

A 47-year-old man with a history of drug and alcohol abuse was admitted to the hospital for double vision and postural instability. MRI of the brain was performed, which showed bilateral leukoencephalopathy. Diffusion tensor imaging revealed a diffuse reduction in fractional anisotropy, suggesting microstructural changes. MRI of the brain and overall clinical picture were stable on subsequent serial examinations.

### Discussion

Scientific evidence supports the deleterious effect of c.45G>T and c.493+2T>C variations on the folate receptor- $\alpha$  (FR $\alpha$ ) protein structure and function. The weakness of the expression and function of FR $\alpha$  without elimination of its function caused by specific compound heterozygous variations may explain the atypical features observed in our patient. Although rare, CFD should be considered in paucisymptomatic adult patients with stable diffuse MRI white matter changes.

## Introduction

*FOLR1* gene variations are commonly associated with cerebral folate deficiency (CFD), a rare neurologic syndrome characterized by low CSF concentration of 5-methyltetrahydrofolate (5-MTHF) despite normal peripheral folate metabolism.<sup>1</sup> CFD typically manifests in early infancy with symptoms, such as irritability, sleep disturbances, and subsequently progresses to severe epilepsy, cerebellar ataxia, and psychomotor retardation.<sup>1</sup> MRI of the brain usually shows diffuse, leukodystrophy-like, white matter changes. In children, treatment with oral calcium folinate or folic acid has shown improvement in clinical symptoms, as well as MRI and EEG abnormalities.<sup>1</sup> To date, clinical and imaging features associated with adult-onset CFD and *FOLR1* gene variations have not been described.

---

From the Centre for Precision and Translational Medicine (C.M., R.C., S.B., N.D.S., C.B.), Department of Medicine, Surgery and Neuroscience, University of Siena; Neurology Unit (M.A.), Department of Neurology and Human Movement Sciences, University Hospital of Siena; Department of Medical, Surgical and Neurological Science (M.A.), University of Siena; and Diagnostic and Functional Neuroimaging Unit (L.M.), Department of Neurology and Human Movement Sciences, University Hospital of Siena, Italy.

Go to [Neurology.org/NG](https://www.neurology.org/NG) for full disclosures. Funding information is provided at the end of the article.

The Article Processing Charge was funded by the authors.

This is an open access article distributed under the terms of the Creative Commons Attribution-NonCommercial-NoDerivatives License 4.0 (CC BY-NC-ND), which permits downloading and sharing the work provided it is properly cited. The work cannot be changed in any way or used commercially without permission from the journal.

## Glossary

**5-MTHF** = 5-methyltetrahydrofolate; **CFD** = cerebral folate deficiency; **DTI** = diffusion tensor imaging; **FR $\alpha$**  = folate receptor- $\alpha$ .

### Methods and Results

We report on a 47-year-old man who presented at the emergency department with a four-day history of slight double vision and postural instability. In his medical history, he reported psoriasis, drug abuse up to age 21 years and alcohol addiction for many years. The neurologic examination showed walking ataxia and vertical diplopia in the left/upper left gaze position. A first brain MRI showed diffuse, bilateral, and symmetric supratentorial hyperintensity on FLAIR images, without enhancement after gadolinium injection (Figure, A). MRI of the spinal cord was unremarkable. Diffusion-tensor imaging (DTI) was also acquired and showed a lower fractional anisotropy in both abnormal and normal-appearing white matter in our patient (Figure, C) when compared with the same brain regions of a sex-matched and age-matched healthy control (Figure, D).

During the hospitalization, the patient was tested for blood and urine biochemical routine, autoimmunity screening, the dosage of folate and lysosomal enzymes,  $\beta$ -galactocerebrosidase, pyruvate and lactate, and the assay of serum heavy metal: All measures were within normal ranges.

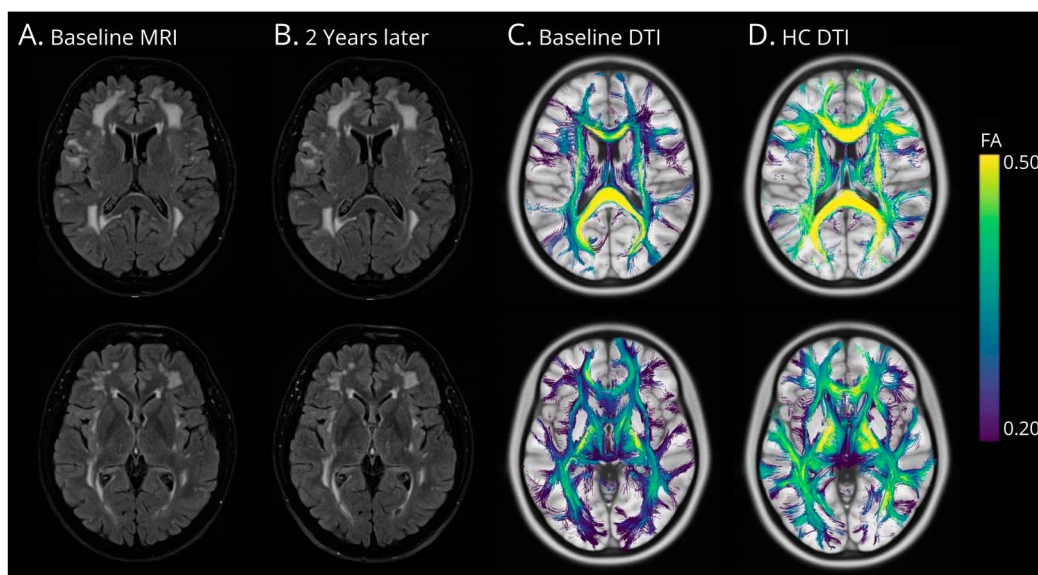
CSF analyses revealed a mild increase in protein levels (51,70 mg/dL, n.v. 20–40) with normal cell count. At 2 years of follow-up, the neurologic examination and brain MRI

performed were stable (Figure, B) than a nonprogressive leukoencephalopathy was hypothesized.<sup>2</sup> A further CSF analysis showed reduced 5-MTHF levels (10 nmol/L, normal values: 41–117), and genetic testing with next-generation sequencing of selected genes revealed the heterozygous variation of the *FOLR1* double gene (c.45G>T and c.493+2T>C); therefore, CFD was diagnosed. The patient's father, mother, and 2 daughters were also assessed. All were symptom-free, had normal neurological examination, and unremarkable blood tests. MRI results showed no abnormalities. The genetic analysis was performed also in the asymptomatic father, mother, and 2 daughters, with the father being a carrier of the variant c.45G > T and 2 daughters and mother being carriers of the c.493+2T>C variation. Written informed consent was obtained from the patient for the case presentation.

### Discussion

*FOLR1* gene variations are associated with CFD, an autosomal recessive disorder characterized by low CSF 5-MTHF concentrations, normal plasma folate values, and late infantile onset with severe developmental regression, epilepsy, and leukodystrophy.<sup>3,4</sup> Folic acid and folates are essential for neurodevelopment and myelin formation<sup>5,6</sup> after intestinal

**Figure** MRI FLAIR Axial Images Performed at Symptoms Onset and 2 Years Later and Correspondent Baseline Diffusion Tensor Imaging (DTI) Analysis Comparing the Patient With a Sex-Matched and Age-Matched Healthy Control (HC) Subject



MRI of the brain showed diffuse, bilateral, and symmetric supratentorial hyperintensities on FLAIR images, without enhancement after gadolinium injection (A) stable 2 years later (B). DTI revealed a diffuse decrease in fractional anisotropy in the CFD patient (C) when compared with a HC (D), suggesting a widespread microstructural damage beyond the lesional tissue.

absorption and are reduced, methylated, and enters the circulation as 5-MTHF. The *FOLR1* gene encodes for the folate receptor- $\alpha$  (FR $\alpha$ ), which is essential in allowing 5-MTHF to cross the blood-brain barrier.<sup>7</sup>

Our patient is the first reported case in the literature of a compound heterozygous variation of *FOLR1* associated with adult-onset leukoencephalopathy and clinical paucisymptomatic picture. Based on the available data, patient's conditions have remained stable over time in the absence of treatment. Despite the mild clinical involvement, MRI changes were diffuse and DTI analysis showed the presence of diffuse microstructural changes beyond lesional white matter.

From a genetic standpoint, in our patient, we identified 2 genetic variations. The first variation is the c.45G>T variation, which is categorized as a missense variation. The second variation is the c.493+2T>C variation, affecting the donor site of the splice. In the ClinVar database, the c.45G>T variation has been reported with supporting evidence indicating its deleterious effects on protein structure and function, as suggested by silicon analysis. In addition, Grapp et al. conducted a study using FR $\alpha$  expression model cell systems and fibroblasts from a cohort of patients with missense variations in the *FOLR1* gene. Their findings revealed that although FR $\alpha$  was expressed, it was not properly localized to the cell membrane. Instead, it was misdirected to various intracellular compartments, leading to a reduction in folic acid binding, thus compromising its primary target.<sup>7</sup>

The c.493+2T>C variation, despite having a total frequency of 0.3123% in the general population according to the genome aggregation database, could potentially lead to the loss of protein function and contribute to the development of the disease. However, conflicting data regarding the true pathogenicity of this variation have been reported in the literature.<sup>8,9</sup> Prediction software for splice alterations, such as BDGP and ESEfinder, suggests that the c.493+2T>C variation may disrupt or weaken the native splice donor site.

Therefore, one possible explanation for the atypical features observed in our patient could be that the presence of these specific compound heterozygous variations weakens the expression and function of FR $\alpha$  without completely eliminating its function. This partial impairment could result in a milder phenotype with late-onset symptoms and a relatively limited number of symptoms (pauci-symptomatic phenotype). The variations may cause a blurred picture of the disease presentation, deviating from the typical pattern seen in cases with a complete loss of function. This phenomenon highlights the complexity of genotype-phenotype correlations and suggests that variations in the degree of protein impairment can lead to diverse clinical manifestations.

In conclusion, this clinical case is an example of how variations in the *FOLR1* gene can be present in adults with limited clinical findings and a stable disease course. Thus, it highlights the importance of considering the diagnosis of CFD in adult patients

presenting with neurologic symptoms and exhibiting a leukodystrophy pattern on MRI. This case underscores the need for increased awareness and recognition of CFD in the adult population to ensure appropriate diagnosis and management of this condition.

## Study Funding

The authors report no targeted funding.

## Disclosure

The authors report no relevant disclosures. Go to [Neurology.org/NG](https://www.neurology.org/NG) for full disclosures.

## Publication History

Received by *Neurology: Genetics* July 21, 2023. Accepted in final form September 1, 2023. Submitted and externally peer reviewed. The handling editor was Editor Stefan M. Pulst, MD, Dr med, FAAN.

## Appendix Authors

Name	Location	Contribution
<b>Carlo Manco, MD</b>	Centre for Precision and Translational Medicine, Department of Medicine, Surgery and Neuroscience, University of Siena, Italy	Drafting/revision of the manuscript for content, including medical writing for content; major role in the acquisition of data; study concept or design; analysis or interpretation of data
<b>Rosa Cortese, MD, PhD</b>	Centre for Precision and Translational Medicine, Department of Medicine, Surgery and Neuroscience, University of Siena, Italy	Drafting/revision of the manuscript for content, including medical writing for content; analysis or interpretation of data
<b>Manfredi Alberti, Dr</b>	Neurology Unit, Department of Neurology and Human Movement Sciences, University Hospital of Siena; Department of Medical, Surgical and Neurological Science, University of Siena, Italy	Major role in the acquisition of data, analysis or interpretation of data
<b>Silvia Bianchi, PhD</b>	Centre for Precision and Translational Medicine, Department of Medicine, Surgery and Neuroscience, University of Siena, Italy	Major role in the acquisition of data; analysis or interpretation of data
<b>Lucia Monti, MD</b>	Diagnostic and Functional Neuroimaging Unit, Department of Neurology and Human Movement Sciences, University Hospital of Siena, Italy	Analysis or interpretation of data
<b>Nicola De Stefano, MD, PhD</b>	Centre for Precision and Translational Medicine, Department of Medicine, Surgery and Neuroscience, University of Siena, Italy	Drafting/revision of the manuscript for content, including medical writing for content; study concept or design
<b>Carla Battisti, MD, PhD</b>	Centre for Precision and Translational Medicine, Department of Medicine, Surgery and Neuroscience, University of Siena, Italy	Drafting/revision of the manuscript for content, including medical writing for content; study concept or design

## References

1. Hyland K, Shoffner J, Heales SJ. Cerebral folate deficiency. *J Inherit Metab Dis*. 2010; 33(S):S63-S70. doi:10.1007/s10545-010-9159-6

2. Nicolai J, van Kempen MJ, Postma AA. Teaching Neuro Images: white matter hypomyelination and progressive calcifications in cerebral folate deficiency. *Neurology*. 2016;87(1):e4-e5. doi:10.1212/WNL.0000000000002805
3. Steinfeld R, Grapp M, Kraetzner R, et al. Folate receptor alpha defect causes cerebral folate transport deficiency: a treatable neurodegenerative disorder associated with disturbed myelin metabolism. *Am J Hum Genet*. 2009;85(3):354-363. doi:10.1016/j.ajhg.2009.08.005
4. Molero-Luis M, Serrano M, O'Callaghan MM, et al. Clinical, etiological and therapeutic aspects of cerebral folate deficiency. *Expert Rev Neurother*. 2015;15(7):793-802. doi:10.1586/14737175.2015.1055322
5. Ramaekers VT, Quadros EV. Cerebral folate deficiency syndrome: early diagnosis, intervention and treatment strategies. *Nutrients*. 2022;14(15):3096. doi:10.3390/nu14153096
6. Grapp M, Just IA, Linnankivi T, et al. Molecular characterization of folate receptor 1 variations delineates cerebral folate transport deficiency. *Brain*. 2012;135(Pt 7):2022-2031. doi:10.1093/brain/aws122
7. Spector R, Johanson CE. Vectorial ligand transport through mammalian choroid plexus. *Pharm Res*. 2010;27(10):2054-2062. doi:10.1007/S11095-010-0162-2
8. Najmabadi H, Hu H, Garshasbi M, et al. Deep sequencing reveals 50 novel genes for recessive cognitive disorders. *Nature*. 2011;478(7367):57-63. doi:10.1038/nature10423
9. Ramaekers VT, Segers K, Sequeira JM, et al. Genetic assessment and folate receptor autoantibodies in infantile-onset cerebral folate deficiency (CFD) syndrome. *Mol Genet Metab*. 2018;124(1):87-93. doi:10.1016/J.YMGME.2018.03.001