



Ethambutol-resistant *Mycobacterium kansasii* cervical lymphadenitis in an immunocompetent adult patient: A case report and literature review

Víctor Asensi^{a,e,*}, Juan J. Palacios^b, Maria Rivas-Carmenado^{a,e}, Tomás Suárez-Zarracina^{a,e}, Enrique Garcia-Carus^{a,e}, Luis M. Fernández^c, Héctor E. Torres^c, Joshua Fierer^d, José A. Carton^{a,e}

^a Infectious Diseases Unit, Hospital Universitario Central de Asturias, Oviedo University School of Medicine, Oviedo, Spain

^b Regional Mycobacterial Unit, Department of Microbiology, Hospital Universitario Central de Asturias, Oviedo University School of Medicine, Oviedo, Spain

^c Department of Pathology, Hospital Universitario Central de Asturias, Oviedo University School of Medicine, Oviedo, Spain

^d VA San Diego Healthcare System, San Diego, California, USA, University of California San Diego School of Medicine, San Diego, USA

^e Group of Translational Research in Infectious Diseases, Instituto de Investigación Sanitaria del Principado de Asturias (ISPA), Oviedo, Spain

ARTICLE INFO

Keywords:

Mycobacterium kansasii
Cervical lymphadenitis
Immunocompetent
Resistance
Ethambutol
Quantiferon

ABSTRACT

Mycobacterium kansasii extrapulmonary infections are infrequent in immunocompetent adults. Rifampin (RIF), clarithromycin (CLR), isoniazid (INH) and ethambutol (EMB) are included in all the standard regimens against *M. kansasii*. We report a case of a healthy 65-year-old male farmer who presented with isolated right supraclavicular lymphadenopathy. The lymph node FNA showed acid-fast bacilli and granulomatous inflammation. Quantiferon TB Gold test, HIV serology, and functional immunological studies were all negative or normal. He was put on a standard 4 drugs anti-tuberculous regimen that was switched to RIF + CLR + INH after the Microbiology lab demonstrated an EMB-resistant *Mycobacterium kansasii* isotype I strain. The patient was cured after 12 months of therapy. This is the 6th reported case of *M. kansasii* extrapulmonary lymphadenitis in an immunocompetent adult and the 2nd showing EMB resistance in the world literature. Antimycobacterial regimens against *M. kansasii*, classically resistant to pyrazinamide (PZA) might also exclude EMB due to its increasing resistance in Europe. A 612 months therapy with at least 2 effective antimycobacterial drugs including RIF + CLR might be enough to treat extrapulmonary *M. kansasii* infections in immunocompetents.

1. Introduction

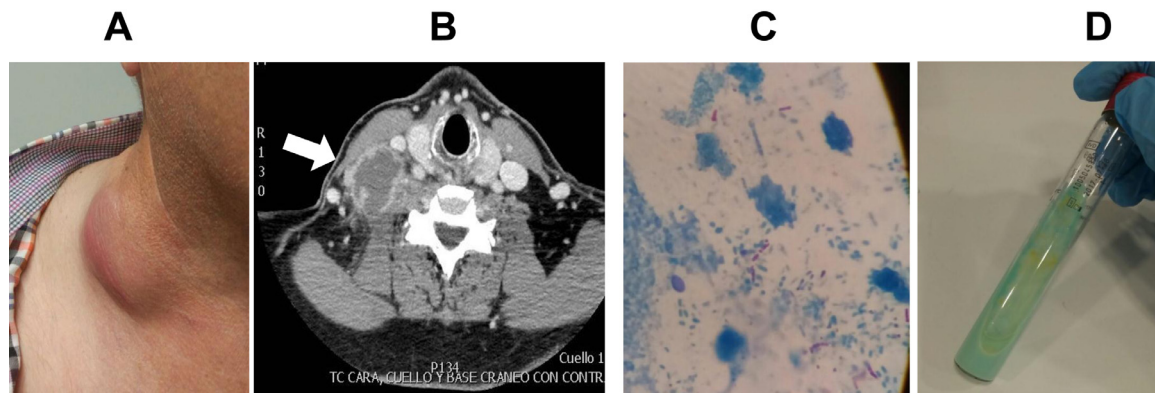
Mycobacterium kansasii is the second most commonly isolated of pathogenic non-tuberculous mycobacteria (NTM), after *Mycobacterium avium complex* (MAC) in patients with the acquired immunodeficiency syndrome (AIDS), and it is the most virulent [1]. *M. kansasii* usually causes lung disease. Extrapulmonary involvement is rare in immunocompetent adults, but does occur in immunocompetent children and in HIV-infected and other immunosuppressed adults [1–3]. *M. kansasii* is probably the easiest of NTM to treat effectively due to similarities with *M. tuberculosis*. *M. kansasii* is classically resistant to pyrazinamide (PZA) and sensitive to rifampin (RIF), isoniazid (INH), ethambutol (EMB), macrolides and aminoglycosides [4,5].

We report here a case of an adult immunocompetent patient with isolated supraclavicular lymphadenitis due to *M. kansasii* resistant to EMB, that was successfully treated with 12 months of RIF + INH + clarithromycin (CLR) therapy.

2. Case presentation

A 65-year-old male farmer with mild bronchiectasis was referred to our hospital with a 3 months history of asymptomatic neck mass. The patient was in a perfect state of health except for the cervical lump. He did not have serious infections in the past. A family history of opportunistic infections was not reported. Physical exam revealed a weight of 106 kg and an enlarged right supraclavicular tumor. The mass was soft and not painful to pressure with overlying erythema (Fig. 1A). Cervical-thoracic computed tomography (CT) confirmed the presence of right supraclavicular necrotic lymphadenopathy, 36 × 45.7 × 67 mm in diameter (Fig. 1B). No other CT cervical or thoracic lymphadenopathies or pulmonary lesions were observed except for mild bibasilar bronchiectasis. A fine needle aspiration (FNA) procedure was performed showing 1–9 acid-fast bacilli (AFB)/100 high power fields by Ziehl-Neelsen staining of the aspirated pus (Fig. 1C). FNA cytology showed granulomatous inflammation. Sputum Ziehl-Neelsen staining, quantitative PCR (qPCR) and culture in Löwenstein-Jensen medium were

^[*] Corresponding author at: Infectious Diseases Unit, Hospital Universitario Central de Asturias, Avenida de Roma s/n, 33011 Oviedo, Spain.
E-mail address: vasensia@gmail.com (V. Asensi).



[Fig. 1]. . A. Right supraclavicular lymphadenopathy, before starting anti-tuberculous therapy; B. Large right necrotic supraclavicular lymph node enlargement (white arrow). The adenopathy compressed the right internal jugular and right brachiocephalic trunk; C. A fine needle aspiration (FNA) procedure was performed showing 1–9 acid-fast bacilli (AFB)/100 high power fields by Ziehl-Neelsen staining of the aspirated pus; D. Yellow, dry colonies of *M. kansasii* grew in Löwenstein-Jensen medium after 2 weeks after transference from Bactec MGIT 960 medium.

negative for mycobacteria. A tentative diagnosis of tuberculous lymphadenitis was made and the patient was started on oral INH 300 mg + RIF 600 mg + PZA 1500 mg + EMB 15 mg/kg daily. Routine hemogram and biochemistry values were normal with an ESR of 25 mm/h, and C-reactive protein (C-RP) of 0.7 mg/dl. Quantiferon TB Gold assay and HIV serology were negative.

Blood levels of IgG, IgM, IgA, complement proteins and granulocytes were normal. Fluorescent-activated cell sorter (FACS) analysis of lymphocytic subpopulations in peripheral blood was normal: CD3⁺ 703/μl (70%), CD4⁺ 367/μl (37%), CD8⁺ 262/μl (26%), ratio CD4⁺/CD8⁺ 1.4. Lymphocytic response to the mitogens phytohemagglutinin, pokeweed, to phorbol myristate acetate + ionomycin and to anti-CD3 monoclonal antibody was normal. Mixed lymphocyte culture stimulated with alloantigens was also normal. A nitroblue tetrazolium test (NBT) done with the patient's peripheral WBC was also normal. All these studies ruled out an underlying immunodeficiency.

Two weeks later the FNA pus sample grew *M. kansasii*, confirmed by MALDI-TOF mass spectrophotometry (Fig. 1D). A subtype I strain was identified by molecular techniques (INNO-LiPA, Mycobacteria V2, Fujirebio, Gent, Belgium; and GenoType Mycobacterium CM/AS, Hain Lab., Nehren, Germany). Broth microdilution, and/or direct agar proportion method and/or Etest assays showed that the isolate was sensitive to INH, RIF, CLR, streptomycin (STR), doxycycline (DOX), moxifloxacin, (MXF), and linezolid (LZD), and resistant to PZA, EMB, amikacin (AMK), kanamycin (KAN), ciprofloxacin (CIP), levofloxacin (LVX) and tigecycline (TGC). His therapy was switched to INH 300 mg + RIF 600 mg + CLR 500 mg/12 h, which was maintained for 12 months. Oral prednisone 30 mg/d was added during the first 3 months of therapy. A small post-FNA right cervical fistula remained for some months, disappearing along with the neck mass after the first 6 months of therapy. Seven months after the end of treatment he remains well.

3. Discussion

Ours is the 6th reported case of *M. kansasii* extrapulmonary lymphadenitis in immunocompetent adults; 5 cases in children under 18 have also been reported. (Table 1) [6–14]. Sites of dissemination included cervical and mediastinal lymph nodes, skin, brain, soft tissue, joint, and peritoneum. Two patients had multiple non-nodal sites of involvement; one had concomitant *Salmonella* bacteremia suggesting an acquired defect in T cell immunity, and the work-up for immunodeficiency was not reported for the second case, who relapsed after treatment with INH, RIF and EMB [10,12].

Our patient had subtype I *M. kansasii* lymphadenitis, the subtype most frequently found in humans and the most pathogenic, but rarely

isolated from the environment [11,15].

This is intriguing because he was a farmer and might be exposed to other serotypes of *M. kansasii* by outdoors exposure to contaminated soil and water via aerosol or cutaneous contact or by drinking contaminated lake, river, or even tap water [1–3]. However, since the node was supraclavicular, it is more likely to have spread from a lung focus not seen in the cervico-thoracic CT. Drinking contaminated spring water while farming or eating raw vegetables in contact with contaminated water or soil are other possibilities of having acquired *M. kansasii* infection by this patient.

Quantiferon–TB Gold test was negative in our immunocompetent patient. This is interesting because *M. kansasii* is one of the antigens making the Quantiferon–TB Gold test, a peptide cocktail stimulating the proteins ESAT-6, CFP-10 and TB7.7. The Quantiferon–TB Gold might be positive in *M. kansasii* infections [16]. However only 52% of the patients with *M. kansasii* disease were positive for the test in one Japanese study [17].

The *M. kansasii* strain from our case showed EMB resistance by microdilution, direct agar proportion and Etest drug susceptibility methods. CIP, LVX AMK, KAN, and TGC resistances were also observed. Very recently Bakulat et al. reported that *M. kansasii* EMB resistance assessed by broth microdilution and Etest was observed in 83/85 (97.7%) of different subtypes (I to VI, I/II and IIB) of *M. kansasii* strains from 7 European countries and South Korea [18]. It will be of interest to determine if this high “*in vitro*” resistance of *M. kansasii* to EMB is confirmed in follow-up studies. Resistances to CIP (17/85, 20%) and CLR (1/85, 1.2%) were also reported in the same study.

A case of EMB and INH-resistant *M. kansasii* chronic tenosynovitis in an immunocompetent was reported in 2018 from the USA. The patient, with previous chemical hand skin damage had continuous exposure to a freshwater lake. He was cured with 6 months of CLR ± RIF therapy [19].

All the seven *M. kansasii* lymphadenitis cases in immunocompetent hosts reported in which the outcome was available were cured. Four of them received 6–18 months of EMB along with RIF and INH and/or CLR and two also underwent surgery with success.

It is not clear presently that there is a gold standard therapy for *M. kansasii* infection. The use of a rifamycin ± a macrolide seems reasonable with the potential addition of EMB [4]. However, the frequency of EMB resistance needs to be confirmed in additional studies. Some additional caution is also needed because although the European resistance rate to CLR is very low, a 26.8% resistance of *M. kansasii* subtype I to CLR has been recently reported from strains isolated in China [20].

Table 1]
Clinical characteristics and outcomes of the reported *Mycobacterium kansasii* lymphadenitis in immunocompetent patients.

Reference/ Year	Country	Number of cases	Race	Age (years) /Gender	Symptoms	Lymphadenitis site	Other organs involved	Culture source	M. kansasii subtype	Comorbidities	EMB sensitivity	Therapy	Duration (months)	Outcome
Kanlikama et al.1993 ⁶	Turkey	2	European	13.3/NA	Neck mass	Submandibular	No	LN	NA	No	NA	INH+RIF+ EMB	NA	Cure
Flint et al.2000 ⁷	New Zealand	1	European	2.2/NA	Neck mass	NA	NA	NA	NA	NA	NA	EMB+ CLR+ surgery	NA	NA
Koth et al.2001 ⁸	France	1	European	79/F	Fever, cough, itching, night sweats	Mediastinal	Skin	LN	NA	No	NA	INH+RIF+EMB	NA	NA
de Juan et al.2002 ⁹	Spain	1	European	2/M	Neck mass + spontaneous fistula	Left lateral cervical	No	LN	NA	No	Sensitive	CLR + EMB	6	Cure
Tabatabael et al.2007 ¹⁰	USA	1	European	74/M	Fever, somnolence, mental status changes	Left supraclavicular, paratracheal, pretracheal, hilar	Brain	LN	NA	Diabetes, alcohol abuse	Sensitive	INH+RIF+ EMB	18	Cure
Salles et al.2007 ¹¹	France	1	European	56/F	Neck mass	Right parotid, submaxillary	No	LN	IV	No	Sensitive	RIF+ EMB+ CLR	NA	NA
Hsiao et al.2014 ¹²	Taiwan	1	Chinese	67/M	Neck mass	Cervical, abdomen	Soft tissue, lung, joint, peritoneum	LN	NA	Hypothyroidism/ Salmonella 09 (group D) infection	Sensitive	INH+ RIF+ EMB	18	Cure/ Relapse/ Permanent cure
Blanc et al.2016 ¹³	France	1	NA	Adult, NA age and gender	Neck mass	Cervical	No	NA	NA	NA	NA	NA	11	Probable cure
Loizos et al. 2018 ¹⁴	Cyprus	1	European	17/M	Neck mass	Cervical	No	LN	NA	No	NA	RIF+ CLR+ surgery	2	Cure
Asensi et al.	Spain	1	European	65/M	Neck mass + post-FNA fistula	Right supraclavicular	No	LN	I	Bronchiectasis	Resistant	INH+ RIF+ CLR	12	Cure

INH = isoniazid; RIF = rifampin; EMB = ethambutol; CLR = clarythromycin; FNA = fine needle aspiration; NA = not available; M = male, F = female; LN = lymph node.

Availability of data and materials

The clinical, image and microbiological data supporting this work are included in the article.

Ethics approval and consent to participate

This was an observational study, in which the patient underwent routine clinical care for *M. kansasii* lymphadenitis, without any change in its management or specific determinations or procedures. Therefore, no formal written informed consent was obtained from the patient. The Research Ethics Committee of the Principality of Asturias granted a formal waiver of ethical approval for this study.

The patients has signed a Hospital Universitario Central de Asturias (HUCA) written consent form for publication of his clinical data and images. Abiding by the Declaration of Helsinki the anonymity of the patient was preserved.

CRediT authorship contribution statement

Víctor Asensi: Conceptualization, Formal analysis, Data curation. **Juan J. Palacios:** Funding acquisition, Formal analysis, Data curation. **Maria Rivas-Carmenado:** Funding acquisition. **Tomás Suárez-Zarracina:** Funding acquisition. **Enrique García-Carus:** Funding acquisition. **Luis M. Fernández:** Funding acquisition. **Héctor E. Torres:** Funding acquisition. **Joshua Fierer:** Writing - original draft, Writing - review & editing. **José A. Carton:** Conceptualization.

Declaration of Competing Interest

The authors declare that they have no conflict of interest.

References

- [1] Horsburgh Jr. CR, Selik RM. The epidemiology of disseminated nontuberculous mycobacterial infection in the acquired immunodeficiency syndrome (AIDS). *Am Rev Respir Dis* 1989;139:4–7. <https://doi.org/10.1164/ajrccm/139.1.4>.
- [2] Bittner MJ, Horowitz EA, Safanek TJ, Preheim LC. Emergence of *Mycobacterium kansasii* as the leading mycobacterial pathogen isolated over a 20-year period at a Midwestern Veterans Affairs hospital. *Clin Infect Dis* 1996;22:1109–10. <https://doi.org/10.1093/clinids/22.6.1109>.
- [3] Bloch KC, Zwerling L, Pletcher MJ, Hahn JA, Gerberding JL, Ostroff SM, Vugia DJ, Reingold AL. Incidence and clinical implications of isolation of *Mycobacterium kansasii*: results of a 5-year, population-based study. *Ann Intern Med* 1998;129:698–704. <https://doi.org/10.7326/0003-4819-129-9-199811010-00004>.
- [4] Griffith DE. Management of disease due to *Mycobacterium kansasii*. *Clin Chest Med* 2002;23:613–21.
- [5] Brown-Elliott BA, Nash KA, Wallace Jr. RJ. Antimicrobial susceptibility testing, drug resistance mechanisms and therapy of infections with nontuberculous mycobacteria. *Clin Microbiol Rev* 2012;25:545–82. <https://doi.org/10.1128/CMR.05030-11>.
- [6] Kanlikama M, Özahinoglu C, Akan E, Özcan K. Mycobacterial species causing cervicofacial infection in Turkey. *Eur Arch Otorhinolaryngol* 1993;250:237–9.
- [7] Flint D, Mahadevan M, Barber C, Grayson D, Small R. Cervical lymphadenitis due to non-tuberculous mycobacteria: surgical treatment and review. *Int J Pediatr Otorhinolaryngol* 2000;53:187–94.
- [8] Kotb R, Dhôte R, Garcia-Ricart F, Permal S, Carlotti A, Arfi C, Christoforov B. Cutaneous and mediastinal lymphadenitis due to *Mycobacterium kansasii*. *J Infect* 2001;42:277–8. <https://doi.org/10.1053/jinf.2000.0800>.
- [9] de Juan Martín F, Marin Bravo MC, Bouthelier Moreno M, Lezcana Carrera MA, Zubiri Ara L, Adiego Leza MI. Infección por micobacterias no tuberculosas en inmunocompetentes. *An Esp Pediatr* 2002;56:357–9.
- [10] Tabatabaei N, Stout J, Goldschmidt-Clermont P, Murdoch D. Central nervous system infection and cutaneous lymphadenitis due to *Mycobacterium kansasii* in an immunocompetent patient. *Infection* 2007;4:291–4. <https://doi.org/10.1007/s15010-007-6208-7>.
- [11] Salles Y, Fabre M, Guitterez MC, Chaudier B, Soler C. Cervical adenitis caused by *Mycobacterium kansasii*: advantage of the INNO-LIPA V2 test in diagnosis of non-tuberculous mycobacterial diseases. *Pathol Biol (Paris)* 2007;55:543–5. <https://doi.org/10.1016/j.patbio.2007.08.008>.
- [12] Hsiao CH, Lai CC, Hsueh PR. High recurrence rate of lymphadenitis due to non-tuberculous mycobacteria and its association with concurrent *Salmonella* infection in Taiwan. *J Microbiol, Immunol Infect* 2014;47:217–21. <https://doi.org/10.1016/j.jmii.2012.11.003>.
- [13] Blanc P, Dutronc H, Peuchant O, Dauchy F-A, Cazanave C, Neau D, et al. Nontuberculous mycobacterial infections in a French hospital: a 12-year retrospective study. *PLoS ONE* 2016;11:e0168290. <https://doi.org/10.1371/journal.pone.0168290>.
- [14] Loizos A, Soteriades ES, Pieridou D, Koliou MG. Lymphadenitis by non-tuberculous mycobacteria in children. *Pediatr Int* 2018;60:1062–7. <https://doi.org/10.1111/ped.13708>.
- [15] Taillard C, Greub G, Weber R, Pfyffer GE, Bodmer T, Zimmerli S, Frei R, Bassetti S, Rohner P, Piffaretti JC, Bernasconi E, Bille J, Telenti A, Prod'homme G. Clinical implications of *Mycobacterium kansasii* species heterogeneity: Swiss National Survey. *J Clin Microbiol* 2003;41:1240–4. <https://doi.org/10.1128/jcm.41.3.1240-1244.2003>.
- [16] Quantiferon –TB gold (QFT) elisa package insert 08/2016. QUIAGEN, Germantown, MD, USA. Available at: http://www.quantiferon.com/wp-content/uploads/2017/04/English_QFT_ELISA_R04_082016.pdf.
- [17] Kobashi Y, Mouri K, Yagi S, Obase Y, Miyashita N, Okimoto N, Matsushima T, Kageoka T, Oka M. Clinical evaluation of the Quantiferon-TB Gold test in patients with non-tuberculous mycobacterial disease. *Int J Tuberc Dis* 2009;13:1422–6.
- [18] Bakula Z, Modrzejewska M, Pennings L, Proboszcz M, Safianowska A, Bielecki J, van Ingen J, Jagielski T. Drug susceptibility profiling and genetic determinants of drug resistance in *Mycobacterium kansasii*. *Antimicrob Agents Chemother* 2018;62:e01788. <https://doi.org/10.1128/AAC.01788-17>. pii: 17.
- [19] Wang M, Berry M, Lehto-Hoffman A, Vi L, Ramessar N. Chronic tenosynovitis due to *Mycobacterium kansasii* in an immunocompetent host. *Case Rep Infect Dis* 2018;3:297531. <https://doi.org/10.1155/2018/3297531>.
- [20] Li Y, Pang Y, Tong X, Zheng H, Zhao Y, Wang C. *Mycobacterium kansasii* subtype I is associated with clarithromycin resistance in China. *Front Microbiol* 2016;7:2097. <https://doi.org/10.3389/fmicb.2016.02097>.