



Since January 2020 Elsevier has created a COVID-19 resource centre with free information in English and Mandarin on the novel coronavirus COVID-19. The COVID-19 resource centre is hosted on Elsevier Connect, the company's public news and information website.

Elsevier hereby grants permission to make all its COVID-19-related research that is available on the COVID-19 resource centre - including this research content - immediately available in PubMed Central and other publicly funded repositories, such as the WHO COVID database with rights for unrestricted research re-use and analyses in any form or by any means with acknowledgement of the original source. These permissions are granted for free by Elsevier for as long as the COVID-19 resource centre remains active.

Effects of open rhinoplasty on upper lip position in profile and frontal views

F. Tosan^a, M. Esmaelinejad^{b,*}, R. Ghorbani^{c,d}

^a Private Practitioner, Tehran, Iran

^b Department Head, Department of Oral and Maxillofacial Surgery, School of Dentistry, Semnan University of Medical Sciences, Semnan, Iran

^c Social Determinants of Health Research Center, Semnan University of Medical Sciences, Semnan, Iran

^d Epidemiology and Biostatistics Department, Faculty of Medicine, Semnan University of Medical Sciences, Semnan, Iran

Accepted 10 August 2020

Available online 15 August 2020

Abstract

Examining the upper lip position is a key indicator of facial beauty. This study aimed to examine the upper lip position following cosmetic rhinoplasty at the frontal and profile views. The medical records of 67 patients who underwent rhinoplasty with no history of any facial skeletal surgery were obtained from archives. Complete preoperative and postoperative photos including the profile view at rest and the frontal view at rest, were prepared and analysed using Adobe Photoshop CC 2015 software. Interpupillary distances of two eyes in frontal views and Glabella to Pogonion (POG) distance in profile views were considered as fixed landmarks to calibrate the preoperative and postoperative photos. Upper lip length, subnasal area, and vermilion points were marked and compared between preoperative and postoperative photos. Data analysis was carried out using one-sample *t*-test and $p < 0.05\%$ was considered as the significant level. Lip length (frontal view) was increased in 46 subjects. There were changes in the profile view of vermilion and subnasal positions in 56 patients and 53 patients, respectively. In surgical procedures on columella strut, maxillary augment, alar resection, spreader graft, columella retraction, and depressor septi muscle release, vermilion and subnasal protrusion in the profile view was statistically significant and lip length increased significantly in the frontal view. In tip rotation surgical techniques, the vermilion and subnasal position showed also significant protrusion. The depressor septi muscle cutting methods had only led to a significant protrusion of the vermilion position and upper lip length. Despite all covariants interfering in rhinoplasty, this cosmetic surgery most often may increase maxillary lip length and helps that maxilla look more protruded.

© 2020 The British Association of Oral and Maxillofacial Surgeons. Published by Elsevier Ltd. All rights reserved.

Keywords: Graft; Lip; Maxilla; Rhinoplasty

Introduction

Facial beauty as an important indicator has always been of human interest; however due to the ambiguous nature of beauty it is difficult to find a single definition for it. But the upper lip position is always considered as a determinant of beauty.¹ The ideal upper lip position in women is when 1–2 mm of gingiva is seen during maximum smile and this position is slightly lower than the above distance in men.² The most important muscles involved in the upper lip position include

levator labii superioris alaeque nasi (LLSAN) and depressor septi nasi (DSN), which are manipulated usually in rhinoplasty.³

Cosmetic nose surgery is one of the most popular cosmetic surgeries and plays a significant role in a change in facial aesthetic proportions.⁴ Moreover, considering the variety of rhinoplasty techniques which are involved in manipulating the tissues adjacent to the lip; it is expected nose cosmetic surgery, as one of the determinants of facial beauty, affects the upper lip position.

Previous studies examining post-rhinoplasty changes in upper lip position in the frontal view showed that insertion of the columella strut, extended spreader graft, and DSN transection decrease the upper lip height and reduce maxillary anterior incisors show during smiling.⁵

Considering that previous studies have only investigated upper lip position changes in the frontal view, the effects of rhinoplasty

* Corresponding author at: Department of Oral and Maxillofacial Surgery, School of Dentistry, Semnan University of Medical Sciences, Semnan, Iran. Tel.: +98 23 33 34 7 86; fax: +98 23 33 33 17 29.

E-mail address: esmaelnejad@gmail.com (M. Esmaelinejad).

on the upper lip position in profile view have not been examined. Moreover, considering that rhinoplasty can affect the upper lip position and improve the patient's profile by using various grafts, such as premaxillary and other augmentation-based treatments. Therefore, examining the upper lip position as an influential indicator of facial and smile beauty as well as factors affecting its position are becoming more important.⁶

On the other hand, the patient and, in turn, the surgeons are always worried about the surgical outcomes.⁷ Therefore, potential dissatisfaction of the patients following rhinoplasty can be reduced by considering the upper lip position before the surgical procedure and the surgical effects on the lip position as an influential indicator on treatment outcomes.

Attempts were made in the present study to investigate the effects of open rhinoplasty on the upper lip length and position simultaneously from the frontal and profile views.

Materials and methods

This historic cohort study was executed between December 2018 and July 2019. The medical records of 67 patients underwent open rhinoplasty more than 6 months ago without any facial skeletal surgery obtained from the archives. Complete preoperative photographs including a profile view and a frontal view at rest were selected. Then new photographs were taken in the same views. The photographs had to be taken at the same position as recorded in the preoperative profiles. The new photos were analysed by Adobe Photoshop CC software (2015 release, Adobe Inc.) in a way that the interpupillary distance of two eyes in the frontal view (Fig. 1) and the Glabella–POG distance in the profile view were considered as fixed reference points in order to avoid possible measurement errors (Fig. 2). The sizes of preoperative and postoperative photos were matched to each other by two mentioned fixed parameters. The upper lip length was defined from the subnasal area to the most inferior level of vermilion border. The other variable measured in current study was the position of upper lip in lateral view. In that order the position of the subnasal and vermilion points were measured as the distance to the glabella–POG line in profile view. The preoperative and postoperative data were calculated and compared to each other and their relationship with the surgical variables included in rhinoplasty. The photographs were assessed by two independent assessors (a maxillofacial surgeon and a dentist) expert in using Photoshop software.

Surgical procedure

Skeletonising performed by transcolumellar and infracartilaginous incisions. Cephalic resection of the lower lateral cartilages, dorsum modification, and lateral osteotomy were preceded in all cases. The other modifications which were different in various cases were established in the recording chart. These surgical procedures were the variables of the study and the collective contribution in repositioning the upper lip length and angle was assessed.

Ethical considerations

Participants were informed of the purpose and design of the investigation and signed an appropriate consent form. The procedures followed were in accordance with the ethical standards of the responsible com-

Table 1

The distribution of position changes of the upper lip landmarks in all cases of rhinoplasty.

Variable	Increased number	Decreased number	SD (%)	p value
Vermillion border position	11	56	+4.82 ± 4.99	<001/0
Subnasal area position	14	53	+3.12 ± 4.61	<001/0
Upper lip length	21	46	+3.25 ± 5.12	<001/0

mittee of Semnan University of Medical Sciences with the ethical code of IR.SEMUMS.REC.1397.153.

Statistical analysis

All calculations have been processed using Statistical Package for Social Science statistical software (version 23; SPSS Inc.). Descriptive statistics including tables and graphs have been applied to show the information. One-sample *t* test was used to determine the significant differences variables. A *p* value of less than 0.05 has been considered statistically significant.

Results

Sixty seven patients (59 female and 8 male) with the mean age of 27.6 were included in the current study. The distribution of upper lip length changes and subnasal and vermilion border positions are categorised in Table 1.

Upper lip length

Percentage of lip length changes (frontal view) was decreased in 21 patients and increased in other cases (46 cases). The upper lip length changes in the frontal view of different surgeries are given in Table 2. These positive changes were statistically significant in columella strut ($p < 0.001$), pre-maxillary augmentation graft ($p = 0.001$), alar resection ($p < 0.001$), spreader graft ($p = 0.001$), columella retraction ($p = 0.046$), DSN release ($p < 0.001$), and DSN removal ($p = 0.005$); however, they were not significant in other procedures it was not ($p > 0.05$).

Subnasal position

Retrusion and protrusion accounted for subnasal position changes in 14 patients and 53 patients, respectively. The mean (SD) of changes in different surgical procedures is presented in Table 3. These incremental changes were statistically significant in columella strut ($p < 0.001$), premaxillary augmentation ($p < 0.001$), alar resection ($p < 0.001$), spreader graft ($P = 0.001$), columella retraction ($p < 0.001$), DSN release ($P = 0.006$), and tip rotation ($p = 0.044$), but they were not significant in other procedures ($p > 0.05$).

Vermillion position

Changes in vermilion position were of retrusion type in 11 individuals and protrusion in 56 individuals. The mean (SD) of changes in different surgical procedures is given in Table 4. These protrusion changes were statistically significant in columella strut ($p < 0.001$), premaxillary augmentation ($p < 0.001$), alar resection ($p < 0.001$), spreader



Fig. 1. Frontal view of the patient. Line A is the interpupillary distance used to match the size of preoperative and postoperative photos. Line B is the upper lip length measured from the subnasal point to the most inferior limit of the vermilion.

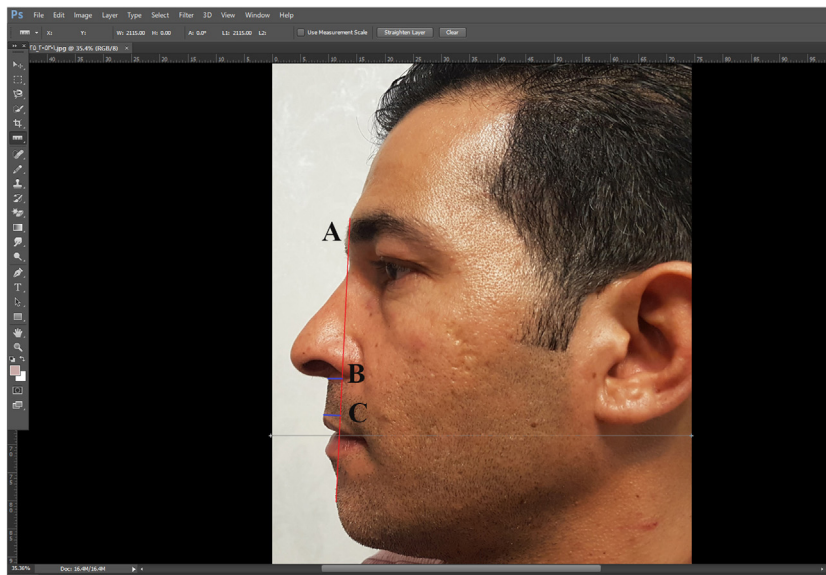


Fig. 2. Lateral view of the patient. Line A is the glabella-POG distance used to match the size of preoperative and postoperative photos. Lines B and C are the distance between the subnasal and vermilion points respectively and line A to estimate the lip position in profile view.

Table 2

Distribution of percentage changes of the upper lip length in frontal views of the patients underwent open rhinoplasty.

Surgical procedures	Number	Increased number	Decreased	Average of changes (%) number	p value
Columella strut graft	53	40	13	$+4.02 \pm 5.11$	<001/0
Premaxillary augmentation	10	9	1	$+6.6 \pm 4.25$	001/0
Alar resection	45	30	15	$+3.16 \pm 5.23$	<001/0
Spreader graft	26	19	7	$+3.81 \pm 5.14$	001/0
Nasal spine alteration	4	2	2	$+0.5 \pm 4.12$	0.824
Tip rotation	10	5	5	$+0.9 \pm 4.95$	0.58
Columella retraction	15	11	4	$+2.93 \pm 5.2$	0.046
DSN removal	6	6	0	$+10 \pm 3.03$	<0.001
DSN release	24	17	7	$+3 \pm 4.77$	0.005
Shield graft	14	7	7	$+0.79 \pm 3.97$	0.472

Table 3
Distribution of protrusion changes of subnasal position in patients underwent open rhinoplasty.

Surgical procedures	Number	Increased number	Decreased number	Average of changes (%)	p value
Columella strut graft	53	43	10	+3.28 ± 4.71	<001/0
Premaxillary augmentation	10	10	0	+10.7 ± 5.62	<001/0
Alar resection	45	36	9	+3.24 ± 4.81	<001/0
Spreader graft	26	22	4	+3.81 ± 4.9	001/0
Nasal spine alteration	4	3	1	+1.25 ± 3.1	0.478
Tip rotation	10	7	3	+3.5 ± 4.79	0.044
Columella retraction	15	14	1	+3.6 ± 2.69	<001/0
DSN removal	6	6	0	+6.83 ± 6.56	0.051
DSN release	24	17	7	+2.71 ± 4.37	0.006
Shield graft	14	9	5	+2.57 ± 4.64	0.058

Table 4
Distribution of percentage of protrusion changes of vermillion position in patients underwent open rhinoplasty.

Surgical procedures	Number	Increased number	Decreased number	Average of changes (%)	p value
Columella strut graft	53	46	7	+5.4 ± 5.06	>001/0
Premaxillary augmentation graft	10	10	0	+11.5 ± 5.48	>001/0
Alar resection	45	38	7	+4.64 ± 4.96	<001/0
Spreader graft	26	21	5	+4.12 ± 4.58	<001/0
Nasal spine alteration	4	3	1	+2 ± 3.37	0.32
Tip rotation	10	7	3	+3.6 ± 4.95	0.047
Columella retraction	15	14	1	+5.2 ± 3.51	<001/0
DSN removal	6	6	0	+8.67 ± 5.12	0.009
DSN release	24	19	5	+4.88 ± 4.61	<001/0
Shield graft	14	9	5	+2.79 ± 4.82	0.05

graft ($p < 0.001$), columella retraction ($p < 0.001$), DSN release ($p < 0.001$), DSN removal ($p = 0.009$), and tip rotation ($p = 0.047$), but they were not significant in other procedures ($p > 0.05$).

Discussion

Facial muscles move in harmony during daily activities such as smiling and talking. According to the philosophical notion that facial beauty is not merely the coordination of static anatomical structures and that facial dynamics are concerned with facial beauty. After cosmetic surgeries, defects that were noticeable only at the start of a smile and static facial positions were of more interest; however, the so called 'facial expression surgery' or 'dynamic surgery' are nowadays used to remove many defects. This technique is used not only to improve the nose shape but also to enhance the patient's smile.⁸ In current study it was decided to investigate the upper lip position 6 months following open rhinoplasty from frontal and profile views.

The human smile is a short and coordinated activity of the imitation muscles, which is mainly associated with a large ascent movement of the upper lip and the lip corners in the vertical vector.⁹ It is possible that the transection of the pulling muscles and ligaments decrease the vertical smile forces, which in turn overcomes non-vertical forces, reduces lip upward movement, and increases lip length, and leads to lip protrusion.

Another cause of upper lip protrusion and subnasal and vermillion points repositioning in this study was premaxillary augmentation graft. Obviously, protrusion increased by the addition of bone and soft tissue to the maxilla. Although most nasal changes in rhinoplasty are associated with increased or decreased bone and sub-cartilage structure, soft tissue modification has an important contribution to the final result.¹⁰

Sometimes rhinoplasty is performed regardless of dynamic muscular function. When patients recover from postoperative muscle function and begin to use their past imitations, such as smiling, the damaged dynamic forces may lead to nasal tip descent in a subtle way over a long period of time, which is related to their preoperative performance. To prevent this from happening, it is essential to carefully examine the facial muscles and preoperative smile patterns.¹¹

Consistent with our study, in a review study on the effects of interventions on DSN muscle in rhinoplasty, Sinno et al showed that treatment of DSN muscle, which involves transection or displacement of the muscle, results in improved aesthetic outcomes in rhinoplasty.¹² Transection or displacement of this muscle improves the position of the nose tip and increases the smile line and enhances the beauty of the face.

A study executed by Ho et al (2014) revealed that DSN muscle transection is not predictable but has little effect on high lip length.¹³ In another study, Kalantar Hormozi et al (2014) concluded that there was no statistically significant difference between DSN muscle transection or displacement at high lip length changes.¹⁴ As mentioned earlier, DSN modification increases the upper lip length. Another study suggested that DSN is an important muscle in nasal dynamics and overactivity of this muscle causes nose tip drop and smile deformity. This muscle is contracted repeatedly daily due to laughs and talking and may increase the nasal length over time.¹⁵

In a retrospective study Pi et al (2017) concluded that the placement of columella strut and extended spreader graft and the DSN muscle transection resulted in downward movement of the upper lip and lower maxillary anterior incisors show during smile.⁵ It was concluded in the present study that these measures increase the upper lip length and protrusion. The present study also investigated the vertical movement of the upper lip and found lower elevation for upper lip.

Although most of the rhinoplasty manoeuvres increased the upper lip length some other procedures in the current study did not have any impact on the lip length. Altering the nasal spine, tip rotation, and shield graft were the procedures that did not significantly change the upper lip length. Tabrizi et al (2012) assessed open rhinoplasty without alar resection and the results showed that the tooth show during maximum smile was significantly higher than before surgery.¹⁶

The importance of current study was the assessment of lip position in profile view. Cerrati et al (2017) evaluated the increased nasal tip projection on lip position.⁶ They assessed the lip position at the level of vermilion and concluded that upper lip would be more projected as the nasal tip projection is increased.⁶ The other anatomical landmark that should be considered in evaluating the lip position in profile view is subnasal area. The changes of upper lip in lateral view are important in camouflage of the premaxilla region in some cases. Rhinoplasty techniques may make a slightly retruded maxilla look better or worse. In the present study two main points of the upper lip including subnasal and vermilion points were marked to show the lip position in regard to the glabella-POG line. It was decided to propose the lateral view of lip position as the term of lip depth. Actually the lip position in profile view is important to make a harmonic face and the right proportion between the nose and maxilla. The distances between reference points compared to the glabella-POG line was called the lip depth as a new aesthetic important index. Premaxillary augmentation graft and columella retraction technique were the most important procedures increased the lip protrusion and reduced the lip depth. Since the most rhinoplasty methods increases the lip protrusion (reduces lip depth) more augmentation techniques should be avoided in more skeletally class II patients or protruded upper incisors.

The key point of the findings of the current study is the appropriate decision made by the surgeon to combine several rhinoplasty manoeuvres to prohibit increase of the upper lip following surgery. Furthermore, if the patient's lip is already longer than normal, the surgeon may suggest a lip lift surgery a few months after rhinoplasty.

The limitations of this study are, although there is collective lip length increase, it is difficult to pinpoint which of the adjuvant procedures are of more dominant in producing the final outcome. In this study, different rhinoplasty manoeuvres were performed according to the patient's needs, and the final result of upper lip position was the outcome of several surgical manoeuvres. Therefore, the result was not merely related to a surgical manoeuvre and could possibly have an effect on the results. Also, some surgical manoeuvres were performed less frequently due to the small number of specimens and this made some of them not significant.

Conclusion

Procedures involved in rhinoplasty including columella strut graft, premaxillary augmentation graft, alar resection, spreader graft, columella retraction, and DSN release, may increase the upper lip length in the frontal view and lead to upper lip protrusion in profile view. The present study investigated the effects of rhinoplasty on the profile and frontal views of the lip and the results can be helpful for surgeons in prediction upper lip position from the frontal and profile view after rhinoplasty.

Conflict of interest

We have no conflicts of interest.

Ethics statement/confirmation of patients' permission

The procedures followed were in accordance with the ethical standards of the responsible committee of Semnan University of Medical Sciences with the ethical code of IR.SEMUMS.REC.1397.153. Participants were informed of the purpose and design of the investigation and signed an appropriate consent form.

Acknowledgement

This study is dedicated to Dr. Abbas Tosan who we lost to COVID-19. He performed the surgery of the presented cases in the current study. We wish God's mercy upon him.

References

1. Krishnan V, Daniel ST, Lazar D, et al. Characterisation of posed smile by using visual analog scale, smile arc, buccal corridor measures, and modified smile index. *Am J Orthod Dentofacial Orthop* 2008;**133**:515–23.
2. Sabri R. The eight components of a balanced smile. *J Clin Orthod* 2005;**39**:155–67.
3. Rohrich RJ, Huynh B, Muzaffar AR, et al. Importance of the depressor septi nasi muscle in rhinoplasty: anatomic study and clinical application. *Plast Reconstr Surg* 2000;**105**:376–83, discussion 384–378.
4. Tollefson TT, Sykes JM. Computer imaging software for profile photograph analysis. *Arch Facial Plast Surg* 2007;**9**:113–9.
5. Pi H, Kurlander DE, Guyuron B. Effects of the rhinoplasty maneuvers on upper lip position and incisor show. *Aesthetic Plast Surg* 2017;**41**:135–9.
6. Cerrati EW, Dayan SH. Association of increasing nasal tip projection with lip position in primary rhinoplasty. *JAMA Facial Plast Surg* 2017;**19**:323–6.
7. Alsarraf R, Larrabee WF, Anderson S, et al. Measuring cosmetic facial plastic surgery outcomes: a pilot study. *Arch Facial Plast Surg* 2001;**3**:198–201.
8. Pearlman SJ. Surgical treatment of the nasolabial angle in balanced rhinoplasty. *Facial Plast Surg* 2006;**22**:28–35.
9. Zabojoja J, Thrikutam N, Tolley P, et al. Relational anatomy of the mimetic muscles and its implications on free functional muscle inset in facial reanimation. *Ann Plast Surg* 2018;**81**:203–7.
10. Sinno S, Chang JB, Chaudhry A, et al. The role of depressor septi nasi manipulation in rhinoplasty: a systematic review. *Plast Reconstr Surg* 2014;**134**:134–5.
11. Benlier E, Balta S, Tas S. Depressor septi nasi modifications in rhinoplasty: a review of anatomy and surgical techniques. *Facial Plast Surg* 2014;**30**:471–6.
12. Sinno S, Chang JB, Saadeh PB, et al. Anatomy and surgical treatment of the depressor septi nasi muscle: a systematic review. *Plast Reconstr Surg* 2015;**135**:838e–48e.
13. Ho Y, Deeb R, Westreich R, et al. Effect of depressor septi resection in rhinoplasty on upper lip length. *JAMA Facial Plast Surg* 2014;**16**:272–6.
14. Kalantar-Hormozi A, Beiraghi-Toosi A. Smile analysis in rhinoplasty: a randomised study for comparing resection and transposition of the depressor septi nasi muscle. *Plast Reconstr Surg* 2014;**133**:261–8.
15. Beiraghi-Toosi A, Rezaei E, Nooghabi MJ, et al. Effect of depressor septi nasi muscle activity on nasal lengthening with time. *Aesthetic Plast Surg* 2013;**37**:984–8.
16. Tabrizi R, Mirmohamadsadeghi H, Daneshjoo D, et al. Effect of open rhinoplasty on the smile line. *J Oral Maxillofac Surg* 2012;**70**:1174–6.