

Hemorrhage Rates Associated with Two Methods of Ventriculostomy: External Ventricular Drainage vs. Ventriculoperitoneal Shunt Procedure

Jun Kyeong KO,¹ Seung Heon CHA,¹ Byung Kwan CHOI,¹ Jae Il LEE,¹
Eun Young YUN,² and Chang Hwa CHOI¹

*Departments of ¹Neurosurgery and ²Biostatistics, Medical Research Institute,
Pusan National University Hospital, Busan, ROK*

Abstract

Cerebrospinal fluid (CSF) diversion is an essential component of neurosurgical care, but the rates and significance of hemorrhage associated with external ventricular drainage (EVD) and ventriculoperitoneal (VP) shunt procedures have not been well quantified. In this retrospective study, the authors examined the frequencies of hemorrhagic complications associated with EVD and VP shunt procedures, and attempted to identify associated risk factors. The treatment records of 370 EVDs in 276 patients and 102 VP shunts in 96 patients performed between 2008 and 2010 were retrospectively reviewed. Post-insertion computed tomographic (CT) scans were analyzed for any new hemorrhage related to the ventricular catheter. The effects of diagnosis at admission, endovascular treatment, anti-platelet medication, and a concurrent craniotomy operation were included in the analysis conducted to identify risk factors of ventricular catheter-related hemorrhage. Hemorrhage following EVD was detected on CT scans in 76 (20.5%) of the 370 cases. However, symptomatic hemorrhage occurred in only 5 cases (1.4% of all EVDs). VP shunt was associated with a higher incidence of ventricular catheter-related hemorrhage than EVD (hemorrhage rate: 43.1%) and the rate of detectable neurological change was 2.9%. Multivariate logistic-regression analysis of risk factors of EVD-related hemorrhage identified preoperative anti-platelet medication as the only significant factor (odds ratio, 3.583 [95% confidence interval, 1.353 to 9.486]; $p = 0.010$). Ventriculostomy-related hemorrhagic complications were more common than anticipated, especially for the VP shunt procedure. However, such hemorrhages are rarely large, rarely the cause of neurological deterioration, and rarely require surgical removal. Preoperative anti-platelet medication appears to affect EVD-related hemorrhage development.

Key words: complication, drain, hemorrhage, intracranial, ventriculostomy

Introduction

The placement of cerebrospinal fluid (CSF) diversion devices, such as external ventricular drainages (EVDs) and ventriculoperitoneal (VP) shunts, are essential components of neurosurgical care. Many qualitative studies on complications after EVD and VP shunt placements have been undertaken, and shown that the two main complications are infection and iatrogenic related hemorrhage. However, the rates and significance of hemorrhage associated with this procedure have not been well quantified, because small hematomas following ventriculostomy are often overlooked or not detected. This retrospective study focuses on the frequency of hemorrhagic

complications associated with EVD or VP shunt placement, and on the prevalences of clinically detectable neurological changes after ventricular catheter-related hemorrhage, as well as a comparison of risk factors associated with ventricular catheter-related hemorrhage.

Materials and Methods

The treatment records of 370 EVDs in 276 patients and 102 VP shunts in 96 patients admitted to our institute between January 2008 and December 2010 requiring CSF diversion were retrospectively reviewed. One hundred and fifty-seven females (57%) and 119 males (43%) aged from 1 month to 90 years (median 56 years) constituted the EVD group, and 50 females (52%) and 46 males (48%) aged from

5 months to 78 years (median 51 years) composed the VP shunt group. Admitting diagnoses of EVD cases included acute complications of cerebrovascular disease (n = 328), the majority of whom had experienced an aneurysmal subarachnoid hemorrhage (SAH) (n = 212) or a hypertensive intracerebral hemorrhage (ICH) (n = 113). Other indications for EVD included traumatic brain injury (n = 16), tumor (n = 12), primary hydrocephalus (n = 12), and intracranial infection/inflammation (n = 2). For VP shunt operations, diagnoses at admission included SAH (n = 53), hypertensive ICH (n = 10), trauma (n = 12), tumor (n = 11), primary hydrocephalus (n = 12), cerebral infarction (n = 3), and intracranial infection/inflammation (n = 1) (Table 1).

It is worth noting that since our institution emphasizes education, a substantial majority of all ventricular catheters are placed by 4th year neurosurgery residents with varying degrees of supervision. Correct placement of ventricular catheters was accomplished in 90% of the operations after one pass, and none of the cases required more than two attempts. The preferred side for ventricular catheter placement is the presumed non-dominant (right) side unless the patient's anatomy or underlying pathology is otherwise prohibitive.

EVDs were placed according to the following protocol under general anesthesia. Kocher's point is first identified and the area is then prepped and draped in a sterile fashion.¹⁾ Following infiltration of a local anesthetic, a skin incision is created and a bur hole is then placed through this incision with a high speed drill. After dural incision, a ventricular catheter is advanced orthogonally to the brain parenchyma and according to the coronal and

sagittal planes, which include the ipsilateral medial canthus and the ipsilateral tragus, respectively. The optimal intraventricular endpoint is defined as in front of the ipsilateral foramen of Monroe, and the maximum insertion depth of the catheter is 6–7 cm.^{2,3)} 3.5-mm outer diameter ventricular catheters were used for EVD except in nine infants, who required 2.5-mm outer diameter catheters. All EVDs were performed regardless of taking antiplatelet agents.

For the VP shunt procedure, an occipital bone entry site located at Frazier's point (6 cm above theinion and 3 cm lateral to the midline) is used.¹⁾ The external landmark toward which the drain is to be directed is the ipsilateral medial canthus in both sagittal and axial planes. The target depth of insertion is approximately 9–11 cm, depending on patient's age. The distal portion of the catheter is attached to a pressure valve which is subsequently connected to a distal catheter.^{1,3)} 2.5-mm outer diameter ventricular catheters were used for VP shunt except in 10 children, who received 2.1-mm outer diameter ventricular catheters. All patients, who have required VP shunt, stopped taking antiplatelet agents at least more than five days preoperatively.

Post-insertion computed tomographic (CT) scans were obtained within 48 hours for all patients. The majority of CT scans were obtained within 8 hours of ventricular catheter placement. Additional post-insertion CT scans were obtained for all patients when clinically necessary.

All CT scans were analyzed for any new hemorrhage related to the ventricular catheter independently by the authors, blinded to clinical outcomes. We included follow-up CT within two weeks of ventriculostomy in this analysis, because we have frequently found new hemorrhages or larger hematomas when CT is conducted later during follow-up. Ventricular catheter-related hemorrhage is defined as any evidence of new hemorrhage along the catheter tract. Ventricular catheter-related hemorrhages were classified according to hematoma size and appearance, as follows: (1) Grade 1: minimal intraventricular hemorrhage (IVH), punctuate intraparenchymal, trace SAHs, hematoma in one cut only, or a maximum hematoma diameter of < 1 cm by 5 mm slice thickness CT (Fig. 1); (2) Grade 2: hematoma in ≤ 3 cuts or a maximum hematoma diameter of < 3 cm by 5 mm slice thickness CT (Fig. 2); and (3) Grade 3: massive IVH, hematoma involving > 3 cut, or a maximum hematoma diameter of ≥ 3 cm by 5 mm slice thickness CT (Fig. 3).

Table 1 Admitting diagnosis of two different ventriculostomies

Admitting diagnosis	EVD (%)	VP shunt (%)
Cerebrovascular		
SAH	212 (57.3)	52 (51.0)
ICH	113 (30.5)	10 (9.8)
Infarct	3 (0.8)	3 (2.9)
Trauma	16 (4.3)	12 (11.8)
Tumor	12 (3.2)	11 (10.8)
Primary hydrocephalus	12 (3.2)	12 (11.8)
Infection/Inflammation	2 (0.5)	1 (1.0)
Total	370 (100)	102 (100)

EVD: external ventricle drainage, ICH: intracerebral hemorrhage, SAH: subarachnoid hemorrhage, VP shunt: ventriculoperitoneal shunt.

Statistical analysis

Statistical analysis was performed with the use of SPSS software (version 20.0; IBM SPSS, Chicago,

Illinois, USA) Chi-square test or Fisher's exact tests were used to compare the proportions between two groups, as appropriate. We performed multivariate logistic-regression analyses with the enter method to identify risk factors associated with EVD-related hemorrhage. All comparisons were made with the use of a two-sided alpha level of 0.05.

Results

I. Hemorrhage rates after EVD

Hemorrhage following EVD was detected on CT scans in 76 (20.5%) of the 370 EVD cases. In 28 cases (7.5% of all EVDs), hemorrhages were Grade 1,

in 40 (10.8% of all EVDs) Grade 2, and in 8 (2.2% of all EVDs) Grade 3 (Table 2). Symptomatic hemorrhage, defined as clinically apparent neurological deterioration directly attributable to ventriculostomy, occurred in 5 cases (1.4% of all EVDs) and of these, 2 cases required surgical clot removal. Despite emergent operation, one patient died and the other was discharged with cognitive impairment due to a massive EVD-related hemorrhage.

II. Hemorrhage rates after VP shunt

VP shunt-related hemorrhage was observed on CT scans in 44 (43.1%) of the 102 VP shunt cases. There were 24 cases (23.5% of all VP shunts) of

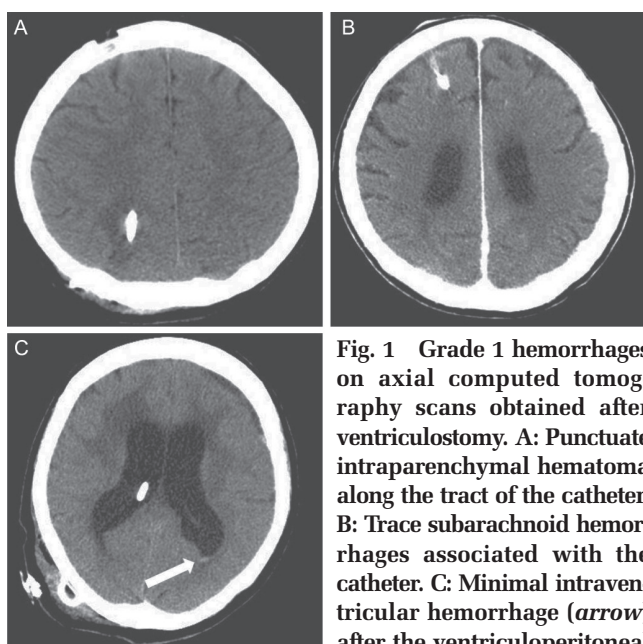


Fig. 1 Grade 1 hemorrhages on axial computed tomography scans obtained after ventriculostomy. **A:** Punctate intraparenchymal hematoma along the tract of the catheter. **B:** Trace subarachnoid hemorrhages associated with the catheter. **C:** Minimal intraventricular hemorrhage (*arrow*) after the ventriculoperitoneal shunt procedure.

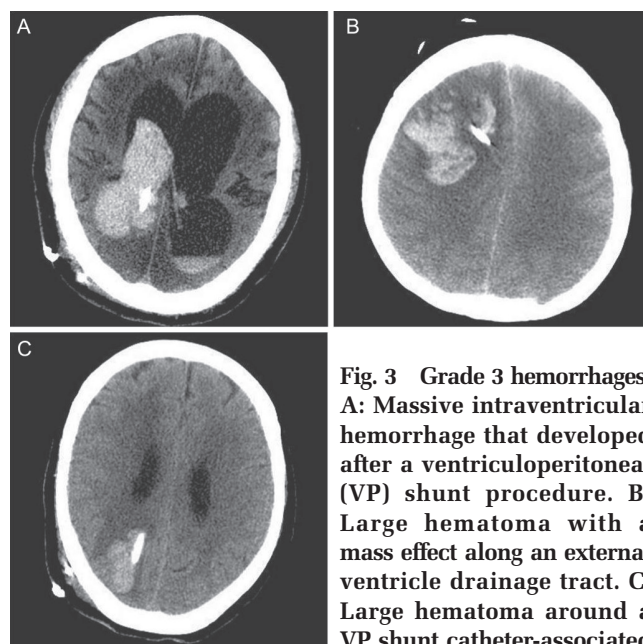


Fig. 3 Grade 3 hemorrhages. **A:** Massive intraventricular hemorrhage that developed after a ventriculoperitoneal (VP) shunt procedure. **B:** Large hematoma with a mass effect along an external ventricle drainage tract. **C:** Large hematoma around a VP shunt catheter-associated with subgaleal hematoma.

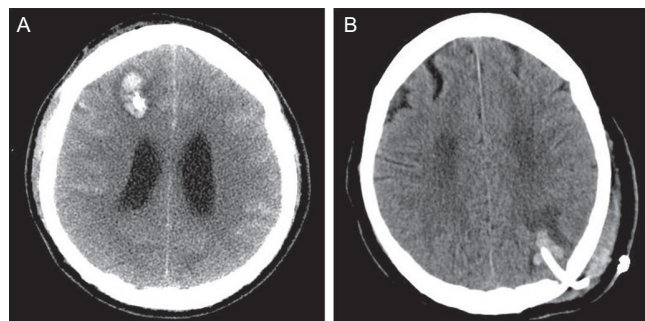


Fig. 2 Grade 2 hemorrhages after external ventricle drainage (A) and ventriculoperitoneal shunt (B) procedures. Maximum diameters of catheter-associated hematomas were less than 3 cm on computed tomography scans.

Table 2 Hemorrhage rates following two different ventriculostomies

Hemorrhagic Cx	EVD (%) (n = 370)	VP shunt (%) (n = 102)	p value
Grade 1	28 (7.5)	24 (23.5)	
Grade 2	40 (10.8)	17 (16.7)	
Grade 3	8 (2.2)	3 (2.9)	
Total	76 (20.5)	44 (43.1)	< 0.001

Cx: complication, EVD: external ventricle drainage, VP shunt: ventriculoperitoneal shunt.

Grade 1 hematoma, 17 (16.7% of all VP shunts) of Grade 2 hematoma and 3 (2.9% of all VP shunts) of Grade 3 hematoma (Table 2). Symptomatic hemorrhage occurred in 3 cases (2.9% of all VP shunts), and manifested as decreased mentality, headache, or nausea. Symptoms gradually improved under conservative treatment, and all three were discharged without neurological deficit. The VP shunt group was found to have a significant higher risk of catheter-related hemorrhage than the EVD group ($p < 0.001$).

III. Hemorrhage rates according to diagnosis at admission

Hemorrhage rates according to diagnosis at admission in both groups are summarized in Figs. 4 and

5. No significant difference was found for hemorrhage rates according to diagnosis at admission in both groups.

IV. Risk factors of EVD-related hemorrhage

The data of patients that underwent EVD was subjected to logistic-regression analysis to identify risk factors of an EVD-related hemorrhage (Table 3). Endovascular treatment, anti-platelet medication including abciximab, and concurrent craniotomy operation were entered into the model. Multivariate logistic-regression analysis using the enter method showed that anti-platelet medication was the only significant risk factor (odds ratio, 3.583 [95% confidence interval, 1.353 to 9.486]; $p = 0.010$).

Endovascular treatment was performed immediately

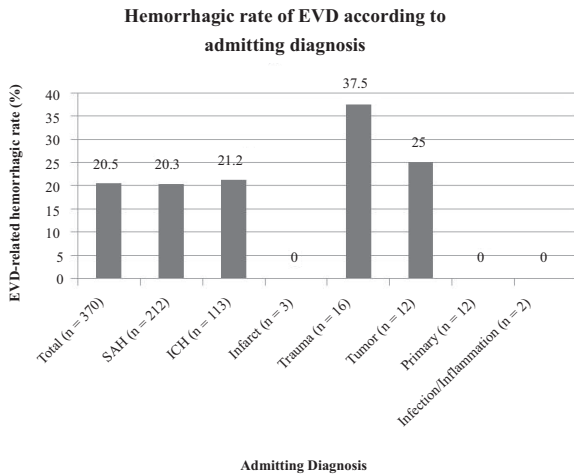


Fig. 4 Bar graph showing the frequency of EVD-related hemorrhage with respect to diagnosis at admission. No significant difference was found for hemorrhage rates according to diagnosis at admission in the EVD group. EVD: external ventricle drainage, ICH: intracerebral hemorrhage, SAH: subarachnoid hemorrhage.

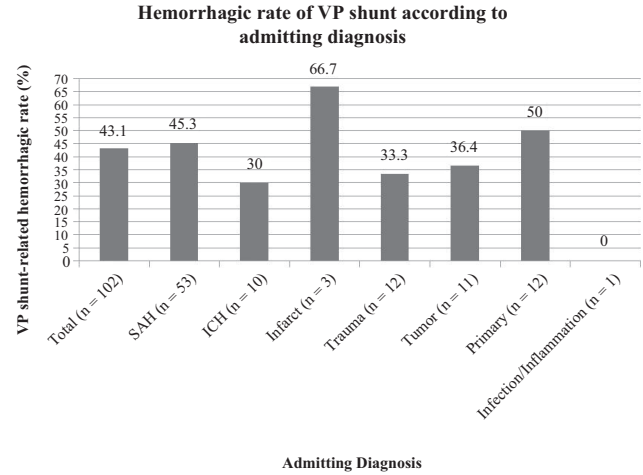


Fig. 5 Bar graph showing the frequency of VP shunt-related hemorrhage by diagnosis at admission. No significant difference was found for hemorrhage rates according to diagnosis at admission in VP shunt group. ICH: intracerebral hemorrhage, SAH: subarachnoid hemorrhage, VP: ventriculooperitoneal.

Table 3 Multivariate analysis of risk factors associated with EVD-related hemorrhage

Variables	Overall (n = 370)	Non-hemorrhage (n = 294)	Hemorrhage (n = 76)	Multivariate	
				OR (95% CI)	p value
EVT	95	71	24	0.664(0.263, 1.675)	0.386
Anti-platelet	57	37	20	3.583(1.353, 9.486)	0.010*
Abciximab	23	19	4	0.451(0.131, 1.549)	0.206
Concurrent op	106	91	15	0.598(0.309, 1.159)	0.128

Values are given as the number of patients. In multivariate model, variables were adjusted with age and sex. *Statistically significant at $p < 0.05$. CI: confidence interval, EVD: external ventricular drainage, EVT: endovascular treatment, op: operation, OR: odds ratio.

before EVD in 95 cases (25.7% of all EVDs), and a hemorrhages occurred in 24 cases. No significant difference in EVD-related hemorrhage rates were found between endovascular treatment group and the rest.

Anti-platelet agents were prescribed and/or administered to selected cases immediately after endovascular treatment as 100 mg aspirin plus 300 mg clopidogrel. EVD-related hemorrhage occurred in 35.1% ($n = 20$) of those patients that received anti-platelet medication ($n = 57$). Anti-platelet medication was a statistically significant risk factor of EVD-related hemorrhage. Abciximab (ReoPro®; a potent inhibitor of hemostasis; Centocor [current name: Janssen Biologics], Leiden, Netherlands) administration was not found to significantly increase the risk of EVD-related hemorrhage.

In many cases, EVD were performed during other craniotomy operations. EVD-related hemorrhage occurred in 14.2% ($n = 15$) of those that underwent concurrent craniotomy ($n = 106$). However, concurrent craniotomy did not significantly increase the risk of EVD-related hemorrhage.

Discussion

The placements of CSF diversion devices, such as EVDs and VP shunts, are considered by most neurosurgeons to be technically straightforward procedures. However, despite its widespread use, ventricular catheter placement is still associated with infection and intracranial hemorrhage. Although numerous protocols have been proposed to minimize ventriculostomy-related infections, the more immediate and higher risk complication of ventriculostomy, that is, of catheter-related iatrogenic hemorrhage, has been overlooked or not detected in previous studies.⁴⁻⁹ Meyer et al.¹⁰ reported a ventriculostomy-related hemorrhage rate of 1%, but only included large hematomas requiring surgical intervention in the analysis and did not include postoperative CT findings. Wiesmann and Mayer¹¹ reported an overall bleeding risk after EVD of 9.4%. However, some of the latest issued, based on analyses of CT findings, indicate much higher ventriculostomy-related hemorrhage rates than were previously expected.^{2,12} Maniker et al.² reported an EVD-related hemorrhage rate of 33% (52/160 patients) and emphasized that even a small hemorrhage without a significant mass effect or immediate sequelae, can provide a seizure focus. Gardner et al.¹² reported a new hemorrhage rate of 41% (77/188 patients) after EVD placement or removal. In the present study, we included follow-up CT images taken within 2 weeks of ventriculostomy,

because we have frequently found new hemorrhages or larger hematomas during later follow-up. The exclusion of follow-up CT would result in an incomplete study. New hemorrhages detected by follow-up CT, not visualized just postoperatively, represent as many as 64.5% of 76 EVD-related hemorrhages, and 27.3% of 44 VP shunt-related hemorrhages.

Although these recent reports demonstrated a higher incidence of EVD-related hemorrhage than anticipated, they also reported that hemorrhages were rarely large and almost never required surgical intervention.^{2,11-13} In the present study, the overall rates of EVD- and VP shunt-related hemorrhages were 20.5% and 43.1%, respectively, which was markedly higher than anticipated, especially in the VP shunt group. A review of literature showed ICH may be seen after 0.4% to 4% of VP shunt operations, and that almost all occurred soon after operation.¹⁴⁻¹⁹ Our observations suggest that small punctuate hematoma is the most common form of VP shunt-related hemorrhage, and this is easily missed on CT images because of its size and proximity to the ventricular catheter. Furthermore, we can suppose that venous congestion and engorgement caused by excessive rotation of the patient's head in VP shunt operation might be an important reason why the rate of VP shunt-related hemorrhage is higher compared to EVD.

In present series, symptomatic hemorrhage was rare, and occurred after only 1.4% of all EVDs and 2.9% of all shunts, which concurs with previous reports. However, massive frontal hemorrhage caused by EVD resulted in mortality and morbidity in two of our patients. On the other hand, VP shunt-related large occipital hematomas induced no neurological deficit. Furthermore, we observed that large subgaleal hematomas frequently were associated with Grade 2 or 3 hematomas in the EVD and VP shunt groups, as seen in Figs. 2B and 3C. We thought that a large amount of subgaleal hematoma and ventricular collapse after tube insertion might induce the pressure gradient across the calvarium, and such a pressure gradient could make a part of subgaleal hematoma to move into the intracranial space through a bur hole. For this reason, it should be emphasized that careful bleeding control of subcutaneous tissue during the procedure is mandatory to prevent EVD and VP shunt-related hemorrhages.

Although Maniker et al.² reported that patients with cerebrovascular disease had a higher rate of EVD-related hemorrhage, we found no significant association between EVD-related hemorrhage rates and diagnosis at admission. Furthermore, we

expected that endovascular treatment, preoperative anti-platelet medication, and concurrent craniotomy would increase EVD-related hemorrhage rates, but only the receipt of preoperative anti-platelet medication was found to be a significant independent risk factor of EVD-related hemorrhage. Dual anti-platelet agents were prescribed to both patients that required surgical removal in EVD group, which cautions that when endovascular treatment is increased, the effects of anti-platelet medication on EVD should be considered.

Intracranial hemorrhage after ventricular cannulation can result from multiple attempts at ventricular puncture, puncture of the choroid plexus, or incorrect placement of the tube within the brain parenchyma.^{18–20} Other mechanisms include a coexistent bleeding disorder, catheter-induced disseminated intravascular coagulation, disruption of an intracerebral vessel by the catheter, hemorrhage from an occult vascular malformation, and head trauma occurring shortly after catheter placement.^{16,19}

Because of the retrospective design of this study, no accurate information was available on the ventricular size and the presence of seizures. These potential risk factors of ventricular catheter-related hemorrhage are best studied prospectively, and thus, we suggest that a larger-scale prospective study be conducted to determine the effects of variables.

Conclusion

This article presents the results of a single-center series on the frequencies of hemorrhagic complications after EVD or VP shunt procedures and their associated risk factors. Ventriculostomy-related hemorrhages occur far more often than has been generally suspected, though they are usually small and rarely cause neurological deterioration. Therefore, these procedures are valuable clinically, because when performed for specific indications, their benefits far outweigh their risks. However, our findings show that decisions regarding preoperative anti-platelet medication be taken only after carefully considering the possibility of hemorrhagic complications. Further prospective studies are needed to evaluate the statistical impact of our observations and to reduce the hemorrhagic rate of these procedures.

Conflicts of Interest Disclosure

The authors certify that there is no conflict of interest with any financial organization regarding the material discussed in the article.

References

- 1) Anderson RC, Kan P, Klimo P, Brockmeyer DL, Walker ML, Kestle JR: Complications of intracranial pressure monitoring in children with head trauma. *J Neurosurg* 101: 53–58, 2004
- 2) Maniker AH, Vaynman AY, Karimi RJ, Sabit AO, Holland B: Hemorrhagic complications of external ventricular drainage. *Neurosurgery* 59: ONS419–424; discussion ONS424–425, 2006
- 3) Woernle CM, Burkhardt JK, Bellut D, Krayenbuehl N, Bertalanffy H: Do iatrogenic factors bias the placement of external ventricular catheters?—a single institute experience and review of the literature. *Neurol Med Chir (Tokyo)* 51: 180–186, 2011
- 4) Camacho EF, Boszczowski I, Basso M, Jeng BC, Freire MP, Guimarães T, Teixeira MJ, Costa SF: Infection rate and risk factors associated with infections related to external ventricular drain. *Infection* 39: 47–51, 2011
- 5) Keong NC, Bulters DO, Richards HK, Farrington M, Sparrow OC, Pickard JD, Hutchinson PJ, Kirkpatrick PJ: The SILVER (Silver Impregnated Line Versus EVD Randomized trial): a double-blind, prospective, randomized, controlled trial of an intervention to reduce the rate of external ventricular drain infection. *Neurosurgery* 71: 394–403; discussion 403–404, 2012
- 6) Lo CH, Spelman D, Bailey M, Cooper DJ, Rosenfeld JV, Brecknell JE: External ventricular drain infections are independent of drain duration: an argument against elective revision. *J Neurosurg* 106: 378–383, 2007
- 7) Lwin S, Low SW, Choy DK, Yeo TT, Chou N: External ventricular drain infections: successful implementation of strategies to reduce infection rate. *Singapore Med J* 53: 255–259, 2012
- 8) Omar MA, Mohd Haspani MS: The risk factors of external ventricular drainage-related infection at hospital kuala lumpur: an observational study. *Malays J Med Sci* 17: 48–54, 2010
- 9) Pfisterer W, Mühlbauer M, Czech T, Reinprecht A: Early diagnosis of external ventricular drainage infection: results of a prospective study. *J Neurol Neurosurg Psychiatr* 74: 929–932, 2003
- 10) Meyer B, Schaller K, Rohde V, Hassler W: Percutaneous needle trephination. Experience in 200 cases. *Acta Neurochir (Wien)* 127: 232–235, 1994
- 11) Wiesmann M, Mayer TE: Intracranial bleeding rates associated with two methods of external ventricular drainage. *J Clin Neurosci* 8: 126–128, 2001
- 12) Gardner PA, Engh J, Atteberry D, Moossy JJ: Hemorrhage rates after external ventricular drain placement. *J Neurosurg* 110: 1021–1025, 2009
- 13) Saladino A, White JB, Wijdicks EF, Lanzino G: Malplacement of ventricular catheters by neurosurgeons: a single institution experience. *Neurocrit Care* 10: 248–252, 2009
- 14) Alcázar L, Alfaro R, Tamarit M, Gómez-Angulo JC,

- Ortega JM, Aragonés P, Jerez P, Salazar F, del Pozo JM: Delayed intracerebral hemorrhage after ventriculoperitoneal shunt insertion. Case report and literature review. *Neurocirugia (Astur)* 18: 128–133, 2007
- 15) Dube SK, Chowdhury T, Yadav R, Rath GP: Intraventricular hemorrhage after ventriculoperitoneal shunt removal. *J Anaesthesiol Clin Pharmacol* 27: 570–571, 2011
- 16) Matsumura A, Shinohara A, Munekata K, Maki Y: Delayed intracerebral hemorrhage after ventriculoperitoneal shunt. *Surg Neurol* 24: 503–506, 1985
- 17) Misaki K, Uchiyama N, Hayashi Y, Hamada J: Intracerebral hemorrhage secondary to ventriculoperitoneal shunt insertion—four case reports. *Neurol Med Chir (Tokyo)* 50: 76–79, 2010
- 18) Savitz MH, Bobroff LM: Low incidence of delayed intracerebral hemorrhage secondary to ventriculoperitoneal shunt insertion. *J Neurosurg* 91: 32–34, 1999
- 19) Zhou F, Liu Q, Ying G, Zhu X: Delayed intracerebral hemorrhage secondary to ventriculoperitoneal shunt: two case reports and a literature review. *Int J Med Sci* 9: 65–67, 2012
- 20) Derdeyn CP, Delashaw JB, Broaddus WC, Jane JA: Detection of shunt-induced intracerebral hemorrhage by postoperative skull films: a report of two cases. *Neurosurgery* 22: 755–757, 1988

Address reprint requests to: Chang Hwa Choi, MD, PhD, Department of Neurosurgery, Pusan National University Hospital, 305 Gudeok-Ro, Seo-Gu, Busan 602-739, Republic of Korea.
e-mail: chwachoi@pusan.ac.kr