


Contents lists available at [ScienceDirect](https://www.sciencedirect.com)

Medical Mycology Case Reports

journal homepage: www.elsevier.com/locate/mmcr

Transudative pleural effusion as an initial presentation of a disseminated cryptococcosis infection in a HIV-negative patient with cirrhosis

Sindhubarathi Murali^{*}, Kara Schweid, Philip Chebaya, Suman Rao, Erik Rufa

SUNY Upstate Medical University, 750 E. Adams St, Syracuse, NY, 13210, USA

ARTICLE INFO

Keywords:

Cirrhosis
Disseminated
Cryptococcus
Transudative
Pleural effusion

ABSTRACT

To our knowledge, this is the first case report of a transudative pleural effusion with positive *Cryptococcal* antigen and culture. We describe a 32-year-old male with end-stage liver disease (ESLD) who presented to an outside hospital with dyspnea and a large pleural effusion. An initial pleural fluid analysis was positive for *Cryptococcal* Ag. However, the infection was eventually found to be widespread as he had positive *Cryptococcal* Ag and cultures in his pleural fluid, serum, and cerebrospinal fluid (CSF). His antimicrobial regimen was escalated from fluconazole to amphotericin B and flucytosine. His medical condition deteriorated, and the patient passed away. Due to its rarity and range of clinical severity, diagnosis of disseminated *Cryptococcosis* can be delayed. We present this case to bring awareness of this diagnosis as a differential in immunocompromised patients regardless of a transudative pleural effusion.

1. Introduction

Cryptococcus is a fungal spore that causes infections, particularly in HIV positive and immunocompromised patients. *Cryptococcus* is an encapsulated yeast found in the environment. The fungus commonly infects the lungs resulting in pneumonia or the central nervous system, causing meningitis [1]. However, the fungus can disseminate to many different organs. Infrequently, individuals with diabetes mellitus, liver disease, kidney disease, and even no known medical history can have disseminated infection [1–3].

Individuals who are HIV-negative with ESLD have significantly higher mortality than HIV-negative patients without ESLD or HIV positive patients. This higher mortality is likely related to the liver's important role in generating an effective immune response, clearing cytokines and bacteria from the vasculature [4]. In patients with ESLD, this response is compromised and results in an increased risk of *Cryptococcal* meningitis and disseminated disease [3].

Cryptococcal meningitis is a disease with significant morbidity and mortality, particularly in cases with disseminated infection. The presence of either of these conditions demands an aggressive treatment regimen with amphotericin B and flucytosine, while milder infections, such as pulmonary *Cryptococcosis*, can be adequately managed with fluconazole [5]. *Cryptococcal* infection in the lungs usually causes an exudative effusion [6–8]. In our literature review, we have not found a

case of an individual with a transudative effusion who had *Cryptococcal* pneumonia or *Cryptococcal* pleural infection.

We present a fatal case of disseminated *Cryptococcus* in a young adult with end-stage liver disease. His course was complicated by many factors: a long-standing ventriculoperitoneal shunt, hypopituitarism, and *Cryptococcal* invasion of a persistent pleural effusion and his ascitic fluid. His case was particularly unique because despite having disseminated infection, his initial thoracentesis showed a transudative effusion.

2. Case presentation

We present a 32-year-old male transferred to our hospital to manage *Cryptococcal* pleural infection and spontaneous bacterial peritonitis. The patient experienced abdominal pain and recurrent ascites, requiring multiple paracentesis procedures and albumin therapy for the past six months. He initially presented to an outside hospital with difficulty ambulating, nausea, dizziness, and a sodium level of 120 mEq/L. Paracentesis was done at an outside hospital, and the patient was started on ceftriaxone for possible spontaneous bacterial peritonitis. He developed dyspnea and increased oxygen requirements. Pleural fluid analysis from the outside hospital was positive for *Cryptococcal* antigen (Ag) with titer 1:256. The patient had no neurological or meningeal symptoms. He was started on IV fluconazole (400 mg) and transferred to our hospital for a higher level of care.

^{*} Corresponding author.

E-mail address: muralis@upstate.edu (S. Murali).

<https://doi.org/10.1016/j.mmcr.2021.08.007>

Received 29 June 2021; Received in revised form 20 August 2021; Accepted 31 August 2021

Available online 6 September 2021

2211-7539/© 2021 The Authors. Published by Elsevier B.V. on behalf of International Society for Human and Animal Mycology. This is an open access article

under the CC BY-NC-ND license (<http://creativecommons.org/licenses/by-nc-nd/4.0/>).

Our patient's medical history was significant for cryptogenic cirrhosis, right hypothalamic juvenile pilocytic astrocytoma status-post resection, and radiation (20 years prior) with bilateral occipital ventriculoperitoneal (VP) shunt placement, and panhypopituitarism. He was taking oral hydrocortisone (30 mg/daily) and desmopressin (DDVAP) and was frequently hypernatremic.

On admission, the patient was afebrile with a normal white blood cell (WBC) count of $7.5 \times 10^9/L$ (Day 0). Blood cultures were initially negative. HIV test was negative. ALT was 28 units/L, and AST was 35 units/L. The viral hepatitis panel was negative. Given the patient's history of panhypopituitarism, he was started on stress-dose steroids (IV hydrocortisone 50 mg q8). On day +1, our patient had symptomatic relief of his dyspnea after a thoracentesis removed 1.5 L of transudative fluid (Table 1). A paracentesis was performed the following day, which showed 206 nucleated cells/ μL , and ceftriaxone was discontinued since the cell count differential was not consistent with spontaneous bacterial peritonitis. CT thorax after the thoracentesis revealed a massive left-sided pleural effusion and atypical pneumonia on the right with reactive lymphadenopathy (Fig. 1). On day +3, the serum *Cryptococcal Ag* was positive. Infectious Disease (ID) recommended switching fluconazole to liposomal amphotericin B (3 mg/kg q24h) and flucytosine (25 mg/kg q6h) to treat a disseminated *C. neoformans* infection. Flucytosine toxicities were monitored with daily complete blood count to ensure there was no agranulocytosis. On day +4, the transudative pleural fluid *Cryptococcal Ag* was positive. On day +5, the blood cultures from admission grew *C. neoformans*. In the following days, the pleural and abdominal fluid cultures also grew *C. neoformans* (Fig. 2). Given fungemia, a transthoracic echo was performed, which showed no vegetation. CT of the head did not reveal any ventriculitis. A lumbar puncture was completed, and the CSF was positive for *Cryptococcal Ag* on day +4. The CSF culture was positive, resulting six days later (+6). The patient was transferred to the neurologic intensive care unit for the removal of his VP shunt and placement of an external ventricular drain (EVD).

The patient had the left VP shunt removed; however, the right could not be removed due to adhesions. The CSF was monitored frequently and remained positive for *Cryptococcal Ag* until the tenth day of antifungal therapy. On day +11, a therapeutic thoracentesis revealed an exudative, serosanguinous fluid (Table 1), which grew three *Cryptococcus* colonies. The patient became lethargic with altered mental status. An EEG was consistent with non-convulsive status epilepticus, and our patient was placed on levetiracetam and lacosamide. He was intubated and put on a midazolam drip with ketamine to achieve burst suppression. The patient required pressor support at this time. Nephrology was consulted for anuric AKI, which was likely due to acute tubular necrosis. The patient had stopped responding to furosemide diuresis and was started on continuous veno-venous hemofiltration (CVVH). His flucytosine was renally adjusted to 25 mg/kg q24 rather than q6. The patient

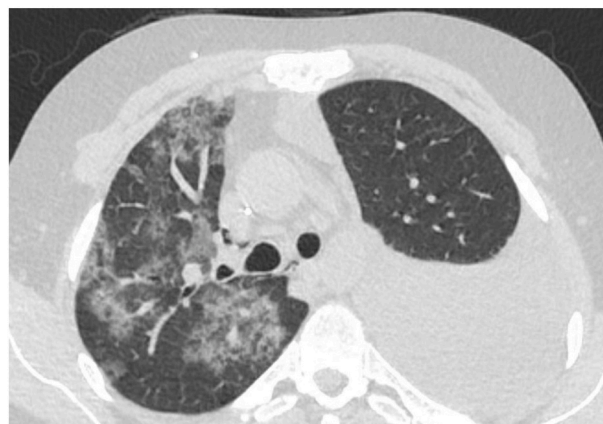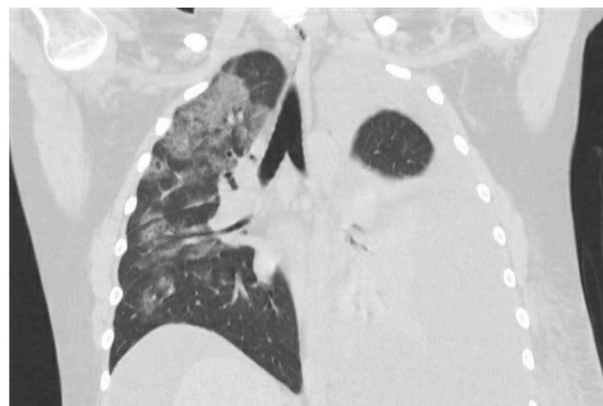


Fig. 1. CT thorax showing right sided *Cryptococcus* pneumonia with mediastinal and hilar lymphadenopathy. There is a massive left sided pleural effusion that was present despite a therapeutic thoracentesis performed the previous day removing 1.5 L of transudative fluid.

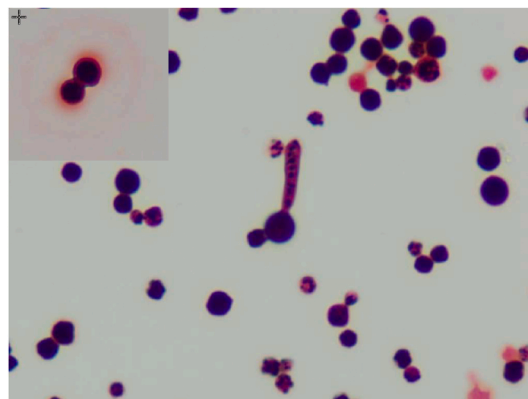


Fig. 2. Gram stain of the culture from pleural fluid. The insert depicts a budding cryptococcal yeast cell.

Table 1

Comparison of pleural fluid and ascitic fluid at different time points. Notice that the initial pleural fluid on 9/5 is transudative according to Light's criteria whereas 9/15 pleural fluid is exudative.

Date	9/5	9/6	9/15	9/18
Fluid Type	Pleural	Ascitic	Pleural	Ascitic
Clarity	Cloudy	Cloudy	Cloudy	Turbid
Color	Orange	Orange	Red	Yellow
Lymphocyte (%)	30	56	51	76
Monocyte (%)	44	9	39	4
Neutrophil (%)	23	33	10	20
RBC (μL)	12, 995	13, 800	92, 571	12, 237
Total Nucleated Cells (μL)	789	206	536	357
Amylase (U/L)	75	83	39	–
Glucose (mg/dL)	104	120	136	–
Pleural Lactate Dehydrogenase (U/L)	94	88	314	–
Serum Lactate Dehydrogenase (U/L)	220	–	490	–
Pleural Total Protein (g/dL)	1.7	1.9	2.0	1.1
Serum Total Protein (g/dL)	4	4	3.7	3.5

further deteriorated with worsening septic shock despite negative repeat blood cultures drawn on day +13. The patient was started on piperacillin/tazobactam and vancomycin, which were later changed to meropenem and daptomycin. The patient required five pressors, sodium bicarbonate infusion, and an increase in stress steroids. He developed shock liver with disseminated intravascular coagulopathy (DIC). On day +14, the patient started to bleed from his nasogastric tube. He was given multiple transfusions of blood, platelets, fresh frozen plasma, and cryoprecipitate. After a discussion with the family the following day, the patient was placed on comfort care measures and died later that

afternoon.

3. Discussion

C. neoformans is an opportunistic and pathogenic fungus usually acquired by inhalation of yeast or basidiospores from environmental sources such as bird droppings and soil [9]. The infection may remain in the lungs, but in immunocompromised states such as HIV, the fungus can disseminate to the central nervous system, skin, and other parts of the body [10]. An immunodeficient state associated with *Cryptococcus* is liver cirrhosis, which was the likely risk factor of our patient. There are various *Cryptococcal* presentations in cirrhotic patients, including meningitis, pneumonia, peritonitis, pleuritis, and disseminated infection [7, 8, 11–15]. We present a case of disseminated *Cryptococcus* infection who initially presented with a transudative pleural effusion that was antigen-positive and culture-positive for *C. neoformans*. To our knowledge, this is the first case report of a transudative pleural effusion with a positive *Cryptococcal* Ag and culture.

Disseminated *Cryptococcosis* is based on positive cultures from any two organ sites or positive blood culture [12, 13, 16]. Our patient's pleural fluid, peritoneal fluid, cerebral spinal fluid (CSF), and blood grew *C. neoformans* at various points in time (Fig. 2). Although the infection source was not identified in our patient, there are two possibilities: lungs or gastrointestinal (GI) tract. Cirrhotic patients are susceptible to increased gut permeability of microorganisms, including fungi, into the bloodstream due to damage to the gut-associated lymphoid tissue [12]. The immunocompromised state that cirrhotic patients experience is called cirrhosis-associated immune dysfunction (CAIDS). CAIDS denotes systemic failure of innate and adaptive immunity [4, 12, 13, 17, 18]. This immune dysfunction could explain how subclinical *Cryptococcal* pneumonia and pleural effusion seen in our patient proceeded quickly to disseminate infection.

Cirrhotic patients with *Cryptococcosis* have a high mortality rate. In one study, all patients with liver cirrhosis died within the first month after the diagnosis of *C. Neoformans* [19]. A delay in the diagnosis of disseminated disease may be a contributing factor to increased mortality rates. The presentation of *Cryptococcal* infection in individuals with liver disease is highly variable. Some patients are asymptomatic, while others rapidly progress to respiratory failure. Presentation variability may contribute to a delay in diagnosing this patient population and ultimately impact their mortality rates [2]. Despite their increased risk, these immunocompromised individuals can still be adequately treated with 400 mg of fluconazole daily for 6–12 months for mild to moderate *Cryptococcal* pneumonia [5]. At the first sign of *Cryptococcal* meningitis or disseminated disease, the patient should be transitioned to amphotericin (IV 0.7–1 mg/kg/day) +/- flucytosine (100 mg/kg/day) for two weeks followed by fluconazole (400–800 mg/d) for 8 weeks and then fluconazole (200 mg/d) for 6–8 months [5].

In this case, the initial positive *Cryptococcal* Ag's significance in the transudative effusion was unclear. Transudative effusions are not typically associated with pleural space infections. We considered this a misclassification of the pleural effusion. Although it is more common for Light's criteria to misclassify transudative effusions as exudative, it is also possible for exudative effusions to be misclassified as transudative [20]. In our case, we speculate the cause of the misclassification to be concomitant hepatic hydrothorax. A less likely possibility is the protein extravasation from the capillaries took several days before the effusion reached exudative values. We also believed meningoencephalitis was unlikely because the patient had no fevers or headaches, and the initial confusion improved after less than a day of treatment for hepatic encephalopathy. Because of the above reasons, our initial suspicion of disseminated disease was low. Given the patient's initial improvement on fluconazole and his AKI, we were hesitant to transition the patient to amphotericin. We determined his condition warranted more aggressive treatment with amphotericin when his positive serum *Cryptococcal* Ag and blood cultures revealed the disease was disseminated. This

transition occurred three days after he arrived at our hospital but twelve days since he first presented to the outside hospital.

As seen with previous cases, there is frequently a rapid progression of disseminated *Cryptococcal* disease to multi-organ failure leading to death in cirrhotic patients [12, 13]. Our patient also had other comorbidities, including an AKI and a VP shunt, which further complicated his medical management. Ultimately, he passed away after thirteen days of amphotericin B treatment. An aggressive approach to therapy by starting amphotericin sooner may have changed the outcome. This case highlights the prevalence of *Cryptococcal* infection in cirrhotic patients and the importance of recognizing the ailment despite variable presentations such as transudative pleural effusion.

Funding

This research did not receive any specific grant from funding agencies in the public, commercial, or not-for-profit sectors.

Consent

Written informed consent was obtained from the patient or legal guardian(s) for publication of this case report and accompanying images. A copy of the written consent is available for review by the Editor-in-Chief of this journal on request.

Written informed consent was obtained from the next of kin since the patient is deceased.

Declaration of competing interest

Please declare any financial or personal interests that might be potentially viewed to influence the work presented. Interests could include consultancies, honoraria, patent ownership or other. If there are none state 'there are none'.

Acknowledgements

We thank all the authors for their contributions. Thank you to Dr. Soma Sanya from Pathology Department at Upstate Medical University for obtaining Gram stain images.

References

- [1] E.K. Maziarz, J.R. Perfect [Internet], Infectious Disease Clinics of North America, 30, W.B. Saunders, 2016, pp. 179–206. Available from: <https://www.ncbi.nlm.nih.gov/pmc/articles/PMC5808417/> [cited 2020 Nov 5], *Cryptococcosis*.
- [2] A. Spec, K. Raval, W.G. Powderly, End-stage liver disease is a strong predictor of early mortality in cryptococcosis [Internet], *Open For. Infect. Dis.* 3 (1) (2016 Jan 1). Available from: <https://pubmed.ncbi.nlm.nih.gov/21397731/> [cited 2020 Nov 5].
- [3] Y.-Y. Lin, S. Shiau, C.-T. Fang, Risk factors for invasive *Cryptococcus neoformans* diseases: a case-control study [Internet], in: K. Nielsen (Ed.), *PLoS One* 10, 2015, e0119090. Available from: <https://dx.plos.org/10.1371/journal.pone.0119090>. Mar 6 [cited 2020 Nov 5].
- [4] A.R. Bonnel, C. Bunchorntavakul, K.R. Reddy, Immune dysfunction and infections in patients with cirrhosis [Internet], in: *Clinical Gastroenterology and Hepatology*, vol. 9 *Clin Gastroenterol Hepatol*, 2011, p. 727–38. Available from: <https://pubmed.ncbi.nlm.nih.gov/21397731/> [cited 2020 Nov 5].
- [5] J.R. Perfect, W.E. Dismukes, F. Dromer, D.L. Goldman, J.R. Graybill, R.J. Hamill, et al., Clinical practice guidelines for the management of cryptococcal disease: 2010 update by the infectious diseases society of America [Internet]. *Clin. Infect. Dis.* 50 (2010) 291–322. Available from: <https://pubmed.ncbi.nlm.nih.gov/20047480/> [cited 2020 Nov 5].
- [6] Y. Zhang, S.X. Zhang, J. Trivedi, A.D. Toll, J. Brahmer, R. Hales, et al., Pleural fluid secondary to pulmonary cryptococcal infection: a case report and review of the literature [Internet], *BMC Infect. Dis.* (2019 Aug 12);19(1). Available from: <https://pubmed.ncbi.nlm.nih.gov/31287901534/> [cited 2020 Nov 5].
- [7] M. Chen, X. Wang, X. Yu, C. Dai, D. Chen, C. Yu, et al., Pleural effusion as the initial clinical presentation in disseminated cryptococcosis and fungaemia: an unusual manifestation and a literature review [cited 2020 Nov 9], *BMC Infect. Dis.* 15 (1) (2015 Sep 22) 385. Available from: <http://bmcinfectdis.biomedcentral.com/articles/10.1186/s12879-015-1132-4>.
- [8] M.W. Saif, M. Raj, Cryptococcal peritonitis complicating hepatic failure: case report and review of the literature [Internet], *J. Appl. Res.* 6 (1) (2006 Jan 1) 43–50.

- Available from: <http://www.ncbi.nlm.nih.gov/pubmed/19816551> [cited 2020 Oct 19].
- [9] D.H. Mitchell, T.C. Sorrell, A.M. Allworth, C.H. Heath, A.R. McGregor, K. Papanoum, et al., Cryptococcal disease of the CNS in immunocompetent hosts: influence of cryptococcal variety on clinical manifestations and outcome [Internet], *Clin. Infect. Dis.* 20 (3) (1995 Mar 1), 611–6. Available from, <https://academic.oup.com/cid/article/20/3/611/321682> [cited 2020 Oct 18].
- [10] K.A. Marr, *Cryptococcus gattii* as an important fungal pathogen of western North America [Internet], in: *Expert Review of Anti-infective Therapy*, vol. 10, Taylor & Francis, 2012, p. 637–43. Available from: <https://www.tandfonline.com/doi/abs/10.1586/eri.12.48> [cited 2020 Oct 18].
- [11] S. Albert-Braun, F. Venema, J. Bausch, K.P. Hunfeld, V. Schäfer, Cryptococcus neoformans peritonitis in a patient with alcoholic cirrhosis: case report and review of the literature [Internet], in: *Infection*. *Infection*, vol. 33, 2005, p. 282–8. Available from: <https://pubmed.ncbi.nlm.nih.gov/16091901/> [cited 2020 Oct 19].
- [12] M. Kandula, A.H. Kelkar, N. Liberio, M.K. Aiyer, Cryptococemia in an HIV-negative patient with decompensated liver cirrhosis [Internet], *J. Community Hosp. Intern. Med. Perspect.* 6 (6) (2016 Dec 15). Available from: <https://pubmed.ncbi.nlm.nih.gov/3161803/?report=abstract> [cited 2020 Oct 19].
- [13] B.R. Yehia, M. Eberlein, S.D. Sisson, D.N. Hager, Disseminated cryptococcosis with meningitis, peritonitis, and cryptococemia in a HIV-negative patient with cirrhosis: a case report [Internet], *Cases J.* 2 (10) (2009) 170. Available from: <https://pubmed.ncbi.nlm.nih.gov/18157678/> [cited 2020 Oct 21].
- [14] V. Cleophas, V. George, M. Mathew, S.C. Samal, G.M. Chandy, Spontaneous fungal peritonitis in patients with hepatitis B virus-related liver disease [Internet], *J. Clin. Gastroenterol.* 31 (1) (2000 Jul), 77–9. Available from, <https://pubmed.ncbi.nlm.nih.gov/10914783/> [cited 2020 Oct 19].
- [15] V.K. Paliwal, P.K. Gupta, P. Rai, R. Verma, Cryptococcal meningitis in a patient with hepatitis C virus related decompensated cirrhosis: coincidental or immunologically related? [Internet], *Trop. Gastroenterol.* (2012). ;33(2):146–8. Available from: <https://pubmed.ncbi.nlm.nih.gov/23025064/> [cited 2020 Oct 19].
- [16] S. Suchitha, C.S. Sheeladevi, R. Sunila, G.V. Manjunath, Disseminated cryptococcosis in an immunocompetent patient: a case report [Internet], *Case Rep. Pathol.* 2012 (2012) 1–3. Available from: <https://pubmed.ncbi.nlm.nih.gov/23025064/> [cited 2020 Oct 19].
- [17] N. Sipeki, P. Antal-Szalmas, P.L. Lakatos, M. Papp, Immune dysfunction in cirrhosis [Internet], *World J. Gastroenterol.* 20 (10) (2014 Mar 14), 2564–77. Available from: <https://pubmed.ncbi.nlm.nih.gov/24627592/> [cited 2020 Nov 9].
- [18] A. Albillos, M. Lario, M. Álvarez-Mon, Cirrhosis-associated immune dysfunction: distinctive features and clinical relevance [Internet], in: *Journal of Hepatology*, vol. 61Elsevier, 2014. . p. 1385–96. Available from: <https://pubmed.ncbi.nlm.nih.gov/25135860/> [cited 2020 Nov 9].
- [19] Y.M. Chuang, Y.C. Ho, H.T. Chang, C.J. Yu, P.C. Yang, P.R. Hsueh, Disseminated cryptococcosis in HIV-uninfected patients [Internet], *Eur. J. Clin. Microbiol. Infect. Dis.* 27 (4) (2008 Apr), 307–10. Available from, <https://pubmed.ncbi.nlm.nih.gov/18157678/> [cited 2020 Oct 20].
- [20] L.F. R S-S, L.V. Ce K, H. Jt, Concordant and discordant exudates and their effect on the accuracy of Light's criteria to diagnose exudative pleural effusions [Internet], *Am. J. Med. Sci.* 352 (6) (2016 Dec 1) 549–556. Available from: <https://pubmed.ncbi.nlm.nih.gov/27916209/> [cited 2021 Aug 1].