


Complicated Case of Multidrug-Resistant Tuberculosis with Multiple Comorbidities, Successfully Treated After Several Treatment Modifications

Benedreky Leo¹  and Heni Retnowulan²

¹Department of Internal Medicine, Faculty of Medicine, Public Health, and Nursing, Gadjah Mada University/Dr Sardjito Hospital, Yogyakarta, Indonesia. ²Division of Pulmonology, Department of Internal Medicine, Faculty of Medicine, Public Health, and Nursing, Gadjah Mada University/Dr Sardjito Hospital, Yogyakarta, Indonesia.

Clinical Medicine Insights: Circulatory, Respiratory and Pulmonary Medicine
Volume 16: 1–4
© The Author(s) 2022
Article reuse guidelines:
sagepub.com/journals-permissions
DOI: 10.1177/11795484221142468



ABSTRACT

A 59-year-old man with relapsed pulmonary TB developed rifampin resistance. He presented with chronic untreated hepatitis B, which developed into liver cirrhosis, type 2 diabetes with diabetic retinopathy, and osteoarthritis of right knee. His initial MDR regimen included levofloxacin, cycloserine, bedaquiline, linezolid, and high-dose isoniazid. He developed episodes of linezolid-induced myelosuppression, resulting in temporary discontinuation and dose reduction, and ultimately, substitution of linezolid. On the seventh month of treatment, he developed severe depression with visual hallucination, resulting in cycloserine dose reduction. We maintained the principle of at least 4 active drugs throughout his treatment. He was considered cured after 26 months of treatment.

KEYWORDS: MDR-TB, multiple comorbidities, adverse events, treatment modification

RECEIVED: April 6, 2022. **ACCEPTED:** November 13, 2022.

TYPE: Case Report

FUNDING: The author(s) received no financial support for the research, authorship, and/or publication of this article.

DECLARATION OF CONFLICTING INTERESTS: The author(s) declared no potential conflicts of interest with respect to the research, authorship, and/or publication of this article.

CORRESPONDING AUTHOR: Heni Retnowulan, Jalan Farmako, Sekip Utara, Yogyakarta 55281, Indonesia. Email: heni.retnowulan@ugm.ac.id

Introduction

Multidrug-resistant tuberculosis (MDR-TB) is notoriously difficult to treat with reported cure rate around 57%.¹ Challenges in treating MDR-TB includes limited drug option, long treatment duration, and significant treatment-related adverse events, resulting in treatment non-compliance and ultimately, high rate of treatment failure.² The presence of comorbidities further complicates patient treatment and is associated with higher rate of treatment failure and mortality.^{3,4} Currently, there is very little literature discussing the optimal strategy of MDR-TB treatment with multiple comorbidities. We report a complicated case of MDR-TB with multiple comorbidities successfully treated after several treatment regimen modifications.

Case Report

A 59-year-old Indonesian man was first diagnosed with pulmonary tuberculosis (TB) in 2011, he completed a full course of category 1 treatment of 2RHZE/4RH (rifampicin (R), isoniazid (H), pyrazinamide (Z), ethambutol (E)) and was considered cured. In January 2018 he experienced chronic productive cough with night sweats. His physical examination was unremarkable. His initial sputum GeneXpert showed drug-susceptible *Mycobacterium tuberculosis*. Chest x-ray was performed, showing perihilar lung infiltrates (Figure 1). He was treated with category 2 treatment of 2RHZES/1RHZE/5RH (rifampicin (R), isoniazid (H), pyrazinamide (Z), ethambutol (E), streptomycin (S)). On the fourth month of treatment, his GeneXpert evaluation showed

rifampicin resistant (RR) and was referred to an Indonesian tertiary-care hospital for initiation of MDR-TB treatment.

Choosing the appropriate MDR regimen for this patient was challenging due to his multiple comorbidities, namely: untreated chronic hepatitis B, which developed into decompensated liver cirrhosis (he was diagnosed with hepatitis B in 2011 but only began treatment with tenofovir disoproxil fumarate 300 mg q.d in January 2018); type 2 diabetes (treated with insulin); diabetic retinopathy; and osteoarthritis of right knee. Second-line injectable drugs (SLID) and ethambutol were used in his previous regimens, thus were omitted. Pyrazinamide, ethionamide/prothionamide, and *p*-aminosalicylic acid (PAS) were omitted due to liver cirrhosis. At the time of his MDR treatment initiation, the 2018 World Health Organization (WHO) guideline was not yet published, thus his MDR regimen was designed based on the 2016 WHO guideline. He started his MDR treatment in July 2018 (baseline body weight: 60 kg), which included levofloxacin 875 mg OD, cycloserine 875 mg OD, bedaquiline 400 mg OD for 2 weeks followed by 200 mg OD until the sixth month of treatment, linezolid 600 mg OD, isoniazid 600 mg OD, and pyridoxine 200 mg OD. Monitoring of adverse drug reaction was performed every 2–4 weeks throughout treatment period, which consisted of, but not limited to: symptom recording, routine physical examination, retinal examination, ECG, complete blood count, liver transaminase levels, bilirubin level, and renal function test. On the second month of treatment, he developed thrombocytopenia without bleeding manifestation due to linezolid-induced myelosuppression. Linezolid was



Creative Commons Non Commercial CC BY-NC: This article is distributed under the terms of the Creative Commons Attribution-NonCommercial 4.0 License (<https://creativecommons.org/licenses/by-nc/4.0/>) which permits non-commercial use, reproduction and distribution of the work without

further permission provided the original work is attributed as specified on the SAGE and Open Access page (<https://us.sagepub.com/en-us/nam/open-access-at-sage>).

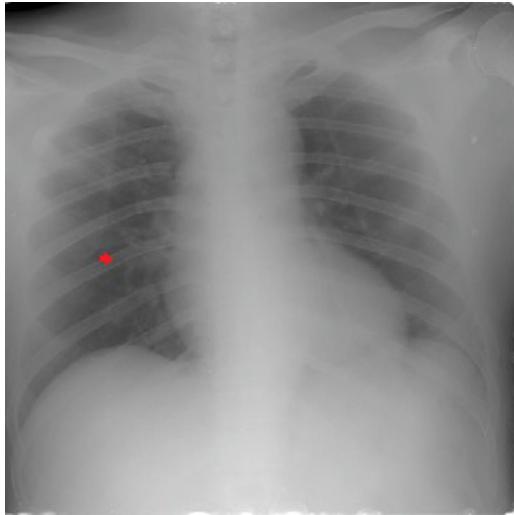


Figure 1. Pre-Treatment chest X-ray showing right perihilar infiltrates.

stopped for 2 weeks and his platelet count increased from 36,000/ μL to 90,000/ μL . Linezolid was reintroduced with lower dose of 300 mg OD. On the seventh month of treatment, he developed severe depression with visual hallucination, which improved after the addition of risperidone 1 mg BID and dose reduction of cycloserine from 875 mg to 500 mg OD. On the 10th month of treatment, he developed pancytopenia due to linezolid-induced myelosuppression. Linezolid was postponed for 2 weeks and reinitiated after resolution of pancytopenia. On the 14th month of treatment, he experienced partial vision loss which was later diagnosed as linezolid-induced optic neuritis. Linezolid was substituted with clofazimine 100 mg OD. Clofazimine was considered as the best option because during this period the 2018 WHO guideline was published and reclassified clofazimine as group B medication (previously as group C medication in 2016 guideline). Since the 14th month of treatment, the regimen of levofloxacin 875 mg OD, cycloserine 500 mg OD, clofazimine 100 mg OD, isoniazid 600 mg OD, and pyridoxine 200 mg OD was maintained until the end of treatment with minimal side effect. He was considered cured after 3 separate negative sputum culture results with total treatment duration of 26 months. Sputum culture and drug susceptibility testing was performed in a government-run out of hospital laboratory. We were unable to receive on time culture result due to technical problems faced by the local laboratory which resulted in the longer treatment duration than the recommended 18–24 months. His complete treatment timeline is summarized in Figure 2.

Discussion

The presence of multiple comorbidities not only significantly limited our treatment options but might have also contributed to the development of severe treatment-related adverse events in this patient, especially related to liver cirrhosis. The main adverse events experienced by this patient were caused by linezolid and cycloserine, both of which are

mainly metabolized in the liver. The permanent discontinuation of linezolid in this patient was due to vision loss caused by linezolid-induced optic neuritis, which might have been predisposed by his diabetic retinopathy. Linezolid inhibits mitochondrial protein synthesis and disruption of cellular proliferation, resulting in myelosuppression and peripheral as well as ocular neuropathy.^{3,5} Linezolid-induced myelosuppression is time-dependent, thus is expected to occur when used long term (≥ 14 days).^{6,7} Fortunately, it's reversible with medication discontinuation and can be resumed with appropriate dose adjustment.^{8,9} On the other hand, linezolid-induced optic neuritis has been associated with permanent vision loss and dose-reduction approach hasn't been proven to be effective risk mitigation strategy.^{10–12} As a consequence of liver cirrhosis, our patient had a baseline platelet count of 110,000/ μL , which might contribute towards the susceptibility of profound thrombocytopenia caused by linezolid. However, it is important to note that his platelet count returned to pre-treatment level after the completion of MDR-TB regimen.

Neuropsychiatric symptom is a frequent adverse event associated with cycloserine and should be routinely assessed, especially when used in combination with isoniazid and levofloxacin.^{13,14} Currently there is no consensus for treating cycloserine-induced neuropsychiatric adverse event. However, it's known to be dose-related with mixed response towards anti-psychotic medications.^{13,15,16} Dose reduction is recommended in patients who are unable to tolerate cycloserine-related toxicity.¹⁷

Treatment-related adverse event in MDR-TB is very common with estimated frequency reported to be around 90%, around half of which require regimen modification, and around 5% of patients require permanent discontinuation of the offending drug.¹⁸ However, treatment outcome is generally unaffected, provided the patient remained compliant.¹⁹ When modifying treatment regimen, we always maintained the principle of at least 4 active drugs as recommended by the WHO guideline.²⁰ Discontinuation of linezolid in this patient left us with very limited drug option. Fortunately, more recent studies reported clofazimine to have better effectiveness against MDR-TB than previously thought,^{21,22} leading to its reclassification as class B agent in the 2018 WHO guideline and conveniently provided us with excellent substitute for linezolid.²⁰ On May 2022, the WHO published a rapid communication suggesting 6-month BPaLM regimen – comprising bedaquiline, pretomanid, linezolid (600 mg) and moxifloxacin, as well as 9-month all oral bedaquiline-containing regimen.²³ Although compelling, these shorter regimens might be difficult to implement on our patient for several reasons. Firstly, access towards pretomanid is still difficult in Indonesia. Secondly, the dose intensity of linezolid was reduced in our patient due to drug-related toxicity. Thirdly, ethionamide,

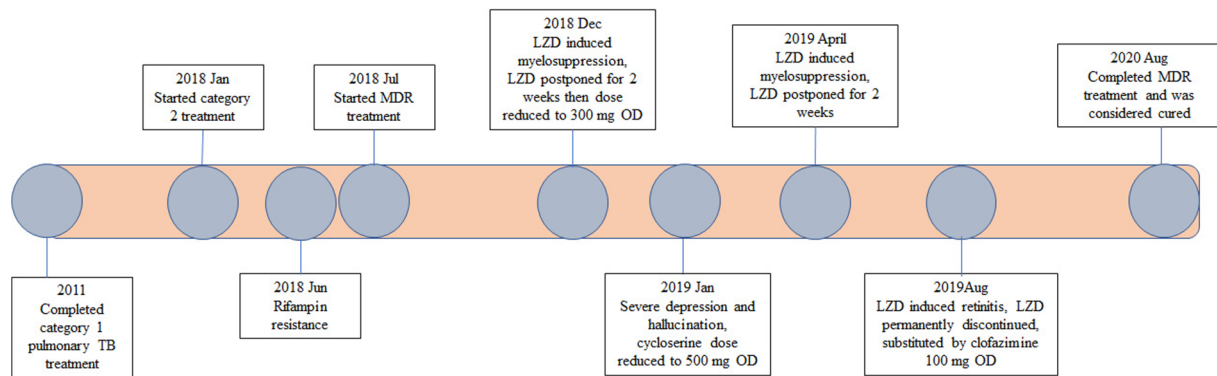


Figure 2. Treatment timeline.

which is a common substitute for linezolid in the 9-month all oral bedaquiline-containing regimen, couldn't be given to our patient due to liver cirrhosis.

It should be noted that our lab was unable to examine the resistance towards isoniazid, thus it is still possible that this patient had rifampicin-monoresistant, isoniazid-susceptible strain, explaining the effectiveness of high-dose isoniazid. Nevertheless, we treated this patient as MDR-TB as suggested by the WHO in such circumstances.²⁰ We managed to maintain levofloxacin and high-dose isoniazid throughout the treatment duration and bedaquiline was given for 6 months as recommended which might contribute to the successful microbiological conversion in this patient. We chose to maximize the treatment duration for at least 24 months (which was later extended to 26 months) as this patient might have impaired immune response due to diabetes and liver cirrhosis.^{24,25}

Conclusion

A personalized treatment approach is required in MDR-TB with multiple comorbidities. Treatment regimen should always consist of at least 4 active drugs. Active detection and prompt management of treatment-related adverse events are necessary to ensure treatment safety and success.

Acknowledgements

The authors express gratitude to Sardjito General Hospital for providing the necessary data for this publication.

Author Contribution(s)

Benedreky Leo: Conceptualization; Writing – original draft; Writing – review & editing.

Heni Retnowulan: Conceptualization; Supervision; Writing – original draft; Writing – review & editing.


Consent for Publication

Written informed consent was obtained from the patient for the publication of this case report and the accompanying data.

Availability of Data and Material

N.A

ORCID iD

Benedreky Leo  <https://orcid.org/0000-0003-2800-6669>

REFERENCES

- Chakaya J, Khan M, Ntoumi F, et al. Global Tuberculosis report 2020 - reflections on the global TB burden, treatment and prevention efforts. *Int J Infect Dis.* 2021;113(Suppl 1):S7-S12.
- Lange C, Dheda K, Chesov D, Mandalakas AM, Udwadia Z, Horsburgh CR Jr. Management of drug-resistant tuberculosis. *Lancet.* 2019;394(10202):953-966.
- Bhering M, Duarte R, Kritski A. Predictive factors for unfavourable treatment in MDR-TB and XDR-TB patients in Rio de Janeiro State, Brazil, 2000-2016. *PLoS One.* 2019;14(11):e0218299.
- Baluku JB, Nakazibwe B, Naloka J, et al. Treatment outcomes of drug resistant tuberculosis patients with multiple poor prognostic indicators in Uganda: A country-wide 5-year retrospective study. *J Clin Tuberc Other Mycobact Dis.* 2021;23:100221.
- De Vriese AS, Coster RV, Smet J, et al. Linezolid-induced inhibition of mitochondrial protein synthesis. *Clin Infect Dis.* 2006;42(8):1111-1117.
- Nagiec EE, Wu L, Swaney SM, et al. Oxazolidinones inhibit cellular proliferation via inhibition of mitochondrial protein synthesis. *Antimicrob Agents Chemother.* 2005;49(9):3896-3902.
- Choi GW, Lee JY, Chang MJ, et al. Risk factors for linezolid-induced thrombocytopenia in patients without haemato-oncologic diseases. *Basic Clin Pharmacol Toxicol.* 2019;124(2):228-234.
- Cai Y, Chai D, Falagas ME, et al. Immediate hematological toxicity of linezolid in healthy volunteers with different body weight: A phase I clinical trial. *J Antibiot (Tokyo).* 2012;65(4):175-178.
- Niwa T, Watanabe T, Suzuki A, et al. Reduction of linezolid-associated thrombocytopenia by the dose adjustment based on the risk factors such as basal platelet count and body weight. *Diagn Microbiol Infect Dis.* 2014;79(1):93-97.
- Chang KC, Yew WW, Cheung SW, et al. Can intermittent dosing optimize prolonged linezolid treatment of difficult multidrug-resistant tuberculosis? *Antimicrob Agents Chemother.* 2013;57(7):3445-3449.
- Azamferei L, Copotoiu SM, Branzaniuc K, Szederjesi J, Copotoiu R, Berteanu C. Complete blindness after optic neuropathy induced by short-term linezolid treatment in a patient suffering from muscle dystrophy. *Pharmacoepidemiol Drug Saf.* 2007;16(4):402-404.
- Park IN, Hong SB, Oh YM, et al. Efficacy and tolerability of daily-half dose linezolid in patients with intractable multidrug-resistant tuberculosis. *J Antimicrob Chemother.* 2006;58(3):701-704.
- Court R, Centner CM, Chirehwa M, et al. Neuropsychiatric toxicity and cycloserine concentrations during treatment for multidrug-resistant tuberculosis. *Int J Infect Dis.* 2021;105:688-694.

14. Behera C, Krishna K, Singh HR. Antitubercular drug-induced violent suicide of a hospitalised patient. *BMJ Case Rep.* 2014;2014: bcr2013201469.
15. Bakhla AK, Gore PS, Srivastava SL. Cycloserine induced mania. *Ind Psychiatry J.* 2013;22(1):69-70.
16. Vega P, Sweetland A, Acha J, et al. Psychiatric issues in the management of patients with multidrug-resistant tuberculosis. *Int J Tuberc Lung Dis.* 2004;8(6):749-759.
17. *Companion Handbook to the WHO Guidelines for the Programmatic Management of Drug-Resistant Tuberculosis.* WHO Guidelines Approved by the Guidelines Review Committee. Geneva; 2014.
18. Zhang Y, Wu S, Xia Y, et al. Adverse events associated with treatment of multidrug-resistant Tuberculosis in China: An ambispective cohort study. *Med Sci Monit.* 2017;23:2348-2356.
19. Gualano G, Mencarini P, Musso M, et al. Putting in harm to cure: Drug related adverse events do not affect outcome of patients receiving treatment for multidrug-resistant Tuberculosis. Experience from a tertiary hospital in Italy. *PLoS One.* 2019;14(2):e0212948.
20. *WHO consolidated guidelines on drug-resistant tuberculosis treatment.* WHO Guidelines Approved by the Guidelines Review Committee. Geneva; 2019.
21. Dalcolmo M, Gayoso R, Sotgiu G, et al. Effectiveness and safety of clofazimine in multidrug-resistant tuberculosis: a nationwide report from Brazil. *Eur Respir J.* 2017;49(3).
22. Hwang TJ, Dotsenko S, Jafarov A, et al. Safety and availability of clofazimine in the treatment of multidrug and extensively drug-resistant tuberculosis: Analysis of published guidance and meta-analysis of cohort studies. *BMJ Open.* 2014;4(1): e004143.
23. World Health Organization. *Rapid communication: key changes to the treatment of drug-resistant tuberculosis.* WHO; 2022.
24. Lin YT, Wu PH, Lin CY, et al. Cirrhosis as a risk factor for tuberculosis infection—a nationwide longitudinal study in Taiwan. *Am J Epidemiol.* 2014;180(1):103-110.
25. Kumar Nathella P, Babu S. Influence of diabetes mellitus on immunity to human tuberculosis. *Immunology.* 2017;152(1):13-24.