

## Radiotherapy and radiosurgery for meningiomas

William C. Chen<sup>1</sup>, Calixto-Hope G. Lucas<sup>2</sup>, Stephen T. Magill<sup>3</sup>, C. Leland Rogers<sup>4</sup>, and David R. Raleigh,<sup>1,5</sup> 

<sup>1</sup>Department of Radiation Oncology, University of California San Francisco, San Francisco, CA 94143, USA;

<sup>2</sup>Department of Pathology, University of California San Francisco, San Francisco, CA 94143, USA; <sup>3</sup>Department of Neurological Surgery, Northwestern University, Chicago, IL 60611, USA; <sup>4</sup>Radiation Oncology, GammaWest Cancer Services, Salt Lake City, UT, USA; <sup>5</sup>Department of Neurological Surgery, University of California San Francisco, San Francisco, CA 94143, USA

**Corresponding Authors:** David R. Raleigh, MD PhD, Assistant Professor, Robert and Ruth Halperin Endowed Chair in Meningioma Research, Brain Tumor Center Principal Investigator and Preclinical Therapeutics Core Director, Departments of Radiation Oncology and Neurological Surgery, University of California, San Francisco, San Francisco, CA, USA ([david.raleigh@ucsf.edu](mailto:david.raleigh@ucsf.edu), [NeuroPub@barrowneuro.org](https://neuro.pub/barrowneuro.org)); C. Leland Rogers, MD, Radiation Oncology, GammaWest Cancer Services, Salt Lake City, UT, USA ([lelandrogers@mac.com](mailto:lelandrogers@mac.com))

### Abstract

Meningiomas comprise a histologically and clinically diverse set of tumors arising from the meningotheial lining of the central nervous system. In the past decade, remarkable progress has been made in deciphering the biology of these common neoplasms. Nevertheless, effective systemic or molecular therapies for meningiomas remain elusive and are active areas of preclinical and clinical investigation. Thus, standard treatment modalities for meningiomas are limited to maximal safe resection, radiotherapy, or radiosurgery. This review examines the history, clinical rationale, and future directions of radiotherapy and radiosurgery as integral and effective treatments for meningiomas.

### Keywords

central nervous system | meningioma | radiation | radiosurgery | radiotherapy

## History of Meningioma Radiotherapy

Some of the earliest published reports using X-rays to treat meningioma are found in Cushing and Eisenhardt's seminal monograph *Meningiomas*, published in 1938.<sup>1</sup> Early application of radiotherapy for meningiomas was sporadic, used varying doses and techniques, and was reserved for recurrent, refractory, or occasionally inoperable tumors. The early observation that rapid meningioma regression after radiotherapy was uncommon led some investigators to conclude that meningioma was "radiation insensitive."<sup>2</sup> Nevertheless, some surgeons, including Donald Simpson in his influential 1957 surgical series,<sup>3</sup> recognized at least some utility for meningioma radiotherapy, noting that "after subtotal resections generally, there is also a case for irradiation."

In 1975, William Wara reported one of the first sizeable meningioma radiotherapy series from patients who were treated

surgically, with or without postoperative radiotherapy, at the University of California San Francisco between 1942 and 1975.<sup>4</sup> Of 213 patients, 84 underwent "total" meningioma resection with no recurrences. Of 92 patients with subtotal resection, 58 were observed and 34 underwent immediate radiotherapy (between 3000 and 5500 rads, or 30–55 Gy using modern nomenclature). The crude recurrence rate in this early study was substantially improved among patients who received adjuvant radiotherapy, from 74% to 29%. These data would be later updated in 1994 by Goldsmith et al,<sup>5</sup> identifying significant improvements in tumor control over time after the advent of CT- and MRI-based radiotherapy planning, and the iterative discovery that radiotherapy dose escalation above 52 Gy was of benefit for many meningiomas.

Subsequent smaller series by Carella et al<sup>6</sup> from New York University in 1982, Solan and Kramer<sup>7</sup> from Thomas Jefferson in 1985, and Petty et al<sup>8</sup> from the Medical College of Wisconsin in 1985 reported similar conclusions about the efficacy and

safety of postoperative radiotherapy in preventing or delaying meningioma recurrence after subtotal resection. In 1981, Smith et al<sup>9</sup> described the first successful application of radiotherapy for optic nerve sheath meningiomas, reporting improvement in visual acuity and/or disease stabilization in five cases. Due to the high risk of blindness from resection of optic nerve sheath meningiomas, radiotherapy appeared to offer a safe and effective alternative primary treatment for an otherwise challenging subset of tumors. More broadly, the 1980s would see the advent of stereotactic radiosurgery and many other technological advances in the delivery of ionizing radiation, marking the beginnings of modern radiotherapy in the treatment of meningiomas.

## Rationale of Meningioma Radiotherapy

It has long been recognized that complete resection of meningioma, when possible, offers the best chance for local control. In 1957, Simpson<sup>3</sup> described a grading system for the extent of meningioma resection, according to which an optimal grade 1 resection required complete tumor removal along with its “dural attachment” and any “abnormal bone” or involved venous sinus. Simpson grade 2 resection required coagulation of the dural attachment, and Simpson grade 3 necessitated complete resection of the intradural tumor with no coagulation or resection of the dura or other involved sites such as the “invaded dural sinus.” Subtotal resections and biopsies were encapsulated in Simpson grade 4 or grade 5 resections, respectively. With long-term follow-up in the pre-imaging era, Simpson observed a gradation in meningioma crude recurrence rates: 9% with Simpson grade 1, 19% with Simpson grade 2, 29% with Simpson grade 3, and 44% with Simpson grade 4.

Meningioma surgical outcomes have improved in the decades since Simpson’s seminal report. Still, several large modern series have posited the enduring relevance of the Simpson grade,<sup>10,11</sup> and the prognostic significance of gross total versus subtotal resection for meningioma control is well-established. In modern practice, an individualized approach balancing aggressive margin clearance against the surgical risk to sensitive structures, as well as consideration of patient- and tumor-specific factors such as meningioma biology, location, imaging features, accessibility, symptom burden, and the possibility of adjuvant and/or salvage radiotherapy or radiosurgery, has been encouraged by many authors, some of whom have called into question the relevance of Simpson grading for meningiomas in the modern era.<sup>12,13</sup>

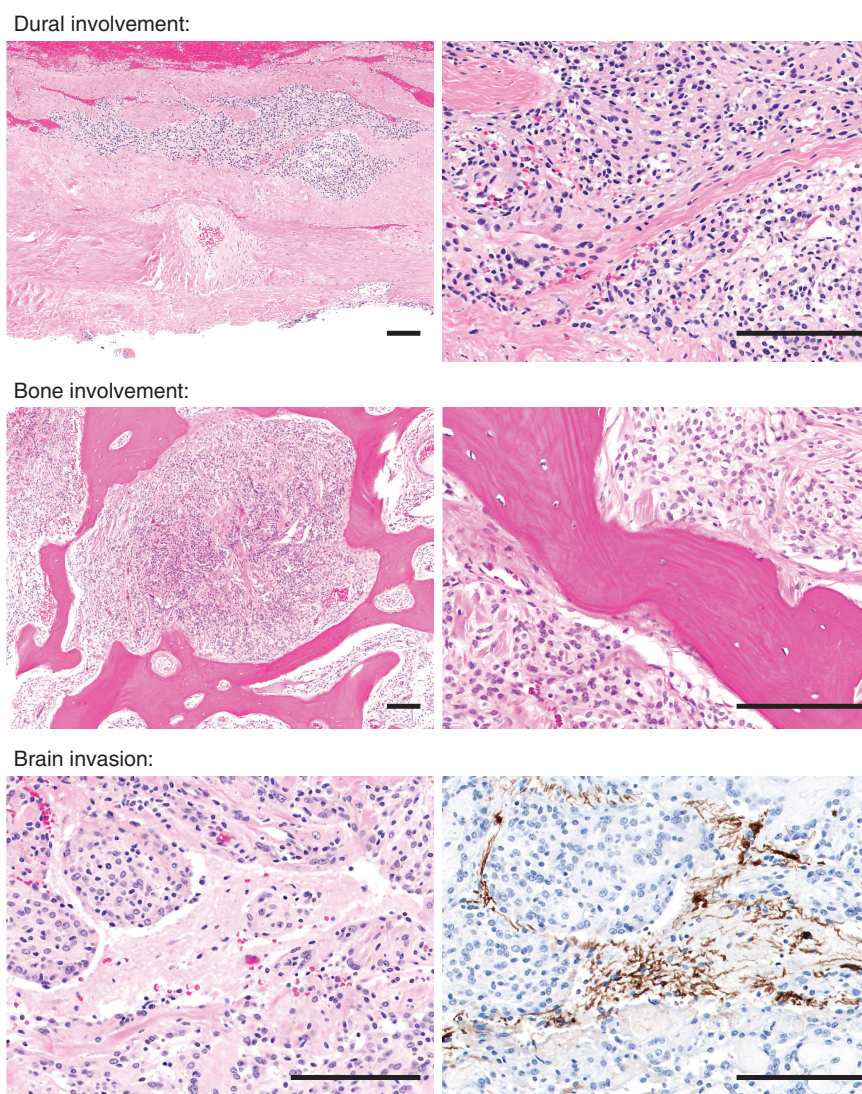
Simpson’s early observations rigorously defined the etiology of meningioma recurrence after resection, and these insights provide a useful framework for integrating the surgical and pathological observations accumulated in the intervening decades, which guide the rationale and design of postoperative meningioma radiotherapy. In brief, the etiologies of meningioma recurrence suspected by Simpson included (i) subdural extension, dural and venous/sinus invasion, (ii) bone invasion, (iii) brain invasion, and (iv) regional multicentric foci of disease, such as satellite lesions (Figure 1).

## Dural and Sinus Invasion

Dural extension or infiltration of varying extent appears to be a common feature of meningiomas of all grades.<sup>14-22</sup> Simpson noted “the dural attachments were invaded in a very large number of cases.” Further, he observed “plaque-like extensions” in the subdural space in 8.5% of cases, and a “thin, flat fringe extending [...] for a centimeter or so” which he linked to recurrences in several cases<sup>3</sup>. MRI-era histologic studies appear to corroborate these observations. Hutzelmann et al<sup>14</sup> in 1998 examined 54 patients with meningioma, 31 of whom had a “flat, contrast-enhancing, probably dural structure adjacent to the tumor.” This linear, enhancing dural margin was invaded by a tumor on surgical pathology in 20 of 31 cases (65%). However, even in the absence of thickened adjacent dura on imaging, Hutzelmann et al noted invasion of surrounding dura on histology in 7 of 23 (30%) cases. The distance of average or maximal infiltration was not noted, but at least 1.5cm of dura was taken in all cases. Other investigations have confirmed that microscopic clusters of meningioma cells are encountered in randomly selected dural strips surrounding meningiomas.<sup>23</sup>

In more recent studies, the radiologic findings described above are commonly referred to as a “dural tail,” an imaging-defined finding of a gradually tapering, hyper-enhancing, thickened dura adjacent to a meningioma or other dural-based tumors.<sup>24</sup> Although the dural tail has been described to consist largely of engorged vasculature and fibrous, hypervascular connective tissue, various reports have identified meningioma cells in the dural margin. For example, Rokni-Yazdi et al<sup>18</sup> in 2009 presented a series and literature review comprised of 74 pathologic reports that revealed evidence of meningioma cells in the dural tail in 51% of cases.

The controversies surrounding the cellular architecture of dural tails are amplified by the observation that hyper-enhancing dura adjacent to meningiomas can have different appearances on MRI, ranging from smooth and tapering, to nodular, or a mixture of multiple imaging characteristics. Qi et al<sup>16</sup> in 2012 described histologic correlates of these MRI findings in 179 convexity meningiomas status post Simpson grade 1 resection. The resected dura was carefully examined at 5mm radial increments from the tumor base to the distal extent, up to 3cm in some resections. Consistent with prior reports, 7 of 16, or 44%, of “smooth type” dural margins contained tumor up to a distance of 1.5 cm. The overall rate of dural invasion, however, was 88.3%, or 158 of 179 tumors, and was more frequent among nodular and mixed type dural tails, for which tumor was occasionally found extending even to a distance of 3 cm. The authors reported 2.5 cm margins were enough to encompass 95% of cases of invasion, and 2 cm margins encompassed 82% of cases of invasion. The nodular type margin was more common and dural invasion was nearly uniform among 25 WHO grade 2–3 tumors, although it is notable that significant changes have been made to the WHO classification of meningiomas since these foundational reports were published. Moreover, the extent of dural invasion has not been investigated in the context of meningioma DNA methylation groups, gene expression programs, or somatic short variants (SSV) influencing clinical outcomes,



**Figure 1.** Microscopic invasion of adjacent structures by meningioma. Histologic examination of grossly uninvolved dura adjacent to a meningioma often reveals small nests of meningioma tumor cells embedded within fibrous connective tissue (left 50 $\times$ , right 200 $\times$  magnification). The hyperostotic bone overlying a meningioma can demonstrate viable tumor cells between lamellar osseous trabeculae (left 50 $\times$ , right 200 $\times$  magnification). Closer examination of the irregular meningioma–brain interface of a brain-invasive meningioma may reveal entrapped tongues of brain parenchyma flanked by nests of meningioma, as highlighted with GFAP immunohistochemistry (left and right 200 $\times$  magnification). Scale bars, 100  $\mu$ m.

and the biologic drivers underlying meningioma tumorigenesis may influence the extent of dural invasion as well as the likelihood of these microscopic deposits to result in tumor regrowth. Thus, further investigation is needed to define how meningioma biology may influence surgical, radiotherapy, or radiosurgical planning in the context of surrounding tissue invasion.

Irrespective of meningioma grade or molecular features, dural sinus invasion can be influenced by tumor location and is particularly common for parasagittal meningiomas.<sup>25–27</sup> Indeed, dural sinus invasion was observed to be an important source of recurrence by Simpson in 1957,<sup>3</sup> and modern evidence suggests parasagittal meningiomas harbor genetic or epigenetic features underlying aggressive clinical behavior. However, due to

morbidity associated with dural sinus resection,<sup>27,28</sup> residual meningioma is sometimes purposefully left behind in this location to minimize the risk of venous injury, cerebral edema, or infarct.<sup>25</sup>

In sum, the inclusion of an adequate margin of at-risk dura and/or dural sinus is important for meningioma surgery, radiotherapy, or radiosurgery, especially for high-grade tumors and for meningiomas with aggressive molecular features. The extent of margin at-risk should be tailored according to meningioma- and patient-specific characteristics.<sup>29</sup> Evolving understanding of biological drivers, some of which correlate with meningioma location, is likely to refine meningioma radiotherapy and inform optimal margins for radiosurgery and fractionated radiotherapy in the future.

## Bone Involvement

Hyperostosis is frequently observed in calvarial or skull base bones adjacent to meningiomas and is thought to be due to reactive changes, perhaps with a contribution from tumor infiltration. Osteolytic changes can also be seen, and histologic studies indicate hyperostotic bone is infiltrated with meningioma cells in 23–90% of cases,<sup>30–33</sup> with significant variation among series. Bone infiltration, in general, has been reported in 7–18% of meningiomas,<sup>34–37</sup> and may be seen even in the absence of radiologic bone abnormality.<sup>33</sup> The significance of hyperostosis as an independent risk factor or nidus for recurrence is not well defined, and the frequency or degree of meningioma infiltration may vary according to tumor location or biology.<sup>38</sup> Indeed, Simpson identified hyperostosis in 36% of his meningioma patients, but also noted that recurrence from invaded bone was uncommon and felt its importance may be overstated.<sup>3</sup>

Common surgical practice is to drill away hyperostotic bone to clear this margin, provided adjacent critical structures can be preserved. Meningioma bone involvement has been suggested to be associated with greater recurrence risk, but it is unclear if the infiltrated bone itself serves as a nidus of recurrence, or if the presence of bone infiltration is a marker of aggressive biology. Intraoperative histologic examination of bone is not common during meningioma resection, and interpretation of the available literature is limited by differing definitions of bone involvement based upon pathology, imaging, intraoperative observations, or a combination thereof.

In sum, until further research illuminates the matter, the inclusion of suspected areas of bone invasion or bone hyperostosis should be considered on a case-by-case basis when designing meningioma radiotherapy or radiosurgery fields and may be sensible when it can be safely accomplished. Pathologic, imaging, or intraoperative findings may be particularly informative for radiotherapy or radiosurgical planning, and further investigation is needed to determine if biologic drivers of meningioma bone involvement can be deconvolved from generic features associated with invasion of surrounding tissues.

## Brain Invasion

Brain invasion is thought to be infrequent in otherwise benign meningiomas, with a reported rate of 3.7% by Simpson<sup>3</sup> and significant variation in subsequent studies.<sup>39</sup> Precise elucidation of the frequency and significance of brain invasion is limited by heterogeneity in definition and heterogeneity in surgical or pathological practice. Broadly, the grossly normal adjacent brain should not be removed during meningioma resection. However, the surgical impression of brain invasion may not be a reliable surrogate, with either no gross evidence of invasion or with leptomeningeal adhesion masquerading as brain parenchymal invasion.<sup>40</sup>

Identification of brain invasion in surgical pathology often depends on incidental detection of microscopic brain tissue at the tumor periphery. The presence of

evaluable brain tissue itself appears to be correlated with meningioma grade, location, and technical aspects of surgery and pathologic analysis.<sup>41</sup> Indeed, a greater number of tissue blocks examined correlates with a higher rate of identification of brain invasion, which was found in 9.4% of otherwise WHO grade 1, 41% of WHO grade 2, and 100% of WHO grade 3 meningiomas in one series.<sup>42</sup> Meningiomas with aggressive biology encoding generic invasion mechanisms may be more adherent to adjacent brain,<sup>43</sup> increasing the likelihood of brain tissue in resection specimens, but perhaps leading to an underestimation of invasion of surrounding tissues for otherwise benign meningiomas.

It is not well established whether the pattern of brain invasion is of significance, as meningioma cells may project into the brain in finger-like extensions, distinct islands, or, in rare instances, diffusely. Multiple studies demonstrate that the presence of brain invasion plus additional pathologic features of atypical or anaplastic meningioma portends poorer prognosis and greater risk of recurrence,<sup>44–46</sup> but the prognostic significance of isolated incidental brain invasion in the absence of other high-grade features, so-called “brain invasion in otherwise benign” (BIOB) meningiomas,<sup>47</sup> remains controversial. Conflicting studies suggest a favorable prognostic profile comparable to benign meningiomas for BIOB tumors,<sup>44</sup> or aggressive behavior comparable to WHO grade 2 meningiomas for BIOB tumors.<sup>40</sup> Radiologic features (Figure 2) such as loss of a cerebrospinal fluid cleft, indistinct brain-tumor interface, or peritumoral edema may also help distinguish the degree of brain invasion,<sup>48</sup> although further data are needed and histologic analyses are not routinely correlated with radiologic findings.

As is the case for bone invasion, there is a lack of reliable data describing direct causality between the presence of microscopic residual meningioma cells in the adjacent brain parenchyma and meningioma recurrence. Frank intraparenchymal recurrence is generally rare and appears to be restricted to anaplastic meningiomas or multiply recurrent, treatment-refractory meningiomas.<sup>29,49</sup> Data regarding the typical depth of brain invasion is also lacking, although the distance of brain invasion is likely to be much smaller than that of bone or dura, and much smaller than that of primary glial or neuronal neoplasms.

In sum, it is unclear whether the inclusion of an explicit brain parenchymal margin is necessary for meningioma radiotherapy routinely, or only in cases with documented brain invasion, or in select cases felt to be at high risk of brain involvement or recurrence based on grade, anatomic location, and imaging or molecular features. Thus, the inclusion of an intraparenchymal brain margin should be carefully considered on a case-by-case basis so as to limit the volume of otherwise normal brain receiving high-dose radiotherapy.

## Rationale for Meningioma Radiotherapy

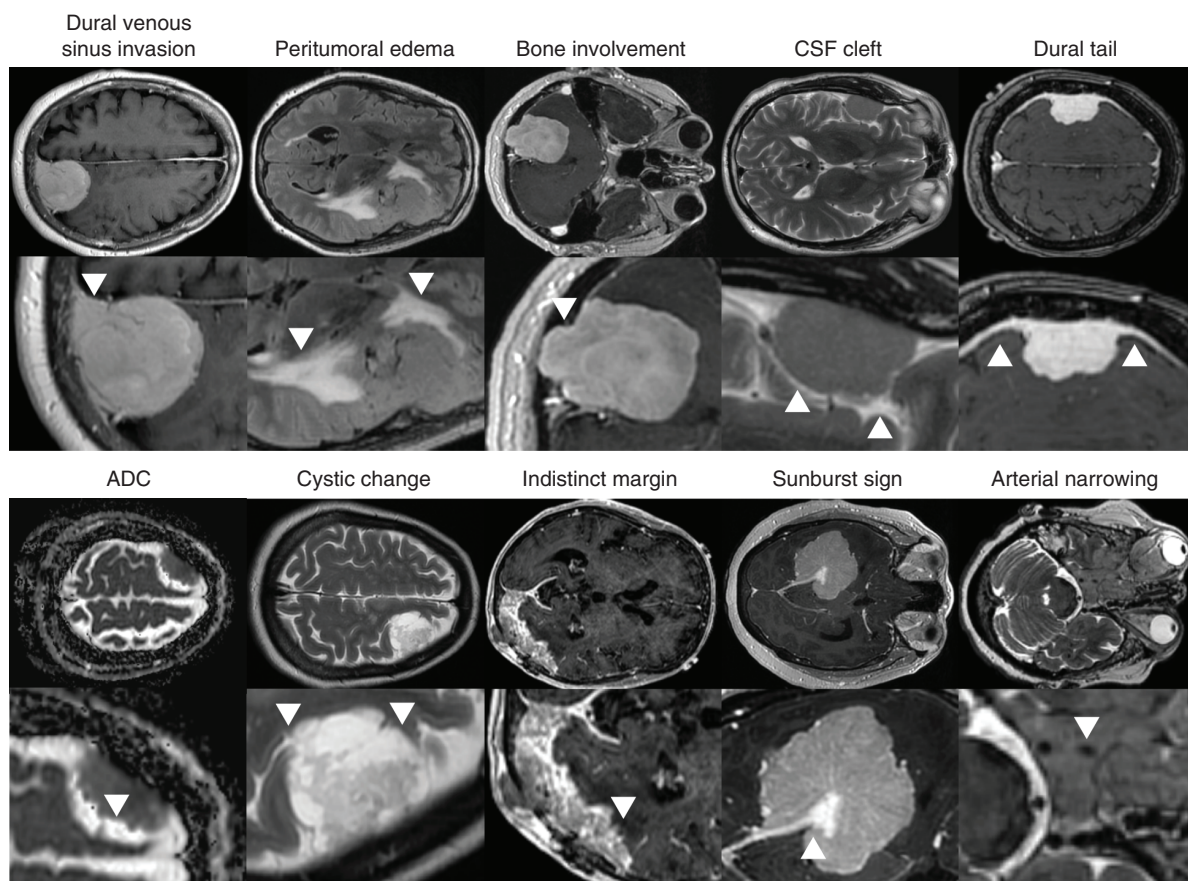
In summary, the surgical and pathological data regarding the frequency, extent, and consequences of meningioma invasion of the dura, dural sinus, bone, or brain are consistent with a neoplasm described by Simpson to be

“prone to infiltrate locally and to recur from such infiltrations.” As infiltrative meningiomas can be difficult to resect without causing undue morbidity, radiotherapy or radiosurgery are important components of individualized and comprehensive care for patients with meningiomas. Contrary to their historical reputation as a radiation insensitive tumor, approximately 80–90% of meningiomas are radiosensitive, with only a small minority of meningiomas growing through radiotherapy treatment.<sup>50</sup> Thus, ionizing radiation may be used to treat microscopic residual meningioma after surgery, to provide local control of gross residual meningioma, to salvage postoperative meningioma recurrence, or as an effective primary treatment to control or shrink meningiomas with potential improvement in clinical symptoms from the mass effect that are otherwise not amenable to resection.

## External Beam Radiotherapy

### Evidence: WHO Grade 1 Meningioma

There is substantial evidence supporting the efficacy of radiotherapy as a treatment for WHO grade 1 meningiomas. Maclean et al<sup>51</sup> in 2014 summarized 18 studies comprised of over 1000 patients and reported outcomes of external beam radiotherapy (EBRT) across a dose range of 45–57.6 Gy (most commonly 50.4–54 Gy). Local control at 5–10 years ranged from 89% to 100%, and rates of late toxicity were 0–12%, with most studies reporting toxicity between 0% and 5%, overwhelmingly low grade. These rates are comparable to the reported rates of 5-year local recurrence of benign meningiomas after gross total resection,



**Figure 2.** Radiologic Features of Meningiomas. Figure reproduced and used with permission from Morin, Chen et al.<sup>48</sup> Examples of radiologic features annotated on preoperative MRIs, such as axial T1 post-contrast image showing a dural tail (arrows) from a right frontal meningioma, axial T2 image showing a CSF cleft sign (arrows) from a right temporal meningioma, axial T1 post-contrast image showing bony involvement (arrow) of the right occipital bone from a right cerebellar meningioma, axial FLAIR image showing peritumoral edema (arrows) from a left frontal meningioma, axial T1 post-contrast image showing dural venous sinus invasion (arrow) from a left posterior parasagittal meningioma, axial T2 image showing narrowing of the right internal carotid artery flow void (arrow) from a multi-compartmental right skull base meningioma, axial T1 post-contrast image showing a “sunburst” sign (arrow) in a right tentorial meningioma, axial T1 post-contrast image showing an indistinct tumor margin with brain parenchyma (arrow) from a left occipital meningioma, axial T2 image showing cystic changes (arrows) in a left frontal meningioma, and an ADC map showing signal hypointensity (arrow) in a right frontal meningioma. Of these features, venous sinus involvement, absence of CSF cleft, ADC hypointensity, peri-tumoral edema, and indistinct margins were associated with increased risk of local failure.<sup>48</sup>

which range from 7% to 23%.<sup>52</sup> Thus, radiotherapy alters the natural course of benign and imaging-defined meningiomas, and also appears to improve local control after subtotal resection of WHO grade 1 meningiomas. Among 7 studies identified by Maclean et al reporting local control after subtotal resection versus subtotal resection followed by EBRT, freedom from progression at 5-years was improved from 38–60% to 80–100% with the addition of EBRT. More recently, the low-risk arm of RTOG 0539 reported 5-year progression-free survival of WHO grade 1 meningiomas after subtotal resection and observation of 72.7%, suggesting concordance between myriad retrospective reports and modern prospective trials.<sup>53</sup>

Multiple studies have reported consistent rates and degrees of meningioma volume reduction after radiotherapy or radiosurgery, with ~30–35%<sup>50,54,55</sup> reduction in size largely occurring during the first two to three years after treatment. Neurological symptom improvement following radiotherapy has been reported in 23–89% of cases,<sup>56–58</sup> although surgery offers faster and more complete relief from symptoms secondary to meningioma mass effect and edema. As intimated above, some of the best data supporting the efficacy and safety of EBRT in the treatment of meningiomas can be found for tumors arising from the optic nerve sheath or cavernous sinus. Vision improvement is seen in 36–80% of optic nerve sheath meningiomas after EBRT, and partial response or stability of tumor is seen in 90–100% of cases, with a very favorable toxicity profile.<sup>59</sup> EBRT for cavernous sinus meningiomas results in tumor control rates of 92–97% at 5–10 years, tumor reduction in 18–30% of cases, and improvement of neurological deficits in 45–71% of cases,<sup>60</sup> although most symptomatic improvements are partial rather than complete.

### Evidence: WHO Grade 2 Meningioma

The evidence supporting the efficacy of radiotherapy as a treatment for WHO grade 2 (atypical) meningiomas after subtotal or gross total resection has grown to be significant, and now includes at least two prospective non-randomized trials: RTOG 0539<sup>61</sup> and EORTC 22042-26042.<sup>62</sup> Further, two recent systematic reviews and meta-analysis have summarized the available observational data in support of adjuvant radiotherapy after subtotal or gross total resection of WHO grade 2 meningiomas. In a pooled meta-analysis, Song et al<sup>63</sup> identified 24 studies comprised of 3078 patients with atypical meningiomas, and reported postoperative radiotherapy improved progression-free survival after either subtotal resection (pooled hazard ratio 0.41, 95% CI 0.30–0.55) or gross total resection (pooled hazard ratio 0.73, 95% CI 0.52–0.92). Chun et al<sup>64</sup> focused on studies reporting outcomes of atypical meningioma after gross total resection, identifying 25 studies with 1232 patients not receiving postoperative radiotherapy and 384 patients receiving postoperative radiotherapy after gross total resection. The pooled data showed a significant benefit of adjuvant radiotherapy after gross total resection in improving local recurrence, with a pooled hazard ratio of 0.50 (95% CI 0.36–0.68), and progression free survival (pooled hazard ratio 0.66, 95% CI 0.51–0.84), with low to moderate study-level heterogeneity.

RTOG 0539 and EORTC 22042 are Phase II prospective trials conducted largely in North America or Europe, respectively. In the intermediate-risk arm of RTOG 0539,<sup>61</sup> 36 of 52 patients had newly diagnosed WHO grade 2 meningiomas status post gross total resection, and 16 had recurrent WHO grade 1 meningiomas. Following 54Gy of EBRT, 3-year progression-free survival for patients enrolled on the intermediate-risk arm of RTOG 0539 was 93.8%, and the rate of local recurrence 4.1%. RTOG 0539 was powered to show an improvement in progression-free survival of at least 20% compared to a historic estimate of 70% at three years, and this endpoint was met. Central review of pathology and MRI imaging for the extent of resection determination were mandatory, and 84.6% of patients received intensity modulated radiotherapy (IMRT), consistent with modern practice. Moreover, radiotherapy was well-tolerated among patients on RTOG 0539, with no grade 3 or higher toxicities attributable to radiation.

EORTC 22042<sup>62</sup> reported outcomes of 56 patients with newly diagnosed WHO grade 2 meningioma status post gross total resection who received postoperative EBRT to 60Gy. Three-year progression-free survival was 88.7%, and the primary endpoint of improvement compared to a historic control was met. The use of 3D conformal radiotherapy (3D-CRT) was more common in EORTC 22042 (46.4%) than in RTOG 0539, and perhaps unsurprisingly, the rate of grade 3–4 late toxicity attributed to EBRT in EORTC 22042 was 8.9% (5 of 56 patients), including 3 patients with seizures, 1 patient with optic neuritis and retinopathy, and 1 patient with cerebral ischemia. Although there was no change in patients' mini-mental status exam at 1, 2, or 3 years after EBRT in EORTC 22042, granular neuropsychiatric testing with greater sensitivity to identify neurocognitive deficits from radiotherapy was not performed. The success of these studies across North America and Europe has provided a foundation for two ongoing Phase III, randomized trials testing the efficacy and safety of postoperative EBRT after gross total resection of WHO grade 2 atypical meningiomas (NRG-BN003 and ROAM/EORTC-1308).

RTOG 0539 and EORTC 22042 comprise the highest levels of evidence currently available for the use of EBRT to treat WHO grade 2 meningiomas. Importantly, these two prospective trials were conducted in the modern era, incorporating more recent standardized WHO grading criteria, which have previously undergone significant changes in 1993 and 2000, and smaller changes in 2007 and 2016, as well as routine MRI imaging for surgical and radiation planning and surveillance, and modern radiotherapy techniques. Substantial heterogeneity still exists in the clinical application of meningioma radiotherapy, and while the published prospective trials provide some guidance, there is significant variability in EBRT target delineation and in the timing of postoperative radiotherapy as an adjuvant treatment versus a salvage intervention.<sup>65</sup> Perhaps due to the availability of effective salvage treatments for meningioma patients in the form of radiotherapy, radiosurgery, and/or repeat resection, the available data do not clearly demonstrate an overall survival benefit from postoperative EBRT, although existing studies have either not been powered to test this endpoint or have not reported outcomes of sufficient duration to identify

overall or disease-specific survival benefits. However, five series<sup>66–70</sup> with very long-term follow-up ranging up to 25 years have noted poor long-term survival among patients with recurrent atypical meningioma. One of these reports with a 25-year follow-up on all living patients reported a mean overall survival of 6 years and no survivors beyond 16 years in this patient population.<sup>68</sup> In addition, salvage therapy can be challenging, less efficacious, and may have disadvantages of higher risks, additional costs, symptoms from tumor regrowth, and the risk of tumor transformation or increased biologic aggressiveness at the time of recurrence.<sup>71–73</sup>

In light of the significant evidence in favor of early postoperative radiotherapy for WHO grade 2 meningiomas, both the European Association of Neuro-Oncology (EANO) and National Comprehensive Cancer Network (NCCN) guidelines recommend EBRT following subtotal resection, with consideration of EBRT following gross total resection.<sup>74,75</sup> It is likely that current and future developments in our understanding of biological drivers or therapeutic vulnerabilities of meningiomas, such as mechanisms underlying radioresistance or biomarkers for radiosensitivity, will allow for a more individualized selection of patients with WHO grade 2 meningiomas who may or may not benefit from postoperative radiotherapy.

### Evidence: WHO Grade 3 Meningioma

WHO grade 3 (anaplastic) meningiomas are rare and aggressive tumors. Studies examining anaplastic meningioma treatments and outcomes are limited, and many investigators have grouped WHO grade 2 and WHO grade 3 meningiomas together for treatment or analysis, as was done for the high-risk strata of RTOG 0539 or EORTC 22042.<sup>76</sup> The available data demonstrate anaplastic meningiomas follow an aggressive clinical course defined by repeated recurrences despite complete resections. Thus, adjuvant EBRT is common for WHO grade 3 meningiomas, although predictive treatment response biomarkers and insights into how adjuvant medical therapies might be optimized for patients with WHO grade 3 meningiomas are lacking.

In the high-risk arm of RTOG 0539 (Table 1), 5-year progression-free survival and overall survival for 17 patients with *de novo* WHO grade 3 meningiomas after surgery and postoperative EBRT to 60Gy was 58.2% and 76.0%, respectively. In two reviews of the literature published in 2014 and 2015,<sup>52,77</sup> 3- to 5-year progression-free survival rates from anaplastic meningiomas ranged from 8.7–61% after a mix of surgery and/or radiotherapy, with most studies reporting rates between 40–50%. Given the aggressive nature of this tumor, current guidelines recommend maximal safe surgical resection and early postoperative EBRT. In treating anaplastic meningiomas with radiotherapy, field design should reflect the nearly uniform propensity of WHO grade 3 meningiomas to invade adjacent dura, at times to a significant degree, as well as the high rates of bone or brain invasion for these relentless malignancies. Although no standard guidelines exist for meningioma radiotherapy field design, individualized margins extending at least 1.5–2.5 cm or more into unresected,

at-risk dura, as well as the inclusion of abnormal bone and a smaller margin into the adjacent brain parenchyma, should be considered.

The role of radiotherapy dose escalation beyond 60Gy for WHO grade 3 meningiomas remain under investigation given the predominance of in-field failures,<sup>78–80</sup> and some limited evidence of radiotherapy dose-response among meningiomas in general. Lee et al<sup>78</sup> used dose escalation to treat gross residual meningiomas to 66Gy with a simultaneous integrated boost, resulting in local control in three of four WHO grade 3 meningiomas and no reported serious toxicity. Chan et al<sup>81</sup> safely dose-escalated gross residual meningiomas to 68.4–72Gy using a mixed photon/proton approach, demonstrating local control in 4 of 4 WHO grade 2 residual tumors after a median follow-up of 145 months, and local control in 1 of 2 WHO grade 3 residual tumors, with no grade 3 or higher toxicity in any case. Boskos et al<sup>82</sup> also found a trend for improved local control and survival with doses above 60Gy for gross residual atypical or anaplastic meningiomas. Regardless of local control, marginal and distant recurrences of high-grade meningiomas are common, and extracranial metastases are possible especially among patients with multiple recurrences, with a reported incidence of up to 8.9% among patients with WHO grade 3 meningiomas.<sup>83</sup> Thus, there is an urgent, unmet need for new treatment paradigms for this patient population.

### Stereotactic Radiosurgery

Numerous studies collectively encompassing well over 5000 patients have reported 5-year local control rates of 86–100% for WHO grade 1 or imaging-defined meningiomas treated with single-fraction stereotactic radiosurgery (SRS), typically using doses ranging from 12 to 18 Gy.<sup>84–87</sup> Meningioma radiosurgery doses of 10Gy or less, or 12Gy or less, were associated with inferior local control in two studies.<sup>88,89</sup> Recently, the multicenter IMPASSE study<sup>90</sup> observed 5-year tumor control of 99.4% after radiosurgery of small, imaging-defined meningiomas compared with 62.1% for matched tumors undergoing observation, demonstrating the efficacy of SRS in altering the clinical trajectory of benign meningiomas. Nevertheless, given the high proportion of imaging-defined meningiomas that do not demonstrate radiologic growth on long-term follow-up in the context of good outcomes with SRS treatment for meningiomas up to 2–3 cm in diameter, many incidentally diagnosed meningiomas can be safely followed with serial MRIs, with treatment reserved until there is documented evidence of progression.<sup>91</sup> Exceptions include incidentally diagnosed meningiomas at risk for causing neurological symptoms due to intimate association with critical neurological structures, which may benefit from early intervention before tumor progression causes symptoms.

Factors associated with improved outcomes and fewer complications after SRS treatment of meningiomas include imaging-defined tumors, smaller tumor volumes, and skull base locations away from the convexity or parasagittal regions. At least four studies have reported meningioma size >10cc to be associated with worse local control

**Table 1.** Reported Prospective Trials of Adjuvant Radiotherapy for WHO Grade 2 Meningiomas.

Trial	Type	Arms	Interventions	RT details	Outcomes
RTOG 0539	Phase II	Arm 1: "Low risk", primary grade 1 Arm 2: "Intermediate risk", 1° grade 2 tumor after GTR, 2° grade 1 tumor Arm 3: "High risk", grade 3 tumor or 2° grade 2, or any grade 2 after STR	Arm 1: Observation Arm 2: 54 Gy/30 fractions Arm 3: 60 Gy/30 fractions	Arm 2: 10 mm GTV-CTV expansion, reduced to 5 mm for uninvolved bone. Arm 3: 54 Gy to a 20 mm GTV-CTV expansion, and 60 Gy to a 10 mm GTV-CTV expansion. CTV-PTV 3–5 mm expansion for both arms. Dural tail and edema excluded from GTV. Hyperostosis and bone invasion included in GTV.	Arm 1: 5y PFS for GTR/STR 94.3%/72.7% Arm 2: 3y PFS 93.8% Arm 3: 3y PFS 58.8%
EORTC 22042-26042	Phase II	Arm 1: Grade 2 tumor after GTR Arm 2: Grade 3 or grade 2 tumor after STR	Arm 1: 60Gy/30 fractions Arm 2: 70 Gy/35 fractions	Arm 1: 10 mm GTV-CTV expansion. Arm 2: 60 Gy to 10 mm GTV-CTV expansion and 10 Gy boost to 5 mm GTV-CTV expansion GTV could include hyperostosis, dural thickening/enhancement, tumor bed, and edema. CTV-PTV 1–5 mm expansion for both arms.	Arm 1: 3y PFS 88.7% Arm 2: NR

**Abbreviations:** CTV, clinical target volume; GTR, gross total resection; GTV, gross tumor volume; Gy, Gray; NR, not reported; PFS, progression free survival; PTV, planning target volume; RT, radiotherapy; RCT, randomized controlled trial; STR, subtotal resection.

and a greater risk of toxicity after SRS,<sup>87,92–94</sup> particularly among non-skull base tumors. Several studies have also noted significantly higher rates of symptomatic worsening of peri-tumoral edema and other complications after SRS for parasagittal or falx meningiomas,<sup>85,94–96</sup> particularly among tumors compressing or invading the dural sinuses.<sup>97</sup> In line with these clinical observations, parasagittal or falx meningiomas may be associated with unique biologic characteristics compared to meningiomas arising from other locations, including a greater frequency of immune infiltration.<sup>98</sup> Moreover, convexity, parasagittal, and falx meningiomas appear to more frequently harbor molecular characteristics underlying aggressive clinical behavior.<sup>99,100</sup>

In general, meningiomas smaller than 2–3cm in diameter or 10cc in volume, with well-defined margins and an adequate distance from critical structures such as the optic nerve/chiasm or brainstem can be effectively treated with single-fraction SRS, with toxicity rates of approximately 10% or less even for low-grade complications. For WHO grade 1 meningiomas or imaging-defined meningiomas, the target typically contains little or no dural margin and excludes the dural tail, with no apparent detriment in local control. At 10 years, reported local control ranges from 83 to 92%. Regional recurrence is possible, with some series with long-term follow-up reporting rates of 15–20% at timepoints past 10 years.<sup>101</sup> For larger meningiomas or meningiomas in close proximity to critical structures, hypofractionated radiosurgery of 18–30 Gy in 3–5 fractions is safe and effective but is supported by less data than single-session SRS for smaller tumors.<sup>93,102,103</sup>

The role of SRS is less well studied in WHO grade 2 and 3 meningiomas, but as with EBRT, in-field, marginal, and distant intracranial progression is common after SRS treatment of high-grade meningiomas. Due both to the propensity of high-grade meningiomas to infiltrate the dura and other adjacent tissues, and the smaller margins used for

SRS, 5-year progression-free survival rates after SRS are low, ranging from 34% to 56%<sup>104–108</sup> with many recurrences elsewhere in the untreated areas of resection cavities.<sup>109</sup> Despite these limitations, SRS can be a versatile and useful treatment for meningiomas due to its exquisitely targeted and conformal delivery of high doses of ionizing radiation, for example in heavily pre-treated patients for whom large field irradiation may afford the unacceptably high risk of wound complications or radionecrosis. Interpretation of the available data supporting the efficacy of SRS as a treatment for atypical and anaplastic meningiomas is limited by the heterogeneity of clinical contexts, including postoperative treatment of residual tumor in the primary setting, salvage treatment of recurrent tumor after surgery and/or prior radiotherapy, or primary treatment without resection. There is limited data regarding SRS dose-response for WHO grade 2-3 meningiomas, and uncertainty among reports suggesting higher SRS doses as to whether higher SRS doses reflect a dose-response or are a proxy for larger effective margins. Further study of the radiobiology and underlying mechanisms of radiosensitivity or radioresistance in meningiomas is needed to guide this clinically versatile treatment.

## Future Directions

### Advances in Meningioma Biology

Recent discoveries have significantly advanced our understanding of the genomic features and biologic drivers of meningiomas. Exome sequencing of meningiomas reveals a plethora of rare but recurring SSVs targeting *TRAF7*, *AKT1*, *KLF4*, *SMO*, *SUFU*, *PIK3CA*, *POLR2A*, *SMARCB1*, *SMARCE1*, *BAP1*, *DMD*, *ARID1A*, the *TERT* promoter, or *CDKN2A/B*.<sup>110–116</sup> The mechanistic impact of most of these SSVs on meningioma tumorigenesis, treatment response,



or resistance remains unknown, and *NF2* mutation with or without chromosome 22q loss remains the most commonly identified alteration among meningiomas, with an estimated prevalence of 40–60%. Among recurrent SSVs, only *TRAF7/KLF4* and possibly *POLR2A* may be mutually exclusive of *NF2* alterations, suggesting potentially divergent paths of tumorigenesis. Early reports indicated that up to 40% of meningiomas may harbor recurrent non-*NF2* alterations, including up to a 25% prevalence of *TRAF7* SSVs. However, subsequent reports have demonstrated a more modest prevalence of 8.7–20% of meningiomas without an *NF2* alteration that encodes one or more recurrent non-*NF2* SSVs, leaving up to 25–50% of meningiomas without an identifiable genetic driver.<sup>113,117</sup> Among meningiomas without alterations of *NF2* or chromosome 22q, meningiomas from the Merlin-intact DNA methylation group or with SSVs targeting *TRAF7/KLF4*, *AKT1*, *SMO*, or *POLR2A* tend to have benign histology, midline skull base location, limited chromosomal instability, and lower rates of aggressive imaging or clinical features.<sup>98</sup> Conversely, meningiomas from Immune-enriched or Hypermitotic DNA methylation groups or with SSVs targeting *DMD*, *ARID1A*, *BAP1*, *SMARCE1*, the *TERT* promotor, or *CDKN2A/B* tend to have aggressive histologic, imaging, or clinical features.<sup>98,115,116,118,119</sup> None of the recurrent SSVs identified thus far have revealed biomarkers for meningioma radiotherapy response or resistance.

### Chromosome Instability

Meningiomas display a wide range of chromosomal instability, and meningioma chromosome copy number gains and losses are associated with high-grade histology and aggressive biology.<sup>98,113,117,120</sup> Numerous chromosomal regions of recurrent copy number variants (CNVs) have been identified. Among these, loss of chromosome 22q is the most frequent, followed by loss of 1p (9–36%) or loss of 14q (15–19%).<sup>117,120</sup> A variety of other chromosome gains or losses have been reported at lower frequencies of 5–15%, such as 1q gain, 3p loss, 6q loss, 9q loss, 17q gain, 18p and 18q loss, 20p gain, or 20q gain.

The co-occurrence of chromosome 22q loss, *NF2* SSVs, and chromosome 1p loss is a poor prognostic marker for meningioma outcomes.<sup>98,113,117</sup> This finding is enriched among atypical and anaplastic meningiomas, and correlates with more aggressive epigenetic and transcriptomic profiles, a greater mitotic rate, and a greater risk of rapid meningioma recurrence and death. The prognostic significance of 1p loss without 22q or *NF2* alteration is less clear, although some studies suggest independent prognostic value.<sup>113</sup> Chromosome 22q loss without 1p loss is associated with intermediate outcomes and may be moderately associated with Immune-enriched meningiomas.<sup>98,117</sup> Notably, multiple studies have reported enrichment of chromosome 22q loss, *NF2* SSVs, and chromosomal instability among meningiomas arising from the cerebral convexity, parasagittal, falx, lateral skull base, or spinal locations, which may be influenced by potential differences in the embryologic origin of the meningeothelial lining of these areas compared to the midline skull base.<sup>121</sup>

Numerous other CNVs have been suggested to be poor prognostic markers for meningioma outcomes, but the validation of independent prognostic features has been stymied by low frequency or co-occurrence with chromosome 22q or 1p alterations (e.g. 1p/14q deletion). Notably, chromosome 9p loss (*CDKN2A/B*), or gain of chromosomes 1q (*USF1*) or 17q may be enriched among anaplastic meningiomas,<sup>122</sup> and widespread polysomy of chromosomes 5, 6 (containing the *HLA* locus), 12, 17, 18, and 20, along with retained 22q and wild type *NF2* are characteristic of angiomatous meningiomas,<sup>123</sup> which are largely benign. Despite the abundance of meningioma CNVs, no CNV permutations have been identified to predict meningioma radiotherapy responses. Moreover, meningioma CNV profiles tend to correlate with epigenetic or transcriptomic grouping schemes but can be discordant in approximately one-third of cases.<sup>98</sup> Thus, it is possible biomarkers predicting meningioma radiotherapy responses may be derived from supervised DNA methylation or gene expression grouping schemes, but the available literature suggests CNVs alone do not encode predictive information.

### DNA Methylation and Gene Expression Profiling

DNA methylation profiling of meningiomas has revealed epigenetic variation with prognostic and biologic significance. Clustering of meningioma DNA methylation profiles identifies 2–6 groups or subgroups of tumors and can provide prognostic stratification equaling or exceeding the performance of histologic WHO grade for meningioma local control, depending on the size, composition, or available clinical data from various cohorts.<sup>98,117,124,125</sup> The incongruous number of meningioma DNA methylation groups reported by different studies may be the product of variable sample sizes or meningioma CNVs, which can confound DNA methylation profiling.<sup>98</sup> Using DNA methylation profiling of 565 meningiomas from independent discovery ( $N = 200$ ) or validation ( $N = 365$ ) cohorts, and controlling for the influence of CNVs on  $\beta$  methylation values, Choudhury et al<sup>98</sup> identified 3 meningioma DNA methylation groups and validated biological drivers across groups using orthogonal mechanistic and functional approaches. In this study, Merlin-intact meningiomas were comprised of largely benign tumors with excellent outcomes harboring at least one functional copy of *NF2* driving meningioma cell apoptosis and sensitivity to cytotoxic therapy, such as ionizing radiation. Immune-enriched meningiomas were comprised of tumors with intermediate outcomes that were distinguished by *NF2* inactivation without chromosome 1p loss and increased immune infiltration driven by *HLA* expression and lymphatic vessel enrichment in the meningioma microenvironment. Hypermitotic meningiomas were comprised of tumors with poor outcomes that were distinguished by concurrent loss of chromosomes 22q and 1p, and enrichment of convergent genetic and epigenetic mechanisms misactivating the cell cycle, such as the *FOXM1* gene expression program, *CDKN2A/B* deletion or hypermethylation, or amplification of the transcription factor *USF1* on chromosome 1q driving *CDK6* expression. By integrating DNA methylation profiling with CNVs, SSVs, and gene expression programs, Nassiri

**Table 2.** List of Genomic, Clinical, Histologic, and Radiologic Risk Factors for Meningioma Recurrence Beyond WHO Grade.

Genomic	Clinical	Histologic	Radiologic
Hypermitotic/Mal DNA methylation group Proliferative integrated molecular group Group C gene expression	Subtotal resection	Elevated Ki67 labeling index	ADC hypointensity
<i>BAP1</i> mutation (rhabdoid)	Recurrent tumor	Elevated mitotic rate	ADC and T2 heterogeneity
<i>TERT</i> promoter mutation	Prior radiation	Brain/bone invasion with other high grade features	Indistinct margins and loss of CSF cleft
<i>CDKN2A/B</i> deletion or hypermethylation	Male sex	Increased number of atypical morphologic features	Brain infiltration
<i>SMARCE1</i> mutation (clear cell)		Loss of PGR staining	Lobulated and non-spherical growth ("mushrooming")
<i>DMD</i> mutation		Elevated FOXM1 staining	Nodular dural margins
<i>ARID1A</i> mutation		Elevated p53 staining	Extensive peritumoral edema*
22q with 1p loss		Loss of H3K27 trimethylation	Multiple meningiomas, meningiomatosis
1p loss			
1q gain			
14q loss			
9p loss and 17q amplification			
22q/ <i>NF2</i> loss with chromosomal instability			
<i>FOXM1</i> overexpression			
Elevated gene expression risk score			

**Abbreviations:** ADC, apparent diffusion coefficient; CSF, cerebral spinal fluid; PGR, progesterone receptor; SSTR2A, somatostatin receptor 2A.

\*However, some benign histologies are associated with exuberant vasogenic edema, including angiomatous and secretory meningiomas.

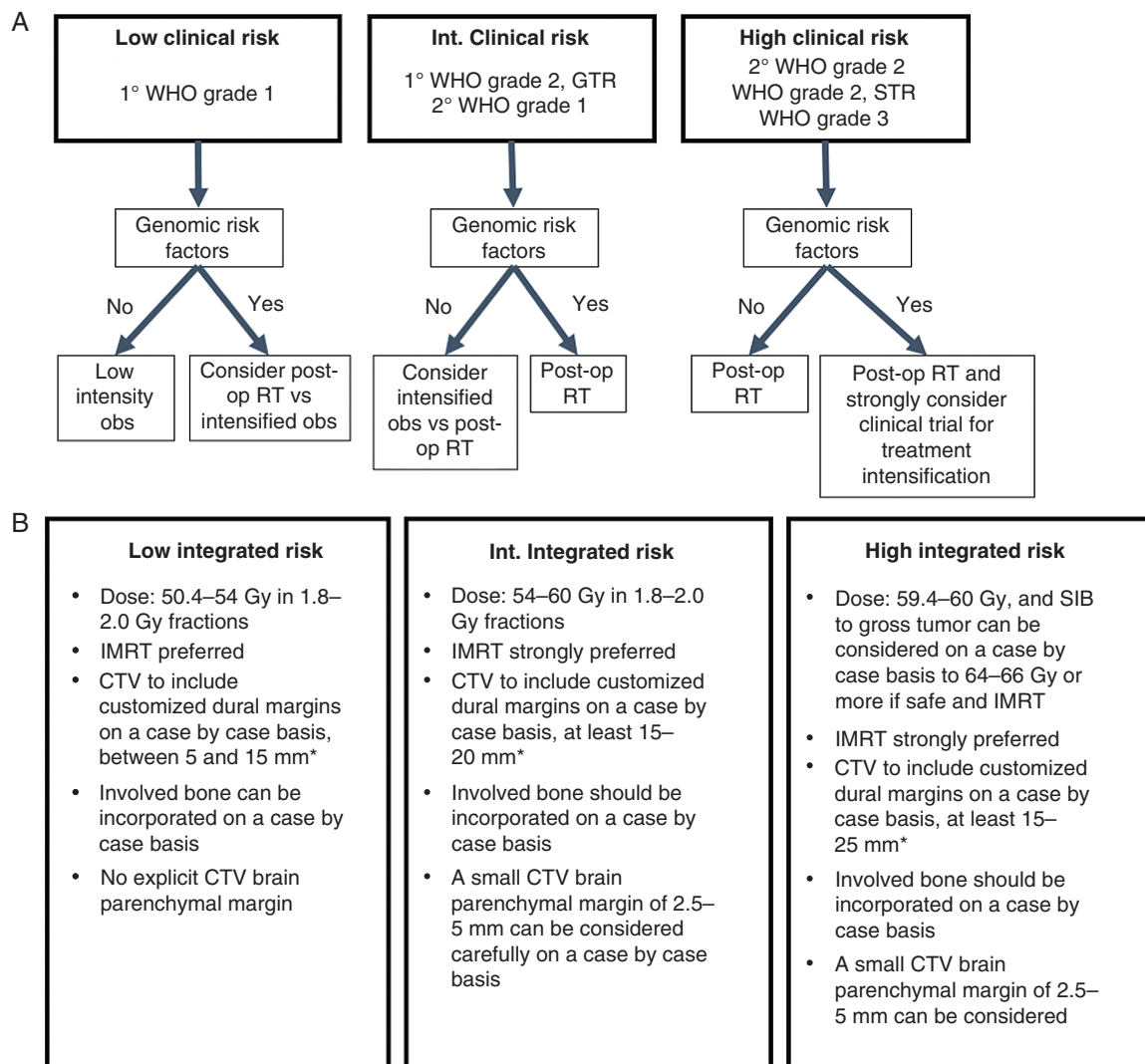
et al<sup>117</sup> described similar meningioma groups including benign, immunogenic, proliferative, and hypermetabolic meningiomas, suggesting the potential existence of DNA methylation subgroups within groups of meningiomas. Regardless of the molecular architecture of meningiomas, neither Choudhury et al, Nassiri et al, nor any other DNA methylation or integrated molecular grouping scheme has revealed a biomarker of meningioma radiotherapy response or resistance.

Transcriptomic profiling of meningiomas has elucidated pathways misactivated across aggressive tumors, including the *FOXM1* gene expression program,<sup>126</sup> the DREAM complex and E2F family of transcription factors,<sup>99</sup> and the PRC2 complex,<sup>99,114</sup> which is implicated in epigenetic regulation. Gene expression analyses have also identified prognostic groups or gene expression biomarkers,<sup>99,127,128</sup> but further work is needed to identify and validate predictive biomarkers able to robustly predict meningioma patients who will benefit from radiotherapy or radiosurgery.

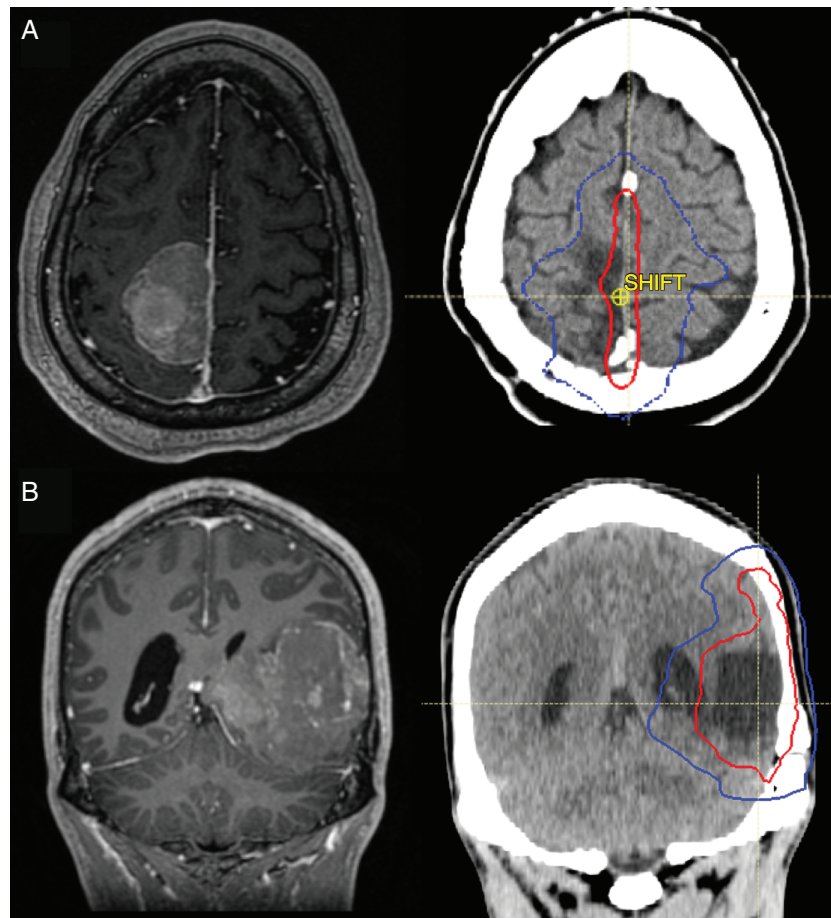
### Incorporation of Meningioma Biology into Clinical Risk Stratification

Much work remains to be done to translate meningioma SSV, CNV, DNA methylation profiling, or gene expression

discoveries to routine diagnosis or treatment. Broadly, it remains unclear how best to implement these discoveries in the clinic, whether by the identification of clinically tractable biomarkers based upon DNA methylation profiling or transcriptomics, or the use of surrogate immunohistochemical markers. Nevertheless, it is clear that by integrating both novel and established clinical, histologic, radiologic, and molecular features, meningioma risk stratification can be refined beyond WHO grade categories (Table 2), allowing for individualized risk assessment to guide the frequency of postoperative surveillance, radiotherapy or radiosurgery recommendations, or the selection of patients for clinical trials testing targeted or molecular therapies (Figure 3, Figure 4). Such tools would allow low-risk WHO grade 2 meningiomas with favorable clinical, histologic, radiologic, or molecular features to safely undergo postoperative imaging surveillance rather than immediate radiotherapy. In contrast, delineation of high-risk WHO grade 2 meningiomas with unfavorable clinical, histologic, radiologic, or molecular features would identify patients requiring closer postoperative imaging surveillance, or early postoperative radiotherapy, or radiosurgery. WHO grade 1 meningiomas with higher risk molecular features are also prone to recurrence, and may similarly benefit from consideration of intensified surveillance, or postoperative radiotherapy or radiosurgery. Irrespective of *in vivo* prognostic or predictive biomarkers,



**Figure 3.** Proposed risk stratification incorporating genomic risk factors. (A) A proposed broad stratification of meningiomas based upon clinical risk groups derived from RTOG 0539 with the incorporation of genomic risk factors (Table 2). In addition to clinical or genomic stratification, meningioma patients benefit from the multidisciplinary discussion for pre-operative planning and postoperative management. Individualized patient and tumor characteristics should be considered, including, but not limited to, tumor location, surgical accessibility, surgical risks, symptom burden, patient priorities, volume and location of the residual tumor if present, and suitability for radiotherapy. At present, a gold standard of genomic risk is unestablished, and incorporation of genomic risk factors should be considered on a case by case basis depending upon availability and local expertise. In this context, “low intensity observation” may vary based upon clinical characteristics, and intensification of observation refers to an increased frequency of surveillance imaging. The use of DOTATATE/DOTATOC imaging may also be helpful in special situations to identify residual disease or distinguish between postoperative changes and tumors. Due to the propensity for very late recurrences, patients should be prepared to continue long-term image surveillance regardless of risk stratification. Finally, although only postoperative radiotherapy is mentioned, the modality and technique of radiation delivery should be determined on a case-by-case basis, and in some cases surgical re-operation may also be reasonable or preferred. (B) A proposed stratification by integrated risk-based upon multidisciplinary discussion incorporating all available factors including clinical, genomic, histologic, and radiologic features. Using such an approach, radiotherapy doses and margins can be individualized. IMRT should be considered standard to limit the volume of the normal brain receiving high doses of ionizing radiation, although low or intermediate dose volumes should also be minimized. DOTATATE/DOTATOC imaging can help identify occult residual tumors for radiotherapy design. All areas of abnormal dura should be incorporated into the CTV. The level of evidence for this stratification is low, but the framework presented here may be used as a guide for risk-adapted, individualized meningioma treatment. Abbreviations: 1°, primary (first diagnosis); 2°, recurrent; CTV, clinical target volume; int., intermediate; GTR, gross total resection; post-op, postoperative; IMRT, intensity modulated radiotherapy; PTV, planning target volume; obs, observation; RT, radiotherapy; SIB, simultaneous integrated boost; WHO, World Health Organization. \*CTV margin should take into account the amount of dura removed during meningioma resection, respecting anatomic boundaries such as uninvolved bone or brain and individualized based on risk factors or anatomy. There is some evidence that meningioma cell invasion can be found up to 3 cm away from the tumor edge, and marginal recurrences up to 2–3 cm away from the resection cavity have been reported. Peritumoral edema should not be included in the CTV. PTV margins should be determined based on institution and machine-specific tolerances. Efforts should be paid to spare normal brain parenchyma from high dose radiotherapy in all circumstances.



**Figure 4.** Meningioma postoperative radiotherapy plans. (A) Top left is a gadolinium enhanced T1 MRI sequence showing a falcine meningioma associated with nodular dura, heterogeneous T1, and lobulated appearance. The patient underwent a gross-total resection, and pathology showed a WHO grade 2 meningioma with 11 mitoses per 10 high powered fields, elevated Ki67 labeling index of 7%, focal areas of spontaneous necrosis, small cell change, weak progesterone receptor staining in ~25% of cells, and retained H3K27me3. An institutional targeted exome sequencing panel showed no pathogenic SSVs, but chromosomes 22q (*NF2*), 1p, and 19q were lost. Given these high risk radiologic, histologic, and genomic features, the patient was treated with postoperative radiotherapy to 59.4 Gy in 33 fractions targeting the at-risk dura/falx only (top right, red line denotes 59.4 Gy isodose line, blue line denotes the 50% isodose line). No CTV margin into brain parenchyma was used. (B) Bottom left is a coronal view gadolinium enhanced T1 MRI sequence showing a large, lobulated, heterogeneously enhancing left temporal mass, abutting the convexity dura and tentorium without an obvious dural tail, associated with moderate peritumoral edema and markedly restricted diffusion with ADC hypointensity. The patient underwent gross total resection with pathology revealing a WHO grade 2 meningioma with 4 mitoses per 10 high powered fields, elevated Ki67 labeling index of 10%, focal hypercellularity, sheeting, small cell change, as well as focal brain invasion. Immunohistochemical staining revealed retained H3K27me3, and positive SSTR2A staining. An institutional exome sequencing panel showed chromosome 22q monosomy and a pathogenic *NF2* SSV, as well as losses of chromosomes 1p, 2p, distal 3p, 4q, 6q, 18 and gains of proximal 3p, 4p, and distal 21q. Given the high risk radiologic and genomic risk factors, the patient was treated with postoperative radiotherapy (59.4 Gy in 33 fractions) to the resection cavity and approximately 15–20 mm customized anisotropic margin of dura at risk, with a small 2.5 mm CTV margin applied into brain parenchyma surrounding the resection cavity due to the presence of brain invasion in the context of high risk genomic and histologic features (bottom right, red line denotes the 59.4Gy isodose line, blue line denotes the 50% isodose line).

there is an unmet need for preclinical research defining the radiobiology and radiosensitivity of meningiomas to guide the selection of patients most likely to benefit from adjuvant treatments, or future investigation of appropriate radiotherapy doses in the context of tumor biology.

### Molecular Imaging and Radiotherapy Planning

The majority of meningiomas of all grades express somatostatin receptor 2A (SSTR2A),<sup>129</sup> allowing for

molecular imaging using various octreotide peptide analog radioligands, most commonly Ga68-DOTATATE positron emitting tomography (PET). DOTATATE imaging has a higher sensitivity compared to standard MRI in identifying meningioma involvement of the dura, dural sinus, or bone, and may be useful both in pre-operative planning and postoperative evaluation of the extent of resection, or in guiding postoperative radiotherapy.<sup>130–133</sup> Remarkably, a study by Bashir et al<sup>134</sup> identified DOTATATE uptake after otherwise gross total resection of 23 of 37 meningiomas (62%). Of these 23 tumors, nine (39%) either

recurred or were proven to have residual meningioma on re-operation. This imaging study and others like it suggest occult residual meningioma at a rate concordant with histologic studies demonstrating dural invasion up to 2–3 cm beyond the tumor edge for 50–75% of meningiomas, and bone infiltration in areas of hyperostosis. A combination of DOTATATE imaging and targeted marginal dural sampling could improve pre-surgical planning or extent of resection, as well as identify otherwise occult residual meningioma postoperatively that could be critical for postoperative radiotherapy planning. Indeed, DOTATATE has also been investigated as a means of guiding target delineation for radiotherapy,<sup>135</sup> and some investigators have demonstrated the feasibility of reducing target size by using customized margins based upon postoperative DOTATATE PET imaging,<sup>132,136</sup> although care should be taken to not omit microscopic residual disease below the detection limit, which is not yet well defined. The underlying biology of macroscopic or microscopic residual meningioma, which may be more common than previously estimated, could influence the likelihood or timeframe of recurrence, underscoring the importance of incorporating genomic or molecular risk stratification into routine meningioma care. To that end, Dutch investigators have proposed a refined grading system for determining “total resection” termed the Copenhagen grade,<sup>137</sup> which incorporates a targeted sampling of dural margins and postoperative DOTATOC PET at 3 months. Based upon the presence or absence of residual meningioma using one or both approaches, the authors proposed tailoring the frequency of surveillance imaging versus consideration of postoperative radiotherapy for otherwise low-risk, WHO grade 1 meningiomas. The addition of genomic profiling may further add to this risk stratification.

## Conclusions

In summary, radiotherapy and radiosurgery are integral components of comprehensive, individualized meningioma care. Radiotherapy is effective in improving local control and symptoms in both the definitive and postoperative setting and can be a useful tool to address areas that are difficult to access intraoperatively. Recent advances in the understanding of meningioma biology or imaging may improve clinical risk stratification of patients, or may refine patient selection for postoperative radiotherapy, radiosurgery, clinical trials, or imaging surveillance.

## Funding

This work is supported by National Institutes of Health grant F32 CA213944 to S.T.M., the UCSF Wolfe Meningioma Program Project and the Northwestern University Malnati Brain Tumor Institute. D.R.R. is supported by National Institutes of Health grant R01 CA262311 and the UCSF Wolfe Meningioma Program Project.

**Conflict of interest statement.** The authors declare they have no competing interests related to this study.

**Supplement sponsorship.** This supplement was sponsored by a generous donation from Mr. Paul Mielnik and his family to help raise awareness and advance the care of patients with meningiomas worldwide.

## References

- Cushing H, Eisenhardt L. *Meningiomas. Their Classification, Regional Behaviour, Life History, and Surgical End Results*. Hafner, 42, 1938. doi:10.1016/s0002-9610(38)91219-x
- King DL, Chang CH, Pool JL. Radiotherapy in the management of meningiomas. *Acta radiol*. 1966;5(1):26–33. doi:10.3109/02841856609139540
- Simpson D. The recurrence of intracranial meningiomas after surgical treatment. *J Neurol Neurosurg Psychiatr*. 1957;20(1):22–39. doi:10.1136/jnnp.20.1.22
- Wara WM, Shelton GE, Newman H, Townsend JJ, Boldrey EB. Radiation therapy of meningiomas. *Amer J Roentgenol*. 1975;123(3):453–458. doi:10.2214/ajr.123.3.453
- Goldsmith BJ, Wara WM, Wilson CB, Larson DA. Postoperative irradiation for subtotally resected meningiomas. A retrospective analysis of 140 patients treated from 1967 to 1990. *J Neurosurg*. 1994;80(2):195–201. doi:10.3171/jns.1994.80.2.0195
- Carella RJ, Ransohoff J, Newall J. Role of radiation therapy in the management of meningioma. *Neurosurgery*. 1982;10(3):332–339. doi:10.1227/00006123-198203000-00006
- Solan MJ, Kramer S. The role of radiation therapy in the management of intracranial meningiomas. *Int J Radiat Oncol Biol Phys*. 1985;11(4):675–677. doi:10.1016/0360-3016(85)90297-4
- Petty AM, Kun LE, Meyer GA. Radiation therapy for incompletely resected meningiomas. *J Neurosurg*. 1985;62(4):502–507. doi:10.3171/jns.1985.62.4.0502
- Smith JL, Vuksanovic MM, Yates BM, Bienfang DC. Radiation therapy for primary optic nerve meningiomas. *J Clin Neuroophthalmol*. 1981;1(2):85–100.
- Gousias K, Schramm J, Simon M. The Simpson grading revisited: Aggressive surgery and its place in modern meningioma management. *J Neurosurg*. 2016;125(3):551–560. doi:10.3171/2015.9.JNS15754
- Przybylowski CJ, Hendricks BK, Frisoli FA, et al. Prognostic value of the Simpson grading scale in modern meningioma surgery: barrow Neurological Institute experience. *J Neurosurg*. 2021;135(2):515–523. doi:10.3171/2020.6.JNS20374
- Schwartz TH, McDermott MW. The Simpson grade: abandon the scale but preserve the Message. *J Neurosurg*. 2021;135(2):488–495. doi:10.3171/2020.6.JNS201904
- Sughrue ME, Kane AJ, Shangari G, et al. The relevance of Simpson grade I and II resection in modern neurosurgical treatment of World Health Organization grade I meningiomas. *J Neurosurg*. 2010;113(5):1029–1035. doi:10.3171/2010.3.JNS091971
- Hutzelmann A, Palmié S, Buhl R, Freund M, Heller M. Dural invasion of meningiomas adjacent to the tumor margin on Gd-DTPA-enhanced MR images: histopathologic correlation. *Eur Radiol*. 1998;8(5):746–748. doi:10.1007/s003300050466

15. Nagashima G, Fujimoto T, Suzuki R, et al. Dural invasion of meningioma: a histological and immunohistochemical study. *Brain Tumor Pathol.* 2006;23(1):13–17. doi:10.1007/s10014-006-0193-x
16. Qi ST, Liu Y, Pan J, Chotai S, Fang LX. A radiopathological classification of dural tail sign of meningiomas. *J Neurosurg.* 2012;117(4):645–653. doi:10.3171/2012.6.JNS111987
17. Guermazi A, Lafitte F, Miaux Y, et al. The dural tail sign - Beyond meningioma. *Clin Radiol.* 2005;60(2):171–188. doi:10.1016/j.crad.2004.01.019
18. Rokni-Yazdi H, Azmoudeh Ardalan F, Asadzandi Z, et al. Pathologic significance of the “dural tail sign.”. *Eur J Radiol.* 2009;70(1):10–16. doi:10.1016/j.ejrad.2008.01.010
19. Wen M, Jung S, Moon KS, et al. Immunohistochemical profile of the dural tail in intracranial meningiomas. *Acta Neurochir (Wien).* 2014;156(12):2263–2273. doi:10.1007/s00701-014-2216-4
20. Murase M, Tamura R, Kuranari Y, et al. Novel histopathological classification of meningiomas based on dural invasion. *J Clin Pathol.* 2021;74(4):238–243. doi:10.1136/jclinpath-2020-206592
21. Nakasu S, Nakasu Y, Nakajima M, Matsuda M, Handa J. Preoperative identification of meningiomas that are highly likely to recur. *J Neurosurg.* 1999;90(3):455–462. doi:10.3171/jns.1999.90.3.0455
22. Yamamuro K, Seichi A, Kimura A, et al. Histological investigation of resected dura mater attached to spinal meningioma. *Spine (Phila Pa 1976)* 2012;37(22). doi:10.1097/BRS.0b013e318268c419
23. Borovich B, Doron Y. Recurrence of intracranial meningiomas: the role played by regional multicentricity. *J Neurosurg.* 1986;64(1):58–63. doi:10.3171/jns.1986.64.1.0058
24. Rokni-Yazdi H, Sotoudeh H. Prevalence of “dural tail sign” in patients with different intracranial pathologies. *Eur J Radiol.* 2006;60(1):42–45. doi:10.1016/j.ejrad.2006.04.003
25. Mathiesen T, Pettersson-Segerlind J, Kihlström L, Ulfarsson E. Meningiomas engaging major venous sinuses. *World Neurosurg.* 2014;81(1):116–124. doi:10.1016/j.wneu.2013.01.095
26. Eichberg DG, Casabella AM, Menaker SA, Shah AH, Komotar RJ. Parasagittal and parafalcine meningiomas: integral strategy for optimizing safety and retrospective review of a single surgeon series. *Br J Neurosurg.* 2020;34(5):559–564. doi:10.1080/02688697.2019.1635988
27. Raza SM, Gallia GL, Brem H, et al. Perioperative and long-term outcomes from the management of parasagittal meningiomas invading the superior sagittal sinus. *Neurosurgery.* 2010;67(4):885–893. doi:10.1227/NEU.0b013e3181ef2a18
28. Sindou MP, Alvernia JE. Results of attempted radical tumor removal and venous repair in 100 consecutive meningiomas involving the major dural sinuses. *J Neurosurg.* 2006;105(4):514–525. doi:10.3171/jns.2006.105.4.514
29. Susko MS, Chen WC, Vasudevan HN, et al. Letter: patterns of intermediate-and high-risk meningioma recurrence after treatment with postoperative external beam radiotherapy. *Neurosurgery.* 2021;89(1):E99–E101. doi:10.1093/neuros/nyab143
30. Lau BL, Che Othman MI, Fathil MFMD, et al. Does Putting Back Hyperostotic Bone Flap in Meningioma Surgery Cause Tumor Recurrence? An Observational Prospective Study. *World Neurosurg* 2019;127:e497–e502. doi:10.1016/j.wneu.2019.03.183
31. Fathalla H, Tawab MGA, El-Fiki A. Extent of hyperostotic bone resection in convexity meningioma to achieve pathologically free margins. *J Korean Neurosurg Soc.* 2020;63(6):821–826. doi:10.3340/jkns.2020.0020
32. Terstegge K, Schorner W, Henkes H, et al. Hyperostosis in meningiomas: MR findings in patients with recurrent meningioma of the sphenoid wings. *Am J Neuroradiol.* 1994;15(3):555–560.
33. Goyal N, Kakkur A, Sarkar C, Agrawal D. Does bony hyperostosis in intracranial meningioma signify tumor invasion A radio-pathologic study. *Neurol India.* 2012;60(1):50–54. doi:10.4103/0028-3886.93589
34. Jääskeläinen J. Seemingly complete removal of histologically benign intracranial meningioma: late recurrence rate and factors predicting recurrence in 657 patients. A multivariate analysis. *Surg Neurol.* 1986;26(5):461–469. doi:10.1016/0090-3019(86)90259-4
35. Chen WC, Magill ST, Wu A, et al. Histopathological features predictive of local control of atypical meningioma after surgery and adjuvant radiotherapy. *J Neurosurg.* 2019;130(2):443–450. doi:10.3171/2017.9.JNS171609
36. Zhao P, Hu M, Zhao M, Ren X, Jiang Z. Prognostic factors for patients with atypical or malignant meningiomas treated at a single center. *Neurosurg Rev.* 2015;38(1):101–107. doi:10.1007/s10143-014-0558-2
37. Gabeau-Lacet D, Aghi M, Betensky RA, et al. Bone involvement predicts poor outcome in atypical meningioma: Clinical article. *J Neurosurg.* 2009;111(3):464–471. doi:10.3171/2009.2.JNS08877
38. Jin L, Youngblood MW, Gupte TP, et al. Type of bony involvement predicts genomic subgroup in sphenoid wing meningiomas. *J Neurooncol.* 2021;154(2):237–246. doi:10.1007/s11060-021-03819-2
39. Brokinkel B, Hess K, Mawrin C. Brain invasion in meningiomas-clinical considerations and impact of neuropathological evaluation: a systematic review. *Neuro Oncol.* 2017;19(10):1298–1307. doi:10.1093/neuonc/nox071
40. Perry A, Stafford SL, Scheithauer BW, Suman VJ, Lohse CM. Meningioma grading: An analysis of histologic parameters. *Am J Surg Pathol.* 1997;21(12):1455–1465. doi:10.1097/0000478-199712000-00008
41. Timme M, Thomas C, Spille DC, et al. Brain invasion in meningiomas: does surgical sampling impact specimen characteristics and histology? *Neurosurg Rev.* 2020;43(2):793–800. doi:10.1007/s10143-019-01125-0
42. Pižem J, Velnar T, Prestor B, Mlakar J, Popović M. Brain invasion assessability in meningiomas is related to meningioma size and grade, and can be improved by extensive sampling of the surgically removed meningioma specimen. *Clin Neuropathol.* 2014;33(5):354–363. doi:10.5414/NP300750
43. Nakasu S, Fukami T, Jito J, Matsuda M. Microscopic anatomy of the brain-meningioma interface. *Brain Tumor Pathol.* 2005;22(2):53–57. doi:10.1007/s10014-005-0187-0
44. Nakasu S, Nakasu Y. Prognostic significance of brain invasion in meningiomas: systematic review and meta-analysis. *Brain Tumor Pathol.* 2021;38(2):81–95. doi:10.1007/s10014-020-00390-y
45. Endo T, Narisawa A, Ali HSM, et al. A study of prognostic factors in 45 cases of atypical meningioma. *Acta Neurochir (Wien).* 2016;158(9):1661–1667. doi:10.1007/s00701-016-2900-7
46. Detti B, Scoccianti S, Di Cataldo V, et al. Atypical and malignant meningioma: Outcome and prognostic factors in 68 irradiated patients. *J Neurooncol.* 2013;115(3):421–427. doi:10.1007/s11060-013-1239-7
47. Baumgarten P, Gessler F, Schittenhelm J, et al. Brain invasion in otherwise benign meningiomas does not predict tumor recurrence. *Acta Neuropathol.* 2016;132(3):479–481. doi:10.1007/s00401-016-1598-1
48. Morin O, Chen WC, Nassiri F, et al. Integrated models incorporating radiologic and radiomic features predict meningioma grade, local failure, and overall survival. *Neuro-Oncology Adv.* 2019;1(1). doi:10.1093/oaajnl/vdz011
49. Schuring-Pereira M, Hagenbeek R, Mast M, et al. Atypical meningioma: patterns of postradiotherapy recurrences. *Br J Neurosurg.* 2021;35(5):591–596. doi:10.1080/02688697.2021.1922606
50. Harrison G, Kano H, Lunsford LD, Flickinger JC, Kondziolka D. Quantitative tumor volumetric responses after Gamma Knife radiosurgery for meningiomas. *J Neurosurg.* 2016;124(1):146–154. doi:10.3171/2014.12.JNS141341
51. Maclean J, Fersht N, Short S. Controversies in Radiotherapy for Meningioma. *Clin Oncol.* 2014;26(1):51–64. doi:10.1016/j.clon.2013.10.001
52. Rogers L, Barani I, Chamberlain M, et al. Meningiomas: knowledge base, treatment outcomes, and uncertainties. A RANO review. *J Neurosurg.* 2015;122(1):4–23. doi:10.3171/2014.7.JNS131644

53. Rogers L, Pugh S, Vogelbaum M, et al. Ctni-57. low-risk meningioma: outcomes from Nrg Oncology/RTog 0539. *Neuro Oncol*. 2020;22(Supplement\_2):ii55–ii56. doi:10.1093/neuonc/noaa215.223
54. Hall JT, Opalak CF, Carr MT, Harris TJ, Broadus WC. The effect of radiation on meningioma volume change. In. *World Neurosurgery*. 2021;153:e141–e146. doi:10.1016/j.wneu.2021.06.080
55. Fega KR, Fletcher GP, Waddle MR, et al. Analysis of MRI volumetric changes after hypofractionated stereotactic radiation therapy for benign intracranial neoplasms. *Adv Radiat Oncol*. 2019;4(1):43–49. doi:10.1016/j.adro.2018.08.013
56. Debus J, Wuendrich M, Pirzkall A, et al. High efficacy of fractionated stereotactic radiotherapy of large base-of-skull meningiomas: long-term results. *J Clin Oncol*. 2001;19(15):3547–3553. doi:10.1200/JCO.2001.19.15.3547
57. Combs SE, Adeberg S, Dittmar JO, et al. Skull base meningiomas: Long-term results and patient self-reported outcome in 507 patients treated with fractionated stereotactic radiotherapy (FSRT) or intensity modulated radiotherapy (IMRT). *Radiother Oncol*. 2013;106(2):186–191. doi:10.1016/j.radonc.2012.07.008
58. Milker-Zabel S, Zabel A, Schulz-Ertner D, et al. Fractionated stereotactic radiotherapy in patients with benign or atypical intracranial meningioma: long-term experience and prognostic factors. *Int J Radiat Oncol Biol Phys*. 2005;61(3):809–816. doi:10.1016/j.ijrobp.2004.07.669
59. de Melo LP, Arruda Viani G, de Paula JS. Radiotherapy for the treatment of optic nerve sheath meningioma: a systematic review and meta-analysis. *Radiother Oncol*. 2021;165:135–141. doi:10.1016/j.radonc.2021.10.009
60. Leroy HA, Tuleasca C, Reyns N, Levivier M. Radiosurgery and fractionated radiotherapy for cavernous sinus meningioma: a systematic review and meta-analysis. *Acta Neurochir (Wien)*. 2018;160(12):2367–2378. doi:10.1007/s00701-018-3711-9
61. Rogers L, Zhang P, Vogelbaum MA, et al. Intermediate-risk meningioma: initial outcomes from NRG Oncology RTOG 0539. *J Neurosurg*. 2018;129(1):35–47. doi:10.3171/2016.11.JNS161170
62. Weber DC, Ares C, Villa S, et al. Adjuvant postoperative high-dose radiotherapy for atypical and malignant meningioma: a phase-II parallel non-randomized and observation study (EORTC 22042-26042). *Radiother Oncol*. 2018;128(2):260–265. doi:10.1016/j.radonc.2018.06.018
63. He L, Zhang B, Zhang J, Guo Z, Shi F, Zeng Q. Effectiveness of postoperative adjuvant radiotherapy in atypical meningioma patients after gross total resection: a meta-analysis study. *Front Oncol*. 2021;10. doi:10.3389/fonc.2020.556575
64. Chun SW, Kim KM, Kim MS, et al. Adjuvant radiotherapy versus observation following gross total resection for atypical meningioma: a systematic review and meta-analysis. *Radiat Oncol*. 2021;16(1). doi:10.1186/s13014-021-01759-9
65. Simon M, Boström J, Koch P, Schramm J. Interinstitutional variance of postoperative radiotherapy and follow up for meningiomas in Germany: impact of changes of the WHO classification. *J Neural Neurosurg Psychiatry*. 2006;77(6):767–773. doi:10.1136/jnnp.2005.077974
66. Chohan MO, Ryan CT, Singh R, et al. Predictors of treatment response and survival outcomes in meningioma recurrence with atypical or anaplastic histology. *Neurosurgery*. 2018;82(6):824–832. doi:10.1093/neuros/nyx312
67. Talacchi A, Muggioli F, De Carlo A, et al. Recurrent atypical meningiomas: combining surgery and radiosurgery in one effective multimodal treatment. *World Neurosurg*. 2016;87:565–572. doi:10.1016/j.wneu.2015.10.013
68. Pettersson-Segerlind J, Orrego A, Lönn S, Mathiesen T. Long-term 25-year follow-up of surgically treated parasagittal meningiomas. *World Neurosurg*. 2011;76(6):564–571. doi:10.1016/j.wneu.2011.05.015
69. Kessel KA, Fischer H, Oechner M, et al. High-precision radiotherapy for meningiomas. *Strahlentherapie und Onkol*. 2017;193(11):921–930. doi:10.1007/s00066-017-1156-3
70. de Almeida AN, Pereira BJA, Pires Aguiar PH, et al. Clinical outcome, tumor recurrence, and causes of death: a long-term follow-up of surgically treated meningiomas. *World Neurosurg*. 2017;102:139–143. doi:10.1016/j.wneu.2017.03.009
71. Bagshaw HP, Burt LM, Jensen RL, et al. Adjuvant radiotherapy for atypical meningiomas. *J Neurosurg*. 2017;126(6):1822–1828. doi:10.3171/2016.5.JNS152809
72. Chen WC, Hara J, Magill ST, et al. Salvage therapy outcomes for atypical meningioma. *J Neurooncol*. 2018;138(2):425–433. doi:10.1007/s11060-018-2813-9
73. Chew J, Chen W, Susko MS, et al. Ncog-48. Transformation from low grade meningioma and prognostic factors for shorter time to recurrence of who grade III meningioma diagnosis. *Neuro Oncol*. 2020;22(Supplement\_2):ii140–ii140. doi:10.1093/neuonc/noaa215.586
74. Nabors LB, Portnow J, Ahluwalia M, et al. Central nervous system cancers, version 3.2020. *JNCCN J Natl Compr Cancer Netw*. 2020;18(11):1537–1570. doi:10.6004/JNCCN.2020.0052
75. Goldbrunner R, Stavrinou P, Jenkinson MD, et al. EANO guideline on the diagnosis and management of meningiomas. *Neuro Oncol*. 2021;23(11):1821–1834. doi:10.1093/neuonc/noab150
76. Rogers CL, Won M, Vogelbaum MA, et al. High-risk meningioma: initial outcomes from NRG Oncology/RTOG 0539. *Int J Radiat Oncol Biol Phys*. 2020;106(4):790–799. doi:10.1016/j.ijrobp.2019.11.028
77. Kaur G, Sayegh ET, Larson A, et al. Adjuvant radiotherapy for atypical and malignant meningiomas: a systematic review. *Neuro Oncol*. 2014;16(5):628–636. doi:10.1093/neuonc/nou025
78. Lee JJB, Lee J, Yoon HI, et al. Analysis of patterns of failure and appraisal of postoperative radiation field for grade II–III meningioma. *J Neurooncol*. 2019;144(2):333–341. doi:10.1007/s11060-019-03232-w
79. Askoxylakis V, Zabel-Du Bois A, Schlegel W, et al. Patterns of failure after stereotactic radiotherapy of intracranial meningioma. *J Neurooncol*. 2010;98(3):367–372. doi:10.1007/s11060-009-0084-1
80. Press RH, Prabhu RS, Appin CL, et al. Patterns of failure for grade 2/3 meningioma treated with reduced margin intensity modulated radiation therapy. *Int J Radiat Oncol*. 2013;87(2):S158. doi:10.1016/j.ijrobp.2013.06.408
81. Chan AW, Bernstein KD, Adams JA, Parambi RJ, Loeffler JS. Dose Escalation with proton radiation therapy for high-grade meningiomas. *Technol Cancer Res Treat*. 2012;11(6):607–614. doi:10.7785/tcrt.2012.500267
82. Boskos C, Feuvret L, Noel G, et al. Combined proton and photon conformal radiotherapy for intracranial atypical and malignant meningioma. *Int J Radiat Oncol Biol Phys*. 2009;75(2):399–406. doi:10.1016/j.ijrobp.2008.10.053
83. Dalle CL, Magill ST, Yen AJ, et al. Meningioma metastases: incidence and proposed screening paradigm. *J Neurosurg*. 2020;132(5):1447–1455. doi:10.3171/2019.1.JNS181771
84. Santacrose A, Walier M, Régis J, et al. Long-term tumor control of benign intracranial meningiomas after radiosurgery in a series of 4565 patients. *Neurosurgery*. 2012;70(1):32–39. doi:10.1227/NEU.0b013e31822d408a
85. Pollock BE, Stafford SL, Link MJ, et al. Single-fraction radiosurgery of benign intracranial meningiomas. *Neurosurgery*. 2012;71(3):604–612. doi:10.1227/NEU.0b013e31825ea557
86. Pollock BE, Stafford SL, Utter A, Giannini C, Schreiner SA. Stereotactic radiosurgery provides equivalent tumor control to Simpson Grade 1 resection for patients with small- to medium-size meningiomas. *Int J Radiat Oncol Biol Phys*. 2003;55(4):1000–1005. doi:10.1016/S0360-3016(02)04356-0
87. Kaprelian T, Raleigh DR, Sneed PK, et al. Parameters influencing local control of meningiomas treated with radiosurgery. *J Neurooncol*. 2016;128(2):357–364. doi:10.1007/s11060-016-2121-1
88. Ganz JC, Backlund EO, Thorsen FA. The results of gamma knife surgery of meningiomas, related to size of tumor and dose. *Stereotact Funct Neurosurg*. 1993;61(Suppl 1):23–29. doi:10.1159/000100656

89. Kuhn EN, Taksler GB, Dayton O, et al. Patterns of recurrence after stereotactic radiosurgery for treatment of meningiomas. *Neurosurg Focus*. 2013;35(6). doi:10.3171/2013.8.FOCUS13283
90. Sheehan J, Pikkis S, Islim AI, et al. An international multicenter matched cohort analysis of incidental meningioma progression during active surveillance or after stereotactic radiosurgery: the IMPASSE study. *Neuro Oncol*. 2022;24(1):116–124. doi:10.1093/neuonc/noab132
91. Islim AI, Mohan M, Moon RDC, et al. Treatment outcomes of incidental intracranial meningiomas: results from the IMPACT Cohort. *World Neurosurg*. 2020;138:e725–e735. doi:10.1016/j.wneu.2020.03.060
92. DiBiase SJ, Kwok Y, Yovino S, et al. Factors predicting local tumor control after gamma knife stereotactic radiosurgery for benign intracranial meningiomas. *Int J Radiat Oncol Biol Phys*. 2004;60(5):1515–1519. doi:10.1016/j.ijrobp.2004.05.073
93. Park HR, Lee JM, Park KW, et al. Fractionated gamma knife radiosurgery as initial treatment for large skull base meningioma. *Exp Neurol*. 2018;27(3):245–255. doi:10.5607/en.2018.27.3.245
94. Sheehan JP, Lee CC, Xu Z, et al. Edema following Gamma Knife radiosurgery for parasagittal and parafalcine meningiomas. *J Neurosurg*. 2015;123(5):1287–1293. doi:10.3171/2014.12.JNS142159
95. Bledsoe JM, Link MJ, Stafford SL, Park PJ, Pollock BE. Radiosurgery for large-volume (> 10 cm<sup>3</sup>) benign meningiomas. *J Neurosurg*. 2010;112(5):951–956. doi:10.3171/2009.8.JNS09703
96. Milano MT, Sharma M, Soltys SG, et al. Radiation-induced edema after single-fraction or multifraction stereotactic radiosurgery for meningioma: a critical review. *Int J Radiat Oncol Biol Phys*. 2018;101(2):344–357. doi:10.1016/j.ijrobp.2018.03.026
97. Sheehan JP, Cohen-Inbar O, Ruangkanhasetr R, et al. Post-radiosurgical edema associated with parasagittal and parafalcine meningiomas: a multicenter study. *J Neurooncol*. 2015;125(2):317–324. doi:10.1007/s11060-015-1911-1
98. Choudhury A, Magill ST, Eaton CD, et al. Meningioma epigenetic grouping reveals biologic drivers and therapeutic vulnerabilities. *Nat Genet*. 2022;54(5):649–659. doi:10.1038/s41588-022-01061-8
99. Patel AJ, Wan YW, Al-Ouran R, et al. Molecular profiling predicts meningioma recurrence and reveals loss of DREAM complex repression in aggressive tumors. *Proc Natl Acad Sci USA*. 2019;116(43):21715–21726. doi:10.1073/pnas.1912858116
100. Youngblood MW, Duran D, Montejo JD, et al. Correlations between genomic subgroup and clinical features in a cohort of more than 3000 meningiomas. *J Neurosurg*. 2020;133(5):1345–1354. doi:10.3171/2019.8.JNS191266
101. Kondziolka D, Patel AD, Kano H, Flickinger JC, Lunsford LD. Long-term outcomes after gamma knife radiosurgery for meningiomas. *Am J Clin Oncol Cancer Clin Trials*. 2016;39(5):453–457. doi:10.1097/COC.000000000000080
102. Tuniz F, Soltys SG, Choi CY, et al. Multisession cyberknife stereotactic radiosurgery of large, benign cranial base tumors: preliminary study. *Neurosurgery*. 2009;65(5):898–907. doi:10.1227/01.NEU.0000359316.34041.A8
103. Bria C, Wegner RE, Clump DA, et al. Fractionated stereotactic radiosurgery for the treatment of meningiomas. *J Cancer Res Ther*. 2011;7(1):52–57. doi:10.4103/0973-1482.80462
104. Zhang M, Ho AL, D'Astous M, et al. CyberKnife stereotactic radiosurgery for atypical and malignant meningiomas. *World Neurosurg*. 2016;91:574–581.e1. doi:10.1016/j.wneu.2016.04.019
105. Williams BJ, Salvetti DJ, Starke RM, Yen CP, Sheehan JP. Stereotactic radiosurgery for WHO II and III meningiomas: analysis of long-term clinical and radiographic outcomes. *J radiosurgery SBRT*. 2013;2(3):183–191.
106. Sun SQ, Cai C, Murphy RKJ, et al. Radiation therapy for residual or recurrent atypical meningioma: The effects of modality, timing, and tumor pathology on long-term outcomes. *Neurosurgery*. 2016;79(1):23–32. doi:10.1227/NEU.0000000000001160
107. Pollock BE, Stafford SL, Link MJ, Garces YI, Foote RL. Stereotactic radiosurgery of World Health Organization grade II and III intracranial meningiomas: treatment results on the basis of a 22-year experience. *Cancer*. 2012;118(4):1048–1054. doi:10.1002/cncr.26362
108. Dang AT, Wang C, Kaprelian TB. Adjuvant and salvage radiation therapy for atypical meningioma: a retrospective review of a single institution experience at the University of California at Los Angeles from 1999–2015. *Int J Radiat Oncol*. 2017;99(2):E68–E69. doi:10.1016/j.ijrobp.2017.06.755
109. Choi CYH, Soltys SG, Gibbs IC, et al. Cyberknife stereotactic radiosurgery for treatment of atypical (Who Grade II) cranial meningiomas. *Neurosurgery*. 2010;67(5):1180–1188. doi:10.1227/NEU.0b013e3181f2f427
110. Boström J, Meyer-Puttitz B, Wolter M, et al. Alterations of the tumor suppressor genes CDKN2A (p16INK4a), p14ARF, CDKN2B (p15INK4b), and CDKN2C (p18INK4c) in atypical and anaplastic meningiomas. *Am J Pathol*. 2001;159(2):661–669. doi:10.1016/S0002-9440(10)61737-3
111. Clark VE, Erson-Omay EZ, Serin A, et al. Genomic analysis of non-NF2 meningiomas reveals mutations in TRAF7, KLF4, AKT1, and SMO. *Science (80-)* 2013;339(6123):1077–1080. doi:10.1126/science.1233009
112. Clark VE, Harmancl AS, Bai H, et al. Recurrent somatic mutations in POLR2A define a distinct subset of meningiomas. *Nat Genet*. 2016;48(10):1253–1259. doi:10.1038/ng.3651
113. Driver J, Hoffman SE, Tavakol S, et al. A molecularly integrated grade for meningioma. *Neuro Oncol*. 2022;24(5):796–808. doi:10.1093/neuonc/noab213
114. Harmancl AS, Youngblood MW, Clark VE, et al. Integrated genomic analyses of de novo pathways underlying atypical meningiomas. *Nat Commun*. 2017;8. doi:10.1038/ncomms14433
115. Sahm F, Schimpf D, Olar A, et al. TERT promoter mutations and risk of recurrence in meningioma. *J Natl Cancer Inst*. 2016;108(5). doi:10.1093/jnci/djv377
116. Sievers P, Hielscher T, Schimpf D, et al. CDKN2A/B homozygous deletion is associated with early recurrence in meningiomas. *Acta Neuropathol*. 2020;140(3):409–413. doi:10.1007/s00401-020-02188-w
117. Nassiri F, Liu J, Patil V, et al. A clinically applicable integrative molecular classification of meningiomas. *Nature*. 2021;597(7874):119–125. doi:10.1038/s41586-021-03850-3
118. Shankar GM, Abedalthagafi M, Vaubel RA, et al. Germline and somatic BAP1 mutations in high-grade rhabdoid meningiomas. *Neuro Oncol*. 2017;19(4):535–545. doi:10.1093/neuonc/nov235
119. Sievers P, Sill M, Blume C, et al. Clear cell meningiomas are defined by a highly distinct DNA methylation profile and mutations in SMARCE1. *Acta Neuropathol*. 2021;141(2):281–290. doi:10.1007/s00401-020-02247-2
120. Simon M, Kokkino AJ, Warnick RE, et al. Role of genomic instability in meningioma progression. *Genes, Chromosom Cancer*. 1996;16(4):265–269. doi:10.1002/(sici)1098-2264(199608)16:4<265::aidgcc7>3.0.co;2-w
121. Fountain DM, Smith MJ, O'Leary C, et al. The spatial phenotype of genotypically distinct meningiomas demonstrate potential implications of the embryology of the meninges. *Oncogene*. 2021;40(5):875–884. doi:10.1038/s41388-020-01568-6
122. Weber RG, Boström J, Wolter M, et al. Analysis of genomic alterations in benign, atypical, and anaplastic meningiomas: Toward a genetic model of meningioma progression. *Proc Natl Acad Sci USA*. 1997;94(26):14719–14724. doi:10.1073/pnas.94.26.14719
123. Abedalthagafi MS, Merrill PH, Bi WL, et al. Angiomatous meningiomas have a distinct genetic profile with multiple chromosomal polysomies including polysomy of chromosome 5. *Oncotarget*. 2014;5(21):10596–10606. doi:10.18632/oncotarget.2517



124. Nassiri F, Mamatjan Y, Suppiah S, et al. DNA methylation profiling to predict recurrence risk in meningioma: development and validation of a nomogram to optimize clinical management. *Neuro Oncol.* 2019;21(7):901–910. doi:10.1093/neuonc/noz061
125. Sahm F, Schrimpf D, Stichel D, et al. DNA methylation-based classification and grading system for meningioma: a multicentre, retrospective analysis. *Lancet Oncol.* 2017;18(5):682–694. doi:10.1016/S1470-2045(17)30155-9
126. Vasudevan HN, Braunstein SE, Phillips JJ, et al. Comprehensive molecular profiling identifies FOXM1 as a key transcription factor for meningioma proliferation. *Cell Rep.* 2018;22(13):3672–3683. doi:10.1016/j.celrep.2018.03.013
127. Chen WC, Vasudevan HN, Choudhury A, et al. A prognostic gene-expression signature and risk score for meningioma recurrence after resection. *Neurosurgery.* 2021;88(1):202–210. doi:10.1093/neuros/nyaa355
128. Olar A, Goodman LD, Wani KM, et al. A gene expression signature predicts recurrence-free survival in meningioma. *Oncotarget.* 2018;9(22):16087–16098. doi:10.18632/oncotarget.24498
129. Menke JR, Raleigh DR, Gown AM, et al. Somatostatin receptor 2a is a more sensitive diagnostic marker of meningioma than epithelial membrane antigen. *Acta Neuropathol.* 2015;130(3):441–443. doi:10.1007/s00401-015-1459-3
130. Rachinger W, Stoecklein VM, Terpolilli NA, et al. Increased 68Ga-DOTATATE uptake in PET imaging discriminates meningioma and tumor-free tissue. *J Nucl Med.* 2015;56(3):347–353. doi:10.2967/jnumed.114.149120
131. Sommerauer M, Burkhardt JK, Frontzek K, et al. 68Gallium-DOTATATE PET in meningioma: a reliable predictor of tumor growth rate? *Neuro Oncol.* 2016;18(7):1021–1027. doi:10.1093/neuonc/now001
132. Mahase SS, Roth O'Brien DA, No D, et al. [68Ga]-DOTATATE PET/MRI as an adjunct imaging modality for radiation treatment planning of meningiomas. *Neuro-Oncology Adv.* 2021;3(January):1–9. doi:10.1093/neoajnl/vdab012
133. Zollner B, Ganswindt U, Maihöfer C, et al. Recurrence pattern analysis after [68Ga]-DOTATATE-PET/CT -planned radiotherapy of high-grade meningiomas. *Radiat Oncol.* 2018;13(1). doi:10.1186/s13014-018-1056-4
134. Bashir A, Larsen VA, Ziebell M, Fugleholm K, Law I. Improved detection of postoperative residual meningioma with [68Ga]Ga-DOTA-TOC PET imaging using a high-resolution research tomograph PET scanner. *Clin Cancer Res.* 2021;27(8):2216–2225. doi:10.1158/1078-0432.CCR-20-3362
135. Hadi I, Biczok A, Terpolilli N, et al. Multimodal therapy of cavernous sinus meningioma: Impact of surgery and 68Ga-DOTATATE PET-guided radiation therapy on tumor control and functional outcome. *Neuro-Oncol Adv.* 2021;3(1). doi:10.1093/neoajnl/vdab114
136. Dressen MS, Muthukrishnan A, Tragon TR, Lieberman FS, Mountz JM. Complementary molecular and metabolic characterization of meningiomas with DOTATATE and FDG-PET: Advancing treatment planning and prognostication. *Clin Nucl Med.* 2019;44(1):e26–e27. doi:10.1097/RLU.0000000000002328
137. Haslund-Vinding J, Skjoth-Rasmussen J, Poulsgaard L, et al. Proposal of a new grading system for meningioma resection: the Copenhagen Protocol. *Acta Neurochir (Wien)* 2022;164(1):229–238. doi:10.1007/s00701-021-05025-5