



Contents lists available at ScienceDirect

International Journal of Surgery Case Reports

journal homepage: www.casereports.com

Retrocecal hernia preoperatively diagnosed by computed tomography: A case report



Shingo Ito^{a,b,*}, Ryohei Takeda^a, Ritsuo Kokubo^a, Yoshio Sakai^a, Hirokazu Matsuzawa^b, Kiichi Sugimoto^b, Makoto Takahashi^b, Yutaka Kojima^b, Michitoshi Goto^b, Yuichi Tomiki^b, Kazuhiro Sakamoto^b

^a Department of Surgery, Yotsukaido Tokushukai Hospital, Chiba, Japan

^b Department of Coloproctological Surgery, Juntendo University Faculty of Medicine, Tokyo, Japan

ARTICLE INFO

Article history:

Received 10 May 2017

Received in revised form 9 June 2017

Accepted 11 June 2017

Available online 28 June 2017

Keywords:

Retrocecal hernia
Internal hernia
Pericecal hernia

ABSTRACT

INTRODUCTION: Retrocecal hernia is a rare type of pericecal hernia. Because it is difficult to diagnose preoperatively, it is often treated with emergency operation.

CASE PRESENTATION: An 83-year-old male patient experienced sudden abdominal pain. Marked small bowel dilatation and intestinal obstruction were detected by abdominal computed tomography (CT). An enhanced CT scan also revealed a trapped cluster of small bowel loops behind the cecum and ascending colon. We preoperatively diagnosed small bowel ileus as a result of retrocecal hernia. After conservative therapy with a long intestinal tube, an emergency operation was performed. During the surgery, a portion of the ileum was found to be incarcerated in the retrocecal fossa. Intestinal resection was not necessary because the incarcerated ileum appeared viable, and the orifice to the hernia was opened. The patient was discharged without postoperative complications.

DISCUSSION: The diagnosis of retrocecal hernia can often be confirmed intraoperatively. This disease is identified based on a minimal error in rotation with incarceration behind the cecum during the final phase of descent and fixation of the right colon or failure of cecal and retroperitoneal fixation. Early preoperative diagnosis is important to prevent intestinal ischemia, necrosis, and perforation and to reduce resection rates.

CONCLUSION: Early preoperative diagnosis is important to avoid resection of the small intestine. CT scans are useful for preoperative diagnosis in case of retrocecal hernia.

© 2017 The Author(s). Published by Elsevier Ltd on behalf of IJS Publishing Group Ltd. This is an open access article under the CC BY-NC-ND license (<http://creativecommons.org/licenses/by-nc-nd/4.0/>).

1. Introduction

Pericecal hernia is a rare disease that occurs at one of the four principal fossae in the cecal region [1,2]. Although the correct preoperative diagnosis of pericecal hernias is difficult, we diagnosed retrocecal hernia by computed tomography (CT) before successful surgical treatment. Early preoperative diagnosis of pericecal hernias is important to avoid resection of the small intestine. The presented case has been reported in line with the SCARE criteria [3].

* Corresponding author. Present address: Department of Coloproctological Surgery, Juntendo University Faculty of Medicine, 2-1-1 Hongo, Bunkyo-ku, Tokyo 113-8421, Japan.

E-mail addresses: sgitou@juntendo.ac.jp (S. Ito), daiyokomon@yahoo.co.jp (R. Takeda), kokubowl@yahoo.co.jp (R. Kokubo), y.sakai@yotsutoku.jp (Y. Sakai), hmatsuz@juntendo.ac.jp (H. Matsuzawa), ksugimo@juntendo.ac.jp (K. Sugimoto), mktakaha@juntendo.ac.jp (M. Takahashi), yutachan@juntendo.ac.jp (Y. Kojima), m-goto@juntendo.ac.jp (M. Goto), tomiki@juntendo.ac.jp (Y. Tomiki), kazusaka@juntendo.ac.jp (K. Sakamoto).

<http://dx.doi.org/10.1016/j.ijscr.2017.06.034>

2210-2612/© 2017 The Author(s). Published by Elsevier Ltd on behalf of IJS Publishing Group Ltd. This is an open access article under the CC BY-NC-ND license (<http://creativecommons.org/licenses/by-nc-nd/4.0/>).

2. Case presentation

The patient was an 83-year-old man who presented with sudden pain in the right lower abdomen. He underwent right partial pneumonectomy following a traffic accident; therefore, arterial blood gas analysis showed hypoxia (PCO₂ of 35 mmHg; PO₂ of 70 mmHg). He had no remarkable family history, and his vital signs were normal, except for mild pyrexia of 37.5 °C. Examination of the abdomen revealed rebound tenderness at the right lower portion. Blood tests revealed no abnormalities, except for a white blood cell count of 11,000 mm³ (n.v.: 3200–8500 mm³). Furthermore, marked small bowel dilatation and intestinal obstruction were evident on abdominal X-ray and CT imaging. CT imaging also revealed a dilation of the small bowel in the right lower abdomen, and the cecal colon was displaced inward (Fig. 1). We diagnosed small bowel ileus as a result of retrocecal hernia. The conservative therapy with a long intestinal tube failed to resolve the symptoms, therefore an emergency operation was performed. Because of the patient's hypoxia, laparotomy and not laparoscopy was selected. Intraoperative findings revealed that a part of the small bowel was incarcerated within

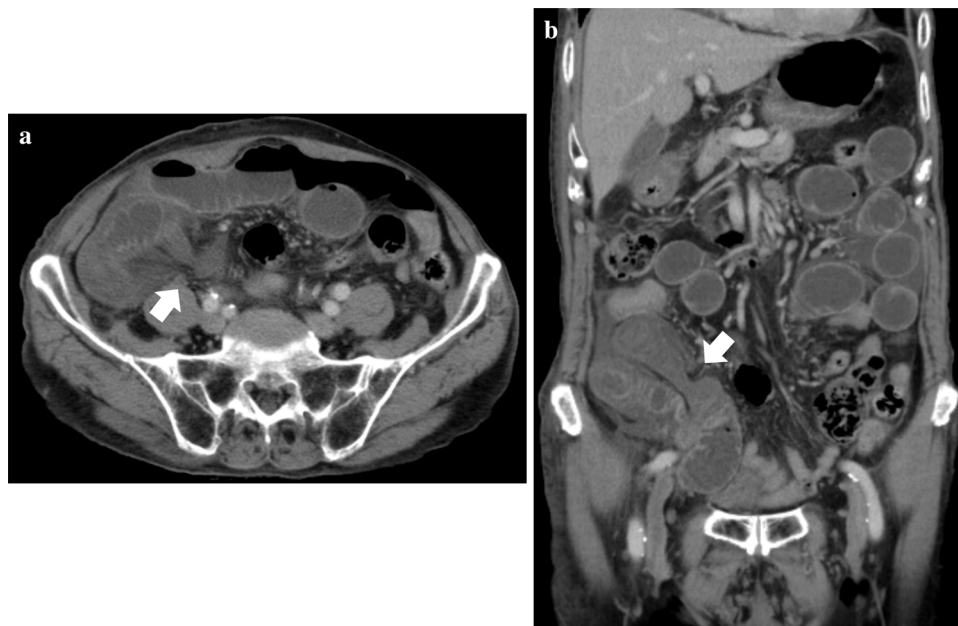


Fig. 1. Computed tomography image showing dilation of the small bowel. The arrow indicates that a small intestinal caliber change is present behind the cecum (a: horizontal image, b: coronal image).

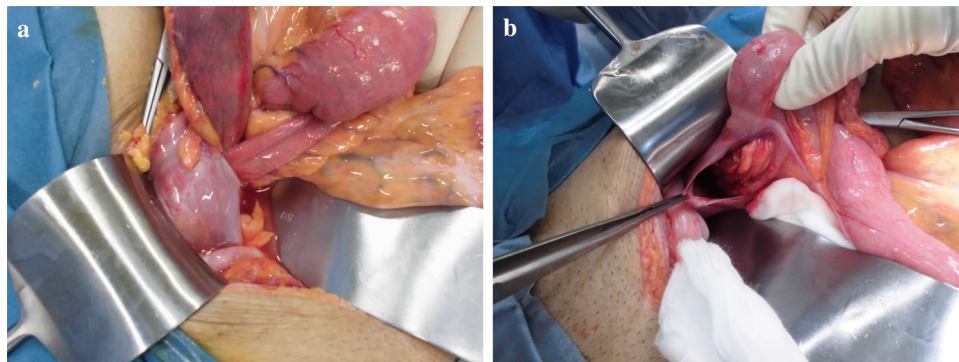


Fig. 2. Intraoperative findings showing incarceration of the ileum in the retrocecal fossa.

the retrocecal recess and the intestinal tract was strangulated in the hernia orifice, thereby confirming retrocecal hernia (Fig. 2). The incarcerated small intestine was viable and reducible, and the orifice of the retrocecal region was opened. He was discharged in a good condition on the 14th postoperative day with no complications. The patient had no recurrence in 6 months after surgery.

3. Discussion

Internal hernias are either congenital or acquired; in majority of the cases, they are acquired because of a previous abdominal surgery [1]. Cases of acquired internal herniation in adults who have undergone an abdominal surgery mainly occur after liver transplantation and bariatric procedures, peritoneal inflammations, traumas, and ischemic changes [2]. Congenital internal hernias in adults are extremely rare and originate from congenital anomalous openings lacking a true peritoneal sac [4]. In such cases, abdominal surgeries are never performed. Internal hernias are generally classified into six types: paraduodenal, pericecal, foramen of Winslow, transmesenteric, pelvic and supravesical, and intersigmoid [4–6]. Moreover, pericecal hernia is a major type of internal hernia that can be classified into four types: superior ileocecal recess, inferior ileocecal recess, paracolic sulcus, and retrocecal

recess [6]. A study reported that paracecal hernias are the most common type of internal hernia, accounting for 46.7% of cases, followed by retrocecal hernias, which account for 26.7% of cases [7].

Because there are no specific symptoms of internal hernias, they are rarely diagnosed preoperatively. Currently, CT is an important tool for the evaluation of intestinal obstruction and acute abdominal diseases [8] and has become the first-line imaging technique in patients with a suspected internal hernia [9]. The CT features of internal hernias include the presence of a sac-like mass or cluster of dilated small bowel loops at an abnormal anatomic location and stretched, engorged, or displaced mesenteric vascular pedicle and converging vessels at the hernia orifice [10]. In case of acute-onset and severe small bowel obstruction, Furukawa et al. [11] recommended performing an emergency surgical procedure, whereas partial bowel dilation can initially be managed with conservative therapy. However, if abnormal bowel loops at unusual anatomic regions, including behind the ascending colon, are detected by CT, surgery is recommended to decrease the risk of hernial strangulation. Furthermore, close monitoring of the patient's vital signs, physical examination, and follow-up CT are useful for preventing small bowel resection.

Table 1
Literature review of retrocecal hernia cases from 2000 to 2017.

No	Author (year)	Age	Sex	Preoperative diagnosis	Operation procedure	Location of hernia	Resection of small bowel	Treatment of the hernia orifice
1	Shibuya ¹²⁾ (2010)	63	M	Strangulation in the ileocecal region	Open	ileum	none	Closure
2	Sasaki ¹³⁾ (2016)	65	M	Internal hernia	Laparoscopy	ileum	none	Closure
3	Hirayama ¹⁴⁾ (2016)	86	M	Retrocecal hernia	Open	ileum	none	Closure
4	Our case (2017)	83	M	Retrocecal hernia	Open	ileum	none	open

We searched PubMed for reports containing the key words “retrocecal hernia” from 2000 to 2017. Four cases have been reported in the literature; including our case [12–14] (Table 1). In all cases; the patients were male; with an average age of 74 years. Three cases were diagnosed with retrocecal hernia or paracecal hernia by preoperative radiological examination. All cases underwent surgery; although none of the cases underwent small bowel resection. However; two of the 31 patients with retrocecal hernia in Japan died following surgery [15]. Therefore; early preoperative diagnosis is imperative in preventing intestinal ischemia; necrosis; and perforation and in reducing resection rates [16]. Although the use of laparoscopic surgery is gradually becoming more widespread [17–19]; it was not suitable for our case because the patient had hypoxia. Researchers in recent reports have described the laparoscopic management of acute small bowel obstruction; which resulted in the early recovery of bowel function and a shortened postoperative stay [19,20]. The treatment for such orifices follows two patterns: opening or closure. In our case; we performed the opening of the orifice. According to a previous study; approximately 50% of approaches to an orifice are either opening or closure [13].

4. Conclusion

Despite low probability, retrocecal hernia should be included in the differential diagnosis for right lower abdominal pain. Abdominal CT scan is useful for the preoperative diagnosis of retrocecal hernias.

Conflicts of interest

The authors have no conflicts of interests.

Funding

None.

Ethical approval

Not applicable.

Informed consent

The patient's consent was obtained.

Author contributions

All authors have approved the final version of this manuscript.

Guarantor

ryohei Takeda, Ritsuo Kokubo, Yoshio Sakai, Kiichi Sugimoto, Yutaka Kojima, Michitoshi Goto, Yuichi Tomik, Kazuhiro Sakamoto.

References

- [1] H.M. Edwards, H. Al-Tayar, A transmesenteric congenital internal hernia presenting in an adult, *J. Surg. Case Rep.* 12 (2013), <http://dx.doi.org/10.1093/jscr/rjt099>.
- [2] K. Sibabrata, M. Vandana, K.R. Pratap, A rare type of primary internal hernia causing small intestinal obstruction, *Case Rep. Surg.* 2016 (2016), <http://dx.doi.org/10.1155/2016/3540794>.
- [3] R.A. Agha, A.J. Fowler, A. Saetta, I. Barai, S. Rajmohan, D.P. Orgill, the SCARE group, The SCARE statement: consensus-based surgical case report guidelines, *Int. J. Surg.* 34 (2016) 180–186.
- [4] G.G. Ghahremani, Internal abdominal hernias, *Surg. Clin. N. Am.* 64 (2) (1984) 393–406.
- [5] A.I. Rivkind, E. Shiloni, M. Muggia-Sullam, Y. Weiss, E. Lax, H.R. Freund, Paracecal hernia: a cause of internal obstruction, *Dis. Colon Rectum* 29 (11) (1986) 752–754.
- [6] G.G. Ghahremani, *Abdominal and Pelvic Hernias*, 2nd ed., Saunders, Philadelphia, 2000.
- [7] T. Hirokawa, T. Hayakawa, M. Tanaka, Y. Okada, H. Sawai, H. Takeyama, T. Manabe, Laparoscopic surgery for diagnosis and treatment of bowel obstruction: case report of paracecal hernia, *Med. Sci. Monit.* 13 (7) (2007) 79–82.
- [8] E.J. Jang, S.H. Cho, D.D. Kim, A case of small bowel obstruction due to a paracecal hernia, *J. Korean Soc. Coloproctol.* 27 (1) (2011) 41–43.
- [9] L.C. Martin, E.M. Merkle, W.M. Thompson, Review of internal hernias: radiographic and clinical findings, *AJR: Am. J. Roentgenol.* 186 (3) (2006) 703–717.
- [10] N. Takeyama, T. Gokan, Y. Ohgiya, S. Satoh, T. Hashizume, K. Hataya, H. Kushiro, M. Nakanishi, M. Kusano, H. Munechika, CT of internal hernias, *Radiographics* 25 (4) (2005) 997–1015.
- [11] A. Furukawa, M. Yamasaki, K. Furuichi, Helical CT in the diagnosis of small bowel obstruction, *Radiographics* 21 (2001) 341–355.
- [12] H. Shibuya, S. Ishihara, T. Akahane, R. Shimada, A. Horiuchi, Y. Aoyagi, K. Nakamura, T. Hayama, H. Yamada, K. Nozawa, K. Matsuda, T. Watanabe, A case of paracecal hernia, *Int. Surg.* 95 (3) (2010) 277–280.
- [13] K. Sasaki, H. Kawasaki, H. Abe, H. Nagai, F. Yoshimi, Retrocecal hernia successfully treated with laparoscopic surgery: a case report and literature review of 15 cases in Japan, *Int. J. Surg. Case Rep.* 18 (2016) 45–47.
- [14] H. Hirayama, A. Nishida, S. Shintani, R. Osaki, A. Sonoda, O. Inatomi, S. Bamba, N. Kitamura, H. Sonoda, M. Sugimoto, T. Shimizu, M. Tani, A. Andoh, A case of a retrocecal hernia successfully diagnosed prior to surgical treatment, *Nihon Shokakibyō Gakkai Zasshi* 113 (9) (2016) 1594–1599.
- [15] T. Kitao, A. Yamaguchi, M. Isogai, T. Harada, Y. Kaneoka, M. Suzuki, Four cases of pericecal hernia, *Nihon Rinsho Geka Gakkai Zasshi* 62 (5) (2001) 1207–1211.
- [16] R. Gomes, J. Rodrigues, Spontaneous adult transmesenteric hernia with bowel gangrene, *Hernia* 15 (3) (2011) 343–345.
- [17] K. Sato, T. Sakurai, H. Sato, K. Yasuda, Y. Kaiwa, Y. Oohashi, A case of retrocecal hernia treated under laparoscopy, *Geka* 72 (2010) 996–999.
- [18] K. Mitsui, K. Namiki, H. Matsumoto, R. Yoshida, N. Hujita, H. Notsuda, A case of retrocecal hernia treated by laparoscopic surgery followed by appendectomy, *Shujutsu* 59 (2005) 1753–1756.
- [19] K. Sakai, T. Fujiki, H. Kuramochi, K. Yamada, H. Jozaki, A case of retrocecal hernia treated with laparoscopic surgery, *J. Jpn. Surg. Assoc.* 65 (2004) 138–141.
- [20] B. Kirshtein, A. Roy-Shapira, L. Lantsberg, E. Avinoach, S. Mizrahi, Laparoscopic management of acute small bowel obstruction, *Surg. Endosc.* 19 (2005) 464–467.

Open Access

This article is published Open Access at sciedirect.com. It is distributed under the [IJSCR Supplemental terms and conditions](#), which permits unrestricted non commercial use, distribution, and reproduction in any medium, provided the original authors and source are credited.