

Available online at www.sciencedirect.com

ScienceDirect

journal homepage: www.elsevier.com/locate/radcr

Case Report

Percutaneous balloon-assisted ultrasound-guided direct glue embolization of deep femoral artery pseudoaneurysm rupture ☆,☆☆,★

Thanh Dung Le, MD, PhD^{a,1}, Van Sy Than, MD, MSc^{a,1,*}, Minh Duc Nguyen, MD, MSc^{b,1}

^aDepartment of Radiology, Viet Duc University Hospital, 40 Trang Thi Street, Hang Bong Ward, Hoan Kiem District, Hanoi 100000, Vietnam

^bDepartment of Radiology, Pham Ngoc Thach University of Medicine, 2 Duong Quang Trung, Ward 12, District 10, Ho Chi Minh City 700000, Vietnam

ARTICLE INFO

Article history:

Received 29 November 2020

Accepted 6 December 2020

Keywords:

Deep femoral artery

Pseudoaneurysm

Percutaneous direct glue embolization

Balloon-assisted embolization

Tunneled femoral vein hemodialysis catheter

ABSTRACT

Deep femoral artery pseudoaneurysm is commonly caused by arterial access in endovascular procedures. Some therapeutic options have been applied for this lesion such as: surgery, ultrasound-guided compression, direct thrombin injection, covered stent, coil embolization. One of the effective therapeutic for treatment of femoral artery pseudoaneurysm but uncommon use is percutaneous direct glue injection. We hereby report a case of right deep femoral artery pseudoaneurysm after 2-week placement of the femoral tunneled hemodialysis catheter which was successfully treated by balloon-assisted percutaneous ultrasound-guided direct glue embolization.

© 2020 The Authors. Published by Elsevier Inc. on behalf of University of Washington.

This is an open access article under the CC BY-NC-ND license (<http://creativecommons.org/licenses/by-nc-nd/4.0/>)

Introduction

Deep femoral artery pseudoaneurysm occurs when the puncture access is more distal than normal, lower the level of femoral bifurcation [1]. Some other circumstances may lead to this condition such as: trauma, surgery, intravenous drug

abuse [2–5]. If not treated appropriately, femoral pseudoaneurysms may cause some complications such as: ruptured pseudoaneurysm, infection, and limb ischemia [6].

Surgery is the classic treatment of femoral artery pseudoaneurysm, but it is an invasive procedure and can lead to local complications (bleeding, infection, neuropathy...). Several non-surgical alternative treatments have also been applied

☆ Competing Interest: There are no conflicts of interest to declare.

☆☆ Acknowledgments: Not Applicable.

★ Funding: This study was not supported by any funding.

* Corresponding author.

E-mail address: sy.hmu0915@gmail.com (V.S. Than).

¹ These authors contributed equally to this article as first authorship.

<https://doi.org/10.1016/j.radcr.2020.12.018>

1930-0433/© 2020 The Authors. Published by Elsevier Inc. on behalf of University of Washington. This is an open access article under the CC BY-NC-ND license (<http://creativecommons.org/licenses/by-nc-nd/4.0/>)

such as: ultrasound-guided compression, percutaneous direct thrombin injection into the pseudoaneurysm, endovascular intervention [1,3,6–10].

Endovascular treatment is a mini-invasive and effective therapeutic treatment for pseudoaneurysms/aneurysms with variety of techniques and material embolization. N-butyl-2 cyanoacrylate (NBCA) glue, a liquid embolic material, is very commonly used for treatment of terminal arterial lesions, or parenchymal injuries, but limited for proximal arterial injuries due to the strougly manipulating or may result in downstream ischemia [11–13].

We describe a case with the right deep femoral pseudoaneurysm after 2 weeks placement of femoral vein hemodialysis catheter, which is successfully treated by percutaneous direct NBCA embolization using balloon-assisted.

Case report

A 57-year-old woman was transferred to our hospital due to a pain pulsatile mass at the right groin for 48 hours after 2-week placement of tunneled hemodialysis catheter. Her medical history included obesity, hypertension, diabetic mellitus,

and end-stage renal disease recently. On clinical examination, she appeared conscious, pallor, hemodynamically stable with a heart rate of 100 bpm, blood pressure of 160/90 mmHg, and room-air peripheral capillary oxygen saturation (SpO₂) of 97%. A pulsatile mass measuring 6 × 10 cm in the location of right femoral catheter with swelling of soft tissue adjacent was found, without sign of right lower extremity ischemia. Blood tests showed an anemia with hemoglobin levels of 57 g/L (normal range 125–145 g/L), hematocrit levels of 0.162 L/L (normal range 0.35–0.47 L/L), and mean corpuscular volume levels of 85.4 fL (normal range 80–100 fL). Neither abnormal levels of white blood cell nor platelet values nor coagulant disorder was found. An increase serum creatinine of 448 μmol/L (normal values <90 μmol/L in women) and uremia of 19.9 mm/L (normal range 1.7–8.3 mmol/L) also recorded. An echo-Doppler and a computed tomography angiography of the lower extremities were performed confirming a pseudoaneurysm of the right deep femoral artery, measuring 8 × 18 mm, with a large hematoma adjacent of 5 × 6 × 15 cm, and edema of surrounding soft tissue.

Due to an acute anemia, 2 units of packed red blood cells were transfused, and an endovascular intervention

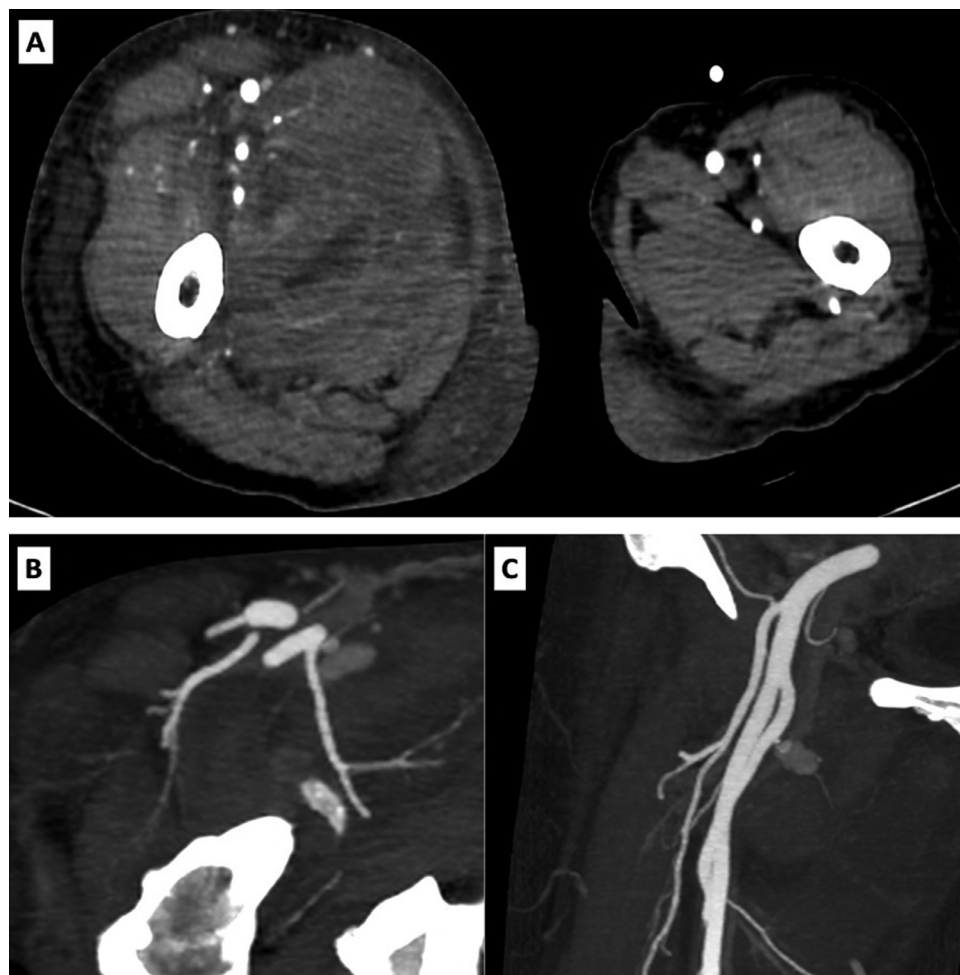


Fig. 1 – Computed tomography angiography of the lower extremities: Axial plan (A) showed a large hematoma of the right thigh with edema of surrounding soft tissue. MIP axial plan (B) and coronal plan (C) showed a pseudoaneurysm arising from the right deep femoral artery.

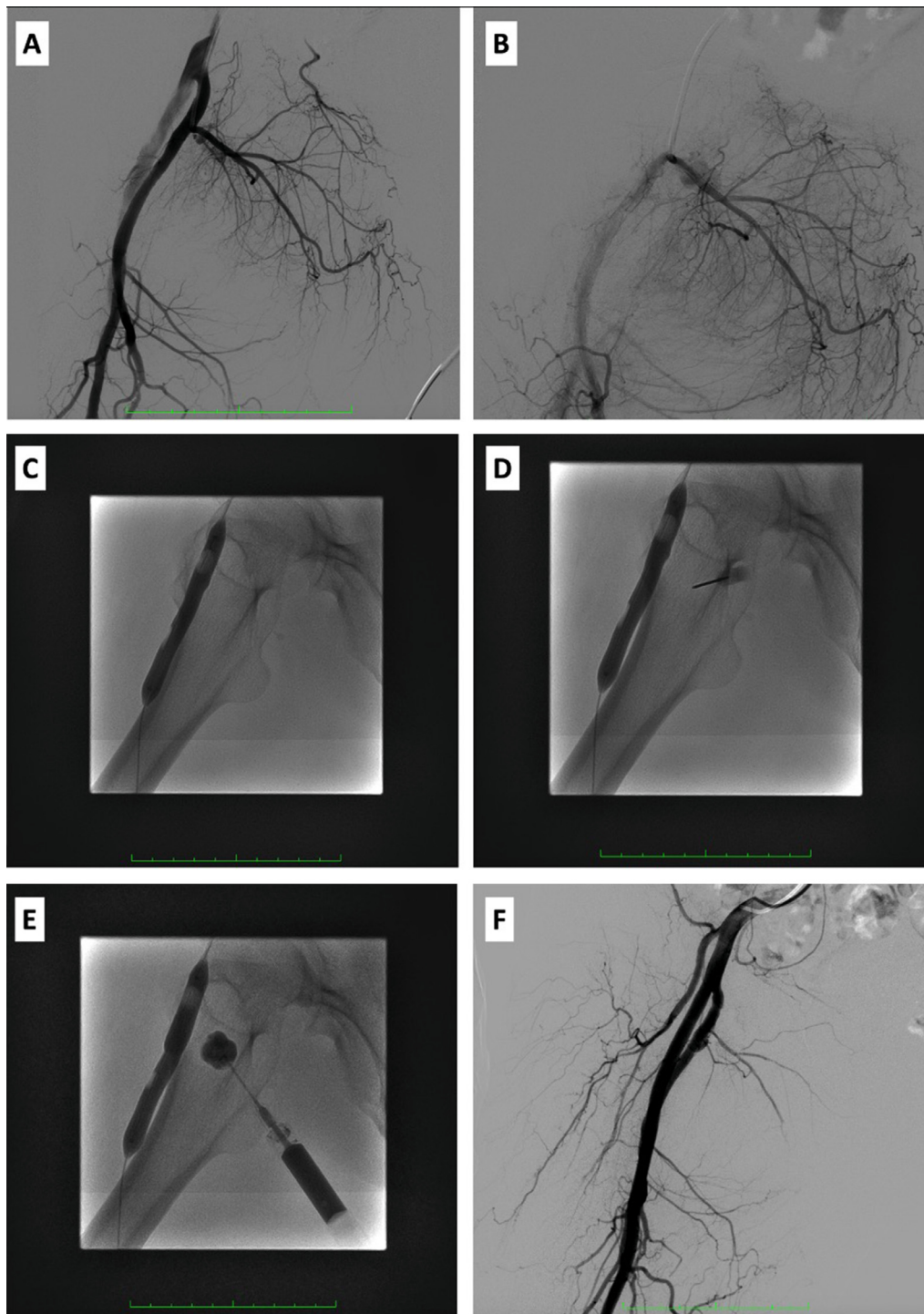


Fig. 2 – Selective right femoral angiography (A) and (B) showed a pseudoaneurysm of right deep femoral artery. (C) An EverCross 0.035" balloon of 8 x 60 mm (PTA Balloon Catheter Medtronic AVE, Santa Rosa, CA, EE. UU) was inflated in front of the pseudoaneurysm's neck to avoid the connection between the pseudoaneurysm and the parent artery. (D) The pseudoaneurysm sac was punctured under ultrasound guidance (not shown) by a needle 18G x 2 1/2". (E) Injection of NBCA into the pseudoaneurysm's sac under fluoroscopy guidance. (F) The final control angiography of the right common femoral artery confirmed no flow into the pseudoaneurysm.

was indicated for treatment the pseudoaneurysm. The patient underwent diagnostic angiography from left common femoral artery approach through a 5.0-French sheath (Terumo, Tokyo, Japan). A pseudoaneurysm of right deep femoral artery measuring 6 × 16 mm with a small neck was presented. Ultrasound-guided puncture of the pseudoaneurysm sac under local anesthesia was carried out with a needle 18G x 2 1/2" (Green Surflo ETFE I.V. Catheters – 50, Terumo, Tokyo, Japan). We inflated an EverCross 0.035" (PTA Balloon Catheter Medtronic AVE, Santa Rosa, CA, EE. UU) of 8 × 60mm in front of the pseudoaneurysm's neck to block blow into the pseudoaneurysm. Five percent glucose solution was used to flush the pseudoaneurysm sac, and following slowly injecting the mixture of NBCA (Histoacryl; B. Braun, Melsungen, Germany) and Lipiodol (Lipiodol Ultrafluide, Laboratoire Guerbet, Aulnay-Sous-Bois, France) with 1:2 dilution under fluoroscopy guidance until the sac is totally filled (Fig. 1). The balloon catheter was deflated 1 minute after injection finished. On the control angiography, a total exclusion of pseudoaneurysm was obtained.

A left cephalo-brachial fistula was created after three days for long term hemodialysis, and a left femoral tunneled hemodialysis catheter was placed while waiting the fistula development. The patient was discharged 3 days after the operation without any complications. The examination at 1-month postoperative was unremarkable and no complication nor any discomfort was found.

Discussion

In this study, our patient had a pseudoaneurysm of the deep femoral artery. Endovascular intervention is preferred over surgery due to less invasive and low rate of local complications [7–9,14], in which covered stent is considered to be highly effective, safe method, but requiring the use of anticoagulant for a long time, and sometimes not available with suitable size. Ultrasound-guided compression was reported with a success rate of up to 90%, but this method is more suitable for non-obese patients, an unruptured pseudoaneurysm, and without coagulation disorders, while it is painful, taking a long time procedure [6,15]. In our patient, obesity, a small neck pseudoaneurysm, with large hematoma surrounding were unsuitable factors for ultrasound-guided compression. Percutaneous direct thrombin injection has already used in some centers with high success rate, regardless of the coagulation status and size of the pseudoaneurysm [16]. This embolic material, however, is expensive, and unavailable in many centers, neither in our institution. The greatest risks of thrombin injection procedure are allergic reaction (especially in whom repeated utilization) and limb ischemia due to the escape of thrombin into the parent artery through the neck of pseudoaneurysm [17].

The percutaneous direct glue injection technique has been commonly used for the treatment AVMs of soft tissue, in which the selective catheterization of pathologic branches could not be performed through endovascular intervention [18,19]. With the same method, it is possible to inject glue directly into the pseudoaneurysm sac through the skin. Aytekin et al. reported a case successful using NBCA instead of

thrombin to embolize the pseudoaneurysm of the radial artery by percutaneous direct puncture [20]. However, as a liquid embolic agent, it has the risk of leakage the glue through the neck of pseudoaneurysm before polymerization which causes limb ischemia. For reducing this risk some techniques were described in literature [14,20,21]. Firstly, the pseudoaneurysm's neck may be compressed by ultrasound probe until no flow into the pseudoaneurysm sac before glue injection [20]. But the difficulty to identify the no flow in the pseudoaneurysm sac by ultrasound is the drawback of this technique. Secondly, the compression of the total pseudoaneurysm sac by ultrasound probe before glue injecting percutaneous injection was performed by Andrea Del Corso et al. [14]. This technique helps to reduce the pseudoaneurysm size, reduce the volume of glue injection, and so minimize the mass effect of the pseudoaneurysm, but limited for obese patients or in cases with big hematoma. Lastly, Aytekin et al. and Loïc Griviau et al. inflated an angioplasty balloon at the parent artery during glue injection [9,21]. With this technique, it is certain to no blood flow into the pseudoaneurysm cavity owing to block pseudoaneurysm neck, and it helps overcome the disadvantages of previous methods, painlessness, regardless coagulant status, obesity, or large hematoma, etc.

Nonetheless, the method using balloon-assisted has some drawbacks. First, it has a risk of the persistent perfusion of pseudoaneurysm due to incomplete injection. Fortunately, this problem can be resolved by repeating the procedure until completely filling the sac, or in case of unsuccessful technique a stent-graft could be used to exclusion the pseudoaneurysm [9]. Secondly, in the case of a large pseudoaneurysm, a large volume of glue injected might cause the mass effect on surrounding structures (nerves, femoral veins) and be discomfort for patient. Furthermore, this technique is necessary a contralateral femoral access which has a risk of the same complication.

Conclusion

Deep femoral artery pseudoaneurysm is commonly caused by vascular procedures, including the placement of tunneled femoral hemodialysis catheter, due to too distal puncture access. Percutaneous ultrasound-guided direct glue embolization using balloon-assisted may be a simple and effective alternative choice for treatment of pseudoaneurysm of the deep femoral artery (Fig. 2).

Ethics approval

For this type of study formal consent is not required.

Informed consent

Informed consent of patient was obtained.

Consent for publication

Consent for publication was obtained for every individual person's data included in the study during the post-withdrawal visit, noted in the patient's paper medical record.

REFERENCES

- [1] Hamraoui K, Ernst SM, van Dessel PF, Kelder JC, ten Berg JM, Suttorp MJ, et al. Efficacy and safety of percutaneous treatment of iatrogenic femoral artery pseudoaneurysm by biodegradable collagen injection. *J Am Coll Cardiol* 2002;39:1297–304.
- [2] Alsmady M, Abdallah F, Shanti H, Samara O. Spontaneous femoral artery pseudoaneurysm in a young patient. *J Surg Case Rep* 2012;2012:18–18.
- [3] Moini M, Rasouli MR, Rayatzadeh H, Sheikholeslami G. Management of femoral artery pseudo-aneurysms in Iran: a single centre report of 50 cases. *Acta Chir Belg* 2008;108:226–30.
- [4] Mousavi SR, Saberi A, Tadayon N, Zeynalzadeh M, Kavyani A. Femoral artery ligation as treatment for infected pseudo-aneurysms, secondary to drug injection. *Acta Chir Belg* 2010;110:200–2.
- [5] Klouaris C, Katsargyris A, Papapetrou A, Vourliotakis G, Tsiodras S, Georgopoulos S, et al. Infected femoral artery pseudoaneurysm in drug addicts: the beneficial use of the internal iliac artery for arterial reconstruction. *J Vasc Surg* 2007;45:498–504.
- [6] Eisenberg L, Paulson EK, Kliewer MA, Hudson MP, DeLong DM, Carroll BA. Sonographically guided compression repair of pseudoaneurysms: further experience from a single institution. *AJR Am J Roentgenol* 1999;173:1567–73.
- [7] Altunbas G, Sucu M. Ultrasound guided compression for iatrogenic femoral artery pseudo aneurysms. *Ann Vasc Surg* 2018;49 321–321.
- [8] Hendriks JM, Dieleman P, Delrue F, d'Archambeau O, Lauwers P, Van Schil P. Spontaneous pseudo-aneurysm of the deep femoral artery treated by a covered stent. *Acta Chir Belg* 2007;107:412–15.
- [9] Griviau L, Chevallier O, Marcelin C, Nakai M, Pescatori L, Galland C, et al. Percutaneous ultrasound-guided balloon-assisted embolization of iatrogenic femoral artery pseudoaneurysms with Glubran® 2 cyanoacrylate glue: safety, efficacy and outcomes. *Quant Imaging Med Surg* 2018;8:796.
- [10] Okwuonu CG, Ojeh-Oziegbe O, Adejumo O, Iyawe I. Iatrogenic femoral artery pseudoaneurysm complicating vascular access for haemodialysis in a patient with end-stage renal disease; unexpected occurrence after a common procedure. *J Med Trop* 2016;18:116.
- [11] Takeuchi Y, Morishita H, Sato Y, Hamaguchi S, Sakamoto N, Tokue H, et al. Guidelines for the use of NBCA in vascular embolization devised by the Committee of Practice Guidelines of the Japanese Society of Interventional Radiology (CGJSIR). *Jpn J Radiol* 2014;32:500–17.
- [12] Kish JW, Katz MD, Marx MV, Harrell DS, Hanks SE. N-butyl cyanoacrylate embolization for control of acute arterial hemorrhage. *J Vasc Interv Radiol* 2004;15:689–95.
- [13] Won Y, Lee SL, Kim Y, Ku YM. Clinical efficacy of transcatheter embolization of visceral artery pseudoaneurysms using N-butyl cyanoacrylate (NBCA). *Diagn Interv Imaging* 2015;96:563–9.
- [14] Del Corso A, Vergaro G. Percutaneous treatment of iatrogenic pseudoaneurysms by cyanoacrylate-based wall-gluing. *Cardiovasc Intervent Radiol* 2013;36:669–75.
- [15] Loftus WK, Isaacs JL, Spyropoulos P. Femoral artery pseudo-aneurysm: ultrasound guided compression repair. *Australas Radiol* 1993;37:256–8.
- [16] Hanson JM, Atri M, Power N. Ultrasound-guided thrombin injection of iatrogenic groin pseudoaneurysm: Doppler features and technical tips. *Br J Radiol* 2008;81:154–63.
- [17] Kurzawski J, Sadowski M, Janion-Sadowska A. Complications of percutaneous thrombin injection in patients with postcatheterization femoral pseudoaneurysm. *J Clin Ultrasound* 2016;44:188–95.
- [18] Ryu CW, Whang SM, Suh DC, Kim S-M, Jang Y-J, Kim H-J, et al. Percutaneous direct puncture glue embolization of high-flow craniofacial arteriovenous lesions: a new circular ring compression device with a beveled edge. *Am J Neuroradiol* 2007;28:528–30.
- [19] Parihar A, Tomar S, Phadke RV. Direct sac puncture and glue embolization of intraosseous AVM of the maxilla. *Int J Oral Maxillofac Surg* 2011;40:749–52.
- [20] Aytakin C, Firat A, Yildirim E, Kirbas I, Boyvat F. Ultrasound-guided glue injection as alternative treatment of femoral pseudoaneurysms. *Cardiovasc Intervent Radiol* 2004;27:612–15.
- [21] Aytakin C, Boyvat F, Gebedek Ö, Coskun M. Balloon-assisted ultrasound-guided direct percutaneous embolization of a peripheral pseudoaneurysm with n-butyl cyanoacrylate. *Eur Radiol* 2002;12:S185–8.