

A patient with solid gynecologic cancer causing lactic acidosis, severe hypercalcemia, and hypoglycemia

John Hausken¹  | Ellen M. Haave² | Håkon Haugaa^{1,3} | Else M. Løberg^{4,5} | Ulf E. Kongsgaard^{1,5}

¹Department of Anesthesiology, Division of Emergencies and Critical Care, Oslo University Hospital, Oslo, Norway

²Department of endocrinology, Oslo University Hospital, Oslo, Norway

³Lovisenberg Diaconal University College, Oslo, Norway

⁴Department of Pathology, Oslo University Hospital, Oslo, Norway

⁵Medical Faculty, University of Oslo, Oslo, Norway

Correspondence

John Hausken, Department of Anaesthesiology, Division of Emergencies and Critical Care, Oslo University Hospital, Oslo, Norway.
Email: jhausken@ous-hf.no

Funding information

Only institutional funding was received.

Key Clinical Message

Though rare in cervical cancer patients, paraneoplastic syndrome usually presents with several endocrine and hormonal symptoms. Knowledge of the pathophysiology that underlies these abnormalities is beneficial to diagnosis and treatment. An interdisciplinary approach and test analysis prior to initiating specific treatment is recommended, though prognosis appears poor in advanced cases.

KEY WORDS

cervical squamous cell carcinoma, hypercalcemia, hypoglycemia, insulin-like growth factor, lactic acidosis, non-islet-cell tumor hypoglycemia, paraneoplastic syndrome

1 | INTRODUCTION

Endocrine paraneoplastic syndromes occur in patients with malignant disease and are caused by tumor production of hormones or peptides leading to metabolic derangements. These syndromes are typically detected after cancer diagnosis,^{1,2} and physician knowledge about these syndromes is important for patient care.³ Herein, we report an unusual case of paraneoplastic syndrome with three different simultaneously occurring metabolic disturbances in a 45-year-old female with a solid gynecologic tumor.

2 | CASE PRESENTATION

The previously healthy patient was admitted to her local hospital with suspected malignant disease because of a history of

low back pain, genital bleeding, and weight loss of 16 kg over the previous 6 months. Her medical condition was impaired, with blurred consciousness, pale skin, and dehydration. On clinical examination, multiple lymph nodes were located in the axillary, upper lateral quadrant of the right breast, and in the inguinal regions.

Laboratory tests (Table 1) revealed severe hypercalcemia combined with acute kidney injury. Treatment to lower calcium levels was initiated with intravenous hydration, loop diuretics, calcitonin, and bisphosphonate. Parathyroid hormone (PTH) level was low, excluding primary hyperparathyroidism. Multiple myeloma with lytic bone lesions or skeletal involvement was less likely. However, the patient had a very high concentration of parathyroid hormone-related protein (PTH-rP) (100.3 pmol/L; normal range: <2.6 pmol/L) and a paraneoplastic syndrome was suspected. An ultrasound (US) and computed tomography (CT) scan revealed a large pelvic

TABLE 1 Biochemical data

	At admission	Second measurement 11:00 AM	Final measurement 10:15 AM	Normal range
Glucose	1.0	5.1	7.7	4.2-6.3 mmol/L
Insulin	ND	ND	376	<160 pmol/L
C-peptide	ND	952	5566	300-1480 pmol/L
Proinsulin	ND	ND	39	<36 pmol/L
IGF1	ND	ND	<i>Prof. Frystyk laboratory, DK</i>	
IGF2	ND	ND	<i>Prof. Frystyk laboratory, DK</i>	
Big-IGF2	ND	ND	<i>Prof. Frystyk laboratory, DK</i>	
Cortisol	ND	284	ND	138-690 nmol/L
ACTH	ND	0.2	ND	<10.2 pmol/L
pH	7.23			7.35-7.45
pCO ₂	5.7			4.7-6.0 kPa
HCO ₃	18.0			22-26 mmol/L
BE	-9.6			±3 mmol/L
Lactate	9.2			0.6-1.4 mmol/L
Albumin	23			36-45 g/L
Total calcium	4.65			2.15-2.51 mmol/L
Creatinine	235			45-90 μmol/L
PTH	1.1			1.5-7.0 pmol/L
PTH-rP	100.6			<2.6 pmol/L

Case Report paraneoplastic syndrome in a solid gynecological tumor. ACTH, adrenocorticotrophic hormone; IGF, insulin growth factor; PTH, parathyroid hormone; PTH-rP, Parathyroid hormone-related protein.

tumor, and upon subsequent gynecological examination, cervical cancer was suspected. Moderate dilatation of the renal pelvis and calyces was found on CT and US, though percutaneous nephrostomy was not required.

Histopathological examinations of cervical biopsies confirmed a diagnosis of cervical squamous cell carcinoma. The patient's clinical condition deteriorated within a few days, first with worsening of her mental condition, which was already impaired at admission. Twelve days after admission, she was transferred to our tertiary referral cancer hospital for further assessment. Upon arrival, after a prolonged fasting period, she was found to have profound hypoglycemia, high lactate levels, and metabolic acidosis (Table 1). She also had sinus tachycardia (heart rate 130/min), low blood pressure (104/64 mmHg), hyperventilation (respiratory rate 30/min), SpO₂ >90% (room air), and an axillary temperature of 36.7°C. Twenty mL glucose 50% bolus was administered immediately, followed by an infusion of glucose 10% at a rate of 200 mL/h. To treat the hypercalcemia, crystalloids, calcitonin (500 IU/24 hours, Miacalcic®, Essential Pharma, Surrey, UK), and glucocorticoids (dexamethasone 8 mg*4) were administered intravenously. A high urine output was

targeted with furosemide 10 mg/h. Daily glucose administration was approximately 300 g to maintain acceptable blood glucose levels. Lactate and calcium levels remained elevated throughout her hospital stay (Figure 1). Since thiamine deficiency may cause lactic acidosis (LA), thiamine 100 mg was administered twice daily empirically. Reinvestigation of earlier and new biopsies from axillary lymph nodes confirmed the diagnosis of squamous cell cervical cancer. Despite referral to a critical care unit, the negative clinical course could not be reversed. Because of her advanced stage of illness, chemotherapy was considered futile. Life-supporting therapy was therefore withdrawn, and the patient died 18 days after her first admission.

Postmortem autopsy revealed large masses of low differentiated squamous cell carcinoma filling the entire pelvis and invading the rectum and urinary bladder. In addition, peritoneal carcinomatosis and metastases to the lungs and both adrenal glands were found. No metastases were found in the brain, liver, or pancreas, but hepatic steatosis was indicated. Immunohistochemical examination with respect to insulin showed no evidence of insulin-positive tumor cells.

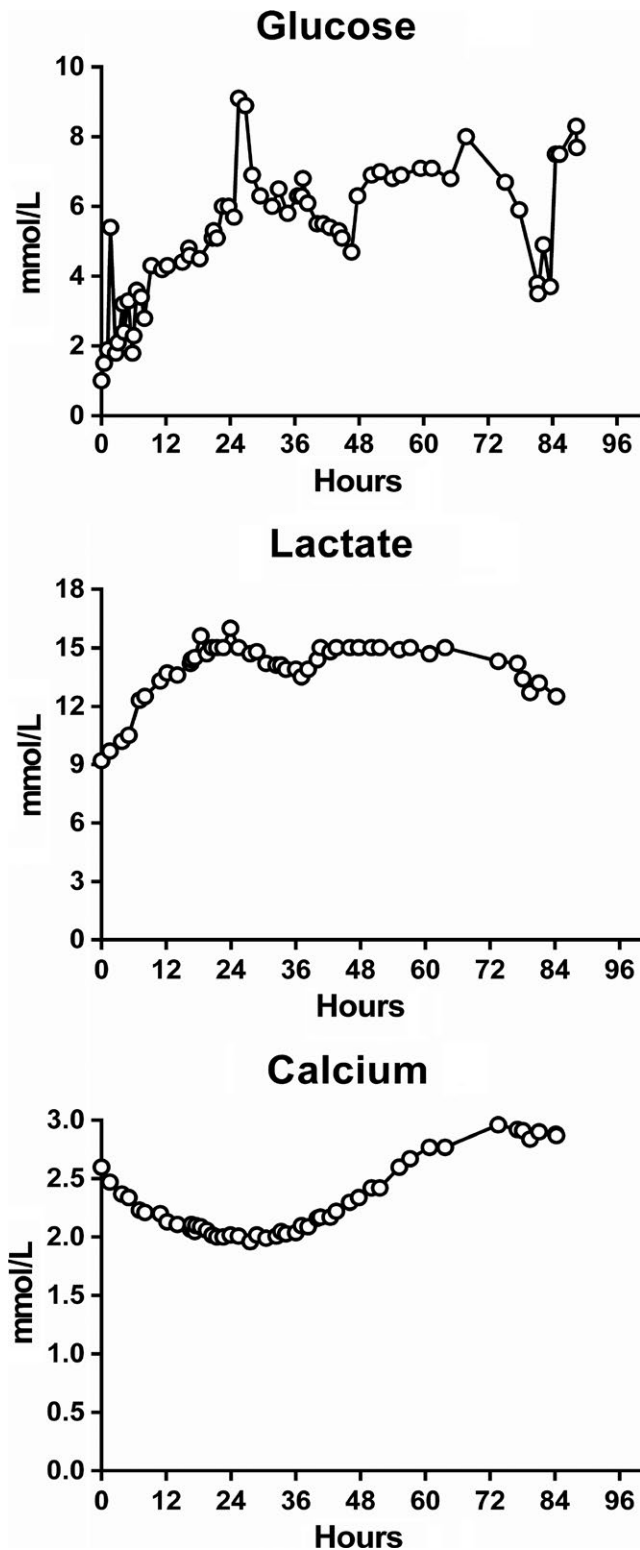


FIGURE 1 Biochemical analysis of blood-glucose, lactate, and ionized calcium

Postmortem serum analyses revealed normal values of insulin-like growth factor (IGF) 1, IGF-2, and pro-IGF-2, low bioactive IGF-2, and a high concentration of IGF-binding protein-2 (IGFBP-2) (Figure 1). Furthermore,

immunohistochemical analyses with anti-IGF-2 polyclonal rabbit antibodies (Abcam, Anti-IGF-2 antibody, ab9574) showed positive tumor cells, demonstrating the presence of IGF-2-producing cells in the primary tumor.

3 | DISCUSSION

To our knowledge, this is the first report of a patient with gynecological malignancy simultaneously presenting three different hormonal or metabolic abnormalities: hypoglycemia, elevated lactate/LA, and hypercalcemia. Our aim in presenting this case is to evaluate paraneoplastic syndrome, possible pathophysiological mechanisms, and diagnostic challenges. As such, we do not emphasize the important oncologic perspective.

3.1 | Hypoglycemia

Possible causes of persistent hypoglycemia in non-diabetics include drugs, alcohol, sepsis, liver failure, hormone deficiencies (adrenal insufficiency and hypopituitarism), and endogenous hyperinsulinemia. Tumor-induced hypoglycemia is usually related to insulin hypersecretion by a pancreatic islet tumor (insulinoma), but can also be caused by non-pancreatic tumors called non-islet-cell tumor hypoglycemia (NICTH).⁴ NICTH should always be considered when hypoglycemia occurs in patients with advanced malignancy,⁵ usually of mesenchymal, vascular, or epithelial cell types,⁶⁻⁸ and in patients with a large tumor burden. The most common cause of NICTH is an overproduction of IGF-2.⁹ Daughaday et al were the first to show that tumor-induced hypoglycemia is associated with an aberrant production of pro-IGF-2 (ie, big-IGF-2) resulting in insulin-like activity.¹⁰ Plasma concentrations of IGF-1 and IGF-2 can be 1000 times greater than insulin in NICTH.¹¹ High concentrations of IGF-1 or big-IGF-2 can cause hypoglycemia by binding to insulin-receptor, due to the homology between the IGF-2 and insulin molecules.

Non-insulin-dependent glucose uptake by the tumor, reflected in hyperlactacidemia, is often found in these cases and may also contribute to hypoglycemia.¹² The metabolic alterations caused by NICTH are reversible after surgical removal of the big-IGF-2-producing tumor,¹³ although metabolic disturbances usually relapse.^{12,14}

In the current case, neither the patient's liver enzymes, bilirubin, nor International Normalized Ratio were elevated, and she did not have any liver metastases. However, the moderate liver steatosis may have somewhat altered the hepatic capacity for glucose production. There was evidence of tumor infiltration and destruction from metastases to both adrenal glands and adrenal insufficiency with reduced cortisol production that may have led to hypoglycemia. Twenty-four

hours after admission, cortisol concentration was within the physiological range. The very low adrenocorticotrophic hormone at this time is usually a result of prior administration

of a high dose of intravenous dexamethasone (24 mg). This patient's surprisingly high cortisol level may have also been due to interferences of dexamethasone, or another unknown

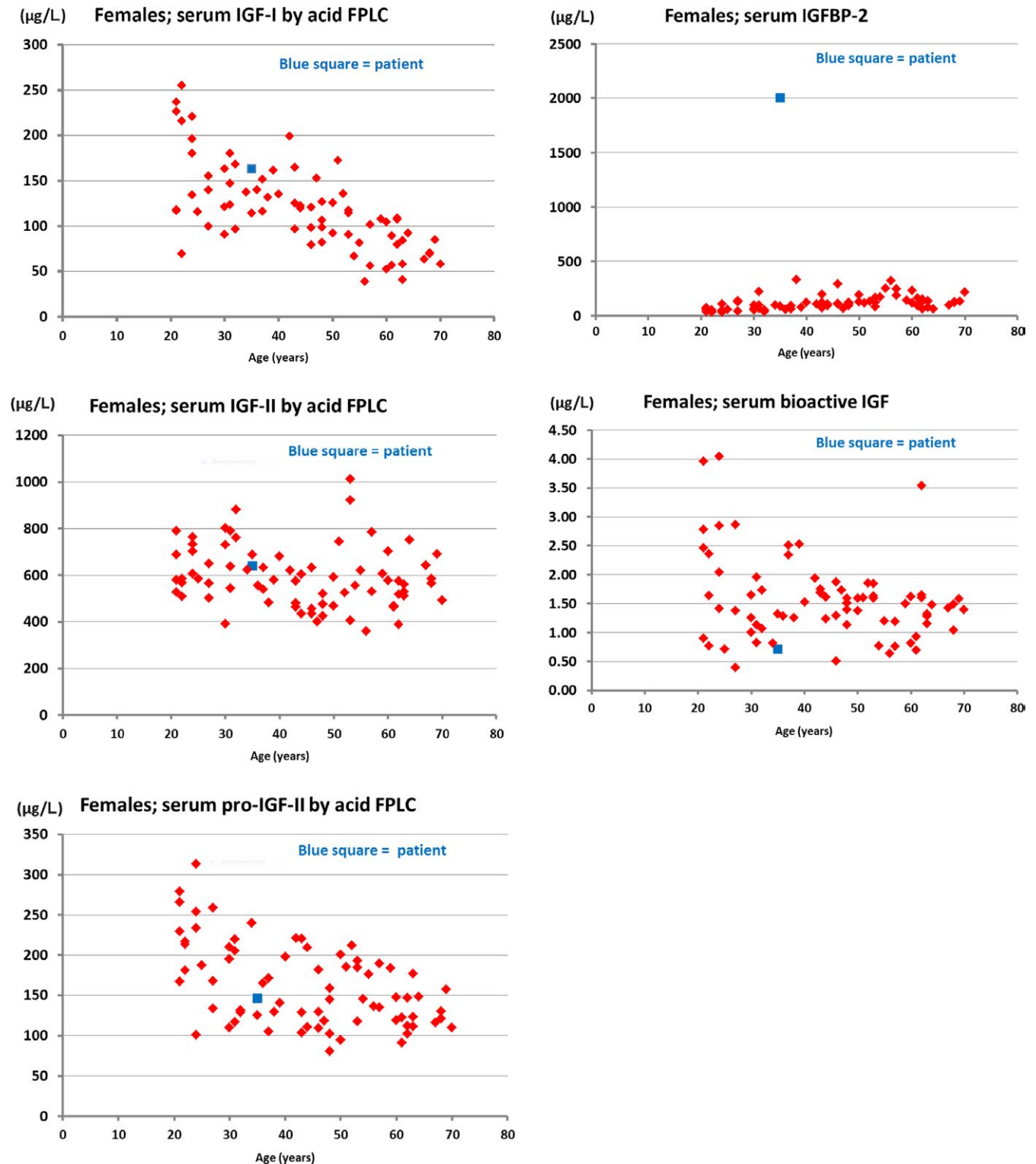


FIGURE 2 Data on serum levels of IGF-I, IGF-II, pro-IGF-II, IGFBP-2 and bioactive IGF. Normal reference values in red, patient measurements in blue. Very high levels of IGFBP-2 are seen in tumor-hypoglycemia, but also in other malignant diseases. Thus, an elevated serum IGFBP-2 is not diagnostic for tumor-hypoglycemia. Serum IGF-I is usually very low in patients with tumor-hypoglycemia and this is not the case in the present patient (Frystyk et al Diabetologia 1998)

interference, in the cortisol assay (Roche Diagnostics, 1st generation assay).

Unfortunately, relevant blood samples for hormone analysis were not collected at admission, when the patient had hypoglycemia, making the results more difficult to interpret. C-peptide, insulin, and proinsulin were measured 4 days after admission (approximately 7 hours before she died), and at that time, blood glucose was within the normal range (Figure 1). Insulin and especially C-peptide concentrations were very high, whereas proinsulin was low compared with insulin concentration. Such high levels of C-peptide may be due to hyperglycemia or insulin resistance. Additionally, increasing renal failure in the terminal phase may have contributed to the reduced clearance of C-peptide. Moreover, interference in the C-peptide assay (Roche diagnostics) cannot be entirely excluded.

Since blood tests were not collected while the patient was hypoglycemic, we cannot determine if there was endogenous insulin production; however, it is unlikely that the patient had insulinoma in addition to the primary cancer. No tumors were detected in the pancreas on the CT scan or autopsy, and immunohistochemical examination of the biopsies did not detect insulin-producing cells.

Typical findings in true cases of NICTH causing hypoglycemia include high IGF-2, and more frequently, high IGF-2 and low IGF-1, with an IGF-2/IGF-1 ratio $>10:1$.⁵ Our patient had normal concentrations of IGF-2 and pro-IGF-2, low bioactive IGF-2 and high IGFBP-2 (Figure 2). In addition, IGF1 was in the normal range. High levels of IGFBP-2 are seen in tumor-hypoglycemia, but also in other malignant diseases, thus an elevated serum IGFBP-2 is not diagnostic for tumor-hypoglycemia.¹⁵ Unfortunately, no samples were taken during hypoglycemia, which complicated the interpretation. In addition, samples were taken several days after starting high-dose steroid treatment, which may have attenuated the typical findings.

Steroids decrease and suppress big-IGF-2,^{7,12,16} and large doses may provide remarkable improvements in glucose homeostasis and other biochemical markers of IGF-2-producing tumors.^{17,18} This is probably the reason for such findings in our patient, for whom laboratory analyses of IGF-1 and IGF-2/big-IGF-2 were completed several hours after administration of steroids. However, immunohistochemical staining with anti-IGF-2 was positive, most likely proving the presence of IGF-2-producing cells in the primary tumor, which caused severe hypoglycemia (Figure 3).

IGFs are multifunctional peptides that play a pivotal role in cell regulation; they consist of IGF-1 and IGF-2, with three cell-membrane receptors and IGF-binding proteins. These factors can play an important paracrine/autocrine role in promoting tumor growth during tumor progression; however, these roles vary depending on the tissue origin.¹⁹⁻²¹ IGF-1 may also be a useful biomarker for assessing risk and early

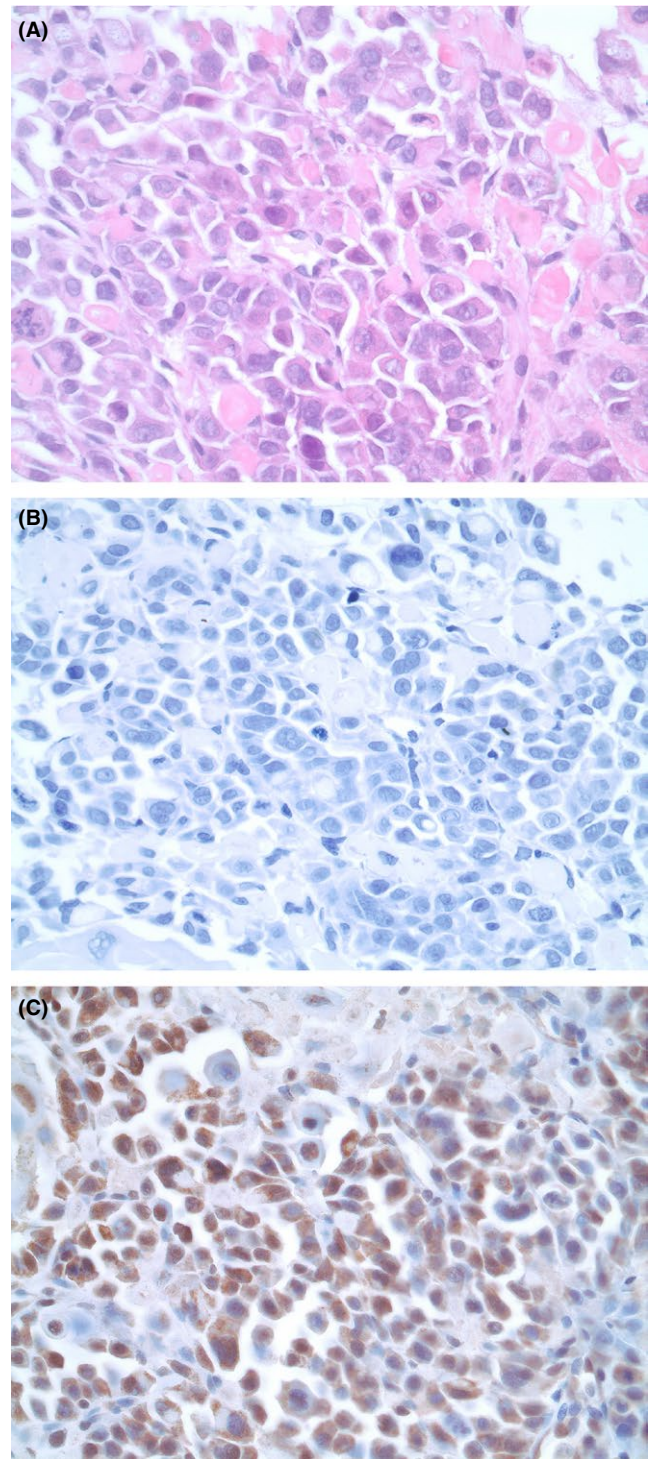


FIGURE 3 Biopsy from an axillary lymph node with metastasis of a poorly differentiated squamous cell carcinoma. A, Hematoxylin and eosin (H&E) staining, obj. $\times 40$. B, Immunohistochemical staining with anti-insulin antibody, obj. $\times 40$. The tumor cells are negative. C, Immunohistochemical staining with anti-IGF2 antibody, obj. $\times 40$. The tumor cells are positive (brown)

diagnosis of precancerous growth in the cervix,²² and IGF-2 may be a reliable marker for early diagnosis and the monitoring of therapy efficacy.²³

3.2 | Lactic acidosis (LA)

Hyperlactatemia is defined as a mild-to-moderate (2-4 mmol/L) increase in blood lactate concentration without metabolic acidosis, whereas LA is characterized by persistently increased blood lactate levels (usually >5 mmol/L) associated with metabolic acidosis. LA is divided into two subtypes: type A and B. Type A is due to tissue hypoxia, whereas type B occurs without any evidence of poor tissue perfusion or oxygenation.²⁴ However, LA can also be a rare complication in solid tumors, as first reported in acute leukemia by Field et al.²⁵ The mechanism behind this is incompletely understood and probably multifactorial, but may be partly explained by an enhanced aerobic glycolytic activity in cancer cells.²⁶ In contrast to normal tissue, cancer cells frequently develop a modified glucose metabolism (Warburg effect), whereby blood glucose consumed by the tumor cells is converted to lactate even in the presence of adequate oxygen.^{27,28} In our case, despite evidence of hepatic steatosis, liver failure could be biochemically excluded as a possible cause of tissue hypoperfusion because hypotension or sepsis was most likely not the case. LA type B implies a poor prognosis; in a review of 29 cases, 22 died within a few weeks after its detection,²⁶ and patients whose disease was not treated or who did not respond to chemotherapy died with active LA.²⁹ In our patient, administration of glucose suggested increased lactate production by the tumor.

3.3 | Hypercalcemia

All types of malignant neoplasms can cause hypercalcemia, which is divided into four types³⁰: (a) increased secretion of PTH-rP from tumor cells, (b) osteolytic activity of bone metastases, (c) hypercalcemia due to elevated secretion of vitamin D, and (d) ectopic secretion of PTH from the tumor.

Production of PTH-rP is a common cause of hypercalcemia and is the most common paraneoplastic endocrine syndrome.³¹ About 80% of patients with malignancy-associated hypercalcemia (MAH) have increased PTH-rP serum levels,³² and the high calcium levels are a result of the combined effects of PTH-rP on kidney and bone. Secretion of endogenous PTH is suppressed by PTH-rP-mediated hypercalcemia, as was the case in our patient. Clinical manifestations of hypercalcemia include nausea/vomiting, weakness, and altered mental status, and may provoke life-threatening arrhythmias when calcium levels exceed >4 mmol/L. When MAH occurs in patients with advanced cancer,³² life expectancy is poor; a case series found that median survival is only 30 days.³³

4 | CONCLUSION

The combination of hypoglycemia with LA and hypercalcemia is uncommon and, to our knowledge, has not been

previously reported in a patient with a solid gynecologic tumor. Exploring the mechanisms behind a paraneoplastic syndrome may be challenging. Methodical interpretation of laboratory findings and involvement of an interdisciplinary team of clinicians are both valuable. Since glucocorticoid therapy may alter the biochemical picture, we recommend postponing its administration until all necessary laboratory samples have been obtained.

ACKNOWLEDGMENTS

We thank Ingeborg Goverud for the immunohistochemically laboratory analysis of the tumor biopsies.

CONFLICT OF INTEREST

The authors declare that they have no competing interests.

AUTHORS' CONTRIBUTIONS

All authors contributed to writing and revising the manuscript. The authors are experienced anesthesiologists, endocrinologist and pathologists involved in the multidisciplinary management of cancer patients at the comprehensive cancer center of a large tertiary care university hospital.

CONSENT FOR PUBLICATION

A copy of the written consent is available for review by the journal editor.

AVAILABILITY OF DATA AND MATERIAL

Data are available in the hospital's medical records.

ORCID

John Hausken  <http://orcid.org/0000-0001-8012-4609>

REFERENCES

1. Pelosof LC, Gerber DE. Paraneoplastic syndromes: an approach to diagnosis and treatment. *Mayo Clin Proc.* 2010;85(9):838-854.
2. Paraschiv B, Diaconu CC, Toma CL, Bogdan MA. Paraneoplastic syndromes: the way to an early diagnosis of lung cancer. *Pneumologia.* 2015;64(2):14-19.
3. Viau M, Renaud MC, Grégoire J, Sebastianelli A, Plante M. Paraneoplastic syndromes associated with gynecological cancers: a systematic review. *Gynecol Oncol.* 2017;146(3):661-671.
4. Iglesias P, Diez JJ. Management of endocrine disease: a clinical update on tumor-induced hypoglycemia. *Eur J Endocrinol.* 2014;170(4):R147-R157.
5. Livingstone C. IGF2 and cancer. *Endocr Relat Cancer.* 2013;20(6):R321-R339.

6. Scott K. Non-islet cell tumor hypoglycemia. *J Pain Symptom Manage.* 2009;37(4):e1–e3.
7. Thomas J, Kumar SC. Nonislet cell tumor hypoglycemia. *Case Rep Endocrinol.* 2013;2013:308086.
8. Bodnar TW, Acevedo MJ, Pietropaolo M. Management of non-islet-cell tumor hypoglycemia: a clinical review. *J Clin Endocrinol Metab.* 2014;99(3):713-722.
9. Daughaday, WH. Insulin-like growth factors and tumour hypoglycaemia. In: Sheaves, R, Jenkins, PJ, Wass, JAH, eds. *Clinical Endocrine Oncology.* Oxford: Blackwell Science; 1997:496-501.
10. Daughaday WH, Kapadia M. Significance of abnormal serum binding of insulin-like growth factor II in the development of hypoglycemia in patients with non-islet-cell tumors. *Proc Natl Acad Sci USA.* 1989;86(17):6778-6782.
11. Baxter RC. The insulin-like growth factors and their binding proteins. *Comp Biochem Physiol B.* 1988;91(2):229-235.
12. Teale JD, Marks V. Glucocorticoid therapy suppresses abnormal secretion of big IGF-II by non-islet cell tumours inducing hypoglycaemia (NICTH). *Clin Endocrinol (Oxf).* 1998;49(4):491-498.
13. Daughaday WH, Emanuele MA, Brooks MH, Barbato AL, Kapadia M, Rotwein P. Synthesis and secretion of insulin-like growth factor II by a leiomyosarcoma with associated hypoglycemia. *N Engl J Med.* 1988;319(22):1434-1440.
14. Marks V, Teale J. Tumours producing hypoglycaemia. *Endocr Relat Cancer.* 1998;5:111-130.
15. Frystyk J, Skjaerbaek C, Zapf J, Orskov H. Increased levels of circulating free insulin-like growth factors in patients with non-islet cell tumour hypoglycaemia. *Diabetologia.* 1998;41(5):589-594.
16. Teale JD, Wark G. The effectiveness of different treatment options for non-islet cell tumour hypoglycaemia. *Clin Endocrinol (Oxf).* 2004;60(4):457-460.
17. Baxter RC, Holman SR, Corbould A, Stranks S, Ho PJ, Braund W. Regulation of the insulin-like growth factors and their binding proteins by glucocorticoid and growth hormone in nonislet cell tumor hypoglycemia. *J Clin Endocrinol Metab.* 1995;80(9):2700-2708.
18. Perros P, Simpson J, Innes JA, Teale JD, McKnight JA. Non-islet cell tumour-associated hypoglycaemia: 111In-octreotide imaging and efficacy of octreotide, growth hormone and glucocorticosteroids. *Clin Endocrinol (Oxf).* 1996;44(6):727-731.
19. Samani AA, Yakar S, LeRoith D, Brodt P. The role of the IGF system in cancer growth and metastasis: overview and recent insights. *Endocr Rev.* 2007;28(1):20-47.
20. Lee SW, Lee SY, Lee SR, Ju W, Kim SC. Plasma levels of insulin-like growth factor-1 and insulin-like growth factor binding protein-3 in women with cervical neoplasia. *J Gynecol Oncol.* 2010;21(3):174-180.
21. Durzynska J. IGF axis and other factors in HPV-related and HPV-unrelated carcinogenesis (review). *Oncol Rep.* 2014;32(6):2295-2306.
22. Wu X, Tortolero-Luna G, Zhao H, Phatak D, Spitz MR, Follen M. Serum levels of insulin-like growth factor I and risk of squamous intraepithelial lesions of the cervix. *Clin Cancer Res.* 2003;9(9):3356-3361.
23. Mathur SP, Mathur RS, Underwood PB, Kohler MF, Creasman WT. Circulating levels of insulin-like growth factor-II and IGF-binding protein 3 in cervical cancer. *Gynecol Oncol.* 2003;91(3):486-493.
24. Ruiz JP, Singh AK, Hart P. Type B lactic acidosis secondary to malignancy: case report, review of published cases, insights into pathogenesis, and prospects for therapy. *ScientificWorldJournal.* 2011;11:1316-1324.
25. Field M, Block J, Rall D. Lactic acidosis in acute leukemia. *Clin Res.* 1963;11:193-197.
26. Claudino WM, Dias A, Tse W, Sharma VR. Type B lactic acidosis: a rare but life threatening hematologic emergency. A case illustration and brief review. *Am J Blood Res.* 2015;5(1):25-29.
27. Vander Heiden MG, Cantley LC, Thompson CB. Understanding the Warburg effect: the metabolic requirements of cell proliferation. *Science.* 2009;324(5930):1029-1033.
28. De Groot R, Sprenger RA, Imholz AL, Gerding MN. Type B lactic acidosis in solid malignancies. *Neth J Med.* 2011;69(3):120-123.
29. Sillos EM, Shenep JL, Burghen GA, Pui CH, Behm FG, Sandlund JT. Lactic acidosis: a metabolic complication of hematologic malignancies: case report and review of the literature. *Cancer.* 2001;92(9):2237-2246.
30. Stewart AF. Hypercalcemia associated with cancer. *N Engl J Med.* 2005;352(4):373-379.
31. DeLellis RA, Xia L. Paraneoplastic endocrine syndromes: a review. *Endocr Pathol.* 2003;14(4):303-317.
32. Lumachi F, Brunello A, Roma A, Basso U. Medical treatment of malignancy-associated hypercalcemia. *Curr Med Chem.* 2008;15(4):415-421.
33. Ralston SH. Cancer-associated hypercalcemia: morbidity and mortality. Clinical experience in 126 treated patients. *Ann Intern Med.* 1990;112(7):499-504.

How to cite this article: Hausken J, Haave EM, Haugaa H, Løberg EM, Kongsgaard UE. A patient with solid gynecologic cancer causing lactic acidosis, severe hypercalcemia, and hypoglycemia. *Clin Case Rep.* 2019;7:64–70. <https://doi.org/10.1002/ccr3.1904>