

Restless arms syndrome: prevalence, impact, and management strategies

This article was published in the following Dove Press journal:
Neuropsychiatric Disease and Treatment

Elisabeth Ruppert¹⁻³

¹Sleep Disorders Center - CIRCSom, Department of Neurology, Hôpital Civil, 67091 Strasbourg, France; ²Faculty of Medicine, University of Strasbourg, 67000 Strasbourg, France; ³Institute for Cellular and Integrative Neurosciences, CNRS - UPR 3212, University of Strasbourg, 67000 Strasbourg, France

Abstract: This literature review focuses on restless arms syndrome (RAS), an upper limb variant of restless legs syndrome (RLS). RLS, also known as Willis-Ekbom disease, is a frequently occurring neurological disorder characterized by an irresistible urge to move the lower limbs often accompanied by unpleasant sensations in the legs, worsened at rest and in the evening, improved by movement. Extension of leg restlessness to the upper limbs is frequently reported in typical patients who had RLS only in the legs and usually occurs later in the course of RLS, restlessness remaining most invalidating in the lower limbs. In RAS, the arms are predominantly affected with little or no involvement of the legs. Cases of restless shoulders syndrome or periodic arm movements without arm restlessness were not considered. A total of 9 articles with 10 cases were included and analyzed for the adherence to the five essential diagnostic criteria of the International RLS Study Group (IRLSSG) classification, as well as for the additional supportive features. All of the reported cases were classified as having definite RAS. The clinical history and disease evolution of two previously reported patients were completed and updated. Overall, the clinical picture of RAS does not differ from that of RLS, except for the symptoms localization on the upper limbs. Underlying mechanisms of the spread of RLS to upper limb restlessness and of RAS remain unknown. Whether RAS is a phenotypic variant of RLS or a separate entity needs further investigations. RAS likely remains underdiagnosed and according to IRLSSG diagnostic criteria RAS should be considered when RLS-like symptoms are present in one or both arms, especially when they have a circadian pattern and are improved by movement and dopaminergic therapy. Clinicians should be aware of this rare condition, especially as treatment using dopaminergic agonists proves to be very efficient.

Keywords: RLS variant, RLS equivalent, restless upper limb, restlessness of upper extremities, Willis-Ekbom disease, periodic arm movements

Introduction

Restless legs syndrome (RLS) is a neurological disorder characterized by an irresistible urge to move the lower limbs often accompanied by unpleasant sensations in the legs, worsened at rest and in the evening. Symptoms are improved by movement.^{1,2} RLS, also known as Willis-Ekbom disease, was initially described by Thomas Willis in 1685.³ The term “restless legs syndrome” was introduced by Karl-Axel Ekbom and first formal diagnostic criteria were published in 1945.^{4,5}

Clinically significant RLS has a substantial negative impact on sleep with delayed sleep onset and/or sleep maintenance insomnia as well as on daytime functioning with complaints of fatigue, daytime sleepiness, reduced concentration, and depression.¹ RLS decreases the quality of life, is a debilitating affection in its severe forms and could rise the mortality.⁶

Correspondence: Elisabeth Ruppert
Centre des Troubles du Sommeil –
CIRCSom, Hôpital Civil, Place de l'Hôpital,
BP 426, Cedex, 67091 Strasbourg, France
Tel +33 38 811 6430
Fax +33 38 811 5153
Email elisabeth.ruppert@chru-strasbourg.fr

RLS prevalence was estimated at 9.4–15% of the occidental populations according to community-based surveys studying RLS as a symptom only.⁷ When frequency/severity criteria were added, prevalence ranged from 2.2% to 7.9% and when differential diagnosis was applied prevalence estimates were between 1.9% and 4.6%.⁷

Dopaminergic agonists have a clear therapeutic effect, but they can also cause augmentation syndrome aggravating symptoms severity due to higher dosages or a prolonged use.^{8,9} The pathophysiology of RLS remains overall elusive.¹⁰ We classically use to distinguish an idiopathic or primary form with early-onset and genetic predispositions from a secondary or symptomatic form.¹¹ The latter is commonly associated with iron deficiency,^{12,13} renal failure,¹⁴ or consequently to certain drugs such as neuroleptics and antidepressants (tricyclic or selective serotonin reuptake inhibitors).^{15,16} According to recent publications, overlapping genetic risk factors may play a role in primary (idiopathic) and secondary (symptomatic) RLS suggesting an inappropriate causal relation of this classification.¹⁷

The diagnosis of RLS is assessed by using purely clinical criteria. The cardinal criteria of the International RLS Study Group (IRLSSG) proposed in 2003 are based on the report of an urge to move legs (and arms) with or without unpleasant sensations, enhanced by rest, relieved by movement, and worsened in the evening or at night.¹¹ In the updated criteria, a fifth element was added with the occurrence of the above-mentioned features being not solely accounted for as symptoms primary to another medical or a behavioral condition in order to be more specific and exclude mimics.¹ Additional supportive features add to the accuracy of the diagnosis with the existence of excessive periodic leg movements (PLMs), a positive response to dopaminergic treatment, a family history of RLS and the lack of expected daytime sleepiness.¹ Lack of expected daytime sleepiness is a characteristic but counterintuitive finding in RLS patients. In moderate-to-severe RLS, patients have chronic short sleep times but generally do not report a level of daytime sleepiness that would be expected for the degree of sleep loss.¹ A slightly modified version of the diagnostic criteria has been published by the American Academy of Sleep Medicine (AASM) in their International Classification of Sleep Disorders (ICSD-3).²

Most patients with restless legs also suffer from PLMs, an extremely common disorder. These are episodes with involuntary, repetitive, and stereotyped limb movements during sleep or periods of wakefulness in the night. Movements are similar

to the Babinski response and consist in a characteristic dorsiflexion of the hallux, sometimes the movement extends with a dorsiflexion of the ankle and a partial flexion of the knee and the hip. PLMs may be associated with an arousal, causing sleep fragmentation and daytime sleepiness. Diagnostic criteria of PLMs are well established.^{2,18}

For a reliable diagnosis of each RLS, it is of importance that all five essential IRLSSG criteria are met,¹⁹ particularly in case of atypical localizations.

One of the problems of establishing the diagnosis of RLS is the explicit focus of the International Criteria on leg movements. Despite being called restless “legs” syndrome, RLS may also involve the arms or other body parts. Involvement of the upper extremities has been initially reported by Willis and later by Ekbom.^{3,4} Arm involvement is reported in 21–57% of cases when RLS symptoms are more severe, spreading to other body parts, but the legs must be affected.¹ Restless arms are mostly reported in case of augmentation syndrome which indicates earlier onset of symptoms and spreading of complaints within the limbs, including the arms. This can happen early or at any time during treatment as a response to dopaminergic treatment. The prevailing diagnostic criteria and the focus on the lower limbs make it difficult to diagnose RLS variants such as restless arms syndrome (RAS) with the arms affected predominantly and little or no involvement of the legs.^{20–28} RLS variants with involvement of other body parts than the limbs have been reported and in a recent literature review the authors analyzed 19 case reports of patients having “RLS” symptoms responding to the IRLSSG criteria but affecting exclusively the face (6/19), abdomen (6/19), genitalia (4/19), bladder (2/19), and lower back (1/19).²⁹

In this literature review, we focus on RAS solely.

Materials and methods

Publications on RAS were searched on PubMed, a service of the National Library of Medicine’s National Center for Biotechnology Information: <http://www.ncbi.nlm.nih.gov>. The following search terms were used: RAS, arm restlessness, upper limb restlessness, periodic arm movements (PAMs), and periodic movements of the upper limbs. Only articles published in English were considered.

This literature review focuses on cases with RAS and does not include other variants of upper limb restlessness such as restless shoulders syndrome. Case reports of patients with RLS extending to the upper limbs were not considered, nor were considered cases of patients having solely PAMs non-associated with RAS.

A total of 9 articles with 10 cases were included and analyzed for the adherence to the five essential diagnostic criteria of the IRLSSG classification, as well as for the additional supportive features. No diagnostic criterion specific for RAS exists. According to the updated IRLSSG criteria,¹ RAS was classified as an RLS variant rather than included in an expanded definition of RLS.

Results

RAS: literature review on existing cases

Nine articles with a total of 10 RAS case studies were included in this literature review.

Analyses for adherence to IRLSSG diagnostic and supportive criteria (Table 1)

All of the 10 cases were fulfilling the IRLSSG criteria except for symptoms being localized in the arms. In the updated IRLSSG criteria,¹ atypical cases of RLS including RAS are best classified as an RLS variant rather than being included in an expanded definition of RLS. The case study by Webb in 1979,²⁰ previous to the publication of the IRLSSG diagnostic criteria,¹¹ did not clearly state about the essential diagnostic criteria of worsening symptoms at rest. However, the author described that the urge to move was present only at night and returned a few minutes after moving one or both arms. He further wrote that the pattern continued until sleep intervened. Additionally, the author states having developed the interest in RLS because himself was that patient he reported of. Given this description the second essential criterium seems fulfilled.

The fifth essential criterium about symptoms not solely accounted for as symptoms primary to another medical or behavioral condition was added in the updated version of the IRLSSG criteria published in 2014.¹ This element was not clearly stated in any of the articles. As all of the case reports had detailed clinical information without any data other than RAS explaining symptoms, diagnosis seems specific and excludes mimics.

Among the supportive features, PLMs (supportive feature 1) were not reported in half of the patients, probably because no polysomnography had been performed.^{23,26,28} PLMs were present in the other five patients.^{21,22,24,25,27} Periodic movements were present in the upper limbs of patient number 7 with movements of repeated extension of the small finger and in patient number 9.^{25,27} Whether PLMs in the upper limbs had been characterized with electromyogram of the extensor carpi radialis (ECR) muscle in the other three patients was not reported.

The second supportive feature on dopaminergic treatment response was present in all of the 8 reported patients. In patient number 1 dopaminergic treatment might not have been tested as RAS was diagnosed retrospectively after symptoms had disappeared.²⁰ In patient number 4, RAS developed clearly under antipsychotic treatment with olanzapine and resumed with its withdrawal.²³ As neuroleptics might induce RLS through blockage of dopaminergic receptors,^{11,12} it is highly probable that dopamine was involved in the pathophysiology of RAS in patient number 4. Similarly, in patient number 10 the neuroleptic haloperidol, administered due to an initial diagnosis of hemichorea-hemiballismus, worsened symptoms while the introduction of levodopa markedly improved RAS.²⁸ In all other patients dopamine agonists had been used with ropinirole being very efficient in patient number 2,²¹ and pramipexole being reported to be efficient in the other patients.^{22,24–27}

A highly probable case of RLS was reported in the parental grandfather of patient number 4.²³ No positive family history of RLS (supportive feature 3) was present in four patients.^{21,25–27} Family history was not reported in the other five patients.^{20,22,24,28}

The last supportive feature with lack of profound daytime sleepiness had not been reported in any of the articles. During clinical follow-up, this item is nevertheless clearly present in patients number 7 and 9.^{25,27}

Characteristics of the reported cases (Table 2)

Of the ten reported RAS patients, two were women. Age at RAS onset was heterogeneous between 23 and 73 years and the reported diagnosis delay varied between 4 months and 25 years. Symptoms were bilateral in eight patients,^{20–25,27} and right-sided in two.^{26,28} Clinical symptoms accompanying the urge to move were described as “twitching and wiggling”,²¹ “burning and itching”,²² “tingling and prickling”,²³ “inner discomfort”,²⁴ “unpleasant”,²⁴ “cramp”,²⁴ “pins and needles”,²⁵ “tickling sensation deep inside the muscles”,²⁶ “electric shock sensations”,²⁷ “prickling and pain”.²⁸ In three patients the urge to move was associated with movements during wakefulness at rest “that were more athetoid than jerky or irregular”,²⁰ “myoclonic-like jerks”,²⁷ “irregular and coarse hyperkinetic movements”.²⁸

In one patient, RAS was drug-induced using olanzapine for chronic paranoid schizophrenia.²³ In patient number 10, right-sided RAS seems to be stroke-related due to a left thalamic infarction involving the posterolateral

Table 1 Reported cases restless arms syndrome and analyses for adherence to IRLSSG diagnostic and supportive criteria

Case number	Publication	Five essential diagnostic criteria					Additional features supporting diagnosis			
		1. Urge to move	2. Worse at rest	3. Relief by movements	4. Worse in the evening or night	5. Symptoms not solely accounted for/ by a medical/ behavioral condition	1. PLMs	2. Dopaminergic treatment response	3. Family history	4. Lack of profound daytime sleepiness
1	Webb, 1976; <i>JAMA</i> ²⁰	Y	n.r.	Y	Y	Y	n.r.	n.r.	n.r.	n.r.
2	Freedom et al, 2003; <i>Arch Neurol</i> ²¹	Y	Y	Y	Y	Y	Y	Y	N	n.r.
3	Horvath et al, 2008; <i>Lancet</i> ²²	Y	Y	Y	Y	Y	Y	Y	n.r.	n.r.
4	Konstantakopoulou et al, 2009; <i>J Clin Psychopharmacol</i> ²³	Y	Y	Y	Y	Y	n.r.	n.r.	Highly probable RLS grandfather	n.r.
5	Munhoz et al, 2012; <i>Clin Neurol Neurosurg. Case</i> ²⁴	Y	Y	Y	Y	Y	Y	Y	n.r.	n.r.
6	Munhoz et al, 2012; <i>Clin Neurol Neurosurg. Case</i> ²⁴	Y	Y	Y	Y	Y	n.r.	Y	n.r.	n.r.
7	Ruppert et al, 2012; <i>Mov disord</i> ²⁵	Y	Y	Y	Y	Y	Y	Y	N	Y
8	Gupta et al, 2013; <i>J Neurosci Rural Pract</i> ²⁶	Y	Y	Y	Y	Y	n.r.	Y	N	n.r.
9	Ruppert et al, 2015; <i>Neurology</i> ²⁷	Y	Y	Y	Y	Y	Y	Y	N	Y
10	Kim et al, 2017; <i>Acta Neurol Belg</i> ²⁸	Y	Y	Y	Y	Y	n.r.	Y	n.r.	n.r.

Abbreviations: Y, yes; N, no; n.r., not reported.

Table 2 Reported cases and characteristics of restless arms syndrome

Case #	Publication	Sex	Age at RAS onset	Diagnosis delay	Symptoms' localization	Clinical characteristics	Triggering factor/comorbidities	Impact on sleep/day-time functioning	Treatment efficiency	Symptoms' evolution
1	Webb, 1976; <i>JAMA</i> ²⁰	M	23	n.r.	Bilateral	"urge to move the arms in an aimless manner"; "movements were more athetoid than jerky or irregular"	Onset 6 months following spinal cord injury with complete paralysis below the fourth thoracic vertebra and persistent paresthesia in both legs	n.r.	n.r.	Symptoms gradually disappeared without recurrence for 23 years
2	Freedom et al, 2003; <i>Arch Neurol</i> ²¹	M	77	1 year	Bilateral; symmetric	"twitching and wiggling"	Possible beginning peripheral neuropathy; history of coronary artery disease with coronary bypass surgery; hiatal hernia; pulmonary tuberculosis in the past	Y	Ropinirole tramadol; clonazepam, gabapentin	Two years after RAS onset the restlessness had progressed to involve the legs
3	Horvath et al, 2008; <i>Lancet</i> ²²	M	39	25 years	Bilateral	"burning and itching"	Hay fever; asthma	Y	Pramipexole	Extension to daytime RAS
4	Konstantakopoulos et al, 2009; <i>J Clin Psychopharmacol</i> ²³	M	24	<1 week ?	Bilateral	"tingling and prickling"	Drug-induced (24 h following olanzapine introduction, but not with risperidone nor amlisupride); chronic paranoid schizophrenia	Y	n.r.	No recurrence after 3 months follow-up
5	Munhoz et al, 2012; <i>Clin Neurol Neurosurg. Case</i> ²⁴	M	47	7-months	Bilateral arms and lateral part of shoulders	"inner discomfort"	n.r.	n.r.	Pramipexole	Significantly improved using pramipexole after 30 months follow-up
6	Munhoz et al, 2012; <i>Clin Neurol Neurosurg. Case</i> 2 ²⁴	M	44	4-months	Bilateral; symmetric	"unpleasant" "cramp"	n.r.	Y	Pramipexole	Complete symptoms remission using pramipexole after 18 months follow-up
7	Ruppert et al, 2012; <i>Mov disord</i> ²⁵	F	35	5 years	Bilateral	"pins and needles"	Focal epilepsy controlled with oxcarbazepine; mild right hemiparesis with periventricular lesions resulting from perinatal complications	Y	Pramipexole and iron; tramadol	RAS extended 3.5 years later with minor discomfort in the legs; augmentation syndrome

(Continued)

Table 2 (Continued).

Case #	Publication	Sex	Age at RAS onset	Diagnosis delay	Symptoms' localization	Clinical characteristics	Triggering factor/comorbidities	Impact on sleep/day-time functioning	Treatment efficiency	Symptoms' evolution
8	Gupta et al, 2013; <i>J Neurosci Rural Pract</i> ²⁶	F	28	7-months	Right	"tickling sensation deep inside the muscles"	Bilateral cervical ribs; depression	Y	Pramipexole and iron; clonazepam and duloxetine	Depression appeared after RAS onset; almost complete regression of RAS at 3 weeks follow-up
9	Ruppert et al, 2015; <i>Neurology</i> ²⁷	M	73	<2 years	Bilateral	"electric shock sensations and myoclonic-like jerks"	Hypertension; obstructive sleep apnea syndrome efficiently treated using CPAP; non-evolutionary monoclonal IGA Kappa pic; vitiligo; chronic, moderate, bilateral compressions of the ulnar nerves at the level of the elbows, as well as the median nerves at the carpal tunnel, treated surgically in the past with normal neurological examination and the patient had noticed no relationship between restlessness severity and the evolution of these comorbidities; spinal stenosis C3-7 without signs of compression, minor left antero-lateral pontine hypersignal more likely of vascular origin and an état criblé in both insula and lentiform nuclei revealed by cervical and brain MRI	Y	Piribedil; ropinirole; pramipexole; rodotigotine; gabapentin; pregabalin; clonazepam; tramadol; oxycodone; fentanyl	RAS was preceded about 8 years earlier by transient RLS with no need for specific medication; augmentation syndrome
10	Kim et al, 2017; <i>Acta Neurol Belg</i> ²⁸	M	65	10 days after discharge post-stroke hospitalization	Right, predominant on the proximal part of the arm	"prickling and pain with irregular and coarse hyperkinetic movements"	Stroke-related after left thalamic infarction involving the posterolateral nucleus with mild hemiparesis and dysesthesia on the right side, predominantly on the upper extremity, no neurological deficits were observed on discharge	n.r	Levodopa improved symptoms previously worsened using haloperidol	n.r.

Abbreviations: F, female; M, male; Y, yes; N, no; n.r., not reported.

nucleus.²⁸ In patient number 1, RAS seems to have been triggered by a spinal cord injury with complete paralysis below the fourth thoracic vertebra and persistent paresthesia in both legs. Spinal trauma had preceded RAS for 6 months and symptoms gradually disappeared without recurrence for 23 years.²⁰ Patient number 7 had a bilateral RAS in a context of focal epilepsy and mild right hemiparesis with periventricular lesions resulting from perinatal complications.²⁵ Patient number 9 had very severe RAS with onset at the age of 73 years in a context of hypertension; obstructive sleep apnea syndrome efficiently treated using CPAP; non-evolutionary monoclonal IGA Kappa pic; vitiligo. Neurologically, he had chronic, moderate, bilateral compressions of the ulnar nerves at the level of the elbows, as well as the median nerves at the carpal tunnel, treated surgically in the past with normal neurological examination. The patient had noticed no relationship between restlessness severity and the evolution of these comorbidities. A spinal stenosis C3-7 without signs of compression was diagnosed using cervical MRI. Brain MRI revealed a minor left anterolateral pontine hypersignal more likely of vascular origin, as well as an *état criblé* in both insula and lentiform nuclei.²⁷ Patient number 2 had a possible beginning peripheral neuropathy, coronary heart disease, and pulmonary tuberculosis diagnosis in the past.²¹ No neurological comorbidities were described in the other patients.

Impact and management strategies of RAS

Impact of RAS on sleep and daytime functioning was not reported in three patients.^{20,24,28} All other patients had symptoms with mainly sleep onset and maintenance insomnia, loss of sleep, non-refreshing sleep, daytime sleepiness, and fatigue.²¹⁻²⁷ Suicidal thoughts were present in patient number 9 when symptoms severity were at worse.²⁷ Patient number 8 had developed depression following RAS onset.²⁶

Dopaminergic treatment was efficient in all eight reported patients. In two patients administration of iron supplementation was used,^{25,26} and treatment with tramadol improved three patients.^{21,25,27} Gabapentin was efficient in two patients,^{21,27} and clonazepam was reported in three patients.^{21,26,27} Augmentation syndrome was observed in two patients.^{25,26}

In patients number 1 and 4, RAS resumed with no specific RLS medication.^{20,23} Follow-up showed in most cases either a complete or a partial regression of symptoms under treatment. In patient number 2 restlessness extended

to the lower limbs 2 years after RAS onset,²¹ and in patient number 3 symptoms extended to daytime RAS.²¹ Extension to the legs with minor discomfort was present in patient number 7 in case of augmentation syndrome,²⁵ as well as exceptionally in patient number 9.²⁷

Clinical history and disease evolution of previously reported patients

In this section, supplementary information is given regarding two of the previously reported cases.^{25,27}

Patient number 7²⁵

A 40-year-old female patient complained of paraesthesia in the upper limbs that had appeared 5 years earlier during a clonazepam withdrawal. She had the status of well-controlled focal epilepsy (oxcarbazepine 600 mg/d) with periventricular lesions due to perinatal complications; psychogenic non-epileptic seizures and by-pass surgery with BMI at 35 kg/m².

Her main complaint concerned major upper limb discomfort and poor sleep quality. She suffered from pins and needles in her arms, predominantly distal, causing a severe discomfort that was transiently relieved by the urge to move her limbs and by walking. These symptoms appeared at rest and evolved with a striking circadian rhythmicity, fulfilling the criteria for RAS. Given sleep onset and maintenance insomnia, she had loss of sleep but lack of expected daytime sleepiness. Her sleep was unrefreshing impacting daytime functioning with fatigue and reduced concentration. Symptoms remained isolated on the upper limbs for 3.5 years before extending to the lower limbs, causing minor discomfort, in case of augmentation syndrome. The patient noted an important relief after treatment with iron and the dopaminergic agonist pramipexole 0.27 mg/d. Insomnia with delayed sleep onset and nocturnal awakenings due to upper limb discomfort was ameliorated, but the patient continued complaining of unrefreshing sleep. PLMs were suspected in the patient and videopolysomnography (vPSG) was performed. An electromyogram was added on the ECR muscle as periodic movements of the upper limbs were suspected in this patient with arm restlessness.³⁰

With the patient's consent and in order to better characterize the efficiency of dopaminergic agonist treatment, we realized 1) a first night vPSG with the habitual dosage of 0.27 mg pramipexole (Figure 1A), 2) followed by an abrupt drug withdrawal on the second night causing very severe sleep onset and maintenance insomnia with sleep

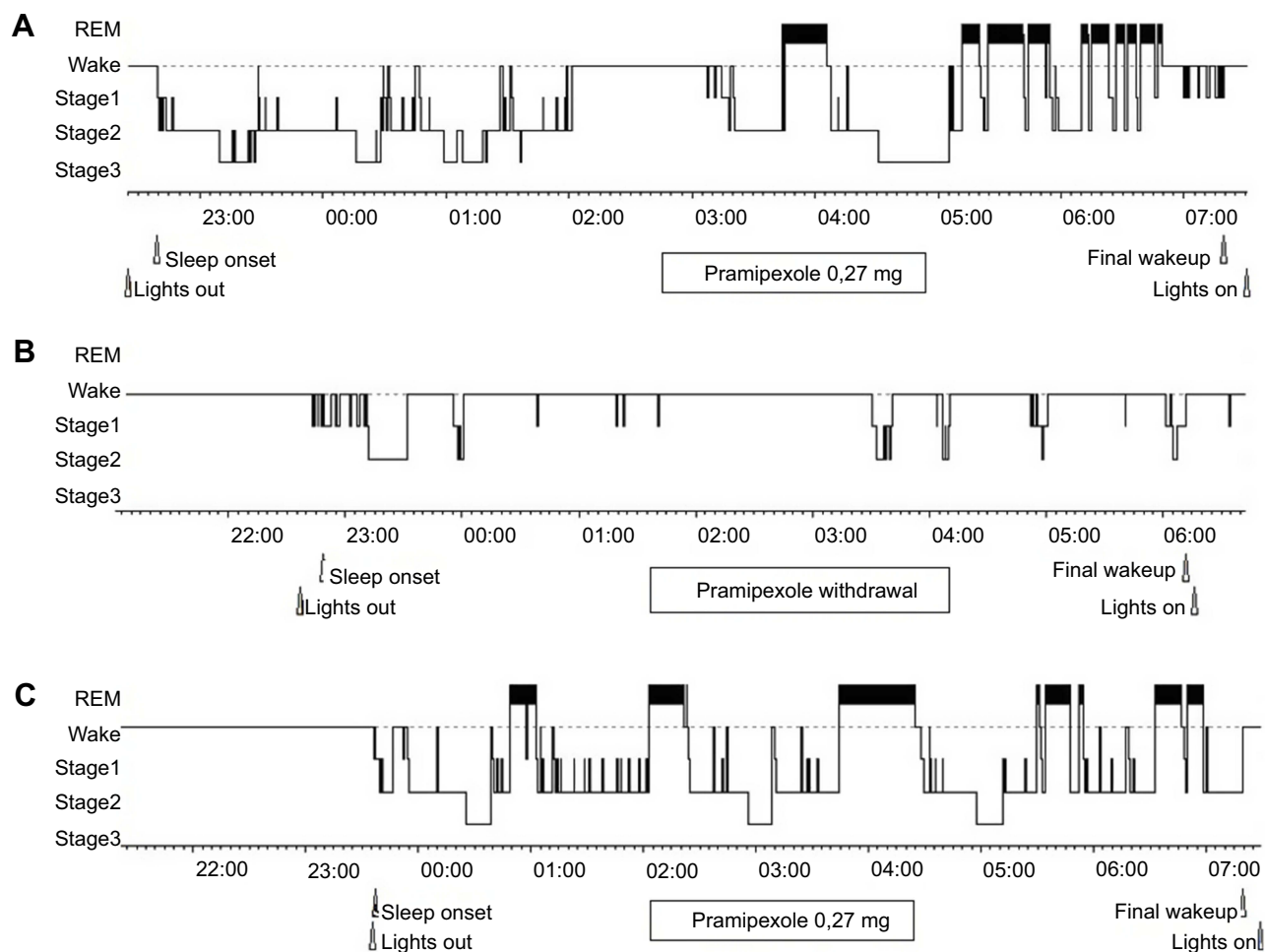


Figure 1 Dopaminergic treatment response in patient number 7. Hypnograms of patient number 7 having vPSGs with a first night under the habitual dosage of 0.27 mg pramipexole (A), followed by vPSG on the second night after an abrupt drug withdrawal causing very severe sleep onset and maintenance insomnia with sleep loss due to a major rebound of restlessness (B) and a third night of vPSG after reintroduction of pramipexole 0.27 mg relieving symptoms and permitting the patient to recover sleep (C).

Abbreviation: vPSG, videopolysomnography

loss due to a major rebound of restlessness evaluated 38/40 at the IRLS severity scale (Figure 1B) and 3) reintroduced pramipexole 0.27 mg on the third night relieving symptoms and permitting the patient to recover sleep (Figure 1C). The patient had daytime naps following the second night explaining the slightly delayed sleep onset and absence of profound sleep rebound. (Figure 1)

Videography showed periodic movements with repeated extension of the little finger occurring during periods of wakefulness in the night and during sleep. Electromyographic activity of the ECR fulfills the AASM criteria for periodic limb movement disorder, apart from their localization.³¹ No sleep disordered breathing was observed.

After 8 years of follow-up, RAS was still relieved using pramipexole 0.18 to 0.27 mg/d. At higher dosages, the patient experiences augmentation syndrome with the

need to instore tramadol and taper off pramipexole. No change in RAS severity was observed related to menopause.

Patient number 9²⁷

A 73-year-old patient complained of myoclonic-like jerks in both forearms associated with sensations described as “aggressive, painful and hard” occurring only close to bedtime and causing severe insomnia. He had videotaped himself while shaking and scratching his arms, and as soon as he stopped moving, myoclonic-like jerks appeared on the upper limbs. He seemed exhausted.

Symptoms began to appear progressively starting at age 68, becoming severe at age 71. They occurred only at rest and were debilitating at around bedtime. The patient described discomfort in both forearms, spreading to the wrists and arms, and exceptionally to the lower limbs with

minor discomfort as compared to the upper limbs. Due to the irresistible urge to move, he was often ambulating during the evening or at night, shaking or massaging his upper limbs for hours. Occasionally, showering with cold water also gave him some relief. Symptoms evolved with a striking circadian rhythmicity, fulfilling the criteria for RLS, apart from their localization on the upper limbs.¹ Diagnosis of RAS, an upper limb variant of RLS, was done by the patient's general practitioner as symptoms severity became important.

Paresthesia was associated with myoclonic-like jerks, characterized by the patient as "electric shocks", causing severe sleep-onset and sleep-maintenance insomnia. These involuntary flexion movements of the arms appeared as the patient's upper limbs were at rest. They were synchronous or asynchronous, repetitive, separated by several seconds, and evocative of a periodic arm movement disorder during wakefulness.

Symptoms severity fluctuated depending on the night, with periods of several weeks described as "crises" or "partial relief". No factors could be identified to explain this capricious evolution, even though coffee and white wine consumption sometimes could exacerbate RAS severity, as well as when the patient did intense exercise using his arms, eg, driving a tractor during the day. As symptoms worsened over the years, the patient suffered psychologically and reported suicidal thoughts when arm restlessness was at its worse. Sleep quality was poor with sleep loss, fatigue, reduced concentration but lack of expected daytime sleepiness.

No family history of RLS was known. At around age 60, the patient had a short period with minor and transient RLS. No specific medication had been needed.

Dopaminergic agonists transiently relieved RAS (piribedil, ropinirole, pramipexole, rotigotine),⁸ but several weeks or days after treatment onset, symptoms would intensify leading to an augmentation syndrome.⁹ Similarly, clobazam, gabapentin, and pregabalin temporarily alleviated restlessness, yet without lasting improvement. It remains unclear whether the patient had augmentation syndrome with these non-dopaminergic drugs. Finally, tramadol, administered daily at 75 mg, proved to be the most efficient for the patient, as well as fentanyl 2.1 mg daily or oxycodone 5 mg/d during periods of crises.

Further diagnosis indicated hypertension and severe obstructive sleep apnea syndrome efficiently treated with continuous positive airway pressure (CPAP). He was followed-up for a non-evolutionary monoclonal IGA Kappa

pic and vitiligo. Neurological examination was normal. Biological assessment of the patient's body iron status showed no deficiency with ferritin at 151 µg/L (N: 58–319). The patient was also followed-up for chronic, moderate, bilateral compressions of the ulnar nerves at the level of the elbows, as well as the median nerves at the carpal tunnel, treated surgically in the past. At the time, these nerve compressions were clinically asymptomatic. The patient noticed no relationship between RAS severity and the evolution of these comorbidities. Further investigations included cervical MRI revealing spinal stenosis C3-7 without any signs of compression. Brain MRI showed a minor left anterolateral pontine hypersignal more likely of vascular origin and an *état criblé* in both insula and lentiform nuclei.

Video-polysomnographic monitoring with CPAP was performed and scored manually. The patient had decreased amounts of slow wave sleep and his sleep was highly fragmented (arousal index 54.73/h), mainly due to typical PLMs (PLMs index 55.16/h). He spent 73 mins at night having severe restlessness in his arms and PAMs during wakefulness.

During the first years of follow-up, RAS severity remained very severe and only partially relieved using different treatment adjustments including oxycodone 10 mg/d, clobazam 1.5 mg/d and exceptionally associated with transdermal lidocaine. At around age 78, RAS became less severe and long-term treatment could be interrupted. Solely oxycodone diminished to 2.5 mg/d was taken in case of RAS exacerbation. During the same period, the patient had developed invalidating age-related macular degeneration.

Discussion

Prevalence of RAS

The present literature review focuses on RAS as defined by restlessness limited to the upper limbs. However, in some patients symptoms could extend to restlessness in the legs.^{21,25,27} Only 10 patients responding to these criteria have been reported so far in the literature by eight different teams suggesting that RAS might be an extremely rare condition. However, prevalence of RAS remains largely unknown. The long time-delay (up to 25 years) between the onset of symptoms and RAS diagnosis probably reflects the diagnostic difficulties related to the atypical topography. RAS is possibly underdiagnosed, especially in milder and transient forms. Further, there might be

a publication bias with a predominance of more atypical forms being published including possibly comorbidity-triggered RAS,^{20,23,25,27,28} particularly severe RAS,²⁷ or the presence of misleading symptoms such as itching.²² The first reported patient was a 23-year-old medical student with post-injury RAS and a spontaneously favorable evolution without relapse over 23 years.²⁰ At times, the author states that there was the concern that symptoms were the beginning of a neurological disease or even a psychosis. The author concludes his letter to the editor with the words “I developed the interest in this strange condition because I was that medical student”. Most probably, this early and interesting case observation would not have been published if the author had not been the patient and been able to diagnose RAS himself.

Reported RAS cases were fulfilling the IRLSSG diagnostic criteria apart from the localization of symptoms on the upper limbs

Even though the second essential criterium was not clearly stated in the first included case description from 1976, prior to the initial publication of the IRLSSG criteria,¹¹ the detailed clinical observation allowed to deduce that this element was present. Similarly, the fifth essential criteria added in the updated IRLSSG version was missing in all of the reported cases.¹ As no other medical or behavioral condition than RAS explaining the symptoms were present in the exhaustive case descriptions, it was concluded that diagnosis was specific to RAS and mimics excluded. It is unclear whether the presence or absence of supportive features had been systematically checked explaining missing data, all the more as publication of the supplemental features were posterior to most case reports.¹

PLMs were present in 5/10 RAS patients. This supplemental element is poorly specific to RLS, as PLMs are not necessarily associated to RLS.^{2,32} Likewise, PAMs have been recorded in patients without RLS or RAS.³³ Periodic movements in the upper limbs have been present in 15 of 22 patients with RLS in a study by Chabli et al³⁰. Only one case description found PAMs with a repeated extension of the small finger.²⁵ Further characterization of PAMs is needed, especially in RAS patients. This literature review did not include patients with isolated PAMs, unrelated to restlessness in the arms.³⁴

A positive response of symptoms regarding the dopaminergic system was present in all patients, except the one

from Webb which had a diagnosis delay of several years following transient RAS.²⁰ RAS was either relieved using dopaminergic agonists/levodopa or drug-induced/aggravated by neuroleptics blocking the dopaminergic system. Apart from the particular situation of Parkinson's disease where restlessness can be related to wearing off phenomenon,³⁵ sensitivity of restlessness to dopamine is a specific marker for RLS and its phenotypic variants.¹ The presence of this supplemental feature is of importance, especially in atypical forms.

RLS is frequently present in families of patients with an early disease onset, also called idiopathic or primary RLS. Only one patient had a grandparent with probable RLS.²³ No patient had positive family history of RLS in first-degree relatives. This might be linked to either a more elderly population, late-onset RLS patients have less family history, or to the presence of a high percentage of patients with probably comorbidity-triggered RAS. Furthermore, family history was unreported in about half of the patients, possibly due to underrecognition of the disease.

Lack of profound daytime sleepiness is a very relevant clinical feature. However, it is particularly difficult to objectify this symptom as most patients with severe RLS describe unrefreshing sleep with daytime fatigue and sleepiness. This might explain the important missing data regarding this supportive feature.

RAS and RLS share same clinical characteristics

As for RLS, RAS was reported in both genders women and men. Large population studies show that RLS affects more frequently women,⁷ whereas RAS was reported in two women and in eight men. Similarly, to RLS, age at RAS onset was heterogeneous and varied between 23 and 73 years. The urge to move was accompanied in some patients by more atypical symptoms such as “burning and itching” or painful “electric shock sensations”.^{22,27} These symptoms could be misleading, but have also been described in a large cohort of RLS patients.^{36,37} In some patients periodic movements of the upper limbs were present during wakefulness at rest, similarly to PLMs during wakefulness observed in RLS patients.² Symptoms of RAS were bilateral, except for two patients having a right-sided RAS.^{26,28} RLS typically involves symptoms in both legs but not necessarily at the same time or symmetrically.¹ Purely unilateral symptoms only in one leg occur with RLS and in some cases may relate to unilateral neurological conditions.^{1,38} Poststroke RAS was described in

one patient developing right-sided RAS following left thalamic infarction.²⁸ Stroke-related RLS has been described previously.^{39–44} In several patients, RAS was possibly triggered by comorbidities raising the question of secondary RAS. Symptomatic forms of RLS have been suggested in numerous medical conditions with sometimes controversial results from different studies.¹⁷ The frequency of RLS increases substantially if at least three medical comorbidities, such as cardiovascular disease, diabetes, arterial hypertension, or depression, are present.⁴⁵ Neuroleptics induced RAS in one patient and exacerbated symptoms in another.^{23,28} Different drugs, mainly neuroleptics, antidepressants, and anesthetics have been described to exacerbate preexisting RLS or induce secondary RLS.^{16,46–48} The differential diagnosis of akathisia in the patient with olanzapine-induced RAS was not considered as motor symptoms were initiated by dysesthesias with urge to move.²³ Akathisia is a common and very distressing movement disorder associated with antipsychotic drugs.⁴⁹ The syndrome consists of a subjective feeling of inner restlessness and an urge to move, as well as objective components traducing this inner restlessness, eg, rocking while standing or sitting, lifting feet as if marching on the spot and crossing and uncrossing the legs while sitting. In akathisia, symptoms do not worsen specifically at night and limb movements do not provide, even temporarily, relief from the irresistible urge to move them.^{50,51} Some of the patients' quotations (eg, "inner discomfort";²⁴ "electric shock sensations";²⁷ "prickling and pain"²⁸) are spelling out the very fitting parallels between RAS/RLS and akathisia. Akathisia is a potential differential diagnosis for RLS.⁵² No clear data exist on the prevalence of akathisia in general medical settings. A recent large study among a community sample of patients with the mental health condition schizophrenia on several psychotropic medications found a prevalence of about 15–35%.⁵³ Unfortunately, akathisia often goes unrecognized.

RAS management strategies and impact are comparable to those of RLS

Similarly to RLS, RAS patients benefitted from dopaminergic treatment, complementation of iron deficiency, treatment of coexisting obstructive sleep apnea and good sleep hygiene. Alpha 2 delta ligands and opioids might also be efficient in RAS.⁸

Impact of RAS on sleep and daytime functioning was important and present in most patients. As for RLS, some RAS patients developed depression and suicidal thoughts when symptoms were severe.¹⁵ A substantial negative impact

of RLS on quality of life and health has been described in RLS, but had not been evaluated in RAS patients.¹

Overall, the clinical picture of RAS seems not differ from that of RLS, except for the localization of the symptoms on the upper limbs. However, RAS patients had less family history as compared to idiopathic RLS and genetic risk factors of RAS are unknown. Large sample studies including long-term follow-up of RAS patients are needed.

RAS and other phenotypic variants of RLS

Restless arms due to an extension to the upper limbs are commonly observed in severe RLS patients, especially in case of augmentation syndrome.⁹ Arm involvement is reported in 21–57% of cases.¹ Usually restlessness in the upper extremities appears later in the course of typical patients who had RLS only in the legs. In this situation, restlessness remains most invalidating in the lower limbs with a milder discomfort in the arms as compared to the legs. However, symptoms severity can be predominant on the upper limbs in exceptional cases of RLS extension to the arms.^{48,54} Rare cases of restlessness limited to the shoulders have been described.⁵⁵ This literature review focuses on RAS limited to the upper limbs with a possible extension to the lower limbs in some patients. It remains unknown whether a continuum exists from RLS limited to the lower limbs, RLS extending to the upper limbs, RAS extending to the lower limbs, and RAS limited to the upper limbs. Specific underlying mechanisms of the spread of RLS to restlessness in the upper limbs and of RAS have not yet been identified. It remains hypothetic whether in RAS cervical spinal segments might be involved rather than lumbar segments.

Other studies have reported RLS sensations in the abdominal region, groin and genital areas, buttocks, back, chest, neck, and face.^{29,56,57} In a recent literature review on atypical RLS excluding limbs, a definitive RLS according to IRLSSG criteria was diagnosed in 7/19 reported patients with restlessness in the face (2/7), back (1/7), abdomen (2/7), bladder (0/7) and genitalia (2/7). These cases were assumed to be RLS equivalents.²⁹ Patients with restless abdomen, a variant of RLS, were reported to be homozygous for the most common RLS/PLMS-associated risk allele in the BTBD9 gene.⁵⁸ No data about genetics in RAS have been reported. Turini et al further discussed the relationship between RLS and burning mouth syndrome as well as restless genital syndrome. A hormonal pathogenic substrate was suggested in these atypical forms.²⁹ It remains unknown whether RAS, other RLS variants, and RLS are part of a same entity and share

common pathophysiological mechanisms, or whether their underlying neural substrates differ.

Peripheral neuropathy could be implicated in the pathophysiological process of RLS.^{59,60} In that case nerve damage with irritation of peripheral nerves could result in any kind of isolated restlessness in patients probably genetically predisposed. The IRLSSG felt, in its updated version, that rare atypical cases of RLS affecting predominantly the arms with little or no involvement of the legs and responding to dopaminergic treatment appear to be a variant of RLS and did not include them in an expanded definition of RLS.¹ These atypical cases need to be further investigated in order to clarify whether they are phenotypic variants of RLS or separate entities.

Conclusions

The upper limb variant of RLS likely remains underdiagnosed. According to IRLSSG diagnostic criteria, RAS should be considered when RLS-like symptoms are present in one or both arms, especially when they have a circadian pattern and are improved by movement and dopaminergic therapy. However, careful differential diagnosis and ruling out of another medical or behavioral condition are needed in order to be specific and exclude mimics. RLS and RAS seem to share same clinical characteristics and patient care seems overall comparable. Clinicians should be aware of this rare condition, especially as treatment using dopaminergic agonists proves to be very efficient. Given the limited number of reported cases, larger sample size studies are needed for better characterizing RAS. Further explorations of symptom evolution and differential diagnoses of RLS and its variants are needed for a more holistically approach and prevent compartmentalization.^{17,29}

Abbreviations list

AASM, American Academy of Sleep Medicine; CPAP, continuous positive airway pressure; ECR, extensor carpi radialis muscle; ICSD-3, International Classification of Sleep Disorders; IRLSSG, International RLS Study Group; PLMs, periodic leg movements; RAS, restless arms syndrome; RLS, restless legs syndrome; vPSG, videopolysomnography.

Funding

This paper did not benefit from any sources of funding.

Disclosure

The author reports no conflicts of interest in this work.

References

- Allen RP, Picchietti DL, Garcia-Borreguero D, et al. Restless legs syndrome/Willis-Ekbom disease diagnostic criteria: updated International Restless Legs Syndrome Study Group (IRLSSG) consensus criteria—history, rationale, description, and significance. *Sleep Med.* 2014;15(8):860–873. doi:10.1016/j.sleep.2014.03.025
- American Academy of Sleep Medicine (AASM). *The International Classification of Sleep Disorders: Diagnostic & Coding Manual (ICSD-3)*. 3rd ed. Darien (IL): American Academy of Sleep Medicine; 2014.
- Willis T. *The London Practice of Physic*. London: Basset & Crook; 1685.
- Ekbom KA. Restless legs: clinical study. *Acta Med Scand.* 1945;158 (Suppl.):1–123.
- Ekbom KA. Restless legs syndrome. *Neurology.* 1960;10:868–873. doi:10.1212/WNL.10.9.868
- Li Y, Wang W, Winkelmann JW, Malhotra A, Ma J, Gao X. Prospective study of restless legs syndrome and mortality among men. *Neurology.* 2013;81(1):52–59. doi:10.1212/WNL.0b013e318297eee0
- Ohayon MM, O'Hara R, Vitiello MV. Epidemiology of restless legs syndrome: a synthesis of the literature. *Sleep Med Rev.* 2012;16 (4):283–295. doi:10.1016/j.smrv.2011.05.002
- Garcia-Borreguero D, Silber MH, Winkelmann JW, et al. Guidelines for the first-line treatment of restless legs syndrome/Willis-Ekbom disease, prevention and treatment of dopaminergic augmentation: a combined task force of the IRLSSG, EURLSSG, and the RLS-foundation. *Sleep Med.* 2016;21:1–11. doi:10.1016/j.sleep.2016.01.017
- García-Borreguero D, Williams A-M. Dopaminergic augmentation of restless legs syndrome. *Sleep Med Rev.* 2010;14(5):339–346. doi:10.1016/j.smrv.2009.11.006
- Trenkwalder C, Allen R, Högl B, et al. Comorbidities, treatment, and pathophysiology in restless legs syndrome. *Lancet Neurol.* 2018;17 (11):994–1005. doi:10.1016/S1474-4422(18)30311-9
- Allen RP, Picchietti D, Hening WA, Trenkwalder C, Walters AS, Montplaisi J. Restless legs syndrome: diagnostic criteria, special considerations, and epidemiology. A report from the restless legs syndrome diagnosis and epidemiology workshop at the National Institutes of Health. *Sleep Med.* 2003;4(2):101–119. doi:10.1016/S1389-9457(03)00010-8
- Earley CJ, Connor J, Garcia-Borreguero D, et al. Altered brain iron homeostasis and dopaminergic function in Restless Legs Syndrome (Willis-Ekbom Disease). *Sleep Med.* 2014;15(11):1288–1301. doi:10.1016/j.sleep.2014.05.009
- Sun ER, Chen CA, Ho G, Earley CJ, Allen RP. Iron and the restless legs syndrome. *Sleep.* 1998;21(4):371–377. doi:10.1093/sleep/21.3.305
- Gigli GL, Adorati M, Dolso P, et al. Restless legs syndrome in end-stage renal disease. *Sleep Med.* 2004;5(3):309–315. doi:10.1016/j.sleep.2004.01.014
- Becker PM, Sharon D. Mood disorders in restless legs syndrome (Willis-Ekbom disease). *J Clin Psychiatry.* 2014;75(7):e679–e694. doi:10.4088/JCP.13r08692
- Patatanian E, Claborn MK. Drug-induced restless legs syndrome. *Ann Pharmacother.* 2018;52(7):662–672. doi:10.1177/1060028018760296
- Trenkwalder C, Allen R, Högl B, Paulus W, Winkelmann J. Restless legs syndrome associated with major diseases: a systematic review and new concept. *Neurology.* 2016;86(14):1336–1343. doi:10.1212/WNL.0000000000002542
- Ferri R, Fulda S, Allen RP, et al. World Association of Sleep Medicine (WASM) 2016 standards for recording and scoring leg movements in polysomnograms developed by a joint task force from the International and the European Restless Legs Syndrome Study Groups (IRLSSG and EURLSSG). *Sleep Med.* 2016;26:86–95. doi:10.1016/j.sleep.2016.10.010
- Hening WA, Allen RP, Washburn M, Lesage SR, Earley CJ. The four diagnostic criteria for Restless Legs Syndrome are unable to exclude confounding conditions (“mimics”). *Sleep Med.* 2009;10(9):976–981. doi:10.1016/j.sleep.2008.09.015

20. Webb AT. Letter: restless arms syndrome. *JAMA*. 1976;236(7):822.
21. Freedom T, Merchut MP. Arm restlessness as the initial symptom in restless legs syndrome. *Arch Neurol*. 2003;60(7):1013–1015. doi:10.1001/archneur.60.7.1013
22. Horvath J, Landis T, Burkhard PR. Restless arms. *Lancet*. 2008;371(9611):530. doi:10.1016/S0140-6736(08)60240-8
23. Konstantakopoulos G, Oulis P, Michalopoulou PG, Papadimitriou GN. Olanzapine-induced “restless arms syndrome.”. *J Clin Psychopharmacol*. 2009;29(1):89–90. doi:10.1097/JCP.0b013e31819302a0
24. Munhoz RP, Arruda WO, Teive HAG. An upper limb variant of RLS? Report of 2 cases. *Clin Neurol Neurosurg*. 2012;114(3):265–266. doi:10.1016/j.clineuro.2011.10.016
25. Ruppert E, Cretin B, Meyer C, Kilic-Huck U, Bourgin P. Characterization of periodic upper limb movement disorder in a patient with restless arms syndrome. *Mov Disord*. 2012;27(11):1459–1461. doi:10.1002/mds.24035
26. Gupta R, Lahan V, Goel D. Restlessness in right upper limb as sole presentation of restless legs syndrome. *J Neurosci Rural Pract*. 2013;4(1):78–80. doi:10.4103/0976-3147.105625
27. Ruppert E, Tranchant C, Kilic-Huck U, Carpentier N, Bataillard M, Bourgin P. Bedtime-related jerks in the upper limbs associated with restless arms syndrome. *Neurology*. 2015;84(9):959. doi:10.1212/WNL.0000000000001306
28. Kim H-Y, Park M-H, Kwon D-Y. Post-stroke restless arm syndrome mimicking hemichorea-hemiballism. *Acta Neurol Belg*. 2017;117(3):791–792. doi:10.1007/s13760-017-0758-y
29. Turrini A, Raggi A, Calandra-Buonaura G, Martinelli P, Ferri R, Provini F. Not only limbs in atypical restless legs syndrome. *Sleep Med Rev*. 2018;38:50–55. doi:10.1016/j.smrv.2017.03.007
30. Chabli A, Michaud M, Montplaisir J. Periodic arm movements in patients with the restless legs syndrome. *Eur Neurol*. 2000;44(3):133–138. doi:10.1159/00008221
31. American Academy of Sleep Medicine (AASM). *The International Classification of Sleep Disorders, Diagnostic and Coding Manual*. 2nd ed. Westchester (IL): American Academy of Sleep Medicine; 2005.
32. Haba-Rubio J, Marti-Soler H, Tobback N, et al. Clinical significance of periodic limb movements during sleep: the HypnoLaud study. *Sleep Med*. 2018;41:45–50. doi:10.1016/j.sleep.2017.09.014
33. Gabelia D, Mitterling T, Högl B, Wenning GK, Frauscher B. Do periodic arm movements during sleep exist in healthy subjects? A polysomnographic study. *Sleep Med*. 2014;15(9):1150–1154. doi:10.1016/j.sleep.2014.05.014
34. Torabi-Nami M, Mehrabi S, Derman S. Repetitive arm movements during sleep: a polysomnographic assessment. *Basic Clin Neurosci*. 2016;7(3):269–275.
35. Videnovic A. Management of sleep disorders in Parkinson’s disease and multiple system atrophy. *Mov Disord*. 2017;32(5):659–668. doi:10.1002/mds.26918
36. Karroum EG, Golmard J-L, Leu-Semenescu S, Arnulf I. Painful restless legs syndrome: a severe, burning form of the disease. *Clin J Pain*. 2015;31(5):459–466. doi:10.1097/AJP.0000000000000133
37. Karroum EG, Golmard J-L, Leu-Semenescu S, Arnulf I. Sensations in restless legs syndrome. *Sleep Med*. 2012;13(4):402–408. doi:10.1016/j.sleep.2011.01.021
38. Karroum EG, Leu-Semenescu S, Arnulf I. Topography of the sensations in primary restless legs syndrome. *J Neurol Sci*. 2012;320(1–2):26–31. doi:10.1016/j.jns.2012.05.051
39. Lee S-J, Kim J-S, Song I-U, An J-Y, Kim Y-I, Lee K-S. Poststroke restless legs syndrome and lesion location: anatomical considerations. *Mov Disord*. 2009;24(1):77–84. doi:10.1002/mds.22656
40. Ruppert E, Kilic-Huck U, Wolff V, et al. Restless legs syndrome as a first manifestation of a cerebral infarct. *J Clin Sleep Med*. 2014;10(9):1037–1038.
41. Ruppert E, Kilic-Huck U, Wolff V, et al. Brainstem stroke-related restless legs syndrome: frequency and anatomical considerations. *Eur Neurol*. 2015;73(1–2):113–118. doi:10.1159/000366416
42. Ruppert E, Bataillard M, Namer IJ, et al. Hyperdopaminergicism in lenticulostriate stroke-related restless legs syndrome: an imaging study. *Sleep Med*. 2017;30:136–138. doi:10.1016/j.sleep.2016.02.011
43. Hamdaoui M, Ruppert E, Comtet H, et al. Restless legs syndrome related to hemorrhage of a thoracic spinal cord cavernoma. *J Spinal Cord Med*. 2018;41(2):245–247. doi:10.1080/10790268.2017.1368963
44. Woo HG, Lee D, Hwang KJ, Ahn T-B. Post-stroke restless leg syndrome and periodic limb movements in sleep. *Acta Neurol Scand*. 2017;135(2):204–210. doi:10.1111/ane.2017.135.issue-2
45. Szentkirályi A, Völzke H, Hoffmann W, Trenkwalder C, Berger K. Multimorbidity and the risk of restless legs syndrome in 2 prospective cohort studies. *Neurology*. 2014;82(22):2026–2033. doi:10.1212/WNL.0000000000000513
46. Karroum EG, Raux M, Riou B, Arnulf I. Acute exacerbation of restless legs syndrome during perioperative procedures: case reports and suggested management. *Ann Fr Anesth Reanim*. 2010;29(12):920–924. doi:10.1016/j.annfar.2010.09.002
47. Raux M, Karroum EG, Arnulf I. Case scenario: anesthetic implications of restless legs syndrome. *Anesthesiology*. 2010;112(6):1511–1517. doi:10.1097/ALN.0b013e3181de2d66
48. Dondé C, Peter-Derex L, Pitance F, Cotte E, Gonnaud P-M, Saoud M. Pramipexole-responsive acute restless arms syndrome after surgery under general anesthesia: case report and literature review. *Rev Neurol (Paris)*. 2017;173(4):234–236. doi:10.1016/j.neuro.2016.12.035
49. Barnes TR, Braude WM. Akathisia variants and tardive dyskinesia. *Arch Gen Psychiatry*. 1985;42(9):874–878.
50. Walters AS, Hening W, Chokroverty S, Duvoisin R. Restlessness of the arms as the principal manifestation of neuroleptic-induced akathisia. *J Neurol*. 1989;236(7):435. doi:10.1007/BF00314908
51. Walters AS, Hening W, Rubinstein M, Chokroverty S. A clinical and polysomnographic comparison of neuroleptic-induced akathisia and the idiopathic restless legs syndrome. *Sleep*. 1991;14(4):339–345.
52. Kang SG, Lee HJ, Jung SW, et al. Characteristics and clinical correlates of restless legs syndrome in schizophrenia. *Prog Neuropsychopharmacol Biol Psychiatry*. 2007;31(5):1078–1083. doi:10.1016/j.pnpbp.2007.03.011
53. Berna F, Misdrahi D, Boyer L, et al. Akathisia: prevalence and risk factors in a community-dwelling sample of patients with schizophrenia. Results from the FACE-SZ dataset. *Schizophr Res*. 2015;169(1–3):255–261. doi:10.1016/j.schres.2015.10.040
54. Alisky JM. Restless arm symptoms as an extension of restless leg syndrome. *Age Ageing*. 2007;36(1):107. doi:10.1093/ageing/af124
55. Matsubara T, Suzuki K, Okamura M, et al. A 70-year-old woman presenting with restless shoulder following posterior internal capsule infarction. *Rinsho Shinkeigaku*. 2017;57(11):711–715. doi:10.5692/clinicalneuro.1001048
56. Yeh P, Ondo WG, Picchiatti DL, et al. Depth and distribution of symptoms in restless legs syndrome/Willis-Ekbom disease. *J Clin Sleep Med*. 2016;12(12):1669–1680. doi:10.5664/jcsm.6356
57. Valko PO, Siccoli MM, Bassetti CL. Unilateral RLS with predominantly ipsilateral PLMS and variable response to dopaminergic drugs: a variant of idiopathic RLS? *Eur J Neurol*. 2009;16(3):430–432. doi:10.1111/j.1468-1331.2008.02526.x
58. Pérez-Díaz H, Iranzo A, Rye DB, Santamaría J. Restless abdomen: a phenotypic variant of restless legs syndrome. *Neurology*. 2011;77(13):1283–1286. doi:10.1212/WNL.0b013e318230207a
59. Hattan E, Chalk C, Postuma RB. Is there a higher risk of restless legs syndrome in peripheral neuropathy? *Neurology*. 2009;72(11):955–960. doi:10.1212/WNL.0b013e3181a9fad1
60. Rutkove SB, Matheson JK, Logigian EL. Restless legs syndrome in patients with polyneuropathy. *Muscle Nerve*. 1996;19(5):670–672. doi:10.1002/(ISSN)1097-4598

Neuropsychiatric Disease and Treatment

Dovepress

Publish your work in this journal

Neuropsychiatric Disease and Treatment is an international, peer-reviewed journal of clinical therapeutics and pharmacology focusing on concise rapid reporting of clinical or pre-clinical studies on a range of neuropsychiatric and neurological disorders. This journal is indexed on PubMed Central, the 'PsycINFO' database and CAS, and

is the official journal of The International Neuropsychiatric Association (INA). The manuscript management system is completely online and includes a very quick and fair peer-review system, which is all easy to use. Visit <http://www.dovepress.com/testimonials.php> to read real quotes from published authors.

Submit your manuscript here: <https://www.dovepress.com/neuropsychiatric-disease-and-treatment-journal>