



## Oncology

## Severe immune thrombocytopenia induced by nivolumab in a patient with metastatic renal cell carcinoma

Shinro Hata<sup>a,\*</sup>, Satoki Abe<sup>a,b</sup><sup>a</sup> Department of Urology, Oitaken Koseiren, Tsurumi Hospital, Beppu, Oita, Japan<sup>b</sup> Department of Urology, Oita University, Yufu, Oita, Japan

## ARTICLE INFO

## Keywords:

Nivolumab  
 Immune thrombocytopenia  
 Immune-related adverse event  
 Renal cell carcinoma

## ABSTRACT

In the Checkmate-025 trial, nivolumab treatment prolonged overall survival among patients with previously treated advanced renal cell carcinoma (RCC) compared with treatment with everolimus. Although effective, nivolumab is associated with immune-related adverse events (irAEs). However, the occurrence of hematological irAEs is rare. Some studies have reported on nivolumab-induced thrombocytopenia. Nivolumab associated thrombocytopenia in almost all patients improved with administration of various drugs. However, there have been only a few cases that have reported death owing to cancer aggravation. In this paper, we have described a case of nivolumab-induced thrombocytopenia after third-line treatment for metastatic RCC.

## Introduction

Immune checkpoint inhibitors such as anti-programmed cell death protein 1 (PD-1) antibodies or anti-cytotoxic T-lymphocyte-associated-4 (CTLA-4) antibodies are monoclonal antibodies that combine immune checkpoint molecules and inhibit their function. The PD-L1 molecules on the cell surface of cancer cells or stromal cells inhibit T lymphocytes from attacking oneself and evade immune-system self-monitoring. Therefore, T-lymphocytes could attack cancer cells if anti-PD-1 antibodies inhibited the mechanism.<sup>1</sup> In the Checkmate-025 trial, nivolumab treatment prolonged overall survival among patients with previously treated advanced renal cell carcinoma (RCC) compared to everolimus.<sup>2</sup> The effectiveness of nivolumab is high but specific adverse events such as immune-related adverse events (irAEs) have been reported. irAEs have emerged in various organs. However, the occurrence of hematological irAEs is rare. Some studies have reported on nivolumab-induced thrombocytopenia in lung cancer and melanoma.<sup>3,4</sup> Nivolumab associated thrombocytopenia in almost all patients improved with administration of prednisolone, intravenous immunoglobulin (IVIG) and a thrombopoietin receptor agonist. However, there have been only a few cases that have reported death owing to cancer aggravation. Herein, we report a case of nivolumab-induced thrombocytopenia after third-line treatment for metastatic RCC.

## Case presentation

A 70-year-old man with right flank pain consulted our emergency department in March 2016. Computed tomography (CT) revealed a 11.2 × 8.2 × 7.0-cm right renal enhanced mass (Fig. 1). The patient was diagnosed with right RCC (cT3aN0M0), and he underwent radical nephrectomy the following month. Histological examination revealed clear-cell renal cell carcinoma, G3, Fuhrman Grade 3, INFA, v1, ly0, and pT3aN0Mx. Four months later, CT revealed enhanced masses on the liver. The patient was diagnosed with liver metastases of RCC, for which he underwent left hepatic lobectomy in September 2016. In December 2016, new metastases were found in the lungs. Treatment with sunitinib was initiated. However, the lung metastases enlarged, and new liver and lymph node metastases appeared. He was administered axitinib as second-line therapy in April 2017. Both drugs were tolerated with a few side effects including slight renal damage and myelosuppression. However, due to the progressive disease of cancer at all the metastatic sites, nivolumab therapy (3 mg/kg, every 2 weeks) was initiated in May 2018. Pre-treatment platelet counts were slightly decreased with values around 130–140 × 10<sup>3</sup>/μl. The treatment continued for 8 cycles afterward. Chemotherapy-induced diarrhea (Grade 1) was the only side effect observed during the 8 cycles. At the end of the 8th nivolumab infusion, nivolumab therapy was discontinued due to skin eruptions on

**Abbreviations:** PD-1, programmed cell death protein 1; CTLA-4, cytotoxic T-lymphocyte-associated-4; RCC, renal cell carcinoma; irAE, immune-related adverse event; IVIG, intravenous immunoglobulin; CT, computed tomography; ITP, idiopathic thrombocytopenia.

\* Corresponding author. Department of Urology, Oitaken Koseiren, Tsurumi Hospital, 4333 Tsurumi, Beppu, Oita, 874-8585, Japan.

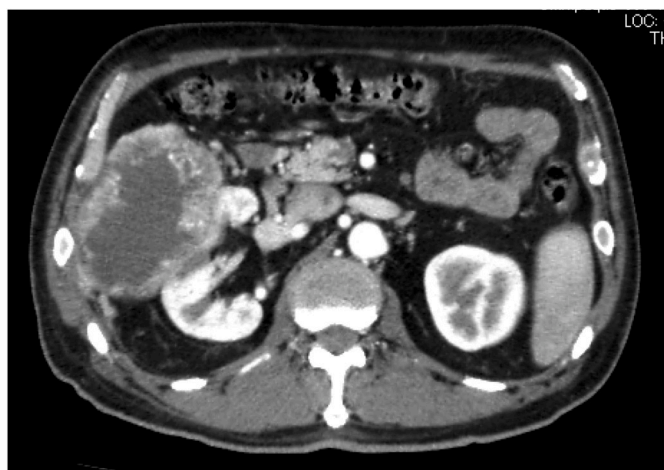E-mail address: [hatashinn@oita-u.ac.jp](mailto:hatashinn@oita-u.ac.jp) (S. Hata).

<https://doi.org/10.1016/j.eucr.2020.101128>

Received 8 January 2020; Accepted 22 January 2020

Available online 28 January 2020

2214-4420/© 2020 Published by Elsevier Inc. This is an open access article under the CC BY-NC-ND license (<http://creativecommons.org/licenses/by-nc-nd/4.0/>).

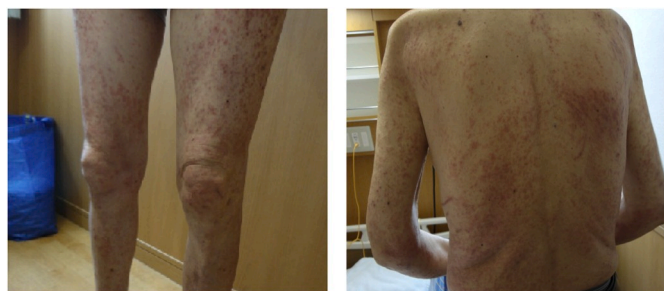

**Fig. 1.** The abdominal computed tomography findings. The computed tomography showed a 11.2 × 8.2 × 7.0 cm right renal enhanced mass. The patient was diagnosed with right renal cell carcinoma (cT3aN0M0).

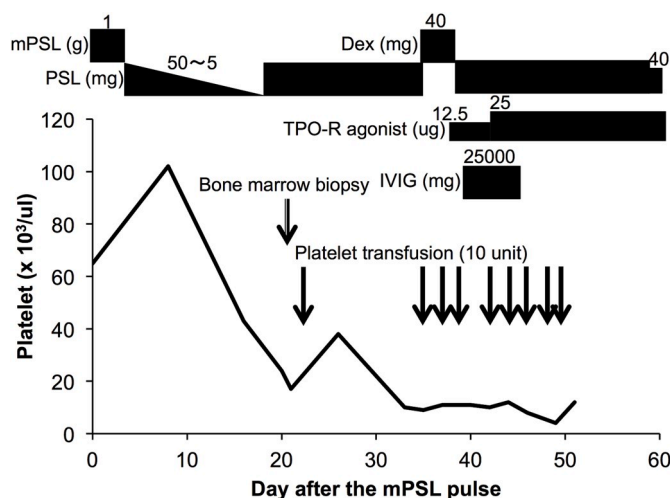
the lower limbs, which were biopsied (Fig. 2). His eruption improved immediately with the use of steroids. The biopsy of the skin eruption revealed that the upper layer of the dermis was edematous, and lymphocytes and eosinophils invaded the stroma. Hence, we diagnosed the patient with nivolumab-induced skin eruptions. Intravenous prednisolone was switched to oral administration; on day 20 after methylprednisolone administration, the patient's platelet count decreased to  $24 \times 10^3/\mu\text{l}$ . We suspected irAE, performed a bone marrow biopsy, and increased prednisolone to 50 mg/day again. However, the following day, his platelet count decreased to  $17 \times 10^3/\mu\text{l}$ , and platelet transfusion was performed the same day. The platelet counts continued to be low for a prolonged time. Hence, on day 33 after methylprednisolone administration, dexamethasone pulse therapy, a thrombopoietin receptor agonist, and IVIG were administered, but to no effect. A platelet transfusion of 90 units was provided throughout the treatment period. There were no hemorrhagic symptoms and the platelet-associated IgG (PA-IgG) level slightly elevated to  $73 \text{ ng}/10^7 \text{ cells}$ . The metastatic lesions were gradually enlarged, and by day 56 after methylprednisolone administration, the patient died (Fig. 3).

**Discussion**

Idiopathic thrombocytopenia (ITP) is an autoimmune disorder caused by the formation of antibodies targeting platelet antigens, leading to thrombocytopenia. It has been termed primary immune thrombocytopenia recently and represents various hemorrhagic symptoms. Erythrocytes and leukocytes normally do not show any abnormalities, and the production of megakaryocytes in bone marrow is normal. ITP is mainly a disorder of exclusion; underlying thrombocytopenic diseases,



**Fig. 2.** Skin eruptions findings. Red eruptions that were itchy appeared on his face, limbs, and trunk. (For interpretation of the references to colour in this figure legend, the reader is referred to the Web version of this article).



**Fig. 3.** Clinical course after methylprednisolone administration. Intravenous prednisolone was switched to oral administration; on day 20, the patient's platelet count decreased to  $24 \times 10^3/\mu\text{l}$ . PSL, prednisolone; mPSL, methylprednisolone; Dex, dexamethasone; TPO-R, thrombopoietin receptor; IVIG, intravenous immunoglobulin.

drugs, and infections should be ruled out.<sup>5</sup> We diagnosed the patient with immune thrombocytopenia based on the following: first, after being administered intravenous prednisolone for skin eruptions, the platelet counts decreased with reduced steroid administration. We decreased the dose of oral prednisolone to 5 mg/day for three weeks as the skin eruptions immediately improved. It may be suggested too early. Second, we diagnosed immune thrombocytopenia based on the findings of the bone marrow biopsy. It revealed that the appearance of megakaryocytes, erythroblasts and granulocytes were normal and the presence of partial megakaryocytes lacking platelet adhesion. Additionally, there was no sufficient evidence to suspect other hematological disorders. However, it is unclear as to why no hemorrhagic symptoms were observed and why the steroid therapy was totally ineffective.

The occurrence of ITP induced by immune checkpoint inhibitors is rare. However, some studies have reported on nivolumab-induced thrombocytopenia in other cancers. ITP induced by nivolumab was reportedly observed in a patient with lung cancer; severe thrombocytopenia suddenly emerged on day 15 after the first nivolumab infusion.<sup>3</sup> In this case, platelet counts were recovered only by steroid therapy. In another case, ITP induced by nivolumab occurred in a patient with metastatic melanoma.<sup>4</sup> The patient was found to have thrombocytopenia before the third administration. He also exhibited hemorrhage of the oral mucosa and a petechial rash. The patient then required steroids, IVIG and romiplostim for management.

**Funding**

This research did not receive any specific grant from funding agencies in the public, commercial, or not-for-profit sectors.

**Conclusion**

To our knowledge, this is the first case report describing thrombocytopenia induced by nivolumab in a patient with metastatic RCC. Thrombocytopenia, particularly ITP, induced by nivolumab is a rare irAE and requires careful follow-up.

**Consent**

Written informed consent was obtained from the patient for publication of this case report and accompanying images.

### Declaration of competing interest

The authors declare no conflict of interest.

### Acknowledgements

We would like to thank Editage ([www.editage.com](http://www.editage.com)) for English language editing.

### References

1. Wei SC, Duffy CR, Allison JP. Fundamental mechanisms of immune checkpoint blockade therapy. *Canc Discov.* 2018;8:1069–1086.
2. Motzer RJ, Escudier B, McDermott DF, et al. Nivolumab versus everolimus in advanced renal-cell carcinoma. *N Engl J Med.* 2015;373:1803–1813.
3. Mori H, Sakai C, Iwai M, et al. Immune thrombocytopenia induced by nivolumab in a patient with non-small cell lung cancer. *Respir Med Case Rep.* 2019;28:100871.
4. Kanameishi S, Otsuka A, Nonomura Y, et al. Idiopathic thrombocytopenic purpura induced by nivolumab in a metastatic melanoma patient with elevated PD-1 expression on B cells. *Ann Oncol.* 2016;27:546–547.
5. Lambert MP, Gernsheimer TB. Clinical updates in adult immune thrombocytopenia. *Blood.* 2017;129:2829–2835.