


# Retinopathy in Egyptian patients with sickle cell disease

## A cross-sectional study

Tamer Hassan, MD<sup>a,\*</sup> , Mohamed Badr, MD<sup>a</sup>, Diana Hanna, MD<sup>a</sup>, Mohamed Arafa, MD<sup>a</sup>, Ahmed Elhewala, MD<sup>a</sup>, Sherief Dabour, MD<sup>b</sup>, Saad Shehata, MD<sup>c</sup>, Doaa Abdel Rahman, MD<sup>a</sup>

### Abstract

Sickle cell disease (SCD) is a disorder that causes red blood cells to become sticky and rigid. Sickle cells can block blood flow in small blood vessels depriving the eye of oxygen and cause damage. This is called sickle retinopathy that can progress to severe proliferative sickle cell retinopathy, bleeding into the eye, detachment of the retina or even loss of vision.

To assess ocular manifestations and detect frequency of retinopathy in patients with SCD.

Cross-sectional study was conducted on 32 patients with SCD. They were 22 males and 10 females with mean age of 12 years. Routine investigations as well as ophthalmological examination including visual acuity, fluorescein angiography and optical coherence tomography were done.

We found that 8 patients (25%) suffered from proliferative retinopathy, 10 patients (31%) showed tortuous retinal veins, while 14 patients (44%) were normal. All patients showed macular thinning on optical coherence tomography examination.

We concluded that frequency of retinopathy in patients with SCD is more than expected and it was higher in patients who started transfusion at a later age. More attention should be paid for this problem and close observations and follow up is strongly needed.

**Abbreviations:** BCVA = best corrected visual acuity, FA = fluorescein angiography, Hb SC = Hemoglobin SC disease, HbSβ = sickle-beta thalassemia, HbSS = homozygous SCD, HU = hydroxyurea, OCT = optical coherence tomography, *P*-value = probability, SR = proliferative sickle cell retinopathy, SCD = sickle cell disease, VOC = vaso-occlusive crisis.

**Keywords:** fluorescein angiography, ocular complications, proliferative retinopathy, sickle cell disease, visual acuity

## 1. Introduction

Sickle cell disease (SCD) is one of the most common genetic diseases worldwide. In Egypt, sickle hemoglobin carrier rates vary from 9% to 22% with a heterogeneous distribution. Among Egyptians, most of the reported globin gene haplotypes are the African ones and the SCD phenotype is severe.<sup>[1]</sup>

Increased in life expectancy of SCD patients in recent years has led to emergence of more disease-related complications, including

ocular manifestations. SCD can affect every vascular bed in the eye and can cause blindness in advanced stages. Ocular lesions result from stasis and occlusion of the small eye vessels by sickled erythrocytes. Vaso-occlusive disease of the retina can be responsible for nonproliferative and proliferative ocular changes (based on the absence or presence of vascular proliferation, respectively). This distinction is important because formation of new vessels is the single most important precursor of potentially blinding complication.<sup>[2]</sup>

Patients are often asymptomatic until complications arise as vitreous hemorrhage and retinal detachment. Some studies report that the incidence and prevalence rates of all ocular complications in SCD increase with age and that proliferative retinopathy progresses rapidly during adolescence, justifying the routine screening of children.<sup>[3,4]</sup>

We aimed at detection of the ocular manifestations in patients with SCD and determining the frequency of retinopathy in those patients in order to prevent vision – threatening complications.

## 2. Materials and methods

A cross-sectional study was conducted over a period of 6 months from April 2017 to September 2017. It Included 32 patients (22 males and 10 females) with SCD who were following up regularly, at Pediatric Hematology outpatient clinics of Zagazig University Hospital and Damanhour teaching hospital. Their ages ranged from 6 to 17 years (mean ± standard deviation = 12 ± 3.39). Data abstraction form was designed to capture appropriate medical information from patients' records.

Editor: Maya Saranathan.

The authors have no funding and conflicts of interest to disclose.

The datasets generated during and/or analyzed during the current study are available from the corresponding author on reasonable request.

<sup>a</sup> Pediatrics Department, Faculty of Medicine, Zagazig University, Zagazig, Egypt,

<sup>b</sup> Ophthalmology Department, Faculty of Medicine, Zagazig University, Zagazig, Egypt, <sup>c</sup> Damanhour Teaching Hospital, Damanhour, El Beheira Governorate, Egypt.

\* Correspondence: Tamer Hassan, Pediatrics Department, Faculty of Medicine, Zagazig University, Zagazig 44519, Egypt (e-mail: dr.tamerhassan@yahoo.com).

Copyright © 2021 the Author(s). Published by Wolters Kluwer Health, Inc. This is an open access article distributed under the terms of the Creative Commons Attribution-Non Commercial License 4.0 (CCBY-NC), where it is permissible to download, share, remix, transform, and buildup the work provided it is properly cited. The work cannot be used commercially without permission from the journal.

How to cite this article: Hassan T, Badr M, Hanna D, Arafa M, Elhewala A, Dabour S, Shehata S, Rahman DA. Retinopathy in Egyptian patients with sickle cell disease: a cross-sectional study. *Medicine* 2021;100:51(e28355).

Received: 22 November 2020 / Received in final form: 16 September 2021 / Accepted: 1 December 2021

<http://dx.doi.org/10.1097/MD.00000000000028355>

### 2.1. Inclusion criteria

- Children with SCD (homozygous SCD [HbSS], sickle-beta thalassemia [HbSβ<sup>0</sup>], HbSβ<sup>+</sup>).
- Age 6 to 17 years.
- Both sex.
- Written informed consent and/or assent before any study-specific procedures.

### 2.2. Exclusion criteria

- Children with systemic diseases as diabetes and hypertension.
- Prematurity and congenital related vascular abnormality.
- Patients with congenital or acquired eye diseases which started before the study, known to affect the visual field, such as aphakia, cataract, glaucoma, optic nerve and macular disease, and previous photocoagulation were excluded from the study.

### 2.3. Methods

- Complete medical history including initial clinical presentation of the disease, frequency of vaso-occlusive crises as well as full transfusion, and chelation history.
- Through clinical examination.
- Routine laboratory investigations including complete blood count, serum ferritin level, and hemoglobin electrophoresis.
- Ophthalmological examination including:
  1. **Visual acuity.** It is measured by Snellen visual acuity charts whenever possible. Normal value is 6/6 which equal 1, other values as 6/12 equals 0.5 and 6/7.5 equals 0.8.
  2. **Fluorescein angiography.** Fluorescein angiography (FA) is a procedure that investigate the integrity of the retinal vasculature. Some common conditions for which FA is indicated include atrophic macular degeneration, central serous chorioretinopathy, cystoid macular edema, ischemic optic neuropathy and malignant choroidal melanoma. It also can diagnose diabetic retinopathy, retinal tumors, retinal vascular occlusions, rubeosis, subretinal neovascular membranes, and unexplained vision loss.

#### 2.3.1. Stages of the test.

- Fluorescein angiograms progress through 5 phases: prearterial (choroidal flush), arterial, arteriovenous, venous and late recirculation. The process begins with injection of sodium fluorescein dye into the antecubital vein. The dye reaches the posterior pole via the short posterior ciliary arteries, then spreads anteriorly to the ora serrata. In most cases, choroidal filling begins 10 to 20 seconds after injection, and is first visible as a patchy and lobular pattern.
- The arterial phase begins 1 to 2 seconds after choroidal filling, and is usually over within seconds of the first appearance of fluorescein dye. In a normal angiogram, branches fill simultaneously. Any delay in the filling of the arterial tree is abnormal and requires investigation. In the arteriovenous phase, dye spreads to the precapillary arterioles, the capillaries and the postcapillary venules, resulting in a laminar flow pattern with a railroad track appearance in the filling venules. Venous filling occurs in 2 phases: laminar and complete. In the laminar venous phase, we can see a flow pattern in which the blood closest to the vessel wall fluoresces. We will see also a bright outline of fluorescence along the walls of the vessel and a

dark line centrally in larger venules. This occurs due to the rapid flow of plasma along the vessel walls and the high density of erythrocytes in the central lumen.<sup>[5]</sup>

- As more blood converges on the larger venules from smaller tributaries, complete venous filling occurs until the lumen completely fills with dye. The filling process usually takes 45 to 60 seconds. The maximum concentration of fluorescein within the choroid and retina occurs 20 to 25 seconds after injection. This point of the study, the peak phase, is the optimal time to see the foveal avascular zone. Shortly after, the dye begins to recirculate. We will see a gradual and progressive reduction in fluorescence as the kidneys remove dye from the bloodstream. The late, or recirculation, phase takes about 7 to 20 minutes. By this time, arteries and veins are virtually devoid of fluorescein, and choroidal flush is barely perceptible. Photos taken at this time help identify late leakage of fluorescein, accumulation of intra-retinal dye and staining of tissues with fluorescein.

**2.3.2. Interpretation.** Monitoring the time the dye takes to travel from the arm to the eye, as well as filling times for the major retinal vascular branches. Next, identification of hypofluorescence or hyperfluorescence areas, and evaluation of any change over the course of the study. Interpretation of the results of FA depends on measuring the extent to which an area hypofluorescence or hyperfluorescence relative to the normal background fluorescein pattern.

**2.3.3. Risks and side effects.** Patients with known hypersensitivity to fluorescein dye should undergo FA only when vital. Although there are many reports of side effects of fluorescein administration, overall, it is a safe diagnostic procedure. The most common reaction, which happens in nearly all patients, is temporary yellowing of the skin and urine.<sup>[6]</sup>

Other than that, nausea and emesis are the most frequently reported reactions. These mild reactions tend to occur in 5% of cases or less.<sup>[7]</sup> More severe reactions such as syncope, thrombophlebitis, fever, nerve palsy and necrosis of local tissue are reported in less than 1% of cases.<sup>[8]</sup> The incidence of death following the injection of fluorescein dye is 1 in 220,000.<sup>13</sup> In some cases, orally administered fluorescein may be administered as an alternative

## 3. Optical coherence tomography

- Optical coherence tomography (OCT) is an imaging technique that uses coherent light to capture micrometer-resolution, two- and three-dimensional images from within optical scattering media (eg, biological tissue). It is used for medical imaging and industrial nondestructive testing. OCT is based on low-coherence interferometry, typically employing near-infrared light. The use of relatively long wavelength light allows it to penetrate into the scattering medium.
- Confocal microscopy, another optical technique, typically penetrates less deeply into the sample but with higher resolution. Depending on the properties of the light source (super luminescent, ultrashort pulsed lasers, and supercontinuum lasers have been employed), OCT has achieved sub-micrometer resolution (with very wide-spectrum sources emitting over a ~100nm wavelength range). OCT is one of a class of optical tomographic techniques.
- A relatively recent implementation of OCT, frequency-domain OCT, provides advantages in signal-to-noise ratio, permitting faster signal acquisition. Commercially available OCT systems

are employed in diverse applications, including art conservation and diagnostic medicine, notably in ophthalmology and optometry where it can be used to obtain detailed images from within the retina.<sup>[9,10]</sup>

#### 4. Statistical analysis

Data were analyzed using IBM SPSS 23.0 for windows (IBM Corp., Armonk, NY) and NCSS 11 for windows (NCSS LCC., Kaysville, U T). Quantitative data were expressed as mean  $\pm$  standard deviation. Qualitative data were expressed as frequency and percentage. The following tests were done:

- Independent-samples *t* test of significance was used when comparing between 2 means.
- Mann-Whitney *U* test was used when comparing 2 means of not normally distributed data.
- Chi-square test of significance was used in order to compare proportions between 2 qualitative parameters.
- Probability (*P*-value): *P*-value  $\leq$  .05 was considered significant, *P*-value  $\leq$  .001 was considered as highly significant and *P*-value  $>$  .05 was considered insignificant.

#### 5. Statement of ethics

The present study was performed according to Helsinki Declaration of 1964, as revised in 2000, and was approved by ethics committee of faculty of medicine, Zagazig University. Informed written consent and/or assent were obtained from all study participants and/or their care givers.

#### 6. Results

##### 6.1. Demographic, transfusion, and chelation characteristics in sickle cell disease patients

The mean age of our patients was  $12 \pm 3.39$  years. They were 22 males (70%) and 10 females (30%). The mean age of start transfusion was 39 months, 94% of patients received blood transfusion, 40% of them were regularly transfused at rate  $\leq$  1 month and 33.3% at rate of 2 to 4 months, while 26.7% of them received transfusion irregularly. Sixty percent of patients received chelation therapy, 50% of them received deferasirox, 16.7% received deferiprone, 8.3% received desferrioxamine while 25% of patients received combined therapy. The mean age of start chelation therapy was 4.83 years that ranged from 2 to 10 years. The range of serum ferritin among our patients was 15 to 4978 ng/mL with a mean of 1352.9 ng/mL.

##### 6.2. Clinical characteristics in sickle cell disease patients

Our results showed that most of patients (60%) presented for the first time with pallor late after 1 year of age, 40% presented with pallor early before age of 1 year. 10% of patients presented with bone pains and 10% with abdominal pains. 81% of patients suffered from vaso-occlusive crisis (VOC) that occurred at a rate of 2 to 4 times/year in 50% of patients,  $>$ 5 times/year in 43.7% and at a monthly rate in 6.3% of patients.

##### 6.3. Types of sickle cell disease in patients

According to type of SCD, 50% of our patients had HbSS while HbS $\beta^+$  and HbS $\beta^0$  each account for 25% of the studied cases.

##### 6.4. Ophthalmologic findings in our patients

Our results showed that the best corrected visual acuity (BCVA) for right eye was 0.708 with a range from 0.05 to 1, while that for left eye was 0.675 with a range from 0.05 to 1.

FA detected tortuous retinal veins in 10 patients (31%) (Fig. 1), proliferative retinopathy in 8 patients (25%) (Fig. 2), while 44% of patients were normal. All studied patients showed macular thinning on OCT examination (Table 1, Fig. 3).

##### 6.5. Visual acuity, fluorescein angiography (FA), optical coherence tomography (OCT) in relation to SCD types

No significant difference was found between SCD types and any of BCVA, FA, and OCT in both eyes (Table 2).

##### 6.6. Relationship between retinopathy and demographic, clinical, transfusion, and chelation characteristics

SCD patients with retinopathy started transfusion therapy at later age compared to those without retinopathy (69 months versus 31.07, respectively, *P* = .04) (Table 3).

There was no significant relationship between retinopathy and chelation therapy or age of start chelation (Table 4). Also, there was no significant relationship between retinopathy and any of demographic and clinical characteristics of patients.

##### 6.7. Relationship between VOC and visual acuity, fluorescein angiography (FA), optical coherence tomography (OCT)

No significant difference was found between VOC and any of BCVA or fluorescein angiography (FA). Statistical analysis cannot be performed with OCT as all patients had macular thinning (Table 5).

#### 7. Discussion

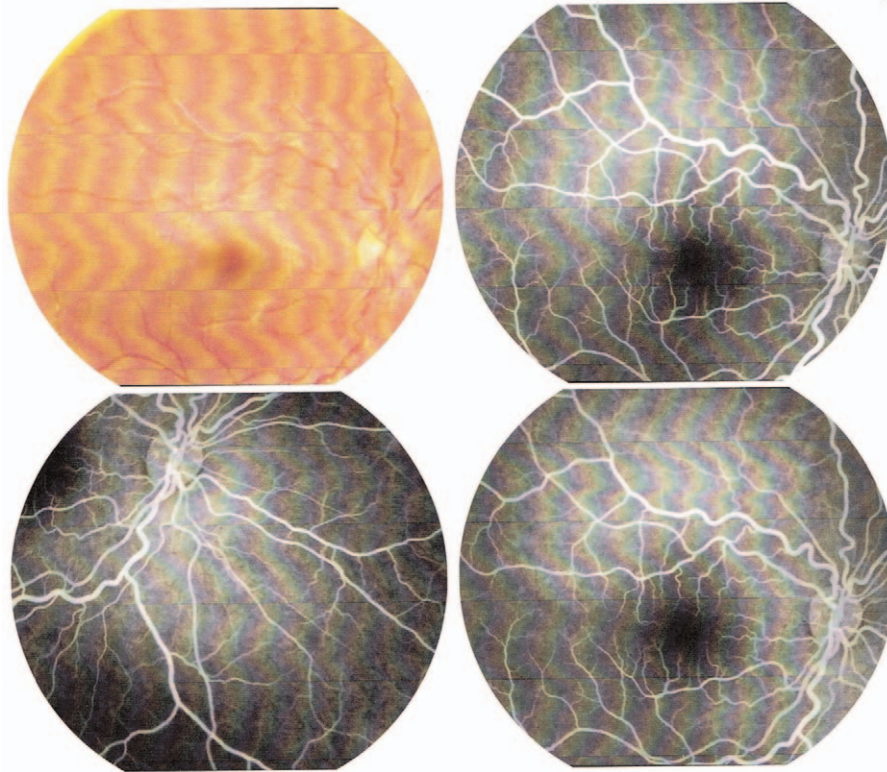
Retinal hypoxia, ischemia, neovascularization, and fibrovascularisation may result from the microvascular occlusion in SCD patients. These vaso-occlusions depend on the degree of blood viscosity, which is proportional to the rate of sickling and the hemoglobin concentration.<sup>[11]</sup>

The most significant ocular changes are those that occur in the fundus, which can be grouped into proliferative and non-proliferative retinal changes. Formation of new vessels is the most important precursor of potentially blinding complications, preceding development of vitreous hemorrhage or retinal detachment. Eye manifestations may be asymptomatic, with unawareness of disease progression, and may have devastating consequences.<sup>[12]</sup>

Sickle cell retinopathy is one of the complications of sickle cell anemia that occurs due to occlusion of retinal vessels, especially in temporal periphery.<sup>[13]</sup> It can cause severe damage to the retina but with regular check-ups and timely treatment the problem may be easily brought under control, which prevents loss of vision in the long run.<sup>[14]</sup>

This cross-sectional study was conducted on 32 patients with SCD who were followed up regularly, at pediatric hematology outpatient clinic of Zagazig University hospitals.

Our study showed that 70% of our patients were males and only 30% were females (male: female ratio of 2.3:1) with a mean age of  $12 \text{ years} \pm 3.39$  and a range from 6 to 17 years.



**Figure 1.** Fluorescein angiography shows bilateral tortuous retinal veins.

Though there was no reasonable explanation of higher male to female ratio in patients with SCD, higher male to female ratio was observed in many studies; Tantawy et al<sup>[15]</sup> assessed retinal changes in 60 children with SCD (34 males and 26 females) with male to female ratio of 1.3:1. The mean age of patients in their study was  $10.3 \pm 7.4$  years (range 3–18 years).

This also was in agreement with a study conducted by Asbeutah et al<sup>[16]</sup> on 43 patients with SCD (27 males and 16 females) with male to female ratio of 1.7:1.

Higher male to female ratio in our study can be attributed to small sample size.

Our study showed that the initial clinical presentation was pallor before 1 year in 40% and after 1 year in 60%, with painful events either bone pains or abdominal pains in 20% of our patients. On the other hand, VOC were present in 81% of patients with a frequency of 2 to 4 times/year in 50% (13 out of 26).

da Silva Filho et al<sup>[17]</sup> described the clinical events in a retrospective study in patients with SCD under 6 years, and reported painful events and acute chest syndrome to be more frequent in under 3 years old children, 94% of children had at least 1 episode and this percentage is quite near to that reported in our study.

Our study showed that 94% of patients received blood transfusion, 40% of them were regularly transfused at rate  $\leq 1$  month and 33.3% at rate of 2 to 4/month, while 26.7% of them received transfusion irregularly. The patients started transfusion at age ranged from 5 months to 10 years with a mean of 39 months.

In agreement with our study, Wanko and Telen<sup>[18]</sup> reported that the majority of patients with sickle cell anemia have received

repeated blood transfusions by adulthood and in their opinion transfusion therapy is likely to further increase in pediatric patients because of recent evidence indicating its ability to prevent organ injury and improve the outcome of complications and this is supported by The Optimizing Primary Stroke Prevention in Sickle Cell Anemia Trial Investigators, 2005.

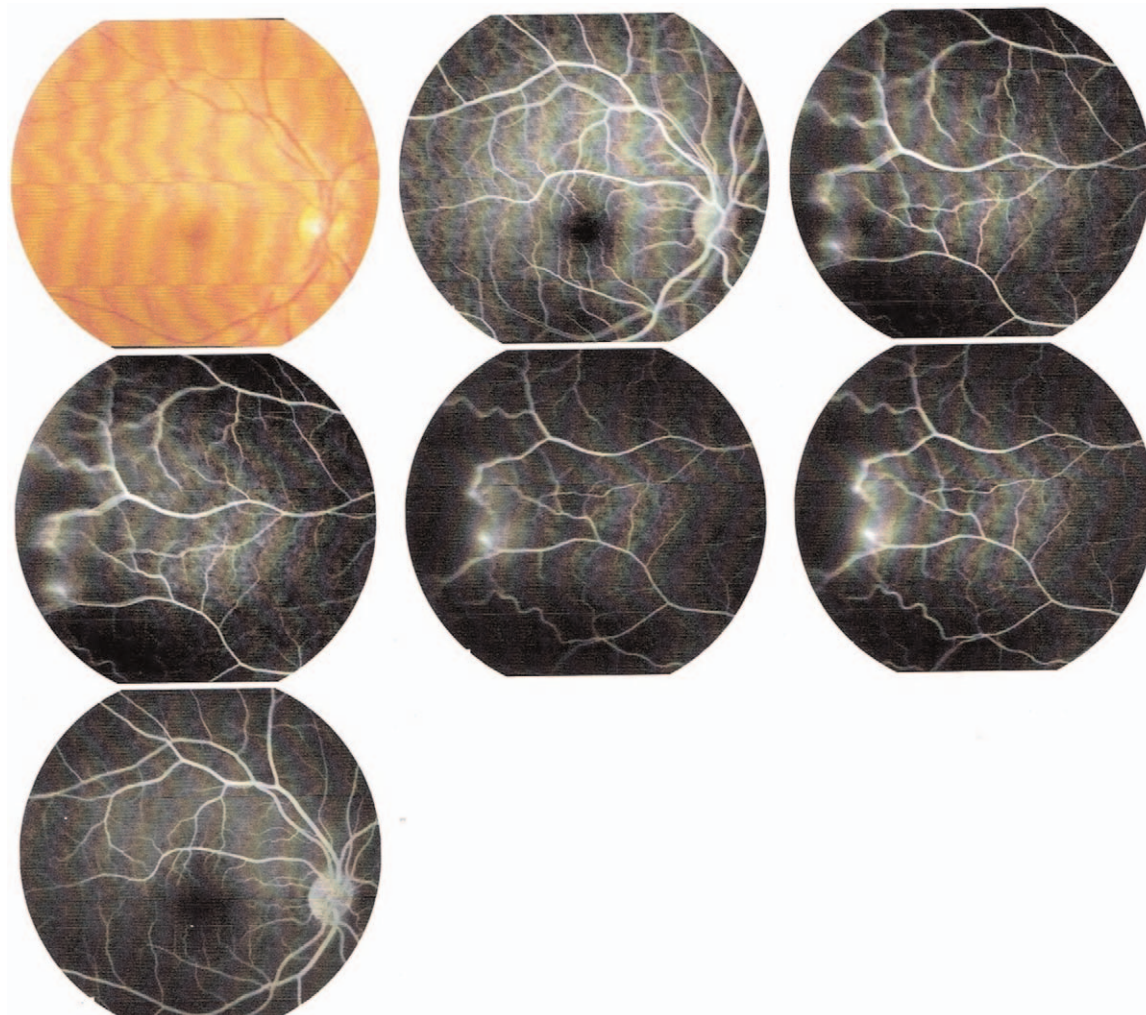
The increased use of transfusions may ultimately be balanced by hydroxyurea (HU) and other newer therapies developed as the complex pathophysiology of SCD is better understood; however, red cell transfusion is considered the most studied and accepted therapy for most acute and many chronic complications of SCD. Physicians caring for patients with SCD should be aware of the unique complications and transfusion requirements in this population.<sup>[18]</sup>

In our study 60% of patients received chelation therapy, patients started therapy at mean age of  $4.83 \pm 2.17$  years with a range from 2 to 10 years. There was no significant relationship between retinopathy and chelation therapy or age of start chelation. The mean of serum ferritin in our patients was of  $1352.9 \pm 650.3$  ng/mL.

Enniful-Eghan et al<sup>[19]</sup> in their large study on 475 patients with SCD, reported that mean serum ferritin level was 1566 ng/mL with a range from 38 to 7240 ng/mL. It was correlated positively with duration of simple transfusion ( $r=0.63, P < .001$ ). However only 6 children were receiving chelation therapy in their study.

Our study showed that, 50% of our patients had HbSS while HbS $\beta^+$  and HbS $\beta^0$  each account for 25% of the studied cases.

Tantawy et al<sup>[15]</sup> reported that 32/60 patients (53%) had HbS $\beta$  (20 had HbS $\beta^+$  and 12 had HbS $\beta^0$ ), and 28/60 patients (47%) had HbSS, and this is quite near to our results.<sup>[15]</sup>



**Figure 2.** Fluorescein angiography shows right proliferative sickle cell retinopathy and left peripheral retinal neovascularization.

Asbeutah et al<sup>[16]</sup> on 43 patients with SCD found that 21 had HbSS (48.8%), 19 had HbSβ<sup>0</sup> (44.2%), and 3 had sickle cell trait (7%).

Higher percentage of homozygous sickle cell anemia was reported by El-Ghamrawy et al<sup>[20]</sup> where 26 (65%) patients had HbSS and 14 patients (35%) had HbSβ<sup>+</sup>.

Our study showed that the BCVA for right eye was 0.708 with a range from 0.05 to 1, while that for left eye was 0.675 with a range from 0.05 to 1. Patients with poor vision in our study were due to amblyopia and not due to proliferative sickle retinopathy.

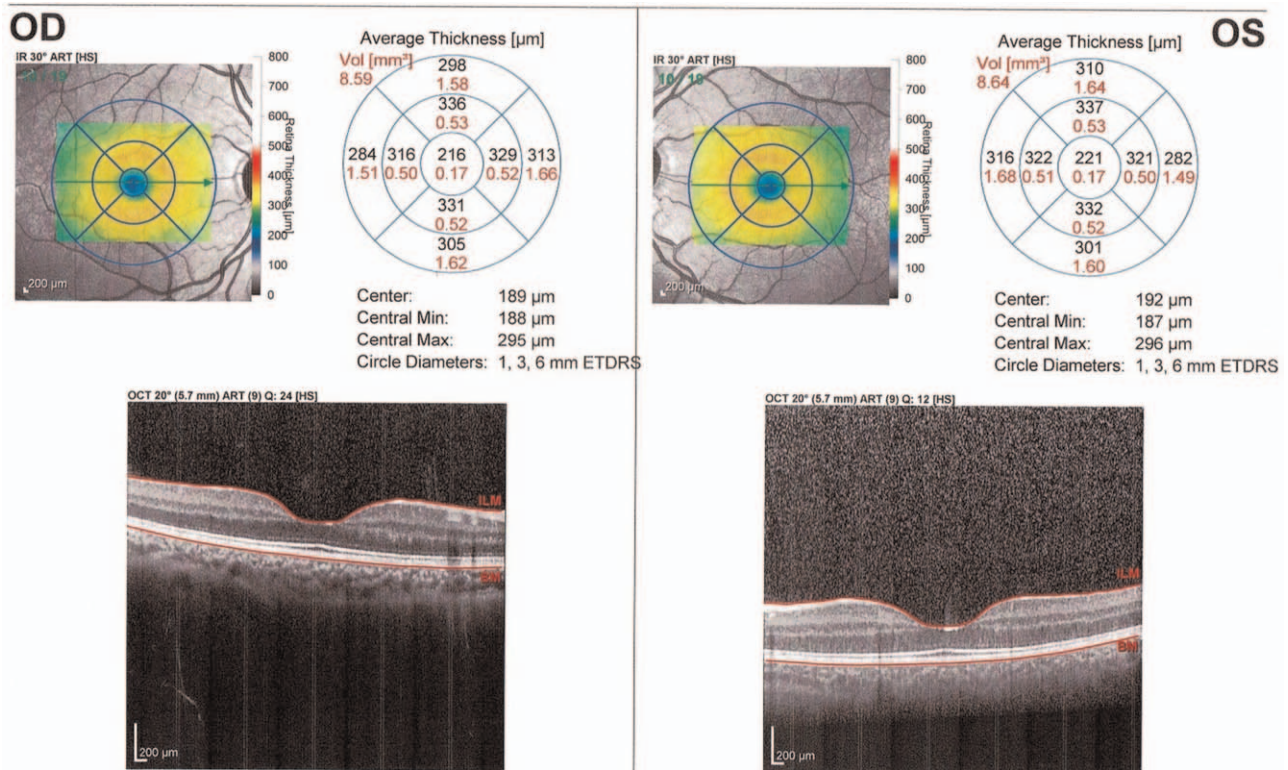
**Table 1**  
**Fluorescein angiography (FA) and optical coherence tomography (OCT) of patients with SCD.**

Variables	SCD patients (n=32)	
	N	%
Fluorescein angiography (FA)		
Normal	14	44.0
Tortuous retinal veins	10	31.0
Proliferative retinopathy	8	25.0
Optical coherence tomography (OCT)		
Macular thinning	32	100.0

Moriarty et al<sup>[21]</sup> conducted ophthalmic assessment of 120 patients with HbSS over a period of 10 years. Visual acuity loss ( $\leq 6/18$ ) attributable to sickle cell retinopathy occurred in 10% of untreated eyes during a mean observation period of 6.9 years. Visual loss was strongly associated with proliferative sickle retinopathy ( $P < .001$ ).

Martin et al<sup>[22]</sup> assessed the visual function of patients with SCD with no visual symptoms despite temporal macular atrophy. All 3 patients included had HbSS. They presented with a 20/20 distance visual acuity. They were all followed up for a severe cerebral vasculopathy related to SCD. Temporal macular atrophy in SCD may have direct consequences on visual function, including in children, even when visual acuity is preserved.

In our study FA detected tortuous retinal veins in 10 patients (31%), proliferative retinopathy in 8 patients (25%), while 44% of patients were normal. All studied patients showed macular thinning on OCT examination. In a study, by Van Meurs,<sup>[23]</sup> involving 87 subjects with HbSS on the island of Curaçao found a high incidence of peripheral retinal vascular closure and proliferative retinopathy. Also, Examination of composite fluorescein angiograms obtained from 15 HbSS patients, revealed significantly small measurements of perfused retina (indicative of larger areas of nonperfusion).



**Figure 3.** OCT line scan passing through the macula of the both eyes revealing bilateral macular thinning: OD: 189 μm and OS: 192 μm. OD = oculus dextrus (right eye), OS = oculus sinister (left eye).

**Table 2**  
**Relationship between fluorescein angiography (FA) and optical coherence tomography (OCT) and types of SCD.**

Variables	HbSS (n=16)		HbSβ <sup>0</sup> (n=8)		HbSβ <sup>+</sup> (n=8)		χ <sup>2</sup>	P-value
	N	%	N	%	N	%		
Fluorescein angiography (FA)								
Normal	10	62.5	2	25.0	2	25.0	9.16	.165
Tortuous retinal veins	2	12.5	4	50.0	4	50.0		
Proliferative retinopathy	4	25.0	2	25.0	2	25.0		
Optical coherence tomography (OCT)								
Macular thinning	16	100.0	8	100.0	8	100.0		Not applicable

χ<sup>2</sup> = Chi-square test.

**Table 3**  
**Relationship between retinopathy and transfusion characteristics of patients with SCD.**

Variables	Patients with retinopathy (n=8)		Patients without retinopathy (n=24)		Test	P-value
	N	%	N	%		
Transfusion dependency						
Yes (n=30)	8	100	22	91.7	χ <sup>2</sup> = 1.25	.263
No (n=2)	0	0.0	2	8.3		
Frequency of transfusion						
Regular at rate ≤ 1 mo (n=12)	3	37.5	9	41.0	χ <sup>2</sup> = 0.305	.858
Regular at rate of 2–4/ mo (n=10)	2	25.0	8	36.3		
Irregular (n=8)	3	37.5	5	22.7		
Age of start of transfusion/mo						
Mean ± SD	69 ± 37.15		31.07 ± 28.17		t = 2.25	.04
Range	36–120 mo		5–84 mo			

SD = standard deviation, t = independent t test, χ<sup>2</sup> = Chi-square test.

**Table 4****Relationship between retinopathy and chelation characteristics of patients with SCD.**

Variables	Patients with retinopathy (n=8)		Patients without retinopathy (n=24)		Test	P-value
	N	%	N	%		
Chelation therapy						
Yes (n=19)	4	50.0	15	62.5	$\chi^2=0.21$	.648
No (n=13)	4	50.0	9	37.5		
Age of start chelation (yr)						
Mean $\pm$ SD	4.5 $\pm$ 2.12		4.9 $\pm$ 2.28		$t=0.24$	.84
Range	3–6 yr		2–10 yr			

SD = standard deviation,  $t$  = independent  $t$  test,  $\chi^2$  = Chi-square test.

In our study, there was no significant difference among sickle disease types in relation to BCVA.

In agreement with our study, Saidkasimova et al<sup>[24]</sup> in their largest study of ocular findings in SCD in the United Kingdom found that visual impairment was not related to hemoglobin genotype.

In our study 8 patients suffered from proliferative retinopathy, 4 of them had HbSS, 2 patients had HbS $\beta^+$ , and 2 patients had HbS $\beta^0$ .

Rosenberg and Hutcheson<sup>[25]</sup> found sickle retinopathy to occur more commonly among patients with HbSS, and Eruchalu et al<sup>[26]</sup> demonstrated that young children with HbSS with severe clinical symptoms can develop sight threatening retinopathy and this is in agreement with our study.

In contrast, Reynolds et al<sup>[27]</sup> and Gill and Lam<sup>[28]</sup> reported that although HbSS patients are associated with most acute life-threatening systemic manifestations, they have few ocular complications, while HbS $\beta^0$  patients have few systemic manifestations and severe ocular disease. This may be attributed to the rate of sickling, blood viscosity and hematocrit, which was explained by Luty and McLeod<sup>[29]</sup> that the hematocrit in HbS $\beta^0$  patients is significantly higher than in HbSS patients.

Tantawy et al<sup>[15]</sup> reported in their study bilateral retinal pigment epithelium mottling with abnormal vessel tortuosity in patients with SCD and represent some incriminated risk factors for such as HbSS, previous stroke, age of the patients, noncompliance with HU therapy, frequency of sickling crises and level of HbS, with no gender difference.

El-Ghamrawy et al<sup>[20]</sup> studied the frequency and pattern of ocular manifestations in Egyptian children and young adults with SCD. In this cross-sectional study, 40 patients aged 2 to 28 years (30 children and 10 young adults) with established diagnosis of SCD (26 with HbSS and 14 with HbS $\beta^0$ ) underwent complete ophthalmic examination with dilated funduscopy. FA was

performed for patients  $\geq 12$  years old. The overall frequency of retinal lesions was 47.5% (46.2 and 50% of HbSS and HbS $\beta^0$  patients, respectively).

In our study, there was no significant difference between different SCD types and frequency of VOC.

On the contrary, other studies reported that patients with homozygous sickle cell and sickle cell  $\beta^0$  thalassemia have a higher frequency of VOC than patients with hemoglobin SC and sickle cell  $\beta^+$  thalassemia genotype. This discrepancy can be attributed to small sample size in our study.<sup>[30,31]</sup>

Our study showed that there was no significant difference between SCD types in our patients with retinopathy and those without retinopathy regarding age and sex.

Downes et al<sup>[32]</sup> described the incidence, prevalence, and natural history of proliferative sickle cell retinopathy (PSR) and reported that PSR had developed in 59 patients (14 HbSS, 45 hemoglobin SC disease [Hb SC]). Incidence increased with age in both genotypes. Prevalence was greater in Hb SC disease, and by the ages of 24 to 26 years, PSR had occurred in 43% subjects with Hb SC disease and in 14% subjects with HbSS.

Eruchalu et al<sup>[33]</sup> found that sight threatening changes in the retina are a well-recognized complication of SCD. However, they usually occur in older patients with hemoglobin SC or S $\beta^+$  thalassemia patterns. It is rarely found under the age of 20 years in patients who are HbSS or S $\beta^0$  thalassemia. This is a report of sight threatening retinopathy in an 8-year-old male Nigerian patient with S $\beta^0$  thalassemia – one of the youngest reported cases to our knowledge. The patient had been diagnosed at birth and had his first ophthalmic examination done at 6 years of age when he developed an acute cerebral syndrome with transient blindness and hemiplegia.

In our study we did not find significant relation between retinopathy and demographic and clinical characteristics in patients with SCD.

**Table 5****Relationship between VOC and visual acuity, fluorescein angiography (FA), optical coherence tomography (OCT).**

Variables	Patients with VOC (n=26)	Patients without VOC (n=6)	Test	P-value
Best corrected visual acuity (BCVA)				
Right eye (OD) mean $\pm$ SD	0.76 $\pm$ 0.34	0.49 $\pm$ 0.39	MW=1.42	1.27
Left eye (OS) mean $\pm$ SD	0.74 $\pm$ 0.33	0.49 $\pm$ 0.39		
Fluorescein angiography (FA)				
Normal (n=14) (n, %)	10 (38.5)	4 (66.7)	$\chi^2=3.59$	.17
Tortuous retinal veins (n=10) (n, %)	10 (38.5)	0 (0.0)		
Proliferative retinopathy (n=8) (n, %)	6 (23)	2 (33.3)		
Optical coherence tomography (OCT)				
Macular thinning (n=32) (n, %)	26 (100.0)	6 (100.0)	Not applicable	

OD=oculus dextrus (right eye), OS=oculus sinister (left eye), MW=Mann-Whitney test, VOC=vaso-occlusive crisis,  $\chi^2$ =Chi-square test.

Similarly, Gill and Lam<sup>[28]</sup> determined the prevalence and age of onset of clinically significant retinopathy in such patients, and to recommend a screening strategy for ophthalmologists. They found no correlation between sickle retinopathy and the presence of systemic occlusive manifestations.

In contrast, Eruchalu et al<sup>[26]</sup> showed a significant retinal disease in children as young as 8 years. In addition, sickle retinopathy was correlated with frequency of pain crises, history of stroke and irregular use of HU therapy, in agreement with Rosenberg and Hutcheson,<sup>[25]</sup> who correlated sickle retinopathy with frequency of crises but not with the frequency of cerebrovascular accident.

On the contrary, in a retrospective review of 258 children with SCD, 54 children with sickle cell retinopathy were identified and compared with age matched controls. Rosenberg and Hutcheson<sup>[25]</sup> noted the following factors significantly correlated with retinopathy: pain crisis, male gender, splenic sequestration.

Our results showed that SCD patients with retinopathy started transfusion at a significantly delayed age compared to those without retinopathy.

This finding should be read in the light of what is commonly known about the protective role of chronic blood transfusion in reducing the complications of SCD especially cerebrovascular and retinal complications.

## 8. Conclusions

We concluded that ocular manifestations and retinopathy were more prevalent in patients with SCD than expected and it correlated with frequent sickling crises and higher HbS level. More close observations and follow up is strongly needed.

## 9. Limitations

Limitations of this study were small sample size and patients were from limited geographical areas and not representing whole Egypt. Larger multicenter studies are still needed to support these findings.

## Acknowledgments

The authors thank studied patients for their great cooperation throughout study phases.

## Author contributions

**Conceptualization:** Tamer Hassan, Mohamed Badr, Sherief Dabour.

**Data curation:** Tamer Hassan, Mohamed Badr, Sherief Dabour.

**Formal analysis:** Tamer Hassan, Mohamed Badr, Sherief Dabour.

**Investigation:** Tamer Hassan, Mohamed Badr, Diana Hanna, Mohamed Arafa, Ahmed Elhewala, Sherief Dabour, Saad Shehata, Doaa Abdel Rahman.

**Methodology:** Tamer Hassan, Mohamed Badr, Diana Hanna, Mohamed Arafa, Ahmed Elhewala, Saad Shehata, Doaa Abdel Rahman.

**Resources:** Tamer Hassan, Mohamed Badr, Diana Hanna, Mohamed Arafa, Ahmed Elhewala, Saad Shehata, Doaa Abdel Rahman.

**Supervision:** Tamer Hassan, Mohamed Badr.

**Validation:** Tamer Hassan, Mohamed Badr.

**Visualization:** Tamer Hassan, Mohamed Badr.

**Writing – original draft:** Tamer Hassan, Mohamed Badr, Diana Hanna, Mohamed Arafa, Ahmed Elhewala, Sherief Dabour, Saad Shehata, Doaa Abdel Rahman.

**Writing – review & editing:** Tamer Hassan, Mohamed Badr.

## References

- [1] Weatherall DJ. The inherited diseases of hemoglobin are an emerging global health burden. *Blood* 2010;115:4331–6.
- [2] Bonanomi MT, Lavezzo MM. Sickle cell retinopathy: diagnosis and treatment. *Arq Bras Oftalmol* 2013;76:320–7.
- [3] Levezuel N, Bastuji-Garin S, Lalloum F, et al. Clinical and laboratory factors associated with the severity of proliferative sickle cell retinopathy in patients with sickle cell hemoglobin C (SC) and homozygous sickle cell (SS) disease. *Medicine* 2011;90:372–8.
- [4] Elagou M, Jyothi S, Gupta B, et al. Sickle cell disease and the eye: old and new concepts. *Surv Ophthalmol* 2010;55:359–77.
- [5] Stone EM, Aldave AJ, Drack AV, et al. Recommendations for genetic testing of inherited eye diseases: report of the American Academy of Ophthalmology task force on genetic testing. *Ophthalmology* 2012;119:2408–10.
- [6] Halperin LS, Olk RJ, Soubrane G, et al. Safety of fluorescein angiography during pregnancy. *Am J Ophthalmol* 1990;109:563–6.
- [7] Butner RW, McPherson AR. Adverse reactions in intravenous fluorescein angiography. *Ann Ophthalmol* 1983;15:1084–6.
- [8] Yannuzzi LA, Rohrer KT, Tindel LJ, et al. Fluorescein angiography complication survey. *Ophthalmology* 1986;93:611–7.
- [9] Bezerra HG, Costa MA, Guagliumi G, et al. Intracoronary optical coherence tomography: a comprehensive review clinical and research applications. *JACC Cardiovasc Interv* 2009;2:1035–46.
- [10] Chua S. High-definition optical coherence tomography for the study of evolution of a disease. *Dermatol Bull* 2015;26:2–3.
- [11] Omolase BO, Paul-Odo B, Omolase C. Ocular findings of sickle cell eye disease patients in Owo: an exploratory study. *World Fam Med J* 2010;8:7–9.
- [12] Fadugbagbe AO, Gurgel RQ, Mendonça CQ, et al. Ocular manifestations of sickle cell disease. *Ann Trop Paediatrics* 2010;30:19–26.
- [13] Osafo-Kwaako A, Kimani K, Ilako D, et al. Ocular manifestations of sickle cell disease at the Korle-bu Hospital, Accra, Ghana. *Eur J Ophthalmol* 2011;21:484–9.
- [14] Hankins JS, Fortner GL, McCarville MB, et al. The natural history of conditional transcranial Doppler flow velocities in children with sickle cell anemia. *Br J Haematol* 2008;142:94–9.
- [15] Tantawy AA, Andrawes NG, Adly AA, et al. Retinal changes in children and adolescents with sickle cell disease attending a paediatric hospital in Cairo, Egypt: risk factors and relation to ophthalmic and cerebral blood flow. *Trans R Soc Trop Med Hyg* 2013;107:205–11.
- [16] Asbeutah A, Gupta R, Al-Saeid O, et al. Transcranial Doppler and brain MRI in children with sickle cell disease and high hemoglobin F levels. *Pediatric Blood Cancer* 2014;61:25–8.
- [17] da Silva Filho IL, Ribeiro GS, Moura PG, et al. Sickle cell disease: acute clinical manifestations in early childhood and molecular characteristics in a group of children in Rio de Janeiro. *Rev Brasil Hematol Hemoterap* 2012;34:196–201.
- [18] Wanko SO, Telen MJ. Transfusion management in sickle cell disease. *Hematol Oncol Clin* 2005;19:803–26.
- [19] Enniful-Eghan H, Moore RH, Ichord R, et al. Transcranial Doppler ultrasonography and prophylactic transfusion program is effective in preventing overt stroke in children with sickle cell disease. *J Pediatrics* 2010;157:479–84.
- [20] El-Ghamrawy MK, El Behairy HF, El Menshawy A, et al. Ocular manifestations in Egyptian children and young adults with sickle cell disease. *Indian J Hematol Blood Transfus* 2014;30:275–80.
- [21] Moriarty BJ, Acheson RW, Condon P, et al. Patterns of visual loss in untreated sickle cell retinopathy. *Eye* 1988;2:330.
- [22] Martin GC, Dénier C, Zambrowski O, et al. Visual function in asymptomatic patients with homozygous sickle cell disease and temporal macular atrophy. *JAMA Ophthalmol* 2017;135:1100–5.
- [23] Van Meurs JC. Relationship between peripheral vascular closure and proliferative retinopathy in sickle cell disease. *Graefes Arch Clin Exp Ophthalmol* 1991;29:543–8.



- [24] Saidkasimova S, Shalchi Z, Mahroo OA, et al. Risk factors for visual impairment in patients with sickle cell disease in London. *Eur J Ophthalmol* 2016;26:431–5.
- [25] Rosenberg JB, Hutcheson KA. Pediatric sickle cell retinopathy: correlation with clinical factors. *J AAPOS* 2011;15:49–53.
- [26] Eruchalu UV, Pam VA, Akuse RM. Ocular findings in children with severe clinical symptoms of homozygous sickle cell anemia in Kaduna, Nigeria. *West Afr J Med* 2006;25:88–92.
- [27] Reynolds SA, Besada E, Winter-Corella C. Retinopathy in patients with sickle cell trait. *Optometry* 2007;78:582–7.
- [28] Gill HS, Lam WC. A screening strategy for the detection of sickle cell retinopathy in pediatric patients. *Can J Ophthalmol* 2008;43:188–91.
- [29] Luty GA, McLeod DS, Penn J. *Angiogenesis in sickle cell retinopathy. Retinal and Choroidal Angiogenesis* Dordrecht: Springer; 2008;389–405.
- [30] Platt OS, Thorington BD, Brambilla DJ, et al. Pain in sickle cell disease. Rates and risk factors. *N Engl J Med* 1991;325:11–6.
- [31] Nagel RL. Sickle cell anemia is a multigene disease: sickle painful crises, a case in point. *Am J Hematol* 1993;42:96–101.
- [32] Downes SM, Hambleton IR, Chuang EL, et al. Incidence and natural history of proliferative sickle cell retinopathy: observations from a cohort study. *Ophthalmology* 2005;112:1869–75.
- [33] Eruchalu UV, Pam VA, Akuse RM. Sight threatening retinopathy in an eight years old Nigerian male with sickle cell  $\beta^0$  thalassemia: case report. *Ann Afr Med* 2004;3:141–3.