



RESEARCH ARTICLE

REVISED Structural brain abnormalities in 12 persons with aniridia
[version 2; referees: 2 approved]

Madison K. Grant ¹, Anastasia M. Bobilev², Jordan E. Pierce³, Jon DeWitte⁴,
James D. Lauderdale^{1,2}

¹Department of Cellular Biology, University of Georgia, Athens, GA, 30602, USA

²Neuroscience Division of the Biomedical and Health Sciences Institute, University of Georgia, Athens, GA, 30602, USA

³Department of Psychology, University of Georgia, Athens, GA, 30602, USA

⁴Athens Radiology Associates, Athens, GA, 30604, USA

v2 First published: 13 Mar 2017, 6:255 (doi: [10.12688/f1000research.11063.1](https://doi.org/10.12688/f1000research.11063.1))
Latest published: 01 Sep 2017, 6:255 (doi: [10.12688/f1000research.11063.2](https://doi.org/10.12688/f1000research.11063.2))

Abstract

Background: Aniridia is a disorder predominately caused by heterozygous loss-of-function mutations of the *PAX6* gene, which is a transcriptional regulator necessary for normal eye and brain development. The ocular abnormalities of aniridia have been well characterized, but mounting evidence has implicated brain-related phenotypes as a prominent feature of this disorder as well. Investigations using neuroimaging in aniridia patients have shown reductions in discrete brain structures and changes in global grey and white matter. However, limited sample sizes and substantive heterogeneity of structural phenotypes in the brain remain a challenge. **Methods:** Here, we examined brain structure in a new population sample in an effort to add to the collective understanding of anatomical abnormalities in aniridia. The current study used 3T magnetic resonance imaging to acquire high-resolution structural data in 12 persons with aniridia and 12 healthy demographically matched comparison subjects. **Results:** We examined five major structures: the anterior commissure, the posterior commissure, the pineal gland, the corpus callosum, and the optic chiasm. The most consistent reductions were found in the anterior commissure and the pineal gland; however, abnormalities in all of the other structures examined were present in at least one individual. **Conclusions:** Our results indicate that the anatomical abnormalities in aniridia are variable and largely individual-specific. These findings suggest that future studies investigate this heterogeneity further, and that normal population variation should be considered when evaluating structural abnormalities.

Open Peer Review

Referee Status:

	Invited Referees	
	1	2
REVISED		
version 2		report
published		
01 Sep 2017		
version 1		
published	report	report
13 Mar 2017		

- 1 **Veronica van Heyningen**, University College London, UK
- 2 **Lutz Jäncke**, University of Zurich, Switzerland

Discuss this article

Comments (0)

Corresponding author: James D. Lauderdale (jdlauder@uga.edu)

Author roles: **Grant MK:** Data Curation, Formal Analysis, Investigation, Methodology, Validation, Visualization, Writing – Original Draft Preparation, Writing – Review & Editing; **Bobilev AM:** Conceptualization, Data Curation, Funding Acquisition, Supervision, Visualization, Writing – Original Draft Preparation, Writing – Review & Editing; **Pierce JE:** Data Curation, Formal Analysis, Methodology, Visualization, Writing – Review & Editing; **DeWitte J:** Investigation, Writing – Review & Editing; **Lauderdale JD:** Conceptualization, Data Curation, Funding Acquisition, Project Administration, Supervision, Writing – Review & Editing

Competing interests: No competing interests were disclosed.

How to cite this article: Grant MK, Bobilev AM, Pierce JE *et al.* **Structural brain abnormalities in 12 persons with aniridia [version 2; referees: 2 approved]** *F1000Research* 2017, **6**:255 (doi: [10.12688/f1000research.11063.2](https://doi.org/10.12688/f1000research.11063.2))

Copyright: © 2017 Grant MK *et al.* This is an open access article distributed under the terms of the [Creative Commons Attribution Licence](#), which permits unrestricted use, distribution, and reproduction in any medium, provided the original work is properly cited. Data associated with the article are available under the terms of the [Creative Commons Zero "No rights reserved" data waiver](#) (CC0 1.0 Public domain dedication).

Grant information: This research was supported by a grant from the Sharon Stewart Aniridia Research Trust to AMB and JDL. *The funders had no role in study design, data collection and analysis, decision to publish, or preparation of the manuscript.*

First published: 13 Mar 2017, **6**:255 (doi: [10.12688/f1000research.11063.1](https://doi.org/10.12688/f1000research.11063.1))

REVISED Amendments from Version 1

We would like to thank our reviewers for their insightful comments and suggestions that contributed towards an improvement of the manuscript. Specific details of the changes can be found in our response to reviewers. Significant changes include:

1) amendments to the identification system for the patients to reflect the same numbering used in a previously published paper on this group of patients; 2) an added supplementary table (Supplementary Table 2) to allow for identification of each patient and their corresponding DICOM file; 3) addition of predicted protein effects for each mutation in Table 1; 4) the addition of a quantitative analysis of corpus callosum volume, total white and grey matter volume, and whole brain volume (Supplementary Table 1 and Supplementary Figure 1) for aniridia and PAX6-normal comparisons.

See referee reports

Introduction

Aniridia is panocular, congenital, and progressive disorder with an occurrence of approximately 1 in 83,000 live births^{1,2}. Aniridia is best characterized by the lack of or hypoplasia of the iris (for which it is named), in addition to several other ocular abnormalities, which culminate in reduced visual acuity³. Due to the progressive nature of the disease, individuals usually develop multiple ocular abnormalities, such as keratopathy, corneal vascularization and opacification, glaucoma, anterior chamber fibrosis, and cataracts⁴⁻⁷. Although aniridia is most well known for its ocular phenotypes, the condition has a number of other abnormalities, including sensory, neural, cognitive, and auditory processing abnormalities^{8,9}.

The development of aniridia in humans is linked to heterozygous loss-of-function mutations to the *PAX6* gene, which encodes a highly conserved transcription factor critical for normal eye and neural development¹. The vast majority of aniridia cases (80%) are associated with mutations in *PAX6*^{2,10}. Functional mutations in this gene can be either sporadic or familial, and causal mutations in aniridia encompass a large number of variants. The majority of these variants are nonsense mutations, which lead to a premature termination codon, and are found across the *PAX6* locus^{10,11}. *PAX6* is expressed in the developing eye, brain, and spinal cord, and is required for aspects of anatomical and functional development of the central nervous system (CNS) and visual system¹². Within the CNS, *PAX6* is involved in patterning, regionalization, and the formation of neural circuits¹³⁻¹⁶. Previous studies of patients with aniridia using structural magnetic resonance imaging (MRI) have shown abnormalities in major fiber tracts and subcortical structures of the brain, including the anterior commissure^{9,17-20}, posterior commissure^{18,20}, corpus callosum^{9,19,20}, pineal gland^{18,20}, optic chiasm²⁰, and olfactory bulb^{17,18}. The most consistently reported abnormalities are found in the anterior commissure, pineal gland, and optic chiasm; abnormalities in the posterior commissure, corpus callosum, and olfactory bulb are found in fewer than 35% of patients examined. Additionally, studies have shown conflicting results regarding grey matter volume differences in aniridia, with reports of both increases and decreases in whole brain grey matter^{21,22}. Most recently, it has been shown that there

is an accelerated age-related increase in cortical thinning of the inferior parietal lobe and prefrontal/premotor areas in both brain hemispheres in aniridia compared to healthy patients²³.

While several previous studies have investigated structural brain abnormalities in patients with aniridia, the variance in brain structures affected and extent of anatomical abnormalities is high. The variance observed in the published literature may be interpreted as a result of genetic differences in patient samples, either directly related to disease-causing mutations or modifier effects caused by genomic differences across subjects. Most of the previous studies examining structural changes in the brain of aniridia patients have focused on a subset of the structures we examined, but only one other study has looked at all five together²⁰. Additionally, we used a 3T magnet instead of a 1.5T, which allows for higher resolution structural images of small structures such as interhemispheric commissures, allowing us to more reliably identify subtle difference. The current study sought to investigate gross anatomical correlates of aniridia in a new population sample with varied *PAX6* mutations. Results from this study will serve as a comparison for previous studies, as well as contribute to what is known about the distribution of neuroanatomical phenotypes in the aniridia population as a whole. Overall, this will serve to clarify the extent of abnormalities in five brain structures in persons with aniridia with varied mutations to the *PAX6* gene and contribute to our global understanding of the neuroanatomical characteristics of the disorder.

Methods

Subjects

A total of 14 individuals with aniridia and 15 healthy comparison individuals participated in the current study. Data from two participants with aniridia were excluded from analyses (due to a significant artifact and missing data). One healthy subject was excluded due to an anatomical abnormality, and two others were excluded because they did not match the demographic profile of an individual in the aniridia group included in the analysis. The remaining 12 individuals with aniridia (7 females; 3 left handed; mean age=36 years, SD=15) and 12 age- and gender-matched comparisons (7 females; 4 left handed; mean age=35 years, SD=14) were included in the analyses (Table 1). Healthy comparison subjects were recruited through flyers posted in the community. Participants with aniridia were recruited through the Aniridia Foundation International Conference held in 2011 in Athens, Georgia and had been clinically diagnosed with aniridia. Exonic sequencing of the *PAX6* gene (11p13) (OMIM: 607108) was conducted at the University of Georgia, as previously described^{10,24}. All mutations, which can be found in Table 1, have been submitted to the Human *PAX6* Allelic Variant Database (http://lsdb.hgu.mrc.ac.uk/home.php?select_db=PAX6), as part of a previous genotype identification study¹⁰. Three of the participants with aniridia belonged to the same family, and all other participants included in the analyses were unrelated. After written informed consent was obtained and MRI safety screening was conducted, all participants completed an MRI session in which a high-resolution structural scan was obtained. The Institutional Review Board of the University of Georgia approved all activities prior to subject recruitment, data collection, and data analysis (project number: 2011-10862-1; STUDY00003122).

Table 1. ANIRIDIA. Subject demographics and structural abnormalities as seen in structural magnetic resonance images. Gender, age, handedness, mutation, and structural abnormalities of both aniridia subjects and healthy comparisons. Subject ID: Numbers are matched subjects, A refers to aniridia subjects, C refers to healthy comparisons. ND, not determined.

ANIRIDIA										
Subject ID	Gender	Age	Handedness	Mutation	Predicted Mutation Effect	Anterior Commissure	Posterior Commissure	Pineal Gland	Corpus Callosum	Optic Chiasm
1A	Male	18	Right	c.949C>T	Nonsense	Reduced	Normal	Reduced	Normal	Reduced
2A	Female	19	Ambidextrous	c.771delG	Frameshift deletion	Reduced	Normal	Reduced	Slightly reduced	Reduced
3A*	Male	20	Right	c.204delC	Frameshift deletion	Reduced	Normal	Reduced	Normal	Reduced
4A*	Female	24	Left	c.204delC	Frameshift deletion	Reduced	Reduced	Reduced	Normal	Reduced
5A	Female	25	Left	ND	ND	Reduced	Reduced center	Highly reduced	Normal	Reduced
6A	Female	28	Right	c.28C>T	Nonsense	Reduced	Normal	Absent	Slightly reduced	Normal
7A	Male	39	Right	c.482delG	Frameshift deletion	Reduced	Normal	Reduced	Normal	Normal
8A	Male	47	Right	ND	ND	Reduced	Normal	Reduced	Normal	Normal
9A*	Male	46	Left	c.204delC	Frameshift deletion	Reduced	Normal	Reduced	Normal	Reduced
10A	Female	51	Right	c.766-3C>G	Splice junction disruption	Reduced	Reduced	Absent	Normal	Normal
11A	Female	53	Right	ND	ND	Reduced	Reduced	Reduced	Normal	Normal
12A	Female	60	Ambidextrous	c.799A>T	Nonsense	Reduced	Reduced	Reduced	Slightly reduced	Reduced

* Indicates individuals from a single family

PAX6 NORMAL										
Subject ID	Gender	Age	Handedness	Mutation	Predicted Mutation Effect	Anterior Commissure	Posterior Commissure	Pineal Gland	Corpus Callosum	Optic Chiasm
1C	Male	18	Right	PAX6 Normal	N/A	Normal	Normal	Normal	Normal	Normal
2C	Female	20	Right	PAX6 Normal	N/A	Normal	Normal	Normal	Normal	Normal
3C	Male	21	Right	PAX6 Normal	N/A	Normal	Normal	Slightly Reduced	Normal	Normal
4C	Female	22	Left	PAX6 Normal	N/A	Normal	Normal	Normal	Normal	Normal
5C	Female	23	Left	PAX6 Normal	N/A	Normal	Normal	Normal	Normal	Normal
6C	Female	28	Left	PAX6 Normal	N/A	Normal	Normal	Normal	Normal	Normal
7C	Male	37	Right	PAX6 Normal	N/A	Normal	Normal	Normal	Normal	Normal
8C	Male	50	Right	PAX6 Normal	N/A	Normal	Normal	Normal	Normal	Normal
9C	Male	50	Left	PAX6 Normal	N/A	Reduced	Normal	Normal	Normal	Normal
10C	Female	48	Right	PAX6 Normal	N/A	Reduced	Reduced	Absent	Normal	Normal
11C	Female	51	Right	PAX6 Normal	N/A	Normal	Normal	Reduced	Normal	Normal
12C	Female	56	Right	PAX6 Normal	N/A	Normal	Normal	Reduced	Normal	Normal

MRI data acquisition

All data were collected on a 3T GE Signa MRI (General Electric, Milwaukee, WI, USA) at the University of Georgia's Bio-Imaging Research Center. To obtain a high-resolution structural scan, images were acquired with a T1-weighted 3D FSPGR sequence [echo time (TE)=min full, flip angle=20°; field of view (FOV)=240 mm × 240 mm; matrix size=256 × 256, 150 axial slices; in-slice resolution=0.94 × 0.94 mm; slice thickness=1.2 mm].

MRI structural analysis

MR images were transferred to a DICOM image format and analyzed using two software programs, SPM run on MATLAB and OsiriX. For SPM analysis, DICOM files were converted to nifti format and analyzed using Statistical Parametric Mapping Software (SPM8; Wellcome Trust Centre for Neuroimaging; <http://www.fil.ion.ucl.ac.uk/spm/>) run on a MATLAB software platform (MATLAB Release 2015b; The Mathworks, Inc., Natick, MA, USA). SPM software was used to compare aniridia subjects to their demographically matched comparison subjects. DICOM files were additionally analyzed using OsiriX Lite DICOM viewer (OsiriX v5.6.; Pixmeo SARL, Bernex, Switzerland) and all images generated using this software. All 24 individual subjects' data were visually inspected for gross anatomical abnormalities in two independent sessions by the first author (MG) and a radiologist (JDW). Regions of interest were determined by literature review to include the anterior commissure, posterior commissure, pineal gland, corpus callosum, and optic chiasm. The only structure that has been examined in the literature that we did not examine in our population was the olfactory bulb. This structure was excluded because both evaluators independently determined that the olfactory bulb could not be reliably assessed in the current data set. The radiologist was blinded to patient status and genotype during visual examination of scans. No new regions of interest were determined during both the first and second examination of the scans.

Corpus callosum quantitative analysis

Following the approach of Free and colleagues (2003), the cross-sectional area of the corpus callosum was quantified at the mid-sagittal plane²¹. In order to align all MR images to the mid-sagittal plane, individual T1 images were reconstructed in AFNI software²⁵ and aligned manually using the anterior commissure, posterior commissure, and interhemispheric landmarks. On the mid-sagittal image, the corpus callosum was manually traced and the number of voxels within this delineation was counted. Additionally, the structural volumes were automatically segmented with FreeSurfer software (<http://surfer.nmr.mgh.harvard.edu>) to obtain estimates of total grey and white matter volume^{26,27}. The ratio of corpus callosum area to total cerebral volume was calculated to control for differences in overall brain size (see [Supplementary Figure 1](#) "Ratio"). [Supplementary Figure 1](#) graphs were created using GraphPad Prism 7 software (<https://www.graphpad.com/>).

Results

Whole brain analysis was used to identify major structural abnormalities in aniridia patients. All neuroanatomical results are reported in [Table 1](#), which includes subject demographics and mutations. We analyzed five major brain structures that demonstrate clear anatomical abnormalities in aniridia patients. Our study showed that all 12 aniridia patients had a reduced anterior commissure when compared to their demographically matched healthy comparisons, as shown in [Figure 1](#). The posterior commissure was reduced in 5/12 aniridia patients and normal in 7/12 of aniridia patients ([Figure 1](#)). Of the five aniridia patients with reduced posterior commissures, one had a reduced commissure at the midline. The pineal gland was affected in all 12 aniridia patients: absent in two ([Figure 1](#)), highly reduced in one, and reduced in nine. The corpus callosum was slightly thinned in 3/12 aniridia patients and normal in 9/12 aniridia patients ([Figure 2](#)). The optic chiasm was reduced in 7/12 of patients ([Figure 2](#)) and normal in 5/12 patients.

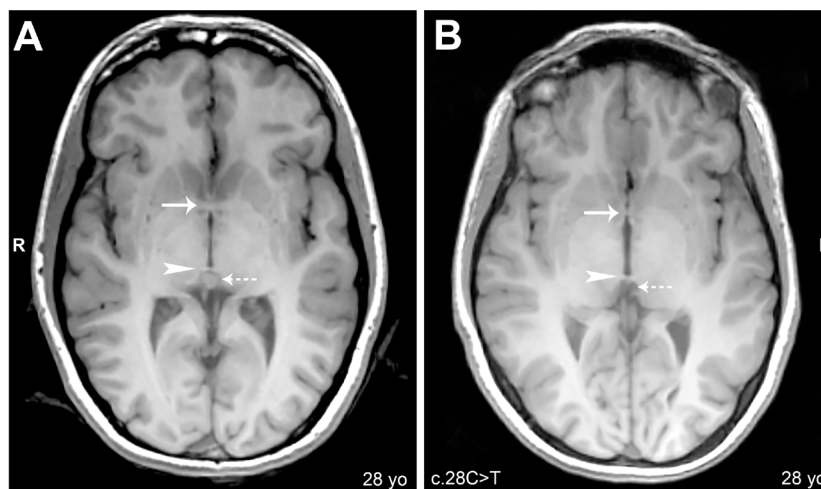


Figure 1. Anterior commissure, posterior commissure, and pineal gland: Axial cerebral T1-weighted magnetic resonance images, slice thickness 1.2mm. (A) Subject 6C: Arrow shows normal anterior commissure; arrowhead shows normal posterior commissure; dashed arrow shows normal pineal gland. (B) Subject 6A: Arrow shows reduced anterior commissure; arrowhead shows normal posterior commissure; dashed arrow shows absence of pineal gland.

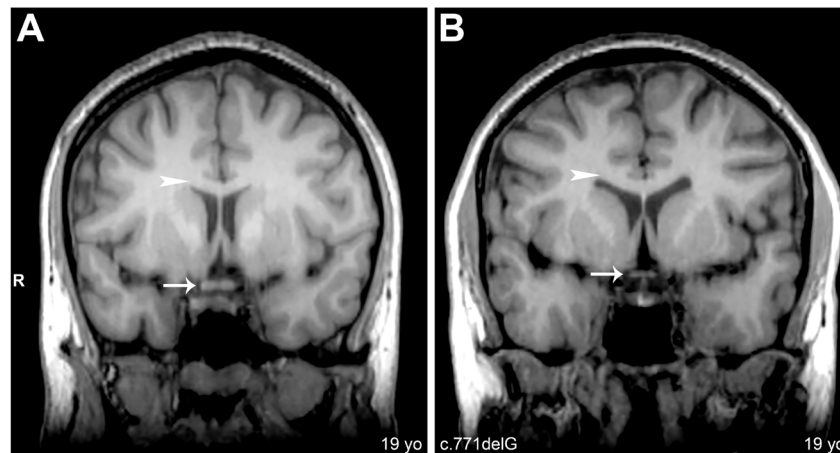


Figure 2. Optic chiasm and corpus callosum: Coronal cerebral T1-weighted magnetic resonance images, slice thickness 1.2mm. (A) Subject 2C: Arrow shows normal optic chiasm. (B) Subject 2A: Arrow shows reduced optic chiasm. Arrowheads in A and B denote normal corpus callosum.

In an effort to consider normal structural variation in the healthy population, we also evaluated healthy comparisons for structural brain abnormalities. We saw a reduced anterior commissure in two of the healthy comparisons and a reduced posterior commissure in one healthy comparison. The pineal gland showed the most variance within the healthy comparison group with one subject with no visible pineal gland, three healthy comparisons with slightly reduced to reduced pineal glands, and eight healthy comparisons with normal pineal glands. All healthy comparisons had normal corpus callosums and optic chiasms. A full description of which structures showed abnormalities in both the aniridia and healthy comparison groups are reported in [Table 1](#). These findings provide context for asserting disease-related changes in the aniridia population, in the current study as well as others.

Additionally, we examined corpus callosum area at the mid-sagittal plane along with grey matter, white matter, and whole brain volume in our aniridia and healthy comparison groups. Grey matter volume and total brain volume averages are indistinguishable between aniridia and healthy comparison subjects. There is a slight reduction in the aniridia patients compared to healthy individuals in average corpus callosum area as well as white matter volume and ratio of corpus callosum area to whole brain volume. However, these are just trends and no measurement was statistically significant, which can also be explained by a high degree of variability within the aniridia population. Volumetric and area measurements along with graphical representations of the data can be seen in [Supplementary Table 1](#) and [Supplementary Figure 1](#).

Dataset 1. Aniridia and healthy comparison MRI data

<http://dx.doi.org/10.5256/f1000research.11063.d153799>

Structural MRI DICOM files for 12 aniridia and 12 healthy comparison individuals. Files are in DICOM format and labeled according to subject I.D. found in [Table 1](#). These files can be opened using SPM software run in Matlab or OsiriX DICOM viewer (see Methods section).

Discussion

The most commonly reported neuroanatomical abnormality in MRI studies of aniridia patients is the anterior commissure. Previous studies have reported changes in the anterior commissure with some cases described as reductions and others reported as complete absence of the structure^{9,17–19}. Consistent with these reports, our study identified a reduction in the anterior commissure in all 12 aniridia patients, but none of the patients lacked the structure. The posterior commissure has also been evaluated in previous studies: one study reports that it is present in all subjects while the other study presented evidence that one patient had an absent structure while the others had normal posterior commissures^{18,20}. We found no individuals lacking the posterior commissure, and fewer than half of our aniridia patients seemed to have an abnormal structure. Interestingly though, it seems as if one patient exhibited a reduction of the posterior commissure at the midline with thickened bundles adjacent to the midline suggesting that commissure formation was incomplete. PAX6 has a known role in formation of the posterior commissure in rodents, so it is likely that this phenotype in humans is a direct consequence of PAX6 deficiency¹⁵. In agreement with previous findings, we also see abnormal or absent pineal glands in our entire patient population. This finding is consistent with sleep regulation deficits in persons with aniridia reported in other studies²⁸. The corpus callosum has also been a structure commonly evaluated in aniridia MRI studies, with many reporting reductions in corpus callosum thickness and severe agenesis^{9,19,20}. However, we found very few patients present with a reduced or abnormal corpus callosum, and propose that the slight reduction we see in three of our patients falls within normal population variation. Unlike most previous studies, we examined the optic chiasm, and found a reduction in the structure in more than half of our patients. This reduction could be a developmental consequence of the disorder or a progressive phenotype associated with reduced levels of PAX6. Anatomical abnormality findings seem to be highly dependent on population sample, and a larger collective sample in the literature will help us get closer to understanding common disease traits and variation.

As described above, we observed a reduction in the anterior commissure in every patient we evaluated and a reduction of the posterior commissure in five patients, but no individuals completely lacked either structure. Our study utilized a high resolution 3T MRI for data acquisition, while most other studies used a 1.5T MRI. Signal to noise ratio from 3T MRIs are almost double that of 1.5T MRIs, which will lead to an improved image quality and resolution from the 3T magnet²⁹. We propose that the difference in observing a reduced versus absent anterior/posterior commissure may be due to a difference in scan resolution between images captured from a 3T versus 1.5T magnet. We see multiple patients in our group who have a severely reduced anterior commissure, and identifying this abnormality using a 1.5T magnet may be more difficult than when using a 3T. Additionally, the posterior commissure is smaller than the anterior commissure naturally, making it more difficult to distinguish between presence and absence in a scan. Lower scan resolution may not capture small structures such as these commissures, especially if they are reduced in size, leading to a false judgment of their absence.

A recent study has found an age component to cortical thickness in aniridia patients when compared to healthy individuals. The study found that in patients with aniridia there is an accelerated reduction in cortical thickness of the inferior parietal lobe and prefrontal/premotor areas in both brain hemispheres²³. Adding to this age component seen in the Yogarajah (2016) study, there are also population differences in brain anatomy, even within healthy groups, between younger subjects and older subjects³⁰. Additionally, as we show in our study, there are anatomical abnormalities even within healthy, unaffected participants. This makes it vitally important for careful selection of comparison subjects, and presents a caveat for interpreting differences we see in this and other clinical populations.

In addition to abnormal structural findings in patient populations with aniridia, multiple studies have assessed volumetric differences in grey and white matter in the brains of aniridia versus healthy comparisons. Similar to the findings in gross structural differences, much variation exists between reports. Some studies show an increase in grey matter volume in aniridia patients compared to healthy control groups, while others find both increases and decreases depending on brain region^{21,22}. Changes in white matter findings follow the same suit with some reports of reductions in white matter and others finding both reductions and increases^{21,22}. Even more interestingly, structures, such as the anterior commissure, posterior commissure, and pineal gland, show no deviation from healthy in these group-wise comparisons. This suggests that either the abnormalities seen in these structures are not as common among aniridia patients as previously thought, or that the characteristics of anatomical changes observed in aniridia patients have a high degree of variability within the population. Due to the consistency of abnormalities in structures like the anterior commissure in our study, as well as others, we predict the latter explains this discrepancy. This explanation is supported by the consistency of our results from volumetric and visual inspection of the corpus callosum in the current dataset. It is also possible that the differences observed across and within studies of these structures are a result of scan resolution and inconsistency of structure localization or plane of imaging to capture them given their small size and overall individual anatomical variation.

Conclusions

The current study investigated anatomical brain abnormalities correlated to aniridia in a new population sample in an effort to serve as a comparison to previous studies. Our aim was to contribute to what is known about the distribution of neuroanatomical phenotypes in the aniridia population as a whole. Although we found similar neuroanatomical abnormalities as previous studies, we find the severity is not as great as previously reported. The anterior commissure and pineal gland seem to be the structures most affected in the aniridia patients we examined, and we do see abnormalities in the posterior commissure, corpus callosum and the optic chiasm, albeit at lower frequency than previously reported. We believe the neuroanatomical abnormalities seen in aniridia populations have a high level of variability, and future studies should be aimed at collecting more patient MRI scans so that the breadth of abnormalities can be assessed.

Ethical approval and consent

MRI sessions were completed after written informed consent was obtained and MRI safety screening was completed. All activities were approved by the Institutional Review Board of the University of Georgia prior to subject recruitment and data collection. All individuals who participated in this study provided consent for their demographic, mutation information, and images to be published.

Data availability

Dataset 1: Aniridia and healthy comparison MRI data: Structural MRI DICOM files for 12 aniridia and 12 healthy comparison individuals. Files are in DICOM format and labeled according to subject I.D. found in Table 1. These files can be opened using SPM software run in Matlab or OsiriX DICOM viewer (see Methods section). doi, [10.5256/f1000research.11063.d153799](https://doi.org/10.5256/f1000research.11063.d153799)³¹

Mutation information that has been presented here is also available through PAX6 Allelic Variant Database (http://lsdb.hgu.mrc.ac.uk/home.php?select_db=PAX6).

Author contributions

AMB and JDL conceived this study as part of a large neuroimaging effort in this clinical population. JEP provided technical expertise on MRI imaging and data acquisition, and assisted AMB with experimental design and data collection. MKG analyzed the data first followed by JDW, who analyzed the data second (independently) to determine structural abnormalities in each brain. MKG and AMB prepared the first draft of the manuscript. All authors were involved in the revisions of the draft manuscript and have agreed to the final content.

Competing interests

No competing interests were disclosed.

Grant information

This research was supported by a grant from the Sharon Stewart Aniridia Research Trust to AMB and JDL.

The funders had no role in study design, data collection and analysis, decision to publish, or preparation of the manuscript.

Acknowledgements

AMB is a Franklin Foundation Neuroimaging Fellow and an ARCS Scholar.

Collection of magnetic resonance imaging data was made possible by the University of Georgia Bioimaging Research Center. J. Branson

Byers participated as an undergraduate researcher through the Center for Undergraduate Research Opportunities at the University of Georgia. The authors wish to thank Ms. Kimberly Mason for her assistance with data collection and subject screening, Ms. Jill Nerby, Director and Founder of Aniridia Foundation International, and the participants in this study for their support of this research.

Supplementary Material

Supplementary Table 1. Subject corpus callosum area and brain volume measurements. Grey matter volume, white matter volume, total brain volume, and corpus callosum area of aniridia and matched subjects. Ratio refers to corpus callosum area/total brain volume. Subject ID: Numbers are matched subjects, A refers to aniridia subjects, C refers to healthy comparisons.

ANIRIDIA					
Subject ID	Grey Matter Volume (mm ³)	White Matter Volume (mm ³)	Total Volume (mm ³)	Corpus Callosum Area (mm ²)	Ratio: CC area/total volume
1A	795957	654158	1450115	774	0.000534
2A	711626	604800	1316426	552	0.000419
3A*	683393	585559	1268952	712	0.000561
4A*	568045	505360	1073405	584	0.000544
5A	595209	573664	1168873	648	0.000554
6A	543481	496139	1039620	542	0.000521
7A	602438	545307	1147745	566	0.000493
8A	646003	616039	1262042	732	0.00058
9A*	621706	607971	1229677	684	0.000556
10A	533370	495092	1028462	713	0.000693
11A	623640	592662	1216302	652	0.000536
12A	528675	489748	1018423	555	0.000545

* Indicates individuals from a single family

PAX6 NORMAL					
Subject ID	Grey Matter Volume (mm ³)	White Matter Volume (mm ³)	Total Volume (mm ³)	Corpus Callosum Area (mm ²)	Ratio: CC area/total volume
1C	653601	568784	1222385	685	0.00056
2C	600216	547621	1147837	653	0.000569
3C	710079	668109	1378188	657	0.000477
4C	611409	542922	1154331	643	0.000557
5C	605760	545683	1151443	883	0.000767
6C	626978	587857	1214835	963	0.000793
7C	728278	734113	1462391	667	0.000456
8C	632857	647710	1280567	721	0.000563
9C	595440	613750	1209190	477	0.000394
10C	523144	484070	1007214	618	0.000614
11C	667226	616716	1283942	795	0.000619
12C	525662	540868	1066530	856	0.000803

Supplementary Table 2. Subject ID. Subject ID used in this paper, MRI DICOM ID for DICOM file matching, and Person ID from Bobilev *et al.* 2016¹⁰.

Subject ID	MRI DICOM ID	Bobilev <i>et al.</i> 2016 Person ID
1A	50009	1001A316/sUGA
2A	50005	124A141/s-124
3A	50022	147A061/f-149
4A	50013	147A064/f-148
5A	50014	N/A
6A	50036	157A121/s-157
7A	50003	114A159/f-173
8A	50010	N/A
9A	50012	147A017/f-147
10A	50015	173A291/s-220
11A	50011	N/A
12A	50016	191A297/s-222
1C	1002	N/A
2C	50031	N/A
3C	1003	N/A
4C	50028	N/A
5C	50044	N/A
6C	50037	N/A
7C	50003 Match	N/A
8C	50034	N/A
9C	1017	N/A
10C	1070	N/A
11C	50032	N/A
12C	50064	N/A

Supplementary Figure 1: Corpus Callosum Cross-sectional area and brain volume comparisons. (A) Representation of manually traced corpus callosum in a mid-sagittal slice. (B) Corpus callosum area. (C) Grey matter volume. (D) White matter volume. (E) Total brain volume. (F) Ratio of corpus callosum area to total brain volume. Line in each graph represents average of group. No statistically significant differences were observed for any of the measurements depicted in this figure ($p < 0.05$).

[Click here to access the data.](#)

References

1. Hanson IM, Seawright A, Hardman K, *et al.*: **PAX6 mutations in aniridia.** *Hum Mol Genet.* 1993; **2**(7): 915–920.
[PubMed Abstract](#) | [Publisher Full Text](#)
2. Grønskov K, Olsen JH, Sand A, *et al.*: **Population-based risk estimates of Wilms tumor in sporadic aniridia. A comprehensive mutation screening procedure of PAX6 identifies 80% of mutations in aniridia.** *Hum Genet.* 2001; **109**(1): 11–18.
[PubMed Abstract](#) | [Publisher Full Text](#)
3. Nelson LB, Spaeth GL, Nowinski TS, *et al.*: **Aniridia. A review.** *Surv Ophthalmol.* 1984; **28**(6): 621–42.
[PubMed Abstract](#) | [Publisher Full Text](#)
4. Grant WM, Walton DS: **Progressive changes in the angle in congenital aniridia, with development of glaucoma.** *Am J Ophthalmol.* 1974; **78**(5): 842–847.
[PubMed Abstract](#) | [Publisher Full Text](#)
5. McCulley TJ, Mayer K, Dahr SS, *et al.*: **Aniridia and optic nerve hypoplasia.** *Eye (Lond).* 2005; **19**(7): 762–764.
[PubMed Abstract](#) | [Publisher Full Text](#)
6. Nishida K, Kinoshita S, Ohashi Y, *et al.*: **Ocular surface abnormalities in aniridia.** *Am J Ophthalmol.* 1995; **120**(3): 368–375.
[PubMed Abstract](#) | [Publisher Full Text](#)
7. Tsai JH, Freeman JM, Chan CC, *et al.*: **A progressive anterior fibrosis syndrome in patients with postsurgical congenital aniridia.** *Am J Ophthalmol.* 2005; **140**(6): 1075–1079.
[PubMed Abstract](#) | [Publisher Full Text](#)
8. Thompson PJ, Mitchell TN, Free SL, *et al.*: **Cognitive functioning in humans with mutations of the PAX6 gene.** *Neurology.* 2004; **62**(7): 1216–1218.
[PubMed Abstract](#) | [Publisher Full Text](#)
9. Bamiou DE, Musiek FE, Sisodiya SM, *et al.*: **Deficient auditory interhemispheric transfer in patients with PAX6 mutations.** *Ann Neurol.* 2004; **56**(4): 503–509.
[PubMed Abstract](#) | [Publisher Full Text](#)
10. Bobilev AM, McDougal ME, Taylor WL, *et al.*: **Assessment of PAX6 alleles in 66 families with aniridia.** *Clin Genet.* 2016; **89**(6): 669–77.
[PubMed Abstract](#) | [Publisher Full Text](#) | [Free Full Text](#)
11. Hingorani M, Williamson KA, Moore AT, *et al.*: **Detailed ophthalmologic evaluation of 43 individuals with PAX6 mutations.** *Invest Ophthalmol Vis Sci.* 2009; **50**(6): 2581–90.
[PubMed Abstract](#) | [Publisher Full Text](#)
12. Kim J, Lauderdale JD: **Analysis of Pax6 expression using a BAC transgene reveals the presence of a paired-less isoform of Pax6 in the eye and olfactory bulb.** *Dev Biol.* 2006; **292**(2): 486–505.
[PubMed Abstract](#) | [Publisher Full Text](#)
13. Manuel M, Price DJ: **Role of Pax6 in forebrain regionalization.** *Brain Res Bull.* 2005; **66**(4–6): 387–393.
[PubMed Abstract](#) | [Publisher Full Text](#)
14. Simpson TI, Price DJ: **Pax6; a pleiotropic player in development.** *Bioessays.* 2002; **24**(11): 1041–1051.
[PubMed Abstract](#) | [Publisher Full Text](#)
15. Mastick GS, Davis NM, Andrew GL, *et al.*: **Pax-6 functions in boundary formation and axon guidance in the embryonic mouse forebrain.** *Development.* 1997; **124**(10): 1985–1997.
[PubMed Abstract](#)
16. Osumi N: **The role of Pax6 in brain patterning.** *Tohoku J Exp Med.* 2001; **193**(3): 163–174.
[PubMed Abstract](#) | [Publisher Full Text](#)
17. Sisodiya SM, Free SL, Williamson KA, *et al.*: **PAX6 haploinsufficiency causes cerebral malformation and olfactory dysfunction in humans.** *Nat Genet.* 2001; **28**(3): 214–216.
[PubMed Abstract](#) | [Publisher Full Text](#)
18. Mitchell TN, Free SL, Williamson KA, *et al.*: **Polymicrogyria and absence of pineal gland due to PAX6 mutation.** *Ann Neurol.* 2003; **53**(5): 658–663.
[PubMed Abstract](#) | [Publisher Full Text](#)
19. Bamiou DE, Free SL, Sisodiya SM, *et al.*: **Auditory interhemispheric transfer deficits, hearing difficulties, and brain magnetic resonance imaging abnormalities in children with congenital aniridia due to PAX6 mutations.** *Arch Pediatr Adolesc Med.* 2007; **161**(5): 463–469.
[PubMed Abstract](#) | [Publisher Full Text](#)
20. Abouzeid H, Youssef MA, ElShakankiri N, *et al.*: **PAX6 aniridia and interhemispheric brain anomalies.** *Mol Vis.* 2009; **15**: 2074–83.
[PubMed Abstract](#) | [Free Full Text](#)
21. Free SL, Mitchell TN, Williamson KA, *et al.*: **Quantitative MR image analysis in subjects with defects in the PAX6 gene.** *Neuroimage.* 2003; **20**(4): 2281–2290.
[PubMed Abstract](#) | [Publisher Full Text](#)
22. Ellison-Wright Z, Heyman I, Frampton I, *et al.*: **Heterozygous PAX6 mutation, adult brain structure and fronto-striato-thalamic function in a human family.** *Eur J Neurosci.* 2004; **19**(6): 1505–12.
[PubMed Abstract](#) | [Publisher Full Text](#)
23. Yogarajah M, Matarin M, Vollmar C, *et al.*: **PAX6, brain structure and function in human adults: advanced MRI in aniridia.** *Ann Clin Transl Neurol.* 2016; **3**(5): 314–30.
[PubMed Abstract](#) | [Publisher Full Text](#) | [Free Full Text](#)
24. Pierce JE, Krafft CE, Rodrigue AL, *et al.*: **Increased functional connectivity in intrinsic neural networks in individuals with aniridia.** *Front Hum Neurosci.* 2014; **8**: 1013.
[PubMed Abstract](#) | [Publisher Full Text](#) | [Free Full Text](#)
25. Cox RW: **AFNI: software for analysis and visualization of functional magnetic resonance neuroimages.** *Comput Biomed Res.* 1996; **29**(3): 162–73.
[PubMed Abstract](#) | [Publisher Full Text](#)
26. Dale AM, Fischl B, Sereno MI: **Cortical surface-based analysis. I. Segmentation and surface reconstruction.** *Neuroimage.* 1999; **9**(2): 179–194.
[PubMed Abstract](#) | [Publisher Full Text](#)
27. Fischl B, Salat DH, Busa E, *et al.*: **Whole brain segmentation: automated labeling of neuroanatomical structures in the human brain.** *Neuron.* 2002; **33**(3): 341–55.
[PubMed Abstract](#) | [Publisher Full Text](#)
28. Hanish AE, Butman JA, Thomas F, *et al.*: **Pineal hypoplasia, reduced melatonin and sleep disturbance in patients with PAX6 haploinsufficiency.** *J Sleep Res.* 2016; **25**(1): 16–22.
[PubMed Abstract](#) | [Publisher Full Text](#) | [Free Full Text](#)
29. Wood R, Bassett K, Foerster V, *et al.*: **PROS AND CONS OF 1.5 T MRI VERSUS 3.0 T MRI.**
[Reference Source](#)
30. Coffey CE, Lucke JF, Saxton JA, *et al.*: **Sex differences in brain aging. a quantitative magnetic resonance imaging study.** *Arch Neurol.* 1998; **55**(2): 169–179.
[PubMed Abstract](#) | [Publisher Full Text](#)
31. Grant MK, Bobilev AM, Pierce JE, *et al.*: **Dataset 1 in: Structural brain abnormalities in 12 persons with aniridia.** *F1000Research.* 2017.
[Data Source](#)

Open Peer Review

Current Referee Status:  

Version 2

Referee Report 26 September 2017

doi:[10.5256/f1000research.13553.r25602](https://doi.org/10.5256/f1000research.13553.r25602)



Lutz Jäncke

Department of Psychology (Neuropsychology) and INAPIC, University of Zurich, Zurich, Switzerland

The paper is now fine and the authors have nicely coped with the reviewer's suggestions and comments.

Competing Interests: No competing interests were disclosed.

I have read this submission. I believe that I have an appropriate level of expertise to confirm that it is of an acceptable scientific standard.

Version 1

Referee Report 18 April 2017

doi:[10.5256/f1000research.11931.r21372](https://doi.org/10.5256/f1000research.11931.r21372)



Lutz Jäncke

Department of Psychology (Neuropsychology) and INAPIC, University of Zurich, Zurich, Switzerland

This is an interesting and extremely important study reporting specific neuroanatomical features in patient group suffering from a rare disease affecting the visual system: aniridia. I have listed my comments and suggestions below.

Introduction

The introduction is fine and discusses the current literature. However, I would suggest to improve a bit the study question. The study question as it is used in the current version is very broad and does not come to the point (e.g., "The current study sought to investigate gross anatomical correlates of aniridia in a new population sample. Results from this study will serve as a comparison for previous studies, as well as contribute to what is known about the distribution of neuroanatomical phenotypes in the aniridia population as a whole."). I would suggest to include a few statements what this new study will add to the literature and what the "problems" of the older studies are? In addition, it could be helpful for the reader to learn the very new and maybe innovative aspects of this study.

Methods

Subjects: Some additional information about the subjects could be helpful (cognitive ability, handedness,

language lateralization). Some of these variables have been shown to be strongly related to the anatomical measures for which the authors are reporting the specific aniridia features.

Statistics: It is not entirely clear how the authors did their between-group comparisons. Did they compare the patients only on a visual-descriptive basis or did they perform a statistical analysis (which I would suggest). When doing a statistical analysis, one could compare single subjects to the mean of the control group. Thus, it would be possible to test each patient against the mean of the healthy control group. Using this comparison it would also be possible to calculate effect size measures for each subject.

By the way, did they use a priorly defined regions of interest?

Discussion

The discussion is fine.

Is the work clearly and accurately presented and does it cite the current literature?

Yes

Is the study design appropriate and is the work technically sound?

Yes

Are sufficient details of methods and analysis provided to allow replication by others?

No

If applicable, is the statistical analysis and its interpretation appropriate?

Partly

Are all the source data underlying the results available to ensure full reproducibility?

Yes

Are the conclusions drawn adequately supported by the results?

Yes

Competing Interests: No competing interests were disclosed.

I have read this submission. I believe that I have an appropriate level of expertise to confirm that it is of an acceptable scientific standard, however I have significant reservations, as outlined above.

Author Response 23 Aug 2017

Madison Grant, University of Georgia, USA

Dr. Lutz Jäncke, Department of Psychology (Neuropsychology) and INAPIC, University of Zurich, Zurich, Switzerland

We thank Dr. Jäncke for the helpful comments and suggestions, which improved the manuscript. Our responses are listed below.

Introduction

- Improve study question
 - Introduction has been revised to improve, clarify, and expand the description of our study question.
- Suggest: to include a few statements what this new study will add to the literature and what the "problems" of the older studies are? In addition, it could be helpful for the reader to learn the very new and maybe innovative aspects of this study.
 - Introduction has been revised to include more information on new aspects for this study. In particular we have emphasized at the end of the "Introduction" section that this study utilized a 3T magnet instead of a 1.5T, allowing for higher resolution when examining small structures such as the anterior and posterior commissure. Additionally, we also clarified, at the end of the "Introduction" section, that our study examined five structures shown to be abnormal in the aniridia population. Previous studies focused on only a subset of structures in each patient rather than all five. By examining all five structures in a new population of aniridia patients, we have added to the collective knowledge on structural brain abnormalities present within the disorder.

Methods

- Subjects: additional information: cognitive ability, handedness, language lateralization
 - We added handedness and predicted protein effect to Table 1. We do not have data on cognitive ability or language lateralization for our participants.
- Statistics: It is not entirely clear how the authors did their between-group comparisons. Did they compare the patients only on a visual-descriptive basis or did they perform a statistical analysis (which I would suggest). When doing a statistical analysis, one could compare single subjects to the mean of the control group. Thus, it would be possible to test each patient against the mean of the healthy control group. Using this comparison it would also be possible to calculate effect size measures for each subject.
 - For this study, the structural changes in Table 1 were concluded by two independent reviews of the MRI scans using a visual-descriptive basis. The methods have been updated to clarify the visual-descriptive assessment.
 - Volumetric analysis was conducted for the corpus callosum using Freesurfer software and results have been added to the manuscript (see supplementary Table 1 and supplementary Figure 1). Findings from this volumetric analysis confirmed our structural examination of the corpus callosum for all subjects. We did not conduct quantitative volumetric analyses on the anterior and posterior commissures as these are relatively small structures and the plane of view was not consistent within all subjects. This is due to variation in slice location within each brain. Because of this we decided to rely on our visual-descriptive assessment of these two structures for our dataset. While not ideal, a visual-descriptive assessment of the anterior and posterior commissures is consistent with previous reports comparing these structures between PAX6 normal individuals and individuals with PAX6 mutations (e.g. Sisodiya et al. 2001; Abouzeid et al., 2009) and captures relative changes

between these two groups.

- By the way, did the use a priorly defined regions of interest?
 - Yes, our Methods section (MRI data analysis) has been revised to state how we determined regions of interest. We used literature review to define which structures would be examined, and had ourthe radiologist (JD) examined the MRI scans for identification of additional regions of interest.

Discussion

The discussion is fine.

Competing Interests: No competing interests were disclosed.

Referee Response (*Member of the F1000 Faculty*) 17 Sep 2017

Lutz Jäncke, Psychology Division Neuropsychology, University of Zurich, Switzerland

Thank you so much. Well done!

Competing Interests: No competing interests were disclosed.

Referee Report 06 April 2017

doi:[10.5256/f1000research.11931.r21598](https://doi.org/10.5256/f1000research.11931.r21598)



Veronica van Heyningen

Institute of Ophthalmology, University College London, London, UK

This is an interesting report on structural brain changes in 12 aniridia patients examined by structural MRI studies, using 12 selected matching controls for comparison. The title and abstract convey details appropriately.

I should say at the outset that I have no expertise in MRI methodology and cannot compare the techniques used here with those used elsewhere, including our own papers.

It is clear, however, that MRI has advanced technically to a significant extent since the first set of papers was published in 2001-3. We need to know how directly comparable the results are. Certainly Sisodiya et al. in 2001 (ref 17) Mitchell et al. and 2003 (ref 18) used voxel-based morphometry and less powerful MRI measurements but showed similar findings with observed reduction or absence of the anterior commissure and olfactory bulb (ref 17) and of the pineal (ref 18). The current study does not mention study of the olfactory bulb. Interestingly olfactory function was also shown to be reduced and very occasionally absent in the first study (ref 17). Reduced interhemispheric transfer is thought to underlie the observed auditory processing problems reported in children with aniridia in ref 19. The current study reported in this paper does not undertake functional smell or auditory tests. Although what seems to be the same cohort, judging by the reported mutations, has been studied by functional fMRI by Pierce et al (ref 24). Surprisingly this overlapping author group (with the current paper) reports an apparently increased functional connectivity in the patients studied in the current paper. The earlier studies by other groups do not look at these functional connectivity changes. It is regrettable that the later studies,

including Yogarajah et al (ref 23) did not follow this up.

Otherwise the major findings are remarkably similar for this study and the previous studies to explore 12 or more cases. The controls in ref 17 and 18 are larger numbers (100) and not directly paired controls. The study in Ref 20 where the posterior commissure reduction was observed, only looked at the index case from three families with aniridia and PAX6 mutations. Reference 23 re-examines many of the same cases as Ref 17 and 18, but about a decade later and with more powerful MRI using surface-based morphometry. The reduced cortical measurements are more obvious in these older cases. The observed reduction of the optic chiasm reported here in 7/12 cases is an interesting new finding, first suggested in the one of the three families studied by Abouzeid et al, ref 20.

Minor comments

1. In the Introduction the PAX6 mutations are described as mostly “single nucleotide polymorphisms”. This is incorrect the changes are extremely rare variants. There are no polymorphisms of any note in the extremely highly conserved PAX6 gene.
2. It is a pity that the patient numbering is different in earlier fMRI work from this group (ref 24). Indeed it is not made clear that ref 24 studies the same cohort as observed in the current paper.
3. It would help to have the protein effects of the mutations in Table 1.
4. Can the olfactory bulb status be observed with the current cohort? It would be interesting to see that reported.

Competing Interests: I am a co-author on several of the cited references, in particular several reporting results of similar studies (refs 17, 18, 19, 23 and some others).

I have read this submission. I believe that I have an appropriate level of expertise to confirm that it is of an acceptable scientific standard.

Author Response 23 Aug 2017

Madison Grant, University of Georgia, USA

Reviewer: Veronica van Heyningen, Institute of Ophthalmology, University College London, London, UK

We thank Dr. van Heyningen for the helpful comments and suggestions, which improved the manuscript. Our responses are listed below.

Comments to the Author:

Minor comments

1. In the Introduction the PAX6 mutations are described as mostly “single nucleotide polymorphisms”. This is incorrect the changes are extremely rare variants. There are no polymorphisms of any note in the extremely highly conserved PAX6 gene.

- The text was modified to read: “The majority of these variants are nonsense mutations, which lead to a premature termination codon, and are found across the *PAX6* locus.”
2. It is a pity that the patient numbering is different in earlier fMRI work from this group (ref 24). Indeed it is not made clear that ref 24 studies the same cohort as observed in the current paper.
 - Numbering of patients has been amended to reflect the same numbering used in the previous paper (ref 24). We have additionally added a supplementary table (Supplementary Table 2) that matches DICOM file names to patient ID from this paper and previous papers using the same patient group. Additionally, we have added a sentence in methods (Subjects) to state that this study and ref 24 used the same patients.
 3. It would help to have the protein effects of the mutations in Table 1.
 - Protein effects have been added to Table 1.
 4. Can the olfactory bulb status be observed with the current cohort? It would be interesting to see that reported.
 - While we agree that the olfactory bulb would be an interesting and important addition, we elected not to pursue this structure because constraints inherent to our data. We have amended methods (MRI data analysis) to discuss explain why we decided not to investigate olfactory bulb in this patient sample.

Competing Interests: No competing interests were disclosed.
