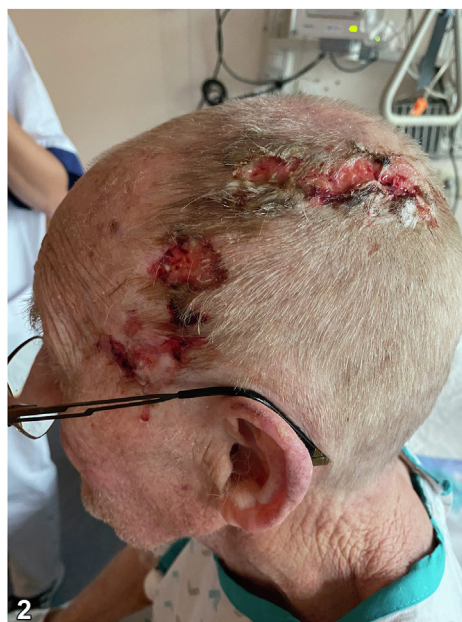
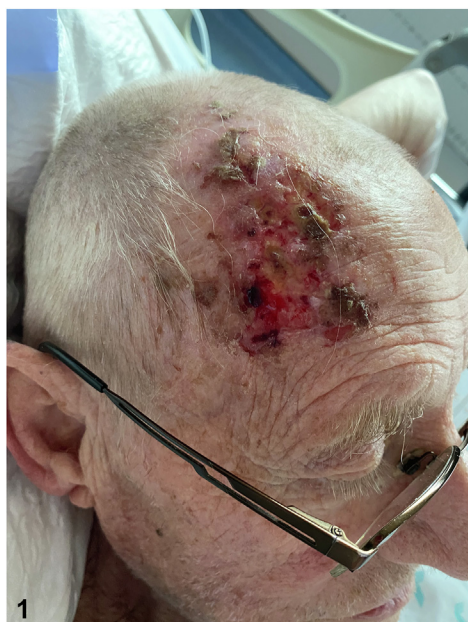
Rapid-onset bilateral scalp ulceration with visual loss

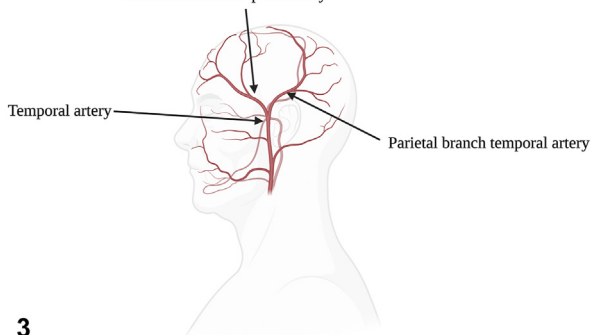


Sophie Golstein, MD,^a Thomas Delguste, MD,^b Frédéric Vandergheynst, MD, PhD,^c
Véronique Lesage, MD,^b and Claire Debusscher, MD^a

Key words: giant cell arteritis; inflammatory vasculitis; scalp necrosis; temporal arteritis; visual loss.



Frontal branch temporal artery



3

From the Department of Dermatology, Hôpital Erasme, Université Libre de Bruxelles, Brussels, Belgium^a; Department of Geriatric Medicine, Hôpital Erasme, Université Libre de Bruxelles, Brussels, Belgium^b; and Department of Internal Medicine, Hôpital Erasme, Université Libre de Bruxelles, Brussels, Belgium.^c

Funding sources: None.

IRB approval status: Not applicable.

Drs Golstein and Delguste are co-first authors who contributed equally to this article.

There is no prior presentation of this case to our knowledge.

Consent for the publication of all patient photographs and medical information was provided by the authors at the time of article submission to the journal stating that all patients gave

consent for their photographs and medical information to be published in print and online and with the understanding that this information may be publicly available.

Correspondence to: Claire Debusscher, MD, Department of Dermatology, Hôpital Erasme, Université Libre de Bruxelles, 808 route de Lennik, 1070 Brussels, Belgium. E-mail: claire.debusscher.priv@gmail.com.

JAAD Case Reports 2022;28:97-9.

2352-5126

© 2022 by the American Academy of Dermatology, Inc. Published by Elsevier, Inc. This is an open access article under the CC BY-NC-ND license (<http://creativecommons.org/licenses/by-nc-nd/4.0/>).

<https://doi.org/10.1016/j.jidcr.2022.07.039>

CASE PRESENTATION

An 84-year-old man presented to the emergency room with a 3-week history of bilateral, painful, ulcerating scalp lesions (Figs 1-3), along with a rapid-onset right eye visual loss.

Bilateral jaw claudication and scalp tenderness had been present for 3 months.

His past medical history was significant for lung adenocarcinoma surgically treated 6 months earlier, hypertension, and lower limb peripheral arterial occlusive disease.

Skin examination revealed sharply demarcated and ulcerated lesions, distributed bilaterally in the temporo-parietal area.

Regional lymph node palpation showed no enlargement.

Laboratory tests showed a mildly elevated C-reactive protein level and sedimentation rate. Complete blood count was unremarkable.

Question 1: What is the most likely diagnosis?

- A. Shingles
- B. Invasive squamous cell carcinoma (SCC)
- C. Giant cell arteritis (GCA) or temporal arteritis
- D. Cutaneous metastases
- E. Calciphylaxis

Answer:

A. Shingles — Incorrect. Shingles (varicella-zoster virus reactivation) may begin with tenderness followed by ulcerated vesicles. Visual loss may also be associated with shingles of the ophthalmic division of the trigeminal nerve. However, the lesions here did not follow a unilateral dermatomal distribution, and no vesicles were present.

B. Invasive SCC — Incorrect. SCCs arise in sun-exposed skin of elderly individuals and may grow rapidly with tenderness and pain. However, they are often hyperkeratotic or scaly at first with ulceration as a secondary change.

C. GCA or temporal arteritis — Correct. GCA, a form of large vessel vasculitis, affects the temporal artery in patients over 50 years of age. Patients present elevated inflammatory parameters and most often nonspecific systemic signs such as fever and weight loss. Ischemic signs are more specific and include at first jaw claudication and scalp tenderness. Scalp and tongue ulcerations as well as visual impairment may occur later. GCA has no specific biological marker.¹ In our patient, the diagnosis was based on clinical and laboratory findings. It was confirmed by an ultrasound of the temporal artery.

D. Cutaneous metastases — Incorrect. Cutaneous metastases occasionally present in a bullous zosteriform pattern, and lung adenocarcinoma represents the most common source of cutaneous metastases in men excluding melanoma. However, solitary or multiple erythematous nodules in the primary

cancer's anatomic vicinity is the most common clinical presentation, and the zosteriform pattern is mostly described on the chest and neck. Scalp metastases originate disproportionately from renal cell carcinoma.

E. Calciphylaxis — Incorrect. Calciphylaxis may present with tender plaques or skin ulcerations. However, it mainly affects patients with chronic end-stage renal disease and calcium metabolism imbalance.

Question 2: Which of the following would be the most optimal initial therapy for the case presented?

- A. Observation
- B. Systemic corticosteroids
- C. Topical steroids
- D. Tocilizumab
- E. Methotrexate

Answer:

A. Observation — Incorrect. Visual loss is—most of the time—an irreversible complication of GCA. This makes GCA an ophthalmic emergency.²

B. Systemic corticosteroids — Correct. Intravenous pulse corticosteroid therapy is prescribed (250-1000 mg methylprednisolone for up to 3 days) for newly diagnosed GCA with acute visual loss. Oral high-dose corticosteroids (40-60 mg/day prednisone-equivalent or prednisone 1 mg/kg/day) are advised in patients without manifestations of ischemia (visual and neurologic involvement). The dose is gradually tapered once remission is achieved.^{1,3}

C. Topical steroids — Incorrect. Topical or intralesional corticosteroids may resolve localized areas of cutaneous involvement in cutaneous polyarteritis nodosa (a medium-sized vessel vasculitis). They are not an option in GCA.

D. Tocilizumab — Incorrect. Tocilizumab, an anti-interleukin-6 receptor monoclonal antibody, is not systematically prescribed as a first-line treatment. It may be combined with systemic corticosteroids as initial treatment in newly diagnosed GCA patients already presenting corticosteroid-related adverse events (AE) or at high risk for such AE.^{1,3}

E. Methotrexate — Incorrect. Methotrexate has long been the corticosteroid-sparing drug for GCA. It is nowadays initially associated with systemic corticosteroids in patients presenting or at high risk of corticosteroid-related AE (as an alternative to tocilizumab) and allows the gradual tapering of the systemic corticosteroid treatment. Although stronger clinical evidence supports the use of tocilizumab compared to methotrexate, the latter can be considered if the patient is at risk of recurrent infections or for cost reasons.

Question 3: This disease may be associated with all the following except:

- A.** Aortic aneurysms
- B.** Stroke
- C.** Ophthalmological complications
- D.** Nonmelanoma skin cancer
- E.** Polymyalgia rheumatica

Answer:

A. Aortic aneurysms — Incorrect. Aortic aneurysms, especially of the thoracic aorta, are a late complication of GCA occurring 5 years or later after the initial diagnosis. This shows the importance of long-term monitoring in these patients.⁴

B. Stroke — Incorrect. Cerebrovascular accidents are serious, difficult-to-treat, and probably underdiagnosed complications of GCA as the differential

diagnosis with thromboembolic occlusion in the elderly is challenging.

C. Ophthalmological complications — Incorrect. The ocular symptoms of GCA are variable. They include diplopia, eye pain, and ocular ischemic lesions.² GCA's most serious complication is the irreversible loss of visual acuity. The incidence of ocular involvement varies from 20% to 70%.

D. Nonmelanoma skin cancer — Correct. Nonmelanoma skin cancers have been reported concomitantly with GCA; however, there is no overall increased incidence of nonmelanoma skin cancers in patients with GCA.⁵

E. Polymyalgia rheumatica — Incorrect. Polymyalgia rheumatica is associated with GCA in 50% of cases. It is characterized by symmetrical and bilateral aching and stiffness in the shoulders, neck, and pelvic girdle, particularly in the morning.¹

Abbreviations used:

AE: adverse events

GCA: giant cell arteritis

SCC: squamous cell carcinoma

Conflicts of interest

None disclosed.

REFERENCES

1. Greigert H, Ramon E, Tarris G, Martin L, Bonnotte B. Temporal artery vascular diseases. *J Clin Med.* 2022;11:275.
2. Hayreh S. Giant cell arteritis: its ophthalmic manifestations. *Indian J Ophthalmol.* 2021;69:227-235.
3. Maz M, Chung SA, Abril A, et al. 2021 American College of Rheumatology/Vasculitis Foundation Guideline for the management of giant cell arteritis and Takayasu arteritis. *Arthritis Rheumatol.* 2021;73:1349-1365.
4. Keramni TA, Warrington KJ. Prognosis and monitoring of giant cell arteritis and associated complications. *Expert Rev Clin Immunol.* 2018;14(5):379-388.
5. Hill CL, Cole A, Rischmueller M, et al. Risk of cancer in patients with biopsy-proven giant cell arteritis. *Rheumatol Oxf Engl.* 2010;49:756-759.