

Norwegian scabies in a patient treated with *Tripterygium glycoside* for rheumatoid arthritis*

Xiaolin Bu¹
Xiaoli Hu¹
Bin Peng³

Juan Fan¹
Xinling Bi²
Denghai Zhang³

DOI: <http://dx.doi.org/10.1590/abd1806-4841.20174946>

Abstract: We report an 80-year-old male patient with severe rheumatoid arthritis who was treated with *tripterygium glycoside*, an immunosuppressive agent made from the extract of a Chinese medicinal herb called *Tripterygium wilfordii* Hook F. The patient had no apparent skin lesions before the treatment, but he developed aggressive hyperkeratotic lesions with rapid progression after using *tripterygium glycoside*. He was repeatedly diagnosed with eczema, but treatment failed to achieve efficacy. Interestingly, a microscopic examination of the lesions revealed numerous scabies mites and eggs. Thus, we confirmed the diagnosis of Norwegian scabies infection. Treated with crotamiton 10% cream and 10% sulfur ointment for one month, the patient's clinical symptoms disappeared.

Keywords: Arthritis, rheumatoid; Herbal medicine; Immunosuppression; *Sarcoptes scabiei*

INTRODUCTION

Norwegian scabies is a rare and highly contagious skin infestation – caused by *Sarcoptes scabiei* var. *hominis* – characterized by a large number of parasites in the skin. It commonly affects immunocompromised patients with conditions such as lymphoma, leukemia, acquired immunodeficiency syndrome, graft-versus-host disease, and patients undergoing treatment with corticosteroids or immunosuppressors.^{1,2} It has been considered that immune response failure, particularly the cell-mediated immunity, is the possible pathogenesis of this disease.³ With the number of immunocompromised patients on the rise, it is imperative that complex dermatologic disorders affecting these patients – such as Norwegian scabies – be recognized.

In the current case report, a male patient with rheumatoid arthritis (RA), who had a long-term use of *tripterygium glycoside* (TG), was diagnosed with Norwegian scabies. TG – a patent medicine in China made from a medicinal herb called *Tripterygium wilfordii* Hook F (TwHF) – can inhibit T lymphocyte and inflammatory cytokines.⁴ It is widely used to treat autoimmune and inflammatory diseases such as RA. Its curative effect has been reported to

be remarkable. Major side effects include irregular menstruation, amenorrhea, premature ovarian insufficiency, and sperm production reduction. However, there has been little literature on Norwegian scabies secondary to long-term RA treated with TG.

CASE REPORT

For more than one month, an 80-year-old male patient sought medical care for his worsening skin lesions that began six months before. At an initial stage, his hands developed erythema with moderate itching. Progressively, the condition involved his trunk and limbs. The lesions were repeatedly diagnosed as eczema, for which antihistamine drugs and corticosteroid creams were administered without efficacy. The condition began to worsen four weeks later. Erythema with hyperkeratosis and scales became more extensive to the whole body and crusted lesions appeared on his buttocks, genitals, and hands. The patient received methylprednisolone intravenously several times, but in vain. Personal and family histories revealed no scabies contact. Since the patient had been diagnosed with severe RA 3 years prior (positive for rheumatoid

Received on 18.07.2015

Approved by the Advisory Board and accepted for publication on 27.09.2015

* Work performed at Shanghai Gongli Hospital – Second Military Medical University – Shanghai, China.

Financial support: The Shanghai Pudong Youth Talent Project in Medicine to Bu XL (PWRq2013-02), and a Shanghai Excellent Academic Leader in Medicine to Zhang DH (XBR2011054).

Conflict of interest: none.

¹ Department of Dermatology at Shanghai Gongli Hospital – Second Military Medical University – Shanghai, China.

² Department of Dermatology at Changhai Hospital – Second Military Medical University – Shanghai, China.

³ Sino-French Cooperative Central Lab at Shanghai Gongli Hospital – Second Military Medical University – Shanghai, China.

factors), TG (60 mg/day) was prescribed as an immunosuppressant therapy, which lasted for about 2 years.

Physical examination revealed that the patient's general condition was fair, except for marasmus. Extensive erythema, scaling, and keratinization were seen on the trunk and limbs. Many thick layers of yellowish white scales and crusts covered the skin of his hands, genitals, and buttocks. The chapped hands bled and his fingers were swollen (Figure 1). No nodules were found in the scrotum. A microscopic examination of the scraping scales in the hands revealed the presence of numerous mites and eggs (Figure 2). Therefore, we diagnosed Norwegian scabies. For treatment, we withdrew TG and prescribed crotamiton 10% cream (daily application for 3 days) and mizolastine capsule (10 mg/day for 3 days). After 3 days, the treatment dramatically alleviated the erythema, scaling, crusts, and itching. Then, the administration of 10% crotamiton cream continued augmented by 10% sulfur ointment applied to serious lesions. After one month, all the lesions disappeared and no live mites were observed on microscopic examination (Figure 3). No outbreak of scabies occurred among the staff.

DISCUSSION

The current case report dealt with Norwegian scabies. The diagnosis was reached based on clinical features and especially on the presentation of numerous mites and eggs under the microscope. A highlight of this case was the history of TG application (a patent medicine in China made from a medicinal herb that is widely used in China and usually believed to produce less side effects).

Norwegian scabies (crusted scabies or hyperkeratotic scabies) is clinically distinct and highly contagious. Typical clinical manifestations include erythroderma with hyperkeratosis, scaling, and crusting of the skin, swollen and crusted fingers, distorted nails, and moderate itching. Our patient presented with all these symptoms.⁵

We believe that TG application served as the main causative factor for the current case. Norwegian scabies is often seen in

immune-suppressed situations, either caused by the use of immunosuppressant drugs or diseases, such as acquired immunodeficiency syndrome.⁶ TG as an immunosuppressive agent could inhibit the activation of T lymphocytes, monocytes/macrophages, and B cells, reduce the number of CD4⁺ T-cells and the levels of many pro-inflammatory cytokines.⁷ Additionally, Norwegian scabies also affects the elderly, most of whom have low immunity. The current case reported an 80-year-old man diagnosed with marasmus, whose immune response was declining with age.⁸

Unfortunately, a wrong diagnosis of eczema was made for months, which might have been ascribed to the rarity of Norwegian scabies. Actually, in China, although most clinicians are familiar with scabies, they seem to be unable to recognize Norwegian scabies. Additionally, physicians assume that the medicinal herbs of traditional Chinese medicine and their extracts have fewer side effects. Therefore, they are unlikely to link TG application to any unexpected medical problem, as indicated in the current case, where the skin lesions were hardly considered to be caused by immune suppression, hence, the period of TG application.

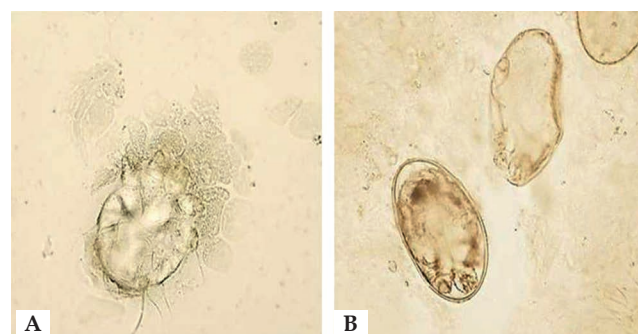


FIGURE 2: A-B: Microscopic examination of the skin scraping clarified with 10% potassium hydroxide showed an adult mite and eggs (Hematoxylin & eosin X400)

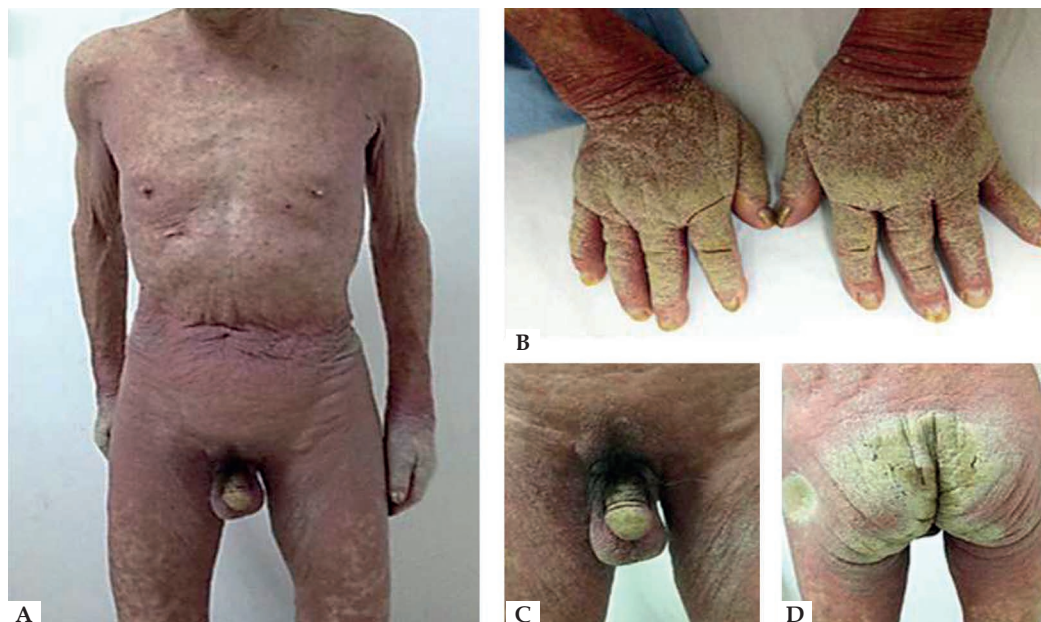


FIGURE 1: A. Extensive erythema, scaling, and keratinization were seen on the trunk and limbs. B-D: Thick layer yellowish white scales and crusts covering the hands, genitals, and buttocks. Chapped hands and swollen fingers

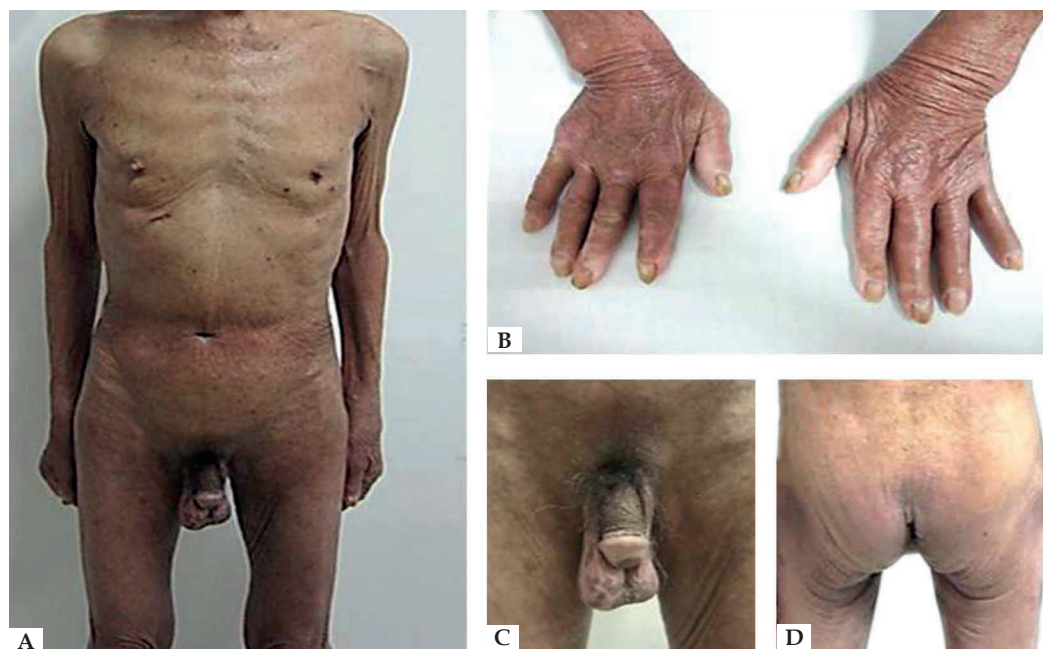


FIGURE 3:
A-D: One month after treatment with crotamiton 10% cream, the lesions subsided leaving a mild pigmentation

As an extract from TwHF, TG has been applied to a variety of autoimmune diseases on a large scale.⁹ With the advance of globalization, TG might be introduced to foreign patients. Therefore, it is imperative that its potential of causing Norwegian scabies be noticed.

In conclusion, we reported a case of Norwegian scabies with a long history of TG application with a view to contributing to the list of possible side effects of TG, an extract from a Chinese herb that is usually considered safe while having immune suppressive effects. □

REFERENCES

1. Towersey L, Cunha MX, Feldman CA, Castro CG, Berger TG. Dermoscopy of Norwegian scabies in a patient with acquired immunodeficiency syndrome. *An Bras Dermatol*. 2010;85:221-3.
2. Baccouche K, Sellam J, Guegan S, Aractingi S, Berenbaum F. Crusted Norwegian scabies, an opportunistic infection, with tocilizumab in rheumatoid arthritis. *Joint Bone Spine*. 2011;78:402-4.
3. Walton SF, Beroukas D, Roberts-Thomson P, Currie BJ. New insights into disease pathogenesis in crusted (Norwegian) scabies: the skin immune response in crusted scabies. *Br J Dermatol*. 2008;158:1247-55.
4. Wan Y, Sun W, Zhang H, Yan Q, Chen P, Dou C, et al. Multi-glycoside of *Tripterygium wilfordii* Hook f. ameliorates prolonged mesangial lesions in experimental progressive glomerulonephritis. *Nephron Exp Nephrol*. 2010;114:e7-e14.
5. Costa JB, Rocha de Sousa VL, da Trindade Neto PB, Paulo Filho Tde A, Cabral VC, Pinheiro PM. Norwegian scabies mimicking rupioid psoriasis. *An Bras Dermatol*. 2012;87:910-3.
6. Fernández-Sánchez M, Saeb-Lima M, Alvarado-de la Barrera C, Reyes-Terán G. Crusted scabies-associated immune reconstitution inflammatory syndrome. *BMC Infect Dis*. 2012;12:323.
7. Yang CL, Or TC, Ho MH, Lau AS. Scientific basis of botanical medicine as alternative remedies for rheumatoid arthritis. *Clin Rev Allergy Immunol*. 2013;44:284-300.
8. Stervbo U, Meier S, Mälzer JN, Baron U, Bozzetti C, Jürchott K, et al. Effects of aging on human leukocytes (part I): immunophenotyping of innate immune cells. *Age (Dordr)*. 2015;37:92.
9. Tao X, Younger J, Fan FZ, Wang B, Lipsky PE. Benefit of an extract of *Tripterygium Wilfordii* Hook F in patients with rheumatoid arthritis: a double-blind, placebo-controlled study. *Arthritis Rheum*. 2002;46:1735-43.

MAILING ADDRESS:

Denghai Zhang
Shanghai Gongli Hospital,
Second Military Medical University,
219, Miao Pu Road,
Pudong New District, Shanghai
200135, P.R. China
E-mail: shanghai_zhang@hotmail.com

How to cite this article: XL Bu, J Fan, XL Hu, XL Bi, B Peng, DH Zhang. Norwegian scabies in a patient treated with *Tripterygium* glycoside for rheumatoid arthritis. *An Bras Dermatol*. 2017;92(4):556-8.