


CASE STUDY

Not just a bump on the head: ultrasound as first-line imaging in a boy with Pott's puffy tumour

Tristan Reddan, BAppSc, GradCertHlthSc, GradDipAppSc, AMS, AFASA¹  & Patricia Connor, BSc, MBBS, FRANZCR^{1,2}

¹Medical Imaging and Nuclear Medicine, Lady Cilento Children's Hospital, South Brisbane, Queensland, Australia

²Wesley Medical Imaging, Auchenthaler, Queensland, Australia

Keywords

Osteomyelitis, paediatrics, Pott's puffy tumour, X-ray computed tomography, ultrasonography

Correspondence

Tristan Reddan, Medical Imaging and Nuclear Medicine, Lady Cilento Children's Hospital, South Brisbane, Queensland 4101, Australia.
Tel: +61 7 3068 3100; Fax: +61 7 3068 3019;
E-mail: tristan.reddan@health.qld.gov.au

Received: 21 June 2017; Accepted: 25 September 2017

J Med Radiat Sci 65 (2018) 71–73

doi: 10.1002/jmrs.251

Introduction

Head and neck lumps can pose a diagnostic dilemma in children as clinical history can be unclear. Both computed tomography (CT) and magnetic resonance imaging (MRI) warrant careful consideration in children, with the radiation burden of the former and need for anaesthesia in younger children and limited availability with the latter. With its lack of ionising radiation, ultrasound is often a first-line modality in paediatric cases with low clinical likelihood. This is the report of such a case, where ultrasound played a valuable role in determining further timely and appropriate investigations.

Case Report

A 6-year-old boy with a month-long history of fluctuant swelling over the right forehead, and more recent complaints of headache presented to the emergency department. He had been seen twice by a general practitioner in the week prior, had no prior medical history or a recollection of recent trauma. The lump was mildly

Abstract

While computed tomography (CT) and magnetic resonance imaging (MRI) have established roles in evaluating Pott's puffy tumour, ultrasound can play a valuable role in identifying the condition, particularly in children. We present the case of a boy with a fluctuant forehead lump and headaches, where ultrasound was the first-line imaging modality and expedited further investigations.

raised, round and measured approximately 30 mm in diameter. It was tender on palpation and without erythema. Inflammatory markers revealed a normal blood white cell count ($8.6 \times 10^9/L$), C-reactive protein (3.3 mg/L) and elevated erythrocyte sedimentation rate (40 mm/h).

Ultrasound of the lump using a high-frequency linear transducer was conducted (Aplio 500, Toshiba Medical Systems, Otawara, Japan). Complete disruption of the outer table of the frontal bone underlying the lump was noted (Fig. 1), with associated periosteal lifting, a subperiosteal collection and surrounding hyperaemia (Fig. 2). Differential diagnoses were osteomyelitis or fracture and haematoma. Decision was made to promptly proceed to unenhanced head CT to further assess bony involvement (SOMATOM Force, Siemens Healthcare AG, Erlangen, Germany) which confirmed the ultrasound findings (Fig. 3A and B). There was significant opacification of the right paranasal sinuses though no evidence of intracranial extension (Fig. 4). Cranial MRI had also been ordered, but given the lack of intracranial extension on CT, this was considered by the treating team to be unnecessary before proceeding to surgery.

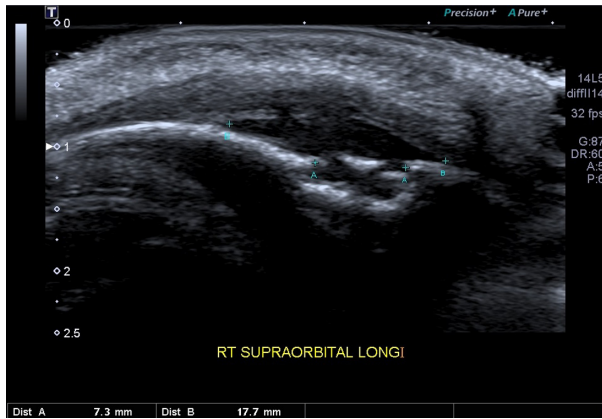

Figure 1. Longitudinal ultrasound image of the forehead lump with periosteal lifting (B callipers) and disruption of the underlying frontal bone (A callipers).

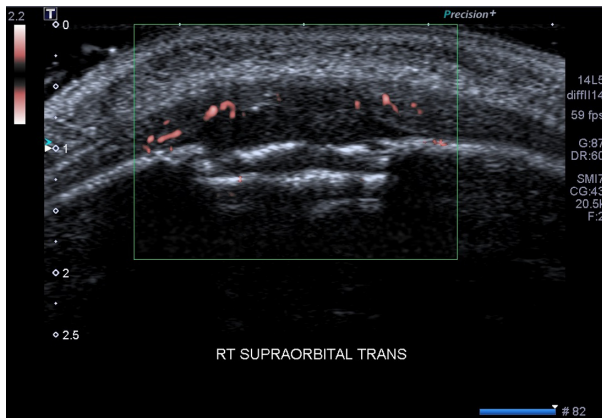


Figure 2. Transverse ultrasound image using superb microvascular imaging (SMI) demonstrating some periosteal hyperaemia.

Functional endoscopic sinus surgery (FESS) confirmed Pott's puffy tumour secondary to chronic sinusitis, a 9-mm polyp was removed and dehiscence of the lamina papyracea was noted. Intravenous antibiotics were administered for 10 days and the patient was discharged without further complication.

Discussion

First described by Sir Percival Pott in the late 18th century, initially in association with head trauma and later with sinusitis, Pott's puffy tumour refers to the presence of a subperiosteal abscess and osteomyelitis of the frontal bone.¹ Untreated it can disseminate through venous drainage, and potentially result in a sinocutaneous fistula.² Intracranial complications such as brain abscess or meningitis are common sequelae.³⁻⁵ A recent review found only 13 documented cases since 1978 in children

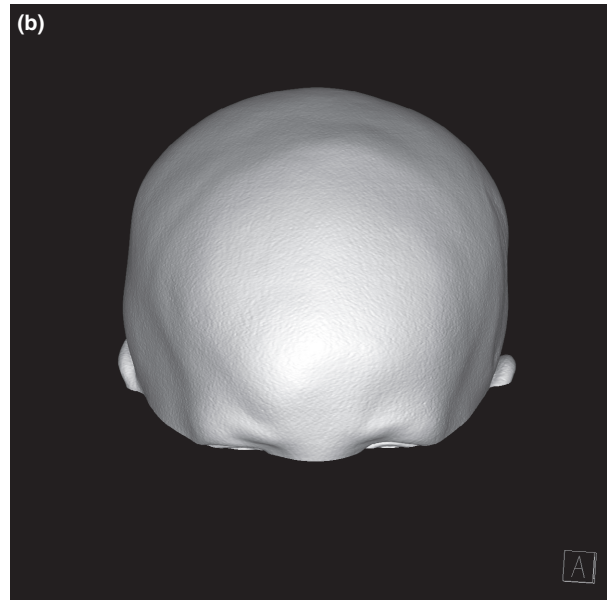
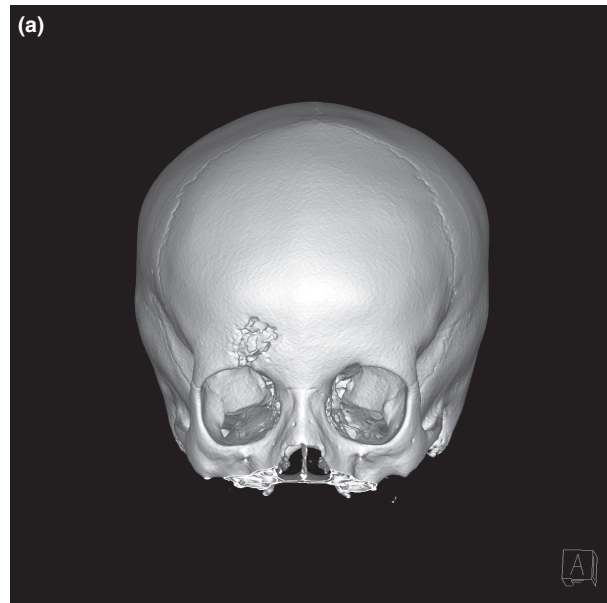


Figure 3. Computed tomography (CT) surface rendering of the bony erosion (A), compared with the more subtle soft tissue swelling overlying it (B).

under 10 years, with presentations more common in adolescents likely due to the development of the valveless diploic venous system.^{2,6} There are only two documented ultrasound cases of the condition, neither demonstrate the same degree of bony destruction as this case.^{1,7}

Conclusion

Pott's puffy tumours are rare and presentation in children can be non-specific. There is often a delay in diagnosis

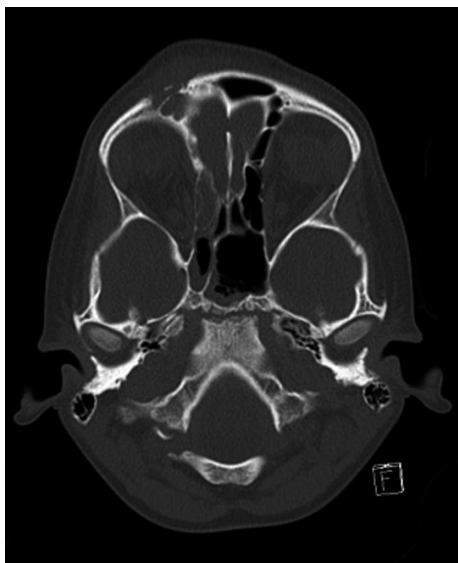

Figure 4. Axial computed tomography (CT) image with sinus opacification, frontal bone erosion and forehead swelling.

due to its presumed rarity in the post-antibiotic era. Along with more established imaging modalities, ultrasound can play an important first-line role in identifying this serious condition, particularly in children.

Acknowledgements

Written informed consent was obtained for this manuscript. All authors contributed to the writing and

revision of this manuscript and declare no funding or conflict of interest.

References

1. Vanderveken OM, De Smet K, Dogan-Duyar S, et al. Pott's puffy tumor in a 5-year-old boy: the role of ultrasound and contrast-enhanced CT imaging-Surgical case report. *Int J Pediatr Otorhinolaryngol Extra* 2012; **7**(1): 1–5.
2. Parida PK, Surianarayanan G, Ganeshan S, Saxena SK. Pott's puffy tumor in pediatric age group: a retrospective study. *Int J Pediatr Otorhinolaryngol* 2012; **76**(9): 1274–7.
3. Blumfield E, Misra M. Pott's puffy tumor, intracranial, and orbital complications as the initial presentation of sinusitis in healthy adolescents, a case series. *Emerg Radiol* 2011; **18**(3): 203–10.
4. Bannon PD, McCormack RF. Pott's puffy tumor and epidural abscess arising from pansinusitis. *J Emerg Med* 2011; **41**(6): 616–22.
5. Nicoli TK, Mäkitie A. Frontal Sinusitis Causing Epidural Abscess and Puffy Tumor. *N Engl J Med* 2014; **370**(11): e18.
6. Gildener-Leapman N, Lin A. Pott's puffy tumor in a 5-year-old male and a review of the literature. *Int J Pediatr Otorhinolaryngol Extra* 2012; **7**(2): 48–51.
7. Weinberg B, Gupta S, Thomas MJ, Stern H. Pott's puffy tumor: sonographic diagnosis. *J Clin Ultrasound* 2005; **33**(6): 305–7.