

Role of neuroimaging in cases of primary and secondary hemifacial spasm

Prabrisha Banerjee, Md. Shahid Alam¹, Kirthi Koka, Ruchi Pherwani, Olma Veena Noronha², Bipasha Mukherjee

Purpose: The objective of this study was to analyze the role of neuroimaging and documenting various intracranial pathologies in primary and secondary hemifacial spasm. **Methods:** This retrospective study included patients with HFS who had undergone neuroimaging. The demographic profile, onset, progression, neuroimaging findings, and types of HFS were documented and analyzed. **Results:** A total of 202 patients (male = 110, female = 92) were included. The mean age of the study population was 51.81 ± 11.76 years. The right side was involved in 104 patients, the left side was involved in 97 patients and bilateral involvement was observed in one patient. Primary HFS: secondary HFS was 9.6:1. The mean age of onset of the spasms in the primary HFS group was 49.26 ± 8.35 years and in secondary HFS was 43.13 ± 12.12 years respectively. The anterior inferior cerebellar artery was the major vessel causing neurovascular conflict in primary HFS ($n = 55$). Facial nerve palsy was the most common cause ($n = 13$) of secondary HFS followed by cerebellopontine angle (CPA) tumors. **Conclusion:** The hemifacial spasm occurs mostly in the fifth decade of life. Primary HFS is more prevalent than secondary HFS. Clinical distinction between them is difficult. Neuroimaging is essential to detect the conflicting vasculature in cases of primary HFS and pathologies like CPA tumor, cyst, and aneurysms in cases of secondary HFS.

Key words: Hemifacial spasm, neuroimaging, neurovascular conflict, primary and secondary, root exit zone

Hemifacial spasm (HFS) is a movement disorder characterized by unilateral, involuntary, and arrhythmic movements of the facial muscles of expression [Fig. 1]. It is usually insidious in onset.^[1] The contractions have a focal onset in the orbicularis oculi muscle and gradually spreads to the lower face.^[2] HFS has been categorized as primary and secondary based on the etiology. Primary HFS represents the contractions produced by the hyperactivity of the facial nerve due to the compression of the nerve at its root exit zone.^[3] The involvement of the facial motor nucleus or an insult to the peripheral course of the nerve by trauma, tumor, inflammation, or demyelination constitutes secondary HFS.^[3,4] Primary HFS is more prevalent and the age of onset is in the 5th decade of life with a female preponderance. Published literature quoted the prevalence rate of HFS to be around 14.5 per 100,000 in women and 7.4 per 100,000 in men.^[5,6] Although secondary HFS is less frequent but the underlying pathology can be grave and life-threatening. Neuroimaging guides us to clinch the diagnosis of secondary HFS. There is a scarcity of articles on HFS in the ophthalmic literature, but interestingly many of these patients initially present to the ophthalmologists for the management. The present study aims to describe the role of neuroimaging and associated intracranial pathologies in cases of HFS and to create awareness on the importance of neuroimaging in HFS amongst ophthalmologists.

Methods

This retrospective study included the patients with HFS presenting to the oculoplasty clinics of two centers of our

Orbit, Oculoplasty, Reconstructive and Aesthetic Services, Sankara Nethralaya, Medical Research Foundation, Chennai, Tamil Nadu, ¹Orbit, Oculoplasty, Reconstructive and Aesthetic Services Aditya Birla Sankara Nethralaya, Kolkata (A Unit of Medical Research Foundation, Chennai), West Bengal, ²VRR Scan Centre, Chennai, Tamil Nadu, India

Correspondence to: Dr. Md. Shahid Alam, Aditya Birla Sankara Nethralaya, Mukundapur, Kolkata - 700 099, West Bengal, India. E-mail: mshahidalam@gmail.com

Received: 02-Mar-2020

Revision: 19-May-2020

Accepted: 16-Jul-2020

Published: 18-Jan-2021

institute between April 2010 and July 2019. All Patients who had undergone Magnetic Resonance Imaging (MRI)/Magnetic Resonance Angiography (MRA) with 3D FIESTA (Fast Imaging Employing Steady State Acquisition) or Constructive Interference in Steady State (CISS) and time of flight angiogram (TOF) MRI sequences were included in the study. The medical records of these patients were reviewed and the data pertaining to our study was collected. The study was conducted in accordance with the Declaration of Helsinki following approval from the Institutional review board and ethics committee.

A detailed history of the patients was obtained particularly antecedent illness, facial nerve palsy, and deafness. All the patients underwent a thorough clinical examination including 5th, 6th, 7th, and 8th cranial nerve examination to screen for secondary HFS. Data relevant to our study including demographic profile, onset, progression, duration of the presenting complaints, laterality, and MRI/MRA imaging findings were recorded. Based on the clinical evaluation and neuroimaging, the patients were grouped into primary or secondary HFS and the differences between the two groups were computed by t-test or Chi-square test. *P* value <0.05 was considered to be statistically significant.

The mean value and the standard deviation were calculated for numerical data and percentage and frequency were computed for categorical data. The statistical analysis was

Access this article online

Website:

www.ijoo.in

DOI:

10.4103/ijoo.IJO_415_20

Quick Response Code:



This is an open access journal, and articles are distributed under the terms of the Creative Commons Attribution-NonCommercial-ShareAlike 4.0 License, which allows others to remix, tweak, and build upon the work non-commercially, as long as appropriate credit is given and the new creations are licensed under the identical terms.

For reprints contact: WKHLRPMedknow_reprints@wolterskluwer.com

Cite this article as: Banerjee P, Alam MS, Koka K, Pherwani R, Noronha OV, Mukherjee B. Role of neuroimaging in cases of primary and secondary hemifacial spasm. Indian J Ophthalmol 2021;69:253-6.

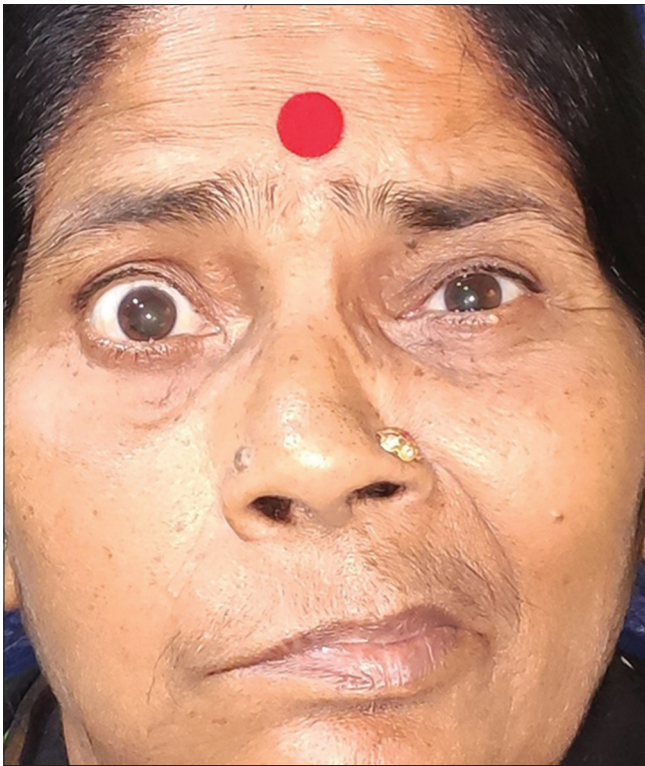

Figure 1: External coloured photograph of a patient showing left primary hemifacial spasm

accomplished with Statistical Package for Social Sciences (SPSS Inc. Chicago, IL, version 22.0).

Results

A total of 202 patients were included in the study. The study comprised of 110 males (54.46%) and 92 females (45.54%). The mean age of the study population was 51.81 ± 11.76 years (Range 15-83 years) and the mean age of onset of the spasms was 48.68 years (Range 14.5-75.5 years) [Table 1]. The right side was involved in 104 patients (51.48%), the left side was found to be involved in 97 patients (48.02%). One patient (0.50%) had bilateral involvement. The mean duration of the symptoms was calculated to be 37.80 ± 38.17 months (Range 5-240 months).

Out of 202 patients, 183 patients (90.59%) had primary HFS (Male = 101, female = 82) and 19 patients (Male = 9, Female = 10) constituted secondary HFS (9.41%). The mean age of the primary HFS group was found to be 52.29 ± 1.41 years (Range 15-80 years) and the mean age of onset of the spasms in this group was noted as 49.26 ± 8.35 years (Range 14.5-75.5 years). The right side: left side ratio was 1.07:1.

Hypertension was the most prevalent systemic disease ($n = 50$, 24.75%) in our study sample followed by diabetes mellitus ($n = 13$, 6.43%), hypothyroidism ($n = 7$, 3.46%) and dyslipidemia ($n = 4$, 1.98%).

Neuroimaging revealed anterior inferior cerebellar artery (AICA) to be the most common vessel compressing the facial nerve at the root exit zone ($n = 55$, 37.93%) followed by posterior inferior cerebellar artery (PICA) ($n = 40$, 27.59%), vertebral artery (VA) ($n = 29$, 20%), PICA and VA together ($n = 6$, 4.14%), vascular loop whose exact anatomy could not be identified ($n = 6$, 4.14%) [Fig. 2], vertebrobasilar artery (VBA) ($n = 5$, 3.45%) [Fig. 3], vertebrobasilar artery dolichoectasia ($n = 2$, 1.37%), AICA and VA together ($n = 1$,

Table 1: Demographic details of the study population

Number of patients (n)	202 patients
Mean duration of symptoms	37.80 ± 38.17 months (Range 5-240 months)
Laterality	Right=104 (51.48%) Left=97 (48.02%) Bilateral=1 (0.50%)
Sex	Male=110 (54.46%) Female=92 (45.54%)
Type of HFS	Primary HFS (n) = 183 (90.59%), Male=101, female=82 Secondary HFS (n) = 19 (9.41%), Male=9, Female=10
Etiology of Primary HFS	AICA=55 (37.93%) PICA=40 (27.59%) VA=20 (29%) PICA + VA=6 (4.14%) Vascular loop=6 (4.14%) VBA=5 (3.45%) VBA dolichoectasia=2 (1.37%) AICA + VA=1 (0.69%) Cavernoma=1 (0.69%)
Etiology of Secondary HFS	Facial nerve palsy=13 CPA meningioma=2 CPA cyst=2 Vestibular schwannoma=1 Inferior cerebellar artery aneurysm=1

HFS – Hemifacial spasm, AICA – Anterior inferior cerebellar artery,

PICA – Posterior inferior cerebellar artery, VA-Vertebral artery,

VBA – Vertebrobasilar artery, CPA – Cerebellopontine angle

0.69%) and congenital vascular malformation ($n = 1$, 0.69%). Thirty eight of the remaining patients had no abnormality noted on neuroimaging.

Nine male patients and 10 female patients were found to have secondary HFS [Table 2]. The mean age of the secondary HFS group was computed to be 48.63 ± 14.48 years (Range 20–83). The mean age of onset of the involuntary contractions was found to be 43.13 ± 12.12 (Range 18-63 years). The left side was more commonly involved in secondary HFS ($n = 10$, 52.63%). HFS secondary to facial nerve palsy was observed in 13 patients (68.42%). Out of 13 facial nerve palsy cases, 4 were due to trauma. HFS following facial nerve palsy was more subtle and could be elicited better on voluntary facial contractions. In the secondary HFS group, Cerebellopontine angle (CPA) tumors comprising meningioma ($n = 2$) and schwannoma ($n = 1$) were found to be other important etiological factors. CPA cyst was noted in 2 cases (10.52%). One case had an aneurysm of the posterior inferior cerebellar artery.

Discussion

The present study found that primary HFS is the more prevalent form and has a slight male preponderance. Neurovascular conflict by AICA was recognized to be the most common cause of Primary HFS whereas most of the cases of secondary HFS were preceded by facial nerve palsy.

HFS is unilateral, progressive, clonic, and tonic contractions of the muscles of facial expression.^[1] Based on etiology, HFS can be primary and secondary.^[3,4] Primary HFS is usually caused by a neurovascular conflict at the root exit zone (REZ) of the facial nerve. The root exit zone is susceptible to neurovascular conflicts as the nerve at REZ does not possess an epineurium

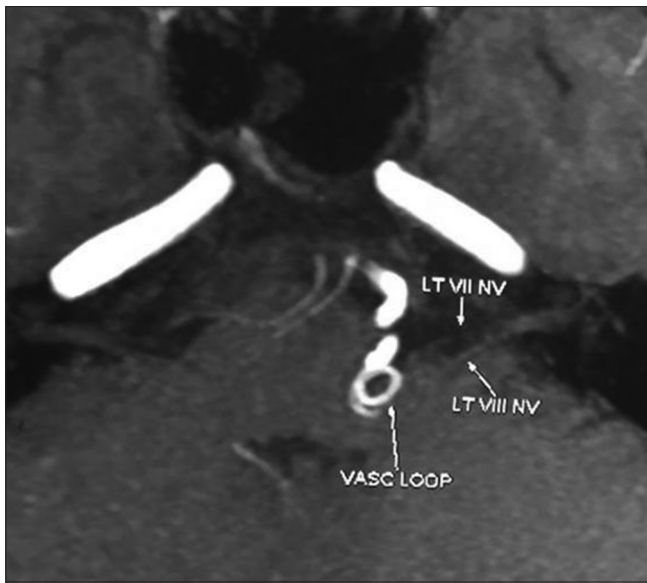


Figure 2: MRA showing left facial nerve compression at REZ by unidentified vascular loop

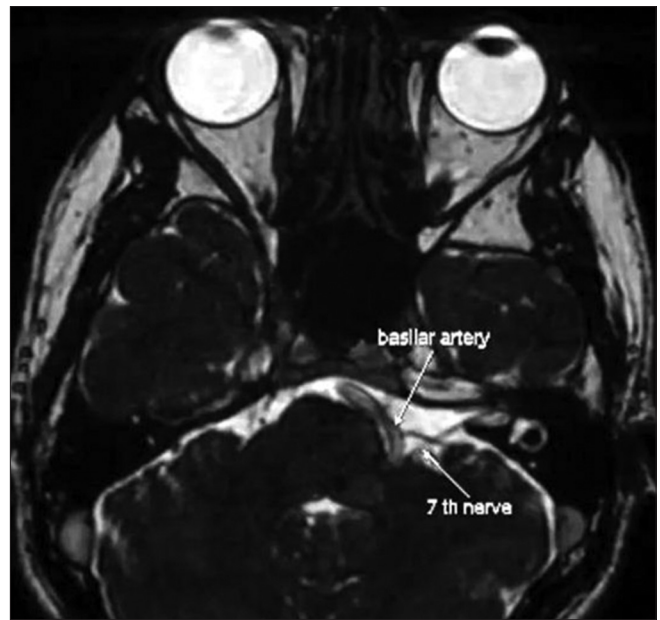


Figure 3: MRI Brain showing left facial nerve compression at REZ by vertebrobasilar artery

Table 2: Comparison of Primary and Secondary HFS

Parameters	Primary HFS	Secondary HFS
Mean age (years)	52.29 ± 1.41	48.63 ± 14.48
M:F	1.23:1	0.9:1
Mean age of onset (years)	49.26 ± 8.35	43.13 ± 12.12
Laterality	Right = 95 Left = 87 Bilateral = 1	Right = 9 Left = 10

HFS – Hemifacial spasm, M – Male, F – Female

and the individual fascicles lack septa. Moreover, the REZ is a transition zone of myelination from central oligodendrocyte cells to peripheral Schwann cells.^[6-8] Development of primary HFS beyond the 5th decade can be attributed to the senile changes in the walls of the blood vessels i.e., loss of elasticity resulting in an ectatic blood vessel. Hypertensive patients are more likely to develop degenerative changes in the blood vessel as already been reported by Defazio *et al.*^[9,10] In the present study we found hypertension to be the most prevalent systemic association in the HFS patients, thus reinforcing the findings of Defazio *et al.* The compression of the nerve by the vessels at the REZ leads to localized demyelination which in turn induces aberrant movements. The “central” hypothesis of hyperexcitability of the facial motor nucleus and the “peripheral” hypothesis of ephaptic and ectopic impulse conduction at REZ had been proposed to be the underlying mechanism of these involuntary movements.^[11,12] Few recent studies have suggested the role of functional MRI (fMRI) to further elucidate the pathogenesis and effect of HFS on various neurological structures and functions. Tu Ye *et al.* have noted an association between HFS and abnormal spontaneous brain activity in regions most involved in motor control and blinking.^[13] They utilized fMRI with regional homogeneity analysis in these particular brain areas. Xu H *et al.* noted a significant reduction in the volume of the right amygdala in patients of HFS.^[14] However these studies are still evolving and in the future, these should provide us with more insight into the pathophysiology of HFS. At present fMRI is available at very few centres across the country and it would not be practical to order fMRI in cases of HFS for the purpose of management.

On neuroimaging, the chief conflicting vessel was noted to be AICA. Our finding corroborates the research work conducted by Batla and Miller *et al.*^[15,16] However, few reports have also stated PICA to be the major conflicting vessels.^[17] Primary HFS was 10 times more common than secondary HFS, as noted by our study, thus echoing the findings of the previous study groups.^[15] As established in previous literature, Bell’s palsy was the leading cause of secondary HFS.^[12] Other important etiologies that surfaced from our study were CPA angle tumor and cyst and inferior cerebellar artery aneurysm. HFS associated with tumor contributes to 0.3 – 2.5% of all HFS and it takes into account meningioma, vestibular schwannoma, lipoma, epidermoid tumors, and glioma, arising from the CPA.^[18,19] Besides CPA tumor; vascular aneurysms, CPA cysts, and demyelinating neuropathy have a small contribution in secondary HFS.^[6] On comparing the primary HFS group with the secondary HFS group, we didn’t find any significant difference ($P > 0.05$) in the mean age of the population, mean age of onset, and the laterality. Hence, we can infer that unless an HFS patient comes with signs of facial nerve palsy or associated hearing loss, we cannot ascertain the type of HFS and the underlying etiopathology. Also, HFS secondary to facial nerve palsy was found to be more subtle and was evoked by facial contractions. In other words, HFS can be the early presentation of CPA tumors and it may get overlooked unless we recommend neuroimaging for all the HFS patients.

Although CPA tumors, cyst, and aneurysm constitute a small percentage, they can lead to permanent neurological deficits if not detected at an early stage and can be life-threatening too. Early diagnosis of these treatable lesions aid in proper management in the form of tumor resection and microvascular decompression (MVD) and patients can be made symptom free.^[20,21] Moreover, in primary HFS, the curative treatment is MVD whereas botulinum toxin and anticonvulsant therapy provide palliation and short term relief.^[16,22] It is important to note the diameter, height, and position of the basilar artery while performing MVD; especially in cases of vertebrobasilar dolichoectasia.^[23] Time of Flight MRI (TOF) should be requested to gather these pieces of information.^[23] Though these are of significance to the treating neurosurgeon; we did not look

for these in our patients since none of our patients were motivated to undergo surgical treatment and were satisfied with the conservative management in the form of an injection of the botulinum toxin. Furthermore, we just had 2 cases of vertebrobasilar dolichoectasia in our case series. The treatment results are out of the scope of the present article.

Magnetic Resonance Angiogram (MRA) is the investigation of choice for diagnosing various intracranial pathologies responsible for primary and secondary HFS. Though we recommend neuroimaging in all cases of HFS. The logistics of getting the imaging done in a tertiary eye care setup remains an issue since the patient has to be referred to a radiology center. Another important issue is the cost factor. In a developing country like India, where patients find it difficult to get investigations done for many other serious issues, they might not be motivated enough to spend money on neuroimaging for a condition that apparently seems cosmetic.

Conclusion

Our study helps us to draw the inference that hemifacial spasm occurs mostly in individuals in their fifties or late forties and primary HFS is more prevalent than secondary HFS. Apart from facial nerve palsy, the clinical diagnosis of the entities is not possible. For primary HFS, MVD is curative therapy and neuroimaging is necessary to detect the conflicting vasculature. Secondary HFS, although constitutes a small percentage, can lead to permanent neurological deficit if left unattended. Hence neuroimaging, in the form of MRI brain and MRA, is mandatory in all patients presenting with HFS to clinch the diagnosis and plan further management.

Declaration of patient consent

The authors certify that they have obtained all appropriate patient consent forms. In the form the patient(s) has/have given his/her/their consent for his/her/their images and other clinical information to be reported in the journal. The patients understand that their names and initials will not be published and due efforts will be made to conceal their identity, but anonymity cannot be guaranteed.

Financial support and sponsorship

Nil.

Conflicts of interest

There are no conflicts of interest.

References

- Evidente VGH, Adler CH. Hemifacial spasm and other craniofacial movement disorders. *Mayo Clin Proc* 1998;73:67-71.
- Kong D, Park K. Hemifacial spasm: A neurosurgical perspective. *J Korean Neurosurg Soc* 2007;42:355-62.
- Janetta PJ, Abbasy M, Maroon JC, Ramos FM, Albin MS. Etiology and definitive microsurgical treatment of hemifacial spasm. *J Neurosurg* 1977;47:321-8.
- Yaltho TC, Jankovic J. The many faces of hemifacial spasm: Differential diagnosis of unilateral facial spasms. *Mov Disord* 2011;26:1582-92.
- Auger RG, Whisnant JP. Hemifacial spasm in Rochester and Olmstead County, Minnesota, 1960 to 1984. *Arch Neurol* 1990;47:1233-4.
- Rosenstengel C, Matthes M, Baldauf J, Fleck S, Schroeder H. Hemifacial spasm: Conservative and surgical treatment options. *Dtsch Arztebl Int* 2012;109:667-73.
- Nielsen VK. Electrophysiology of the facial nerve in hemifacial spasm: Ectopic/ephaptic excitation. *Muscle Nerve* 1985;8:545-55.
- Guclu B, Sindou M, Meyronet D, Streichenberger N, Simon E, Mertens P. Cranial nerve vascular compression syndromes of the trigeminal, facial and vago-glossopharyngeal nerves: Comparative anatomical study of the central myelin portion and transitional zone; Correlations with incidences of corresponding hyperactive dysfunctional syndromes. *Acta Neurochir (Wien)* 2011;153:2365-75.
- Defazio G, Berardelli A, Abbruzzese G, Coviello V, De Salvia R, Federico F, et al. Primary hemifacial spasm and arterial hypertension: A multicenter case-control study. *Neurology* 2000;54:1198-200.
- Defazio G, Martino D, Aniello MS, Masi G, Logroscino G, Manobianca G, et al. Influence of age on the association between primary hemifacial spasm and arterial hypertension. *J Neurol Neurosurg Psychiatry* 2003;74:979-81.
- Choi SI, Kim MW, Park DY, Huh R, Jang DH. Electrophysiologic investigation during facial motor neuron suppression in patients with hemifacial spasm: Possible pathophysiology of hemifacial spasm: A pilot study. *Ann Rehabil Med* 2013;37:839-47.
- Lu AY, Yeung JT, Gerrard JL, Michaelides EM, Sekula RF Jr, Bulsara KR. Hemifacial spasm and neurovascular compression. *ScientificWorldJournal* 2014;2014:349319. doi: 10.1155/2014/349319.
- Tu Y, Wei Y, Sun K, Zhao W, Yu B. Altered spontaneous brain activity in patients with hemifacial spasm: A resting-state functional MRI study. *PLoS One* 2015;10:e0116849.
- Xu H, Guo C, Li H, Gao L, Zhang M, Wang Y. Structural and functional amygdala abnormalities in hemifacial spasm. *Front Neurol* 2019;10:393.
- Batla A, Goyal C, Shukla G, Goyal V, Srivastava A, Behari M. Hemifacial spasm: Clinical characteristics of 321 Indian patients. *J Neurol* 2012;259:1561-5.
- Miller LE, Miller VM. Safety and effectiveness of microvascular decompression for treatment of hemifacial spasm: A systematic review. *Br J Neurosurg* 2012;26:438-44.
- Mercier P, Sindou M. The conflicting vessels in hemifacial spasm: Literature review and anatomical implications. *Neurochirurgie* 2018;64:94-100.
- Han H, Chen G, Zuo H. Microsurgical treatment for 55 patients with hemifacial spasm due to cerebellopontine angle tumors. *Neurosurg Rev* 2010;33:335-40.
- Sprick C, Wirtschafter JD. Hemifacial spasm due to intracranial tumor: An international survey of botulinum toxin investigators. *Ophthalmology* 1988;95:1042-5.
- Elgamal EA, Coakham HB. Hemifacial spasm caused by pontine glioma: Case report and review of the literature. *Neurosurg Rev* 2005;28:330-2.
- Castiglione M, Broggi M, Cordella R, Acerbi F, Ferroli P. Immediate disappearance of hemifacial spasm after partial removal of ponto-medullary junction anaplastic astrocytoma: Case report. *Neurosurg Rev* 2015;38:385-90.
- Dannenbaum M, Lega BC, Suki D, Harper RL, Yoshor D. Microvascular decompression for hemifacial spasm: Long-term results from 114 operations performed without neurophysiological monitoring. *J Neurosurg* 2008;109:3:410-5.
- Kang JH, Kang DW, Chung SS, Chang JW. The effect of microvascular decompression for hemifacial spasm caused by vertebrobasilar dolichoectasia. *J Korean Neurosurg Soc* 2012;52:85-91.