

# Ewing's sarcoma in mandibular similar to dental abscess

Forouz Keshani, Gholamreza Jahanshahi<sup>1</sup>, Bijan Movahedian Attar<sup>2</sup>, Mahsa Kalantari<sup>1</sup>, Seyed Mohammad Razavi<sup>1</sup>, Zahra Hashemzade<sup>3</sup>, Payam Tavakoli<sup>4</sup>

Dental Caries Prevention Research Center, Qazvin University of Medical Sciences, <sup>1</sup>Department of Oral and Maxillofacial Pathology, School of Dentistry, Isfahan, Iran <sup>2</sup>Department of Oral and Maxillofacial Surgery, Dental School, Isfahan, Iran <sup>3</sup>Rafsanjan University of Medical Sciences, <sup>4</sup>Kermanshah University of Medical Sciences

## Abstract

Ewing's sarcoma is a rare malignant neoplasm that comprises approximately 4-6% of primary bone tumors. In most cases, femur and pelvis are affected, and less commonly the head and neck areas (in the jaws, usually the mandible). These tumors have been reported more frequently in males, mostly aged 5-20 years old. Systemic symptoms and signs such as fever, weight loss, anemia, leukocytosis, and elevated erythrocyte sedimentation rate (ESR) may be the first signs in oral Ewing's sarcoma. Such signs and symptoms are also seen in odontogenic infections and abscess. In one case, the patient went to a dentist with pain, swelling, and abscess similar to odontogenic infection and patient's tooth was pulled due to misdiagnosis. This tumor has an aggressive clinical behavior and is identified with rapid growth and high probability of metastasis at diagnosis. Thus, it is necessary to differentiate it from a dental abscess. As for the treatment of Ewing's sarcoma, first the tumor must undergo chemotherapy to reduce its size and, eventually, it undergoes extensive surgery.

This case report deals with a 16-year-old patient wrongly diagnosed with odontogenic infection and abscess, and hospitalized. As the symptoms did not remit, biopsy was carried out and the patient was operated on with Ewing's sarcoma diagnosis.

**Key Words:** Dental abscess, Ewing's sarcoma, mandible

## Address for correspondence:

Dr. Seyed Mohammad Razavi, Department of Oral and Maxillofacial Pathology, School of Dentistry, Isfahan, Iran. E-mail: razavi@dnt.mui.ac.ir

**Received:** 06.01.2013, **Accepted:** 15.01.2013

## INTRODUCTION

Ewing's sarcoma was first introduced by James Ewing in 1921. This is a rare and highly lethal malignant neoplasm of the bone and is composed of small round cells with uncertain histogenesis.<sup>[1]</sup>

Ewing's sarcoma is responsible for about 4-40% of all bone tumors and commonly involves long bones and the pelvis.<sup>[2,3]</sup> Lesions with Ewing's sarcoma diagnosis comprise only 1-4% of head and neck lesions and most cases are associated with the mandible.<sup>[4,5]</sup>

Recent studies indicate that most Ewing's sarcoma cases have had their origins in neuroectodermal tumors.<sup>[6]</sup> This neoplasm usually affects adolescent and young adult males.<sup>[2,5]</sup> In clinical terms, this tumor has an aggressive behavior and is identified with rapid growth and high probability of metastasis at diagnosis.<sup>[7]</sup>

This report introduces the case of a 16-year-old patient with Ewing's sarcoma in the posterior mandible, who

Access this article online	
Quick Response Code:	Website: www.advbiores.net
	DOI: 10.4103/2277-9175.125841

Copyright: © 2014 Keshani. This is an open-access article distributed under the terms of the Creative Commons Attribution License, which permits unrestricted use, distribution, and reproduction in any medium, provided the original author and source are credited.

**How to cite this article:** Keshani F, Jahanshahi G, Attar BM, Kalantari M, Razavi SM, Hashemzade Z, *et al.* Ewing's sarcoma in mandibular similar to dental abscess. Adv Biomed Res 2014;3:62.

was wrongly diagnosed for odontogenic infection and abscess, and hospitalized.

## CASE REPORT

The patient was a 16-year-old girl who visited a dentist complaining of toothache in the summer 2010.

While dealing with the tooth, a prominent lesion was detected and removed along with the tooth. The pain did not subside, and the patient returned with pain and swelling in the mandibular angle accompanied by numbness of lower lip. She was diagnosed with abscess and was admitted to the Ear, Nose and Throat (ENT) department of a hospital where the abscess was drained. Even after the drainage, the pain still persisted; therefore, part of the tissue was removed with incisional biopsy and sent to the oral and maxillofacial department at Faculty of Dentistry. It is noteworthy that bone destruction was not observed in panoramic radiography [Figure 1].

In the horizontal and vertical computed tomography (CT) scan, a clear reduction in trabeculation with indistinct boundary was observed in the mandible posterior to the first molar region [Figure 2].

According to the images, the differential diagnosis of indistinct osteolytic lesions comprises histiocytosis X, Ewing's sarcoma, lymphoma, and osteomyelitis.

The sample contained several pieces of yellowish cream tissue, irregularly shaped with a rubbery texture. Histopathological figure has been shown colonies of proliferation of cells with dysplastic changes such as extensive cytoplasm and large nuclei, prominent small nucleolus, mitotic figures, and polymorphism in stromal connective tissue with wide areas of necrosis [Figure 3].

Accordingly, round cell tumors including Ewing's sarcoma, lymphoma (comprising anaplastic large cell lymphoma, and diffuse large cell lymphoma), metastatic carcinoma, muscular tumors (including rhabdomyosarcoma), and neuroblastoma were included in the differential diagnosis. In order to make differential diagnosis using immunohistochemical (IHC) techniques, the following indicators were assessed and results obtained were [Figure 4]:

Cytokeratin (CK) = -, Desmin = -, S100 = +

Leukocyte Common Antigen (LCA) = -, Vimentin = +, CD99 = strongly +

Metastatic carcinoma, muscular tumors, and a variety of lymphomas were ruled out due to negative CK,

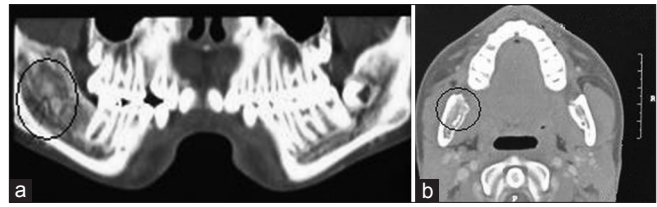


Figure 1: (a) Horizontal CT-scan, (b) coronal CT-scan

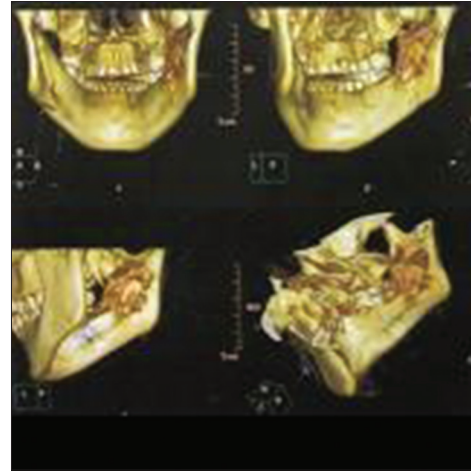


Figure 2: Topography of the bone

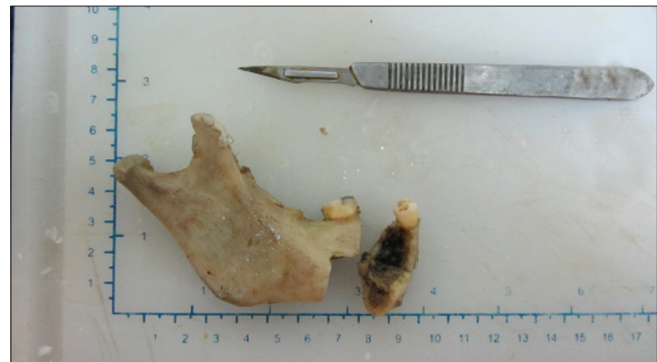

Figure 3: Macroscopic view of mandibulectomy

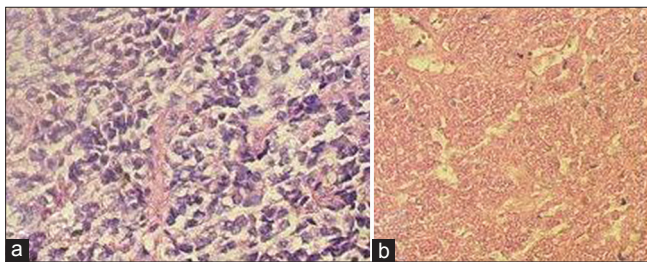
Desmin, and LCA, respectively. Also, due to positive CD99 neuroblastoma was ruled out too, and with strongly positive CD<sub>99</sub> and Vimentin, the diagnosis of Ewing's sarcoma was confirmed.

With this diagnosis, the patient began to undergo combination chemotherapy (Vincristine, Cyclophosphamide, Adriamycin, Iphosphamide, Etoposide) to reduce lesion's size, and then she underwent mandibulectomy by an oral and maxillofacial surgeon to remove lesions. The lesion, mandibular nerve, and sub-mandibular lymph nodes were sent to the pathology department of the oral and maxillofacial department of the dentistry faculty for the final assessment.



In the macroscopic view, there was a piece of bone including the right half of mandible from premolar region to the end of ascending ramus containing posterior tooth and inferior alveolar nerve and sub-mandibular lymph node [Figure 4].

In the histopathological figure, serial sections have been shown areas of bone trabeculae along with normal bone marrow spaces full of hematopoietic cells, fat cells, and areas of necrosis, and hemorrhage. In addition, in slides of the medial section of lower ramus and mandibular medial angle, only a remnant of tumoral cells, including some colonies of proliferation of cells with expansive cytoplasm, unclear boundary, and large nuclei, were seen. The diagnosis of Ewing's sarcoma was established based on these and initial IHC panel, CT scan, and radiography findings. Also, nerve sample and tumor-free lymph nodes were observed [Figure 5]. It appears that tumor has responded to chemotherapy, and after follow-up, mandibulectomy, chemotherapy, and CT scan of the bone, systemic condition of the patient has improved.

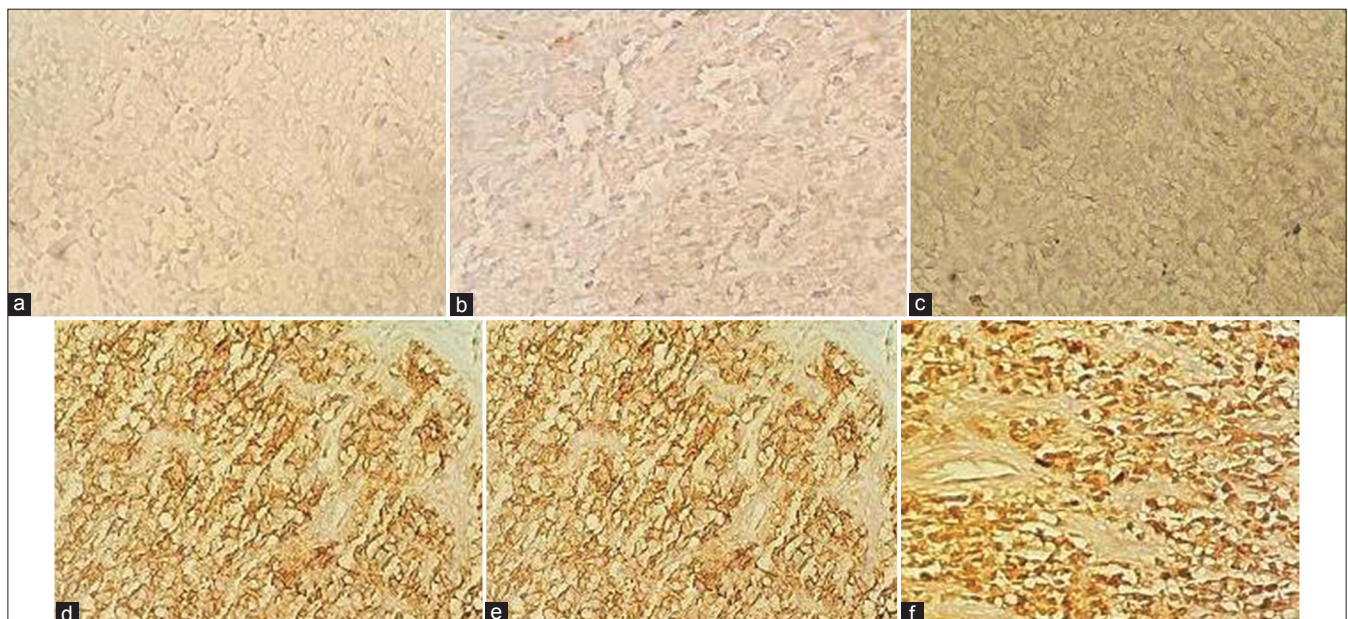


**Figure 4:** (a) Microscopic view of the lesion with H and E staining  $\times 400$ , (b) necrosis

## DISCUSSION

Ewing's sarcoma is a rare malignant neoplasm that comprises approximately 4-6% of the primary bone tumors. Up to 50% of cases involve femur and pelvis, and 1-4% involves head and neck regions. Mandible is often affected when jaws are involved.<sup>[2]</sup> In 85-90% of cases, tumor cells have shown a displacement between chromosome 11 and chromosome 22 (q24; q21) (11, 22).<sup>[6]</sup> Majority of patients are males aged 5-20 years old.<sup>[8]</sup> Clinical findings of Ewing's sarcoma in the head and neck regions have been non-specific and usually involve rapid growth, swelling, and pain.<sup>[2]</sup> Moreover, when mandible is involved, loosening of teeth, middle ear infection, and paresthesia are not uncommon.<sup>[9]</sup> Systemic symptoms such as fever, weight loss, anemia, leukocytosis, and elevated erythrocyte sedimentation rate (ESR) are also seen in some patients. These symptoms may be the first signs of oral Ewing's sarcoma, which are also seen in dental infections (abscess). Gosau *et al.*, also found symptoms similar to odontogenic abscess in a 24-year-old man with Ewing's sarcoma.<sup>[10]</sup> In this case too, the patient visited the dentist with symptoms of pain, swelling, and abscess similar to odontogenic illness, and had his tooth removed due to the wrong diagnosis.

This tumor appears as an osteolytic lesion with vague boundaries in radiography and can be accompanied by the wearing of cortical surface and creating a mass in the soft tissue adjacent to the damaged site. However, this picture is not specific to this disease and may also be seen in other lesions like neuroblastoma,



**Figure 5:** (a) CK staining, (b) LCA, (c) DES, (d) VIM, (e) s100, (f) CD99

osteogenic sarcoma, histiocytosis X, lymphoma, and osteomyelitis.<sup>[2]</sup>

According to a report by Brazao-Silva *et al.*, the sunburst appearance through periosteal bone and displacement or destruction of immature dental follicle can be regarded as the most common radiographic presentation of Ewing's sarcoma of the jaws.<sup>[2]</sup> Although conventional X-ray is still used for bone lesions, other imaging methods like magnetic resonance imaging (MRI) and CT scan are highly recommended for accurate evaluation of lesion's progress on soft tissue and bone before initiation of treatment.<sup>[11]</sup> CT scan was also used in this case to determine the extent and aggression of the tumor. Furthermore, bone scintigraphy was performed to evaluate bone metastases.

The histopathological presentation of Ewing's sarcoma includes layers of small poorly differentiated cells with unclear boundary and little cytoplasm with round or oval nucleus and a variety of growth patterns including diffused lobular and trabecular and pseudo rosette with extensive areas of necrosis and hemorrhage. Mitotic figures are uncommon in Ewing's sarcoma.<sup>[1,2,6]</sup> However, in this case, large cells were observed in the histopathological presentation. In 75% of cases, due to the presence of intracytoplasmic glycogen granules, Periodic Acid Schiff (PAS) staining is positive, which helps the diagnosis, but is not specific, as other tumors with small round cells also turn PAS positive.<sup>[12,13]</sup> Considering microscopic presentation in this case, the following differential diagnoses can be considered: muscle sarcoma (including Rhabdomyosarcoma), metastatic carcinoma, and different types of lymphoma (including anaplastic large cell lymphoma, diffuse large cell lymphoma). For a definite diagnosis, muscular markers (like desmin), CK markers, and LCA are used, respectively, and the proposed differential diagnoses are ruled out if these markers are negative. Also, with detection of positive CD99, the diagnosis of neuroblastoma is ruled out and Ewing's sarcoma is confirmed with positive CD99 and Vimentin.

Current treatment of Ewing's sarcoma involves a combination of surgery and radiation therapy and combination chemotherapy that increase survival rates of patients by 40-80%. Radiotherapy alone can only be done in cases where the primary tumor cannot be removed. Abdel Rahman *et al.*, reported that chemotherapy is used as an adjuvant treatment to reduce lesion size.<sup>[5]</sup> The present patient, too, underwent combination chemotherapy consisting of Vincristine, Cyclophosphamide, Iphosphade, Adriamycin, and Etoposide to reduce lesion size, and after 12 sessions, the lesion was removed by

surgery. In the histopathological presentation, it was clear that almost 100% of the tumor had responded to chemotherapy and no evidence of the tumor was left. Prognosis of Ewing's sarcoma is weak after a few months due to lung metastases and invasion.<sup>[2,14]</sup> Sharada *et al.*, reported that poor prognosis is associated with the presence of systemic symptoms, age under 10 years, pelvic lesions, the presence of metastasis, large tumors, high mitotic rate, and poor response to chemotherapy. Due to early detection, tumors arising from the jaw bone have a better prognosis than long bone tumors.<sup>[1]</sup> Fortunately, the condition of this case, after completion of systemic chemotherapy and subsequent bone scintigraphy was satisfactory and no evidence of recurrence or metastasis is observed.

## CONCLUSION

Ewing's sarcoma of the bone is an uncommon malignancy that rarely occurs in the jaw and as it is mistaken for odontogenic infections, it should be carefully examined clinically, and because of similarity in microscopic presentation with other small round cell tumors, the diagnosis is often difficult. This tumor has the best prognosis if lesion is detected and reduced by chemotherapy early and removed by surgery.

It is recommended that dentists dealing with patients, who have pain and dental lesions, take medical history, perform careful clinical and radiographic examinations, and if necessary, consider referral to appropriate specialists for further follow-up of patients.

## REFERENCES

1. Sharada P, Girish HC, Umadevi HS, Priya NS. Ewing's sarcoma of the mandible. *J Oral Maxillofac Pathol* 2006;10:31-5.
2. Brazão-Silva MT, Fernandes AV, Faria PR, Cardoso SV, Loyola AM. Ewing's sarcoma of the mandible in a young child. *Braz Dent J* 2010;21:74-9.
3. Vikas PB, Ahmed MB, Bastian TS, David TP. Ewing's sarcoma of the maxilla. *Indian J Dent Res* 2008;19:66-9.
4. Schultze-Mosgau S, Thorwarth M, Wehrhan F, Holter W, Stachel KD, Grabenbauer G, *et al.* Ewing sarcoma of the mandible in a child: Interdisciplinary treatment concepts and surgical reconstruction. *J Craniofac Surg* 2005;16:1140-6.
5. Rahman HA, El-Baradie T, El-Baradie M, Bahaa S, Shalan M. Management head and neck ewing's sarcoma family of tumors: Experience of the National Cancer Institute, Cairo University. *J Egypt Natl Canc Inst* 2010;22:41-7.
6. Neville BW, Dam DD, Allen CM, Bouqupt JE. *Oral and Maxillofacial Pathology*. 3<sup>rd</sup> ed. Saunders; 2009. p. 667-9.
7. Lopes SL, Almeida SM, Costa AL, Zanardi VA, Cendes F. Imaging findings of Ewing s sarcoma in the mandible. *J Oral Sci* 2007;49:167-71.
8. Heare T, Hensley MA, Dell'Orfano S. Bone tumors: Osteosarcoma and Ewing's sarcoma. *Curr Opin Pediatr* 2009;21:365-72.
9. Khoury JD. Ewing sarcoma family of tumors. *Adv Anat Pathol* 2005;12:212-20.

10. Gosau M, Baumhoer D, Ihrler S, Kleinheinz J, Driemel O. Ewing sarcoma of the mandible mimicking an odontogenic abscess: A case report. *Head Face Med* 2008;4:24.
11. Gorospe L, Fernández-Gil MA, García-Raya P, Royo A, López-Barea F, García-Miguel P. Ewing's sarcoma of the mandible: Radiologic features with emphasis on magnetic appearance. *Oral Surg Oral Med Oral Pathol Oral Radiol Endod* 2001;91:728-34.
12. Quesada JL, Alcalde JM, Espinosa JM, García-Tapia R. Ewing's sarcoma of the mandible. *J Laryngol Otol* 2003;117:736-8.
13. Talesb KT, Motamedi MH, Jeihounian M. Ewing's sarcoma of the mandibular condyle: Report of a case. *J Oral Maxillofac Surg* 2003;61:1216-9.
14. Berk R, Heller A, Heller D, Schwartz S, Klein EA. Ewing's sarcoma of the mandible: A case report. *Oral Surg Oral Med Oral Pathol Oral Radiol Endod* 1995;79:159-62.

**Source of Support:** Nil, **Conflict of Interest:** None declared.