

Effect of CT manifestations of cholesteatoma on MMP-2, MMP-9 and IL-6 in the serum of patients

YINGZHE WU¹, XIANGLI TANG¹, WEIFANG SHAO² and YUEZHONG LU¹

¹Department of Radiology and ²Clinical Laboratory, Changxing People's Hospital, Huzhou, Zhejiang 313100, P.R. China

Received November 27, 2018; Accepted April 2, 2019

DOI: 10.3892/etm.2019.7484

Abstract. Effect of CT manifestations of cholesteatomatous otitis media on matrix metalloproteinase-2 (MMP-2), matrix metalloproteinase-9 (MMP-9) and interleukin-6 (IL-6) in the serum of patients was investigated. A total of 176 patients with cholesteatomatous otitis media were enrolled as the study group and 181 patients with simple otitis media were enrolled as the control group. Patients were admitted to the Changxing People's Hospital from January 2010 to December 2016. The patients in the study group were classified according to the 64-row spiral CT diagnosis. The expression levels of MMP-2, MMP-9 and IL-6 in the serum of the selected patients were detected by ELISA. MMP-2, MMP-9 and IL-6 expression levels in the study group were higher than those in the control group ($P < 0.05$). MMP-2, MMP-9 and IL-6 expression levels in the serum of the patients with injured ossicular chain were significantly higher than those in the serum of patients with injured malleus or incus ($P < 0.05$), and significantly higher than those in the serum of patients with intact ossicular chain ($P < 0.05$). The levels of MMP-2, MMP-9 and IL-6 in the serum of the patients whose malleus or incus was injured were higher than those in the serum of the patients with intact ossicular chain ($P < 0.05$). There was an obvious positive correlation between the injury degree of different sclerotins in CT manifestations of the patients in the study group and MMP-2, MMP-9, and IL-6 ($P < 0.05$). The high expression levels of MMP-2, MMP-9 and IL-6 in the serum of patients with cholesteatomatous otitis media were positively correlated with the injury degree of ossicle, which may be a sign of poor prognosis of cholesteatomatous otitis media.

Introduction

Cholesteatomatous otitis media, also known as middle ear cholesteatoma, is an infectious disease in the ear (1). Cholesteatomatous otitis media is associated with the abnormal accumulation of squamous epithelium in keratin. The exfoliated epithelium continuously accumulates and expands around, causing the injury of ossicle and the impairment of audition (2,3). If cholesteatomatous otitis media spreads to the nerves, it may result in facioplegia, and patients may even be accompanied with a variety of serious intracranial and extracranial complications, which seriously endanger patients' life (4). At present, the main treatment method of cholesteatomatous otitis media in clinic is operative treatment, the purpose of which is to prevent intracranial complications (5). 'Early diagnosis, early treatment' is the key of treating cholesteatomatous otitis media. In clinic, cholesteatomatous otitis media is commonly detected by imageology, which is spiral CT (6,7). According to the reports of Rogha *et al* (8), the different extent and severity of the injury of sclerotin, which is caused by cholesteatomatous otitis media, can be observed using CT.

Matrix metalloproteinase-2 (MMP-2) and matrix metalloproteinase-9 (MMP-9), the core members of matrix metalloproteinases (MMPs) family, play an important role in various biological processes *in vivo* and in the anti-infective immunization of the body (9,10). Interleukin-6 (IL-6) is involved in the proliferation and differentiation of cells in anti-infective reactions and improves their functions (11). According to related study reports (12), the expression levels of MMP-2, MMP-9 and IL-6 are closely related to the clinical manifestations and the severity of diabetic diseases. However, studies on MMP-2, MMP-9 and IL-6, and the severity of cholesteatomatous otitis media are few (13). This study analyzed the expression levels of MMP-2, MMP-9 and IL-6 in the serum of patients with cholesteatomatous otitis media and injury degree of different sclerotin, in order to provide clinical value for the occurrence and development of cholesteatomatous otitis media, the prediction and prognosis of cholesteatomatous otitis media, and the diagnosis and treatment of it.

Correspondence to: Dr Yuezhong Lu, Department of Radiology, Changxing People's Hospital, 66 Taihuzhong Road, Changxing, Huzhou, Zhejiang 313100, P.R. China
E-mail: zuc9s7@163.com

Key words: cholesteatomatous otitis media, CT, matrix metalloproteinase-2, matrix metalloproteinase-9, interleukin-6

Patients and methods

Patient data. One hundred and seventy-six patients with cholesteatomatous otitis media, admitted to the Changxing

People's Hospital (Huzhou, China), from January 2010 to December 2016, and tested by 64-row spiral CT, were selected and enrolled as the study group. The study group included 91 males and 85 females, aged from 33 to 69 years old, with an average age of 49.65 ± 5.27 years, who were classified according to the presence or absence of injury of ossicle, and the extent and degree of injury. One hundred and eighty-one patients with simple otitis media were selected and enrolled as the control group, which included 98 males and 83 females, aged from 31 to 72 years, with an average age of 51.83 ± 5.39 years. Inclusion criteria: patients who had complete clinical data; and patients who had not received relevant diagnosis and treatment in other hospitals. Exclusion criteria: patients who had carious otitis media; who had middle ear cancer; patients in gestation or lactation period; who had other serious diseases or tumors; with communication disorders or cognitive dysfunction. The study was approved by the Ethics Committee of Changxing People's Hospital. Signed written informed consents were obtained from the patients and/or guardians. All subjects cooperated with the medical workers to finish the relevant diagnosis and treatment.

CT examination method. Philips 64-row spiral CT scanner (Philips Healthcare, Andover, MA, USA) was used. Patients were put in a supine position and the scanning parameters were: 120 kV; 150-200 mA; view field, 240x240 mm; matrix, 512x512; layer thickness, 0.5 mm. The scanning range was from the upper edge of talus cone to the tip of mastoid, and the layer thickness and layer spacing were both 1 mm. Window width was 4,000 Hu and window level was 700 Hu.

Detection method of the expression levels of MMP-2, MMP-9 and IL-6 in the serum of patients. Peripheral venous blood (4 ml) of the patients with cholesteatomatous otitis media was taken when they were fasting. The serum was separated from the blood by a centrifuge at a speed of $2,010 \times g$ for 10 min at 4°C , and it was stored in a refrigerator (Thermo Fisher Scientific, Inc., Waltham, MA, USA), in which the temperature was -20°C , for further detection. Enzyme-linked immunosorbent assay (ELISA) was used to detect the expression levels of MMP-2, MMP-9 and IL-6 in the serum of patients. The detection was performed strictly according to the manufacturer's instructions of human MMP-2 ELISA test kit (item no. H-EL-MMP-2; Shanghai Zeye Biotechnology Co., Ltd., Shanghai, China), human MMP-9 ELISA test kit (item no. RJ12726; Shanghai Renjie Biotechnology Co., Ltd., Shanghai, China) and human IL-6 ELISA test kit (item no. CS-ELISA3732; Shanghai Chunshi Biotechnology Co., Ltd., Shanghai, China). The kits and the samples to be tested were taken out from the refrigerator 30 min in advance and the temperature of them was equated with the room temperature. Then, standard well, blank well, and the well of sample to be tested were respectively established. A total of $50 \mu\text{l}$ of sample were accurately added into the standard well, $40 \mu\text{l}$ of sample diluent were added into the well of sample to be tested, and then $10 \mu\text{l}$ of the sample to be tested were added into it. After the mixture was mixed equably, the holes were sealed with a microplate sealer, and incubation followed at 37°C for 30 min. After this step, the microplate sealer was carefully uncovered, the liquid was discarded and the solution was

anhydrated. Then, each well was filled with $100 \mu\text{l}$ of washing solution, and after left to stand for 30 sec, the washing solution was discarded. This step was repeated 5 times and the solution was dried. Next, $100 \mu\text{l}$ of enzyme-labeling reagent were added into the standard well and the well of sample to be tested. A total of $50 \mu\text{l}$ of A color developing agent and B color developing agent were added into each well successively. The wells were covered with a film and the mixture was shaken gently and equably. The mixture was developed in the dark at 37°C for 15 min. Lastly, $50 \mu\text{l}$ of stop solution were added into each well. After the reaction of each well was stopped, an enzyme label analyzer (Shanghai Yaji Biotechnology Co., Ltd., Shanghai, China) was used to sequentially measure the absorbance (OD value) of each well at a wavelength of 450 nm and the concentrations of MMP-2, MMP-9 and IL-6 in the serum were calculated.

Statistical analysis. SPSS 17.4 software system (SPSS, Inc., Chicago, IL, USA) was used to carry out the statistical analysis. The basic enumeration data of the patients were expressed in the form of percentage [n (%)] and χ^2 test was used for their comparison. The expression levels of MMP-2, MMP-9 and IL-6 were expressed in the form of the mean \pm standard deviation, and t-test was used for the comparison of the differences between two groups, while ANOVA was used for the comparison of the differences between multiple groups, with Least Significant Difference test as the post hoc test. Spearman's correlation analysis was used to analyze the correlation between the injury degree of different sclerotin in CT manifestations of the patients in the study group and MMP-2, MMP-9 and IL-6 expression levels. $P < 0.05$ was considered to indicate a statistically significant difference.

Results

Comparison of the clinical data of the patients between the two groups. In order to ensure that the results of this study are accurate and credible, the clinical data of the patients between the two groups were compared. There was no obvious difference in sex, age, the presence or absence of headache, dizziness, facial paralysis and hearing loss of the patients between the two groups ($P > 0.05$), which proved that the patients in the two groups were comparable. The basic data of the patients are shown in Table I.

Comparison of the expression levels of MMP-2, MMP-9 and IL-6 between the study and the control group. The expression levels of MMP-2 in the study and the control group were 16.45 ± 4.87 and $14.98 \pm 4.51 \mu\text{g/l}$, respectively. MMP-2 expression level in the study group was higher than that in the control group, and the difference was statistically significant ($t = 2.960$, $P = 0.003$). The expression levels of MMP-9 in the study and the control group were 18.96 ± 6.16 and $17.15 \pm 5.58 \mu\text{g/l}$, respectively. MMP-9 expression level in the study group was higher than that in the control group, and the difference was statistically significant ($t = 2.911$, $P = 0.004$). The expression levels of IL-6 in the study and the control group were 25.31 ± 8.55 and $23.51 \pm 7.97 \mu\text{g/l}$, respectively. IL-6 expression level in the study group was higher than that in the control group, and the difference was statistically significant ($t = 2.058$, $P = 0.040$) (Fig. 1).

Table I. Basic data of patients [n (%)].

Factor	Study group (n=176)	Control group (n=181)	χ^2 value	P-value
Sex			0.213	0.644
Male	91 (51.70)	98 (54.14)		
Female	85 (48.30)	83 (45.86)		
Age (years)			0.400	0.527
≤ 45	71 (40.34)	79 (43.65)		
> 45	105 (56.66)	102 (56.35)		
Headache			3.136	0.077
Yes	119 (67.61)	106 (58.56)		
No	57 (32.39)	75 (41.44)		
Dizziness			0.433	0.511
Yes	137 (77.84)	146 (80.66)		
No	39 (22.16)	35 (19.34)		
Facial paralysis			1.528	0.216
Yes	151 (85.80)	163 (90.06)		
No	25 (14.20)	18 (9.94)		
Hearing loss			2.027	0.155
Yes	115 (65.34)	105 (58.01)		
No	61 (34.66)	76 (41.99)		
Injury degree of sclerotin			-	-
Ossicular chain is intact	58 (32.95)	-		
Malleus or incus is injured	61 (34.66)	-		
Ossicular chain is injured	57 (32.39)	-		

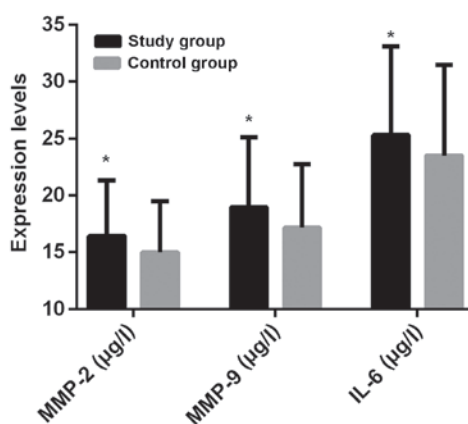


Figure 1. Comparison of the expression levels of MMP-2, MMP-9 and IL-6 between the study and the control group. The expression levels of MMP-2, MMP-9 and IL-6 in the study group were higher than that in the control group and the differences were statistically significant. * $P < 0.05$, compared to the control group. MMP-2, matrix metalloproteinase-2; MMP-9, matrix metalloproteinase-9; IL-6, interleukin-6.

Expression levels of MMP-2, MMP-9 and IL-6 in the patients of the study group with injury degree of different sclerotins in CT manifestations. i) The levels of MMP-2 in the serum of the patients whose CT manifestation showed that the ossicular chain was injured were significantly higher than those in the serum of the patients whose malleus or incus was injured, and the differences were statistically significant ($t=2.664$,

$P=0.009$). MMP-2 levels in the serum of the patients whose ossicular chain was injured were significantly higher than those in the serum of the patients with intact ossicular chain, and the differences were statistically significant ($t=7.140$, $P < 0.001$). Also, the levels of MMP-2 in the serum of the patients whose malleus or incus was injured were higher than those in the serum of the patients with intact ossicular chain, and the differences were statistically significant ($t=4.949$, $P < 0.001$).

ii) MMP-9 levels in the serum of the patients whose CT manifestation showed that ossicular chain was injured were significantly higher than those in the serum of the patients whose malleus or incus was injured, and the differences were statistically significant ($t=3.252$, $P=0.002$). The levels of MMP-9 in the serum of the patients whose ossicular chain was injured were significantly higher than those in the serum of the patients with intact ossicular chain, and the differences were statistically significant ($t=6.352$, $P < 0.001$). Also, the levels of MMP-9 in the serum of the patients whose malleus or incus was injured were higher than those in the serum of the patients with intact ossicular chain, and the differences were statistically significant ($t=3.033$, $P=0.003$).

iii) IL-6 levels in the serum of the patients whose CT manifestation showed that ossicular chain was injured were significantly higher than those in the serum of the patients, whose malleus or incus was injured, and the differences were statistically significant ($t=3.431$, $P=0.001$). The levels of IL-6 in the serum of the patients whose ossicular chain was injured were significantly higher than those in the serum of

Table II. Expression levels of MMP-2, MMP-9 and IL-6 in patients of the study group with injury degree of different sclerotins in CT manifestations.

Item	Ossicular chain is intact (n=58)	Malleus or incus is injured (n=61)	Ossicular chain is injured (n=57)	F value	P-value
MMP-2 ($\mu\text{g/l}$)	11.64 \pm 4.57	15.76 \pm 4.51 ^a	18.19 \pm 5.25 ^{a,b}	27.640	<0.001
MMP-9 ($\mu\text{g/l}$)	16.29 \pm 5.41	19.35 \pm 7.38 ^a	23.64 \pm 6.92 ^{a,b}	17.790	<0.001
IL-6 (mg/l)	19.57 \pm 8.39	23.92 \pm 9.48 ^a	30.61 \pm 11.65 ^{a,b}	18.080	<0.001

^aP<0.05, compared with the patients with intact ossicular chain in CT manifestation; ^bP<0.05, compared with the patients whose malleus or incus was injured in CT manifestation. MMP-2, matrix metalloproteinase-2; MMP-9, matrix metalloproteinase-9; IL-6, interleukin-6.

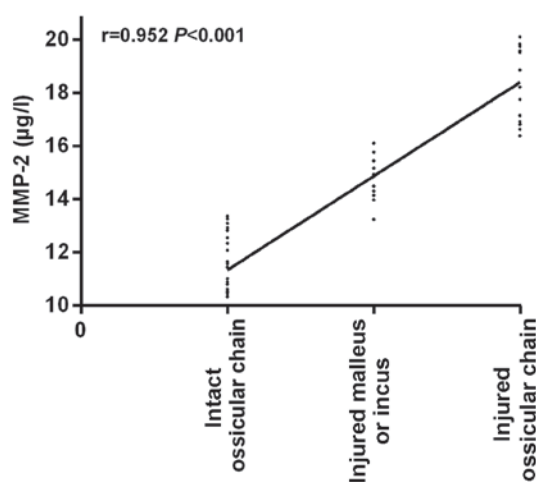


Figure 2. Correlation analysis of the injury degree of different sclerotins in CT manifestations of the patients in the study group and MMP-2. There was an obvious positive correlation between the injury degree of different sclerotins in CT manifestations and MMP-2 ($r=0.952$, $P<0.001$). MMP-2, matrix metalloproteinase-2.

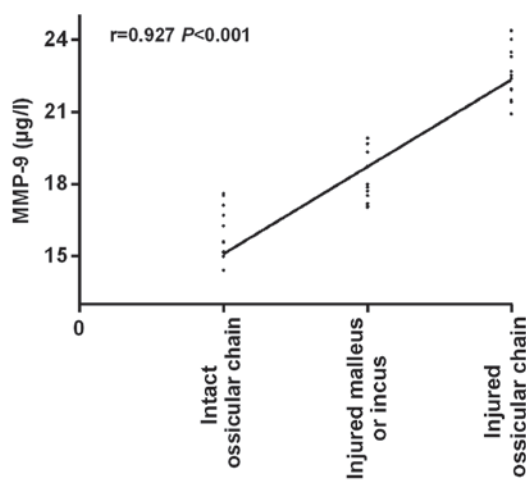


Figure 3. Correlation analysis of the injury degree of different sclerotins in CT manifestations of the patients in the study group and MMP-9. There was an obvious positive correlation between the injury degree of different sclerotins in CT manifestations and MMP-9 ($r=0.927$, $P<0.001$). MMP-9, matrix metalloproteinase-9.

the patients with intact ossicular chain, and the differences were statistically significant ($t=5.839$, $P<0.001$). Moreover, the levels of IL-6 in the serum of the patients whose malleus or incus was injured were higher than those in the serum of the patients with intact ossicular chain, and the differences were statistically significant ($t=2.646$, $P=0.009$) (Table II).

Correlation analysis between the injury degree of different sclerotins in CT manifestations of the patients in the study group and MMP-2. Spearman's correlation analysis showed that MMP-2 expression is positively correlated with the injury degree of different sclerotins in CT manifestations of the patients in the study group ($r=0.952$, $P<0.001$; Fig. 2).

Correlation analysis between the injury degree of different sclerotins in CT manifestations of the patients in the study group and MMP-9. The injury degree of different sclerotins in CT manifestations of the patients in the study group was positively correlated with the expression levels of MMP-9 ($r=0.927$, $P<0.001$), as shown in Fig. 3.

Correlation analysis between the injury degree of different sclerotins in CT manifestations of the patients in the study

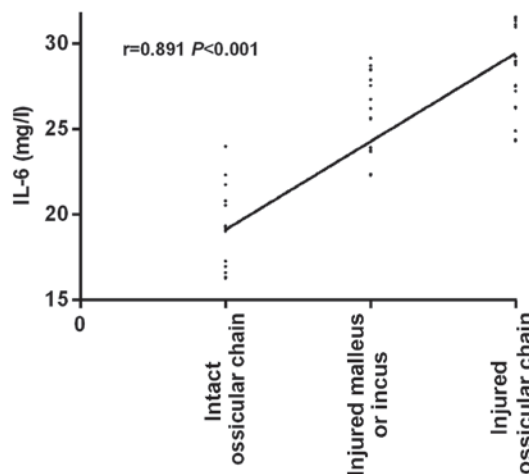


Figure 4. Correlation analysis of the injury degree of different sclerotins in CT manifestations of the patients in the study group and IL-6. There was an obvious positive correlation between the injury degree of different sclerotins in CT manifestations and IL-6 ($r=0.891$, $P<0.001$). IL-6, interleukin-6.

group and IL-6. An obvious positive correlation was observed between the injury degree of different sclerotins in CT

manifestations of the patients in the study group and IL-6 ($r=0.891$, $P<0.001$), as shown in Fig. 4.

Discussion

Cholesteatomatous otitis media is a type of cholesteatoma disease, whose morbidity accounts for 0.5-1.8% of the morbidity of all brain tumors (14). In most patients, it occurs after adulthood. The peak age of patients who suffer from this disease ranges from 40 to 45 years old, and patients aging from 25 to 50 years old correspond to the 72% of patients with this disease (15,16). A large number of researches have reported that if cholesteatomatous otitis media is not treated on time, the cholesteatoma will continue to increase, compress sclerotins and be absorbed, and the auditory ossicle will be injured. If bacteria enter into cranium, serious intracranial complications will occur, which may even lead to the patients death (17-19). There are no obvious specific symptoms in the early stage of cholesteatomatous otitis media, and its symptoms are easily confused with the clinical symptoms of patients with simple otitis media. Also, the primary site of cholesteatomatous otitis media is often concealed and extensive, which brings some difficulties to clinical diagnosis (20).

This study analyzed the clinical data of 176 patients with cholesteatomatous otitis media and 181 patients with simple otitis media. The expression levels of MMP-2, MMP-9 and IL-6 in the patients of the two groups were analyzed and compared, and their correlation with the injury degree of different sclerotins in CT manifestations was investigated. Firstly, it was found that the expression levels of MMP-2 and MMP-9 in the serum of patients with cholesteatomatous otitis media were higher than those in the patients with simple otitis media. Also, the levels of MMP-2 and MMP-9 in the serum of the patients whose ossicular chain was injured were significantly higher than those in the serum of the patients whose malleus or incus was injured and significantly higher than those in the serum of the patients with intact ossicular chain; and MMP-2 and MMP-9 levels in the serum of the patients whose malleus or incus was injured were significantly higher than those in the serum of the patients with intact ossicular chain. Moreover, the injury degree of different sclerotins was found to be significantly and positively correlated with MMP-2 and MMP-9 and the differences were statistically significant. MMP-2 and MMP-9 are the main proteases involved in the degradation of extracellular matrix and basement membrane *in vitro* and *in vivo*, they facilitate the release of angiogenic factors in the body, resulting in the proliferation of cholesteatoma epithelial cells and the injury of sclerotins (21,22). As the injury degree of sclerotins increases, the expression levels of MMP-2 and MMP-9 also increase, so MMP-2 and MMP-9 are closely related to the occurrence and development of cholesteatoma (23). According to the study report of Banerjee *et al* (24), the expression levels of MMP-2 and MMP-9 in patients with extensive cholesteatoma are significantly higher than those in patients with localized cholesteatoma, in consistency with the above results.

In the present study, the expression levels of IL-6 in the serum of patients with cholesteatomatous otitis media were found to be higher than those of patients with simple otitis media. Also, IL-6 levels in the serum of patients whose ossicular chain was injured were significantly higher than those in the serum of

patients whose malleus or incus was injured and those in the serum of patients with intact ossicular chain. The levels of IL-6 in the serum of patients whose malleus or incus was injured were also significantly higher than those in the serum of patients with intact ossicular chain. The injury degree of different sclerotins was significantly and positively correlated with IL-6 and the differences were statistically significant. As known, tissue is stimulated after patients get the disease, releasing a large number of inflammatory factors in the reaction mechanism of the patients' body. Macrophages, B and T lymphocytes can further induce the cascade reaction of cytokines and induce the production of other cytokines and chemokines, as well as stimulate the release of IL-6 and cause a series of inflammatory chain reactions (25,26). According to the reports of Liu *et al* (27), IL-6 plays a key role in the pathogenesis of cholesteatoma, which further supports the results of our experiment.

In this study, due to the limited medical resources in Changxing People's Hospital, the number of the selected subjects was small. A further limitation is the differences in the response of patients with different ages after anesthesia and surgery. Thus, longer-term follow-up surveys for the subjects in this study, will be conducted to confirm the findings of the present study.

In summary, MMP-2, MMP-9 and IL-6 are highly expressed in the serum of patients with cholesteatomatous otitis media, and are significantly and positively correlated with the severity thereof. This is of great significance for the prevention and treatment of cholesteatomatous otitis media, and may be beneficial for clinic.

Acknowledgements

Not applicable.

Funding

No funding was received.

Availability of data and materials

The datasets used and/or analyzed during the present study are available from the corresponding author on reasonable request.

Authors' contributions

YW and XT performed ELISA. WS and YL recorded and analyzed the CT examination results. YW wrote the manuscript. All authors read and approved the final manuscript.

Ethics approval and consent to participate

The study was approved by the Ethics Committee of Changxing People's Hospital (Huzhou, China). Patients who participated in this research had complete clinical data. Signed written informed consents were obtained from the patients and/or guardians.

Patient consent for publication

Not applicable.

Competing interests

The authors declare that they have no competing interests.

References

- Abramson M and Huang CC: Localization of collagenase in human middle ear cholesteatoma. *Laryngoscope* 87: 771-791, 1977.
- Yung M, Tono T, Olszewska E, Yamamoto Y, Sudhoff H, Sakagami M, Mulder J, Kojima H, Incesulu A, Trabalzini F, *et al*: EAONO/JOS joint consensus statements on the definitions, classification and staging of middle ear cholesteatoma. *J Int Adv Otol* 13: 1-8, 2017.
- Morita Y, Yamamoto Y, Oshima S, Takahashi K and Takahashi S: Pediatric middle ear cholesteatoma: The comparative study of congenital cholesteatoma and acquired cholesteatoma. *Eur Arch Otorhinolaryngol* 273: 1155-1160, 2016.
- Xie S, Wang X, Ren J and Liu W: The role of bone resorption in the etiopathogenesis of acquired middle ear cholesteatoma. *Eur Arch Otorhinolaryngol* 274: 2071-2078, 2017.
- Glikson E, Yousovich R, Mansour J, Wolf M, Migirov L and Shapira Y: Transcanal endoscopic ear surgery for middle ear cholesteatoma. *Otol Neurotol* 38: e41-e45, 2017.
- Locketz GD, Li PM, Fischbein NJ, Holdsworth SJ and Blevins NH: Fusion of computed tomography and PROPELLER diffusion-weighted magnetic resonance imaging for the detection and localization of middle ear cholesteatoma. *JAMA Otolaryngol Head Neck Surg* 142: 947-953, 2016.
- Lingam RK and Bassett P: A meta-analysis on the diagnostic performance of non-echoplanar diffusion-weighted imaging in detecting middle ear cholesteatoma: 10 years on. *Otol Neurotol* 38: 521-528, 2017.
- Rogha M, Hashemi SM, Mokhtarinejad F, Eshaghian A and Dadgostar A: Comparison of preoperative temporal bone CT with intraoperative findings in patients with cholesteatoma. *Iran J Otorhinolaryngol* 26: 7-12, 2014.
- Robert S, Gicquel T, Victoni T, Valença S, Barreto E, Bailly-Maître B, Boichot E and Lagente V: Involvement of matrix metalloproteinases (MMPs) and inflammasome pathway in molecular mechanisms of fibrosis. *Biosci Rep* 36: 36, 2016.
- Kim M, Park SC, Baek I and Chun J: Large-scale evaluation of experimentally determined DNA G+C contents with whole genome sequences of prokaryotes. *Syst Appl Microbiol* 38: 79-83, 2015.
- Schmidt-Arras D and Rose-John S: IL-6 pathway in the liver: From physiopathology to therapy. *J Hepatol* 64: 1403-1415, 2016.
- Rysz J, Banach M, Stolarek RA, Pasnik J, Cialkowska-Rysz A, Koktysz R, Piechota M and Baj Z: Serum matrix metalloproteinases MMP-2 and MMP-9 and metalloproteinase tissue inhibitors TIMP-1 and TIMP-2 in diabetic nephropathy. *J Nephrol* 20: 444-452, 2007.
- Trinidade A, Page JC and Dornhoffer JL: Therapeutic mastoidectomy in the management of noncholesteatomatous chronic otitis media: Literature review and cost analysis. *Otolaryngol Head Neck Surg* 155: 914-922, 2016.
- Tono T, Sakagami M, Kojima H, Yamamoto Y, Matsuda K, Komori M, Hato N, Morita Y and Hashimoto S: Staging and classification criteria for middle ear cholesteatoma proposed by the Japan Otological Society. *Auris Nasus Larynx* 44: 135-140, 2017.
- Matsuda K, Tono T, Kojima H, Yamamoto Y, Sakagami M, Mishihiro Y, Hinohira Y and Okuno T: Practicality analysis of the staging system proposed by the Japan Otological Society for acquired middle ear cholesteatoma: A multicenter study of 446 surgical cases in Japan. *Auris Nasus Larynx* 45: 45-50, 2018.
- Rutkowska J, Özgürin N and Olszewska E: Cholesteatoma definition and classification: A literature review. *J Int Adv Otol* 13: 266-271, 2017.
- Suzuki H, Ikezaki S, Imazato K, Koizumi H, Ohbuchi T, Hohchi N and Hashida K: Partial mastoid obliteration combined with soft-wall reconstruction for middle ear cholesteatoma. *Ann Otol Rhinol Laryngol* 123: 571-575, 2014.
- Blanco P, González F, Holguín J and Guerra C: Surgical management of middle ear cholesteatoma and reconstruction at the same time. *Colomb Med (Cali)* 45: 127-131, 2014.
- Zhu Z, Hong Y, Wang Y, He G and Ye S: The significance of keratinocyte in hyperproliferation of middle ear cholesteatoma. *Lin Chung Er Bi Yan Hou Tou Jing Wai Ke Za Zhi* 30: 139-143, 2016 (In Chinese).
- Akkari M, Gabrillargues J, Saroul N, Pereira B, Russier M, Mom T and Gilain L: Contribution of magnetic resonance imaging to the diagnosis of middle ear cholesteatoma: Analysis of a series of 97 cases. *Eur Ann Otorhinolaryngol Head Neck Dis* 131: 153-158, 2014.
- Suchozebrska-Jesionek D, Szymański M, Kurzepa J, Gołabek W and Stryjecka-Zimmer M: Gelatinolytic activity of matrix metalloproteinases 2 and 9 in middle ear cholesteatoma. *J Otolaryngol Head Neck Surg* 37: 628-632, 2008.
- Schmidt M, Grünsfelder P and Hoppe F: Up-regulation of matrix metalloproteinase-9 in middle ear cholesteatoma - correlations with growth factor expression in vivo? *Eur Arch Otorhinolaryngol* 258: 472-476, 2001.
- Zhu W, Xie Y and Wang P: Expression of matrix metalloproteinase-2,9 in cholesteatoma and middle ear cancer. *Zhonghua Er Bi Yan Hou Ke Za Zhi* 36: 119-122, 2001 (In Chinese).
- Banerjee AR, James R and Narula AA: Matrix metalloproteinase-2 and matrix metalloproteinase-9 in cholesteatoma and deep meatal skin. *Clin Otolaryngol Allied Sci* 23: 345-347, 1998.
- Kuczkowski J, Sakowicz-Burkiewicz M, Izycka-Świeszewska E, Mikaszewski B and Pawełczyk T: Expression of tumor necrosis factor- α , interleukin-1 α , interleukin-6 and interleukin-10 in chronic otitis media with bone osteolysis. *ORL J Otorhinolaryngol Relat Spec* 73: 93-99, 2011.
- Kumari N, Dwarakanath BS, Das A and Bhatt AN: Role of interleukin-6 in cancer progression and therapeutic resistance. *Tumour Biol* 37: 11553-11572, 2016.
- Liu W, Xie S, Chen X, Rao X, Ren H, Hu B, Yin T, Xiang Y and Ren J: Activation of the IL-6/JAK/STAT3 signaling pathway in human middle ear cholesteatoma epithelium. *Int J Clin Exp Pathol* 7: 709-715, 2014.



This work is licensed under a Creative Commons Attribution-NonCommercial-NoDerivatives 4.0 International (CC BY-NC-ND 4.0) License.