

Long-term results after primary intraocular lens implantation in children operated less than 2 years of age for congenital cataract

Jaspreet Sukhija, Jagat Ram, Nishant Gupta, Ashish Sawhney, Savleen Kaur

Purpose: To study the long-term outcome of cataract surgery with primary intraocular lens (IOL) in children <2 years. **Materials and Methods:** Retrospective analysis of bilateral cases that were operated before 2 years age for congenital cataract. All underwent primary posterior capsulotomy with anterior vitrectomy and primary IOL implantation. Only those with a follow-up of at least 8 years were evaluated. **Results:** Twenty-six eyes of 13 children with bilateral cataract met the inclusion criteria. Average age at surgery was 14.15 months with a mean follow-up of 102 months. Average preoperative axial length (AL) was 19.93 mm. There was a refractive shift from a mean spherical equivalent of 1.64 D at 2 weeks after surgery to -1.42 D measured at last follow-up. Twenty-four eyes out of 26 (92%) achieved final visual acuity (VA) of 6/18 or more at last follow-up with 19/26 (73%) having acuity of 6/12 or greater. Raised intraocular pressure was documented in one eye only. Average AL recorded at last follow-up was 22.21 mm. **Conclusion:** Primary IOL implantation in children <2 years is a safe surgical procedure with excellent long-term results. The myopic shift is well-controlled and final VA achieved is reasonably good.

Key words: Children, congenital cataract, hydrophobic acrylic intraocular lens, intraocular lens implantation, myopic shift, polymethyl methacrylate

Primary intraocular lens (IOL) implantation in pediatric cataract has been the choice of surgical procedure since quite some time now.^[1-4] However, the age at which IOL needs to be implanted is still debatable when it comes to infants and toddlers. Earlier, there was a trend to leave them aphakic and rehabilitate with contact lens. Lately, there has been a steady increase in the rate of primary IOL implantation in children with congenital cataract who are <2 years. However, caution is advised in children <6 months age as the incidence of adverse events is high.^[5] Risks associated with primary IOL implantation like an adult size IOL being implanted into small eye, postoperative inflammation and glaucoma do preclude one to implant an IOL in an infant's eye. Various studies have addressed these factors, but there is limited evidence on the long-term outcome in children who underwent primary IOL implantation before 2 years age.^[6-9] We herein report our findings in such cases.

Materials and Methods

The records of all children <2 years who were operated between 2000 and 2002 were analyzed. Thirteen children (26 eyes) who had a minimum follow-up of 8 years were included. The rest (12 eyes of six children) had very short follow-up or were lost to follow-up (3 children) or had other structural anomalies like microphthalmia, persistent hyperplastic primary vitreous, coloboma or history of trauma. All eyes underwent primary posterior capsulotomy of approximately 3.5–4 mm in size with anterior vitrectomy and primary IOL implantation. The size of the anterior capsulorhexis was about 5 mm. IOL implanted

was either foldable hydrophobic acrylic (Sensar Optiedge, Abbott Medical Optics, Santa Ana, California and Alcon MA60AC, Fortworth Texas, USA) or single-piece square-edge polymethyl methacrylate (Aurolab SQ3602, Aravind, Madurai, India.). Axial length (AL) was calculated using A scan. IOL power was approximately based on Dahans criteria^[6] and adjusted thereafter for a predictive postoperative retinoscopy of no more than +4 D in infants and +3 in 1–2 years age group. Only eyes with AL of ≥17 mm were considered for IOL implantation. Retinoscopy was first done after surgery at an interval of 2 weeks when no inflammation was documented. Best-corrected visual acuity (VA) was recorded at last follow-up. Intraocular pressure (IOP) was measured with Goldmann appplanation tonometer. AL was recorded at 8 years follow-up.

Results

Twenty-six eyes of thirteen children out of 38 eyes of 19 children who had undergone bilateral cataract surgery during that time met the inclusion criteria [Table 1]. All the cases underwent bilateral sequential cataract surgery with IOL implantation. Follow-up ranged from 96 months to 108 months. Average age at surgery was 14.15 months (range 3–23 months). There were two children <6 months age.

Refractive error

Postoperative retinoscopy ranged from +8 D to -2.75 D with average being 1.64 D. Refractive error at last follow-up ranged from +6.5 D to -11 D with average being -1.42 D. The mean myopic shift in refractive error was -3.06. The difference in refractive error (between immediate postoperative error and that at last follow-up) was highly significant ($P < 0.001$). Change in refractive error in the follow-up period is shown in Fig. 1.

Visual acuity

Final best-corrected VA was 6/18 or more in 24/26 (92%) eyes. About 73% achieved 6/12 or better. We compared the visual

Access this article online

Website:

www.ijo.in

DOI:

10.4103/0301-4738.149131

Quick Response Code:



Advanced Eye Centre, Postgraduate Institute of Medical Education and Research, Chandigarh, India

Correspondence to: Dr. Jagat Ram, Advanced Eye Centre, Postgraduate Institute of Medical Education and Research, Chandigarh, India. E-mail: drjagatram@gmail.com

Manuscript received: 13.08.13; **Revision accepted:** 06.12.14

Table 1: Profile of patients with long-term follow-up

Gender	Eye	Age at surgery (months)	AL (mm)	PO Ret.	Final Refr.	Final VA	IOP (mmHg)	Final AL (mm)
M	R	3	17.94	4	3	6/9	14	19.4
	L	5	17.86	4	3.25	6/12	17	18.82
M	R	5	18.2	7	4	6/12	16	20.25
	L	6	18.4	8	6.5	6/9	12	19.35
M	R	21	22.45	0.75	-1.5	6/9	17	23.19
	L	22	22.55	0	0	6/9	19	23
F	R	22	21.9	4.5	3	6/9	13	20.04
	L	23	22	2	0.75	6/9	15	19.96
M	R	23	20.3	-2.5	-3.25	6/12	12	23.95
	L	16	19.04	3	-5	6/9	17	23.93
M	R	12	19.6	-1	-5	6/12	11	22.39
	L	12	19.8	2	-3	6/12	13	21.86
M	R	16	20.7	0	0.25	6/12	12	22.15
	L	17	20	2	-3	6/12	12	22.22
F	R	15	22.2	-2.75	-6.75	6/18	14	24.92
	L	16	22.31	0	-3.5	6/12	12	23.63
M	R	17	20.6	1	0.25	6/12	17	22.4
	L	18	20.7	0.5	0	6/12	17	22.6
M	R	13	20.95	1	-2.25	6/18	18	22.4
	L	15	20.72	0	-3.75	6/18	32	22.89
F	R	12	19.5	3.5	3.5	6/18	17	21.23
	L	13	19	5	1.75	6/12	16	21.66
M	R	12	18	0.5	-4	6/18	16	22
	L	15	17	0.25	-2.25	6/12	20	22.4
M	R	13	18	-0.75	-9	6/36	17	24.45
	L	16	18.5	-1.5	-11	6/36	17	25.46

AL: Axial length (in mm), PO: Postoperative, Ret.: Retinoscopy, Refr.: Refraction, VA: Visual acuity, IOP: Intraocular pressure

outcome in first and subsequently operated eye in all the children. There was no statistically significant difference in the final VA in the two eyes ($P = 0.916$).

Axial length

Average preoperative AL was 19.93 ± 1.62 mm (range 17.9–22.5 mm). The average AL at last follow-up was 22.21 ± 1.51 mm (range 18.8–25.4 mm). The change in AL between the preoperative AL and that at last follow-up was highly significant ($P < 0.001$) [Figs. 2 and 3].

Complications

Besides amblyopia that was managed by the appropriate occlusion where required, only one eye had raised IOP of 32 mmHg at the age of 4 years. IOP was controlled with topical dorzolamide and timolol. Average IOP documented was 15.8 mmHg at last follow-up. Posterior capsule opacification was seen in two eyes for which surgical capsulotomy was performed.

Discussion

Refined techniques and new generation IOL's for pediatric cataract surgery have shifted the consensus toward implanting an IOL at an early age with decreased risk of complications.

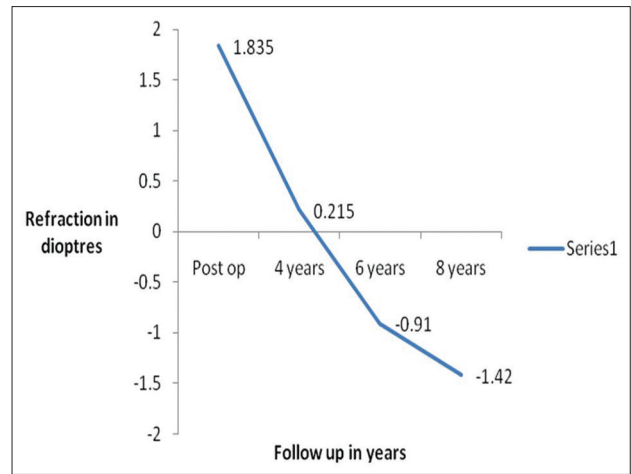


Figure 1: Change in refractive error over the follow-up period of 8 years

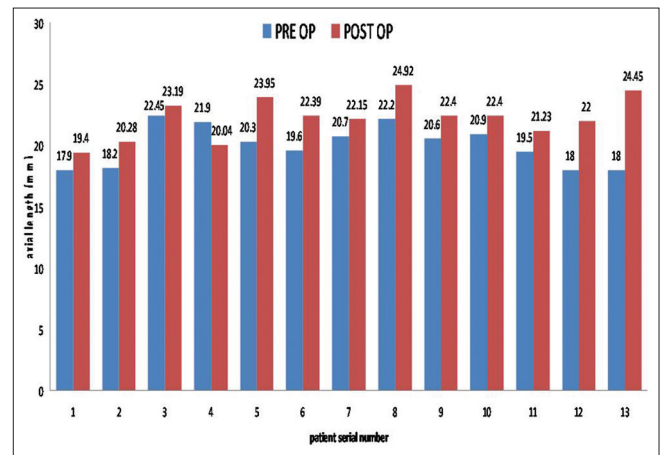


Figure 2: Axial length (AL) of right eye showing preoperative and postoperative final AL of each patient

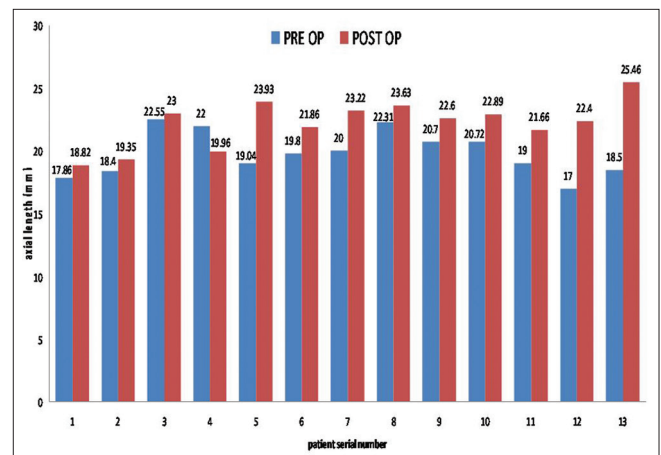


Figure 3: Axial length (AL) of left eye showing preoperative and postoperative final AL of each patient

Major problem in pediatric cataract patients is noncompliance with contact lenses resulting in amblyopia. There however remains a grey zone which makes primary IOL implantation in infants questionable. The outcome of primary IOL implantation

in very young children is unclear because of the paucity of long-range studies. Gouws *et al.* showed that 50% achieved 6/18 or better VA when both eyes were operated.^[10] In a series by Chak *et al.* median VA recorded at 7 years follow-up was 6/18.^[11] Gelbart *et al.* showed that 60% infants achieved VA of 6/18 with best results in those operated before 8 weeks age.^[12] Poor results in previous studies have been attributed to late presentation, improper surgical techniques, inadequate management of amblyopia coupled with aphakia. Thoumziet *et al.* concluded that primary IOL implantation provides significantly better VA than aphakic contact lens corrected eyes after pediatric cataract surgery in infants.^[13] Our case series shows that reasonably good visual outcome is possible in ~70% of the children.

Limited data are available on long-term refractive status in very young children undergoing cataract surgery with primary IOL implantation. Plager *et al.* showed a mean myopic shift of 4.6 D in children operated at age 2 or 3 years over a period of 6 years with a mean rate of shift decreasing as the age increased.^[14] They also emphasized the fact that future myopic shift is unpredictable in young children. Similar observations were made by Crouch *et al.* who showed a myopic shift of 5.96 in children <2 years age with a mean follow-up of 5.4 years.^[15] This study served as a guide to accurate IOL power calculation based on the refractive growth in children. Dahan and Drusedau reported a myopic shift of 6.9 D in infants over a period of 7 years after primary IOL implantation.^[6] Ram *et al.* observed a decrease in initial myopic shift of from 6.60 ± 2.64 D at 1 week postoperatively to 3.03 ± 2.53 D at 1 year following primary IOL implantation in infants.^[1] In a recent review by the same author, the mean refractive error at 2 weeks, 1 year and 3 years after cataract surgery in the age group ≤ 2 years was $+3.3863.07$ D (median $+ 3.75$ D), $+1.72$ D (median $+1$ D) and -0.51 D (median -0.5 D).^[16] We observed a mean refractive shift of 3.06 D over a period of 8 years. This may be related to the power of IOL selected aiming for a less hypermetropic postoperative retinoscopy or a reduction in AL growth in pseudophakic eyes. This finding is supported by Griener *et al.* who showed a decrease in axial growth in children with IOL implantation that subsequently reduced the magnitude of myopic shift.^[17] Inatomi *et al.* showed no significant difference in the AL between two eyes in older children operated for unilateral cataract.^[18] Nischal *et al.* have enumerated multiple reasons for such a large variability seen in myopic shift and AL and have summarized it as "emmetropization" may be abnormal in these abnormal cataractous eyes.^[19]

The incidence of glaucoma was negligible in our study. This may be related to the improved surgical techniques and endocapsular implantation of IOL. Crouch *et al.* did not observe any case of pseudophakic glaucoma in their prospective series.^[15] Ram *et al.* in their study in infants did not report any case of glaucoma at 1 year follow-up.^[1] However in their recent study which is the largest single center study to date, the incidence of glaucoma was just 0.5%.^[16]

Our study shows a favorable long-term outcome of primary IOL implantation in children who were operated before 2 years age. The importance lies in choosing an IOL power to aim for 3–4 D hypermetropia in this age group, performing primary posterior capsular capsulorhexis with endocapsular IOL implantation coupled with the amblyopia management. This series also highlights the fact that the change of AL in pseudophakic eyes

is limited which may be detrimental in decreasing the surprises observed in final refraction over such a long follow-up. However, our study is limited by the fact that there could be selection bias, a retrospective nature and no data on children who were lost to follow-up. There is scope for prospective studies with more cases to answer the shortcomings in this study.

References

- Ram J, Brar GS, Kaushik S, Sukhija J, Bandyopadhyay S, Gupta A. Primary intraocular lens implantation in the first two years of life: Safety profile and visual results. *Indian J Ophthalmol* 2007;55:185-9.
- Solebo AL, Russell-Eggitt I, Nischal KK, Moore AT, Cumberland P, Rahi JS, *et al.* Cataract surgery and primary intraocular lens implantation in children < or = 2 years old in the UK and Ireland: Finding of national surveys. *Br J Ophthalmol* 2009;93:1495-8.
- Fan DS, Rao SK, Yu CB, Wong CY, Lam DS. Changes in refraction and ocular dimensions after cataract surgery and primary intraocular lens implantation in infants. *J Cataract Refract Surg* 2006;32:1104-8.
- O'Keefe M, Mulvihill A, Yeoh PL. Visual outcome and complications of bilateral intraocular lens implantation in children. *J Cataract Refract Surg* 2000;26:1758-64.
- Infant Aphakia Treatment Study Group, Lambert SR, Buckley EG, Drews-Botsch C, DuBois L, Hartmann EE, *et al.* A randomized clinical trial comparing contact lens with intraocular lens correction of monocular aphakia during infancy: Grating acuity and adverse events at age 1 year. *Arch Ophthalmol* 2010;128:810-8.
- Dahan E, Drusedau MU. Choice of lens and dioptric power in pediatric pseudophakia. *J Cataract Refract Surg* 1997;23 Suppl 1:618-23.
- Flitcroft DI, Knight-Nanan D, Bowell R, Lanigan B, O'Keefe M. Intraocular lenses in children: Changes in axial length, corneal curvature, and refraction. *Br J Ophthalmol* 1999;83:265-9.
- Ashworth JL, Maino AP, Biswas S, Lloyd IC. Refractive outcomes after primary intraocular lens implantation in infants. *Br J Ophthalmol* 2007;91:596-9.
- Enyedi LB, Peterseim MW, Freedman SF, Buckley EG. Refractive changes after pediatric intraocular lens implantation. *Am J Ophthalmol* 1998;126:772-81.
- Gouws P, Hussin HM, Markham RH. Long term results of primary posterior chamber intraocular lens implantation for congenital cataract in the first year of life. *Br J Ophthalmol* 2006;90:975-8.
- Chak M, Wade A, Rahi JS, British Congenital Cataract Interest Group. Long-term visual acuity and its predictors after surgery for congenital cataract: Findings of the British congenital cataract study. *Invest Ophthalmol Vis Sci* 2006;47:4262-9.
- Gelbart SS, Hoyt CS, Jastrebski G, Marg E. Long-term visual results in bilateral congenital cataracts. *Am J Ophthalmol* 1982;93:615-21.
- Thoumziet F, Mauris-Tyson S, Colin J, Mortemousque B. Congenital cataract removed early: Long-term visual acuity outcome and refractive changes. *J Fr Ophtalmol* 2010;33:373-9.
- Plager DA, Kipfer H, Sprunger DT, Sondhi N, Neely DE. Refractive change in pediatric pseudophakia: 6-year follow-up. *J Cataract Refract Surg* 2002;28:810-5.
- Crouch ER, Crouch ER Jr, Pressman SH. Prospective analysis of pediatric pseudophakia: Myopic shift and postoperative outcomes. *J AAPOS* 2002;6:277-82.
- Ram J, Gupta N, Sukhija JS, Chaudhary M, Verma N, Kumar S, *et al.* Outcome of cataract surgery with primary intraocular lens implantation in children. *Br J Ophthalmol* 2011;95:1086-90.
- Griener ED, Dahan E, Lambert SR. Effect of age at time of cataract surgery on subsequent axial length growth in infant eyes. *J Cataract Refract Surg* 1999;25:1209-13.

18. Inatomi M, Kora Y, Kinohira Y, Yaguchi S. Long-term follow-up of eye growth in pediatric patients after unilateral cataract surgery with intraocular lens implantation. *J AAPOS* 2004;8:50-5.
19. Nischal KK, Solebo L, Russell-Eggitt I. Paediatric IOL implantation and postoperative refractive state: What role do study methodology and surgical technique play? *Br J Ophthalmol* 2010;94:529-31.

Cite this article as: Sukhija J, Ram J, Gupta N, Sawhney A, Kaur S. Long-term results after primary intraocular lens implantation in children operated less than 2 years of age for congenital cataract. *Indian J Ophthalmol* 2014;62:1132-5.

Source of Support: Nil. **Conflict of Interest:** None declared.