

Lipomatous Infiltration in Tuberous Sclerosis Complex – A Case Series and Literature Review

Mohammed Ilyas, MD¹ , Julio Quezada, MD¹, and Erin K. Opfer, DO²

Abstract

Diffuse Lipomatosis is a dermatological lesion consisting of a poorly circumscribed, infiltrative overgrowth of mature adipose tissue that usually affects the trunk and the extremities. The lesions in the Tuberous Sclerosis Complex (TSC) are usually hamartomatous in nature, but lesions arising from adipocytes are rare. There are only three previous reports of association of TSC with diffuse lipomatosis. Herein we present a case series of diffuse lipomatosis in three subjects with TSC and proceed to review the literature for any other reported cases. On the basis of the three index cases and identification of three more cases in the literature, we believe that there is an association of diffuse lipomatosis with TSC that has not been appreciated until now. We believe that this association in some selected cases will serve to improve diagnosis, surveillance, and management..

Keywords

diffuse lipomatosis, tuberous sclerosis, tuberous sclerosis complex, dermatological lesion, lipoma, tuberous sclerosis surveillance

Received May 30, 2021. Received revised August 16, 2021. Accepted for publication September 3, 2021.

Introduction

Tuberous sclerosis complex (TSC) is a multisystem genetic disorder with variable clinical manifestations.¹ Patients commonly present with benign tumors of the skin, brain, kidney, lung, and heart. Dermatological findings are divided into major and minor features per the 2012 consensus guidelines and update.^{1,2} The major features include hypomelanotic macules, angiofibromas, fibrous cephalic plaques, unguis fibromas, and shagreen patches. The minor criteria include “confetti” skin lesions, dental enamel pits, and intraoral fibromas. Nearly 100% of individuals affected by TSC have skin or dental findings easily detectable on physical examination.²

Benign tumors, including lipoma, are present in individuals with TSC, with renal angiomyolipoma being the most common. Angiomyolipomas have also been previously reported in the skin of individuals with and without TSC.³ Lipomas are rarely reported in TSC in other parts of the body, including the liver, myocardium and adrenal glands.² These are usually described as solitary well-circumscribed lesions that are readily amenable to surgical treatment with a tendency for recurrence after resection.

We describe three individuals with TSC who present with diffuse overgrowth of fatty tissue that resulted in lower limb and lower back deformities. The fatty tissue overgrowth is

best described as diffuse lipomatosis. This finding has previously been described in three other patients with TSC.⁴⁻⁶

Methods

We describe three cases of diffuse lipomatosis associated with TSC. A systematic literature review was then conducted via MEDLINE to identify cases of lipomas associated with TSC.

Results

Three subjects (14-year-old, 13-year-old, and 11-year-old) were found to have diffuse lipomatosis involving extremities and lower back. The first patient presented with disfiguring recurrent lipomatous lesions involving the right lower extremity, and the

¹Division of Pediatrics and Neurology, Children’s Mercy Hospital and Clinics, Kansas City, MO

²Division of Pediatrics and Radiology, Children’s Mercy Hospital and Clinics, Kansas City, MO

Corresponding Author:

Mohammed Ilyas. Clinical Associate Professor, Division of Pediatrics and Neurology, Children’s Mercy Hospital, 2401 Gillham Road, Kansas City, MO, 64108.

Email: milyas@cmh.edu.



second patient presented with painless lipomatosis lesions involving the left lower extremity, and the third patient presented with discomforting recurrent lower back lipomatous lesions. Three more case reports were identified in the existing literature.

Case Report

Patient 1

The first patient is an eleven-year-old girl diagnosed with tuberous sclerosis complex (TSC), focal structural epilepsy, and migraines. She presented to neurology after an unprovoked focal seizure involving her right arm. This prompted a brain MRI that revealed multiple cortical tubers and subependymal nodules. Her genetic workup was negative for a TSC1 and TSC2 mutation, and there was no family history of TSC or lipomatosis. Her epilepsy was well controlled with

oxcarbazepine, and her migraines were well controlled with daily magnesium supplementation. When she was ten years old, her parents noticed that her right thigh seemed to be larger than the left. This prompted an MRI of her lower extremities (Figure 1) which demonstrated an increase in subcutaneous fat that infiltrated the thigh musculature. She was evaluated by plastic surgery and underwent liposuction of the right thigh. Hematoxylin and eosin stains confirmed mature adipose tissue, suggestive of lipoma. No evidence of atypia or malignancy. One year after the liposuction was done, her right thigh was again noted to be enlarged. A repeat MRI of the lower extremities revealed a recurrence of the lipomatosis (Figure 1).

Patient 2

The second patient is a fourteen-year-old boy with a history of TSC, a long-standing history of focal epilepsy, and large

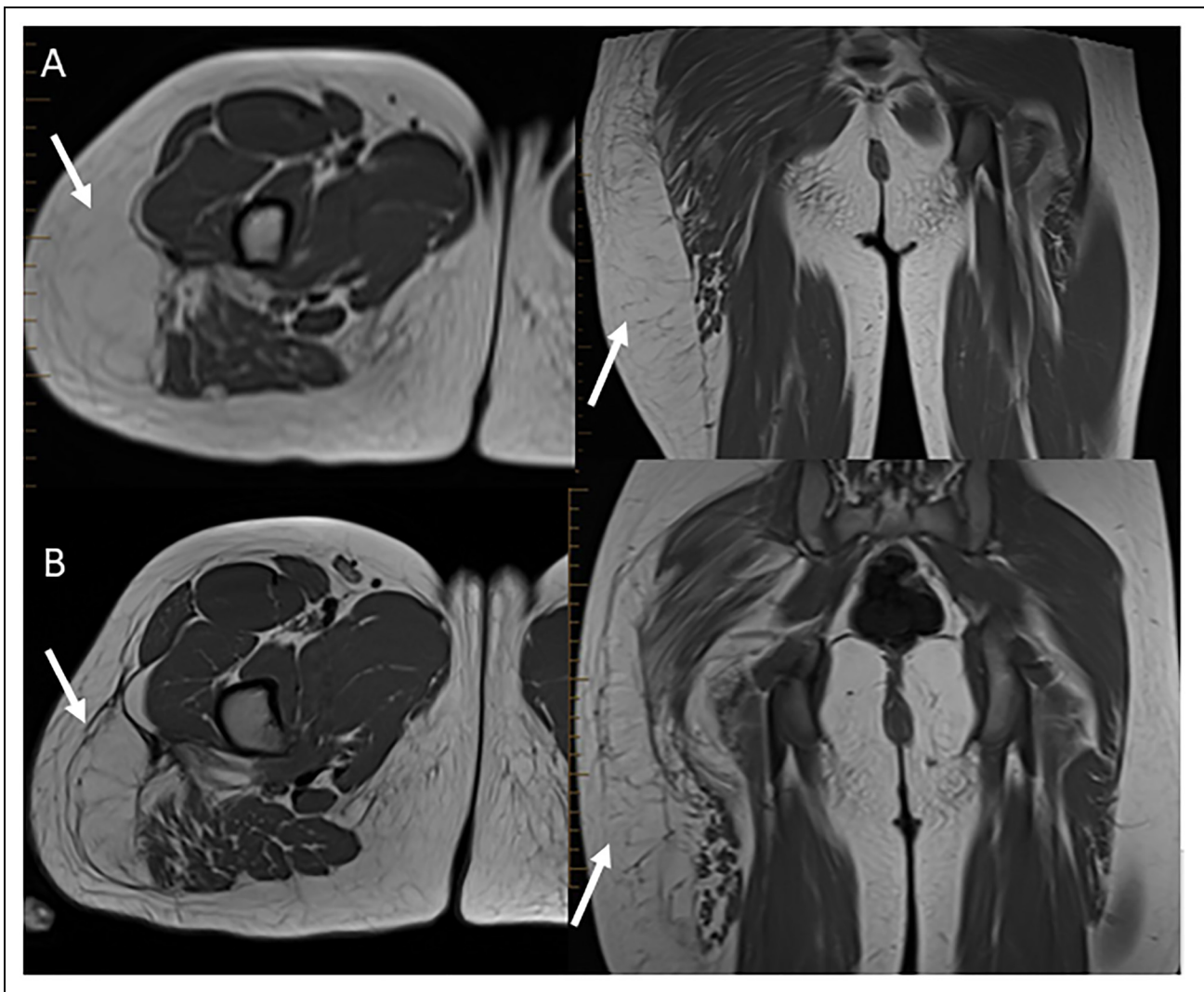


Figure 1. (Patient #1): MRI lower extremity before and after liposuction showing axial and coronal T1 images. Axial and coronal T1 images of the upper right thigh before (A) and after (B) liposuction shows persistent or recurrence of asymmetric prominence of the superficial fatty tissues within the lateral right thigh (short arrows). Similar fatty infiltration of the gluteus maximus and medius muscle (short arrows).

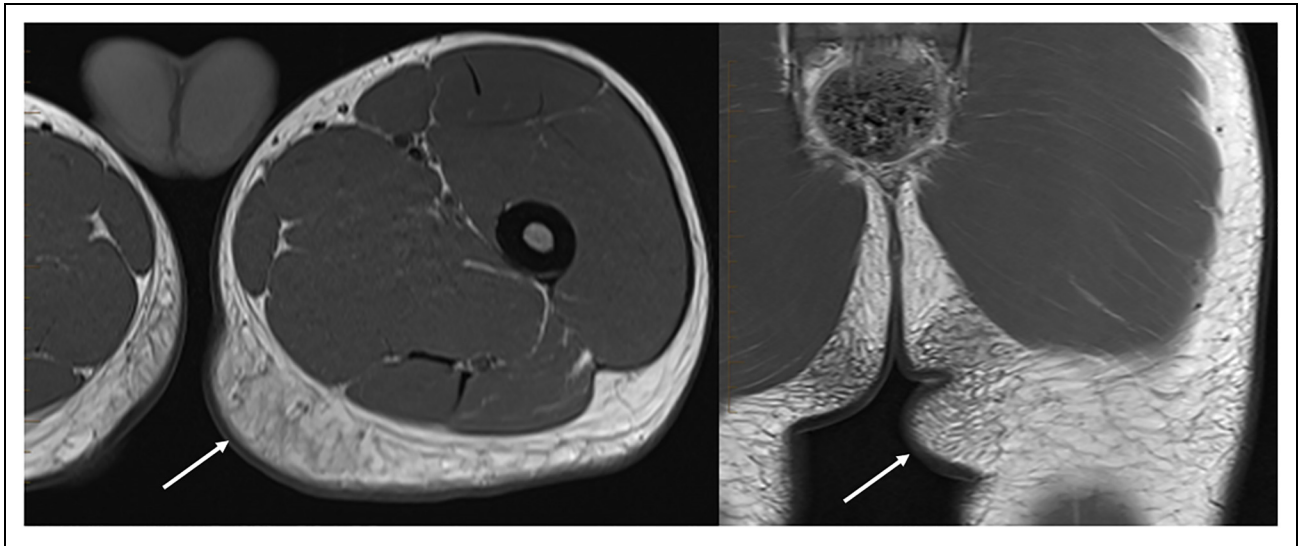


Figure 2. (Patient #2): MRI lower extremity showing axial and coronal T1 images. Axial and coronal T1 images of the left upper thigh/buttock region demonstrates asymmetric prominence of the superficial fatty tissues with reticulation in the posteromedial left buttock region (long arrows). No well-defined mass or lipoma.

sub-ependymal giant cell astrocytomas stable on Everolimus. His genetic workup revealed a pathogenic variant in *TSC2*. He was diagnosed with TSC at around nine months of age following a seizure, and his epilepsy remained well controlled on oxcarbazepine. When he was thirteen years old, the patient-reported a compressible soft tissue swelling in the left mesial thigh region, which was bothering him and causing mild deformity. He denied any pain and declined a surgical intervention.

Initially, an ultrasound of the left lower extremity was done, that showed a 7 cm compressible soft tissue fullness in the left mesial thigh with the same echogenicity as normal adjacent fat. Later an MRI of the Lower extremity was done that confirmed the diagnosis. It showed a smooth marginated asymmetric ovoid prominence of the superficial fat, grossly measuring 7.2 × 3.1 cm, representing an asymmetric fatty tissue proliferation or lipomatous proliferation (Figure 2).

Patient 3

The third patient is a thirteen-year-old boy with a history of TSC, focal structural epilepsy, ADHD, cortical tubers, cardiac rhabdomyomas, hypertension, and recurrent atypical lipoma on the lower back s/p surgical excision × 2. He was diagnosed with TSC at around two years of age following a seizure and met TS clinical criteria, with no further genetic testing was done. His epilepsy was well controlled on oxcarbazepine monotherapy.

At six years of age, he was noted to have soft tissue swelling on the lower back, slowly increasing in size over several months. He denied any pain, but the swelling was bothering him, especially when he sleeps. Ultrasound of the back and subsequent pathology s/p resection done at six and nine years of age showed a bland appearing mature adipose tissue with no evidence

of increased cellularity, necrosis, atypia, or increase in mitotic activity. MRI of the lumbar spine (pre-resection) showed a large 12.1 cm × 10.7 cm × 3.0 cm diameter predominately fatty soft tissue mass within the deep subcutaneous tissues along the posterior aspect of the lumbar spine and sacrum from the lower L2 to the S4 level. There were some atypical features with incomplete encapsulation (Figure 3). He underwent first surgical excision at age six with recurrence in a couple of years, for which another surgical resection was performed with no further recurrence since then.

Discussion

Diffuse lipomatosis is a clinical finding that has previously been reported in patients with TSC.⁴⁻⁶ There are only three case reports of diffuse lipomatosis in patients with TSC. The first case was described by Klein and Barr⁴ in 1986 and involved the right lower extremity in a TSC patient. The lesion infiltrated the muscle and recurred after wide excision. Later, Alcázar et al⁵ also reported an incidental diffuse lipomatosis involving the dorsal transthoracic region that presented with a spontaneous pneumothorax. In 2018, Mittal et al⁶ reported the case of an adult man with diffuse lipomatosis of the right lower extremity that caused significant deformity. Our case report describes three more individuals with TSC who present with a diffuse overgrowth of fatty tissue, best described as diffuse lipomatosis, that resulted in lower limb and lower back deformities. The case reported by Klein and Barr⁴ and Mittal et al⁶ had lower limb involvement, like our first two cases, whereas Alcázar et al⁵ reported dorsal transthoracic involvement, almost similar to our third case.

The first and third case we presented underwent surgical resection of lipomatous infiltration with recurrence of the

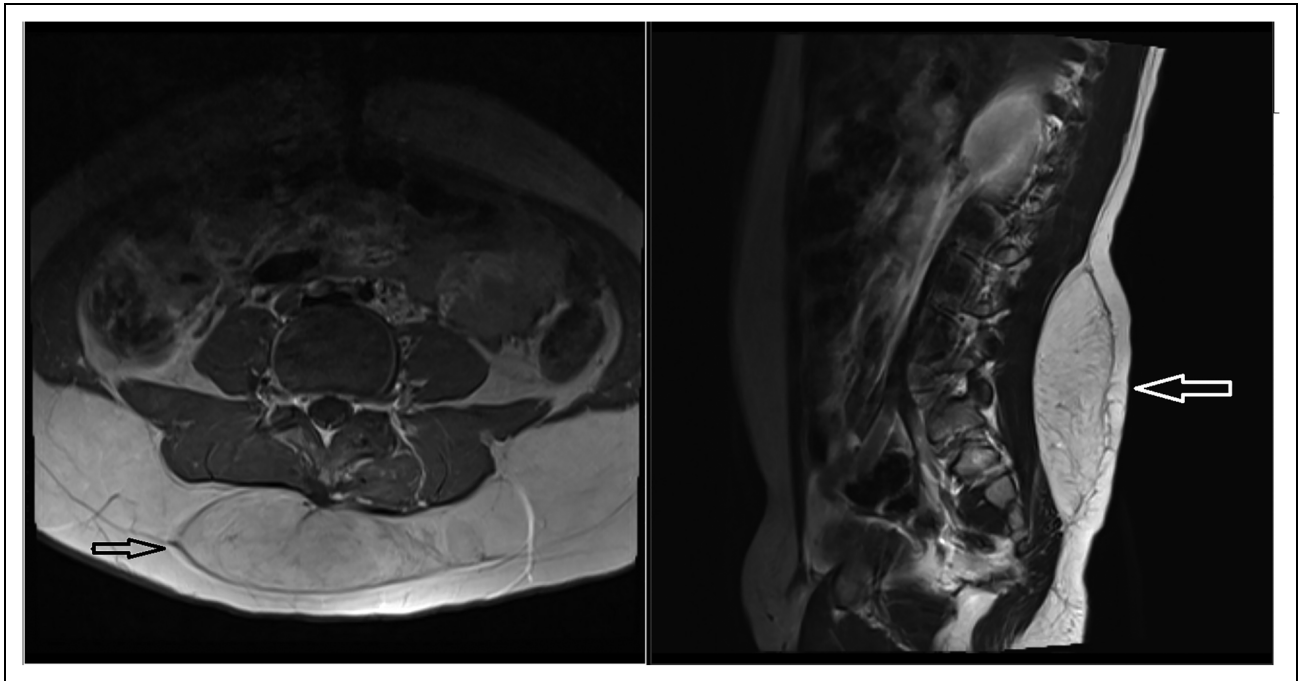


Figure 3. (Patient #3): MRI of the lumbar spine. Axial T1 and sagittal T1 images before liposuction shows large, partially encapsulated fatty soft tissue mass (arrows) with in the deep subcutaneous tissues along the posterior aspect of the lumbar spine and sacrum extending from Lower L2 to the S4 level.

lesions. Recurrence after excision was also reported by Klein and Barr⁴ The indications for the resection were cosmetic and interference with ambulation. Surgical removal via lipectomy or liposuction is the best therapeutic approach for these types of lesions. However, there is a high rate of postoperative local recurrence, especially after liposuction⁷ that should be carefully considered before proceeding with resection.

Diffuse lipomatosis, as reported here, is a rare condition consisting of diffuse, nonlocalized overgrowth of adipose tissue. Diffuse lipomatosis usually occurs in patients under two years of age but may also occur in adolescents and adults. It usually affects the trunk or a limb, but also the head and neck. These lesions can grow to be quite large and may cause compression of vital structures and impair function.⁸ The most frequently reported lipomatosis in children is congenital infiltrating lipomatosis of the face,⁹ in which the adipose proliferation is accompanied by a proliferation of fibrovascular tissue and nerves, unlike diffuse lipomatosis, which involve subcutaneous tissue and muscle but not nerve. Diffuse lipomatosis also needs to be differentiated from “genetic syndromes with the localized accumulation of subcutaneous fatty tissues,¹⁰ where lesions unlike the index cases have characteristic lipedema, symmetrical masses, nodular, and are painful.

Diffuse lipomatosis can be suggested by imaging due to its diffuse, infiltrative appearance, and lack of a defined capsule. Consistent with the nature of the lesions (mature fat cells), the signal changes of T1, T2, and fat-saturated sequences are similar to that of fat which helps in confirming the diagnosis whereas contrast is usually not necessary to establish the

diagnosis.¹¹ However, it can also mimic other fat containing lesions such as liposarcoma or infiltrating lipoma. Histologic sampling may be needed to confirm the diagnosis.

Discrete lipomas are reported in patients with TSC in other parts of the body, such as the liver, heart, and adrenal glands.² Tresoldi et al¹² reported the presence of myocardial fatty foci in TSC and suggested that this may represent an indicator of multiorgan involvement. While angiomyolipomas have previously been well reported in the skin of individuals with TSC,³ the association of hepatic lipomas is rarely observed in patients with tuberous sclerosis complex.^{12,13} While lipomas are usually solitary, well-circumscribed lesions readily amenable to surgical treatment, diffuse lipomatosis associated with TSC, similar to the index cases described herein, may represent a variable presentation and is a separate entity from discrete lipoma.

These isolated benign tumors (like diffuse lipomatosis) have rarely been described in patients with TSC. In addition to the three cases reported here, there are only three other cases reported in the literature of TSC patients with diffuse lipomatosis, which are summarized in Table 1. It is currently unclear if this is due to a lack of potential association or due to a lack of awareness and under reporting of diffuse lipomatosis in the TSC population. The protein products of *TSC1* and *TSC2* (tuberin and hamartin) regulate mTOR (mammalian target of Rapamycin) serine/threonine protein kinase activity^{14,15} which is responsible for the pathogenesis of multiple hamartomas, including lipomatous infiltration. Mutations in other genes like *PIK3CA* & *AKT* can also lead to abnormal expression of the *TSC1* and *TSC2* gene products.^{15,16} Mutations in these

Table 1. Summary of Relevant Clinical Studies Related with Diffuse Lipomatosis.

Clinical studies	No of patients	Age	Indication	Diagnostic criteria	Diagnostic tool	Site
Mittal et al. 2017	1	24 years	progressive diffuse swelling of the right lower limb	Met clinical criteria	Fine needle aspiration cytology MRI	Lower limb
Klein et al. 1986	1	15 years	Recurrent lipomatous tumor of the right lower limb	Met Clinical criteria	Biopsy & Excision x-ray	Lower limb
Alcázar et al. 1998	1	37 years	Diffuse lipomatosis with pneumothorax	Met Clinical criteria	Biopsy x-ray Abdominal CT	Dorsal transthoracic involvement
Ilyas et al. 2021	3	11 years 14 years 13 years	Patient #1 Recurrent diffuse lipomatosis of the right lower limb. Patient #2- Diffuse lipomatosis of the left lower limb Patient #3 Recurrent diffuse lipomatosis of the lower back	Met Clinical criteria Met Clinical criteria (TSC2) Met Clinical criteria	Fine needle aspiration cytology x-ray & MRI Ultrasound & MRI Ultrasound & MRI, Biopsy and Excision	Lower limb Lower limb Lower back

genes lead to the mTOR pathway activation, resulting in cell growth, proliferation, angiogenesis, and tumor formation.¹⁷ Activation of the mTOR pathway might also inhibit lipolysis and stimulate lipogenesis in adipocytes.¹⁶ As studied by Chakrabarti et al¹⁶ in his in-vitro adipocyte model, this phenomenon might explain lipomatous infiltration in the TSC.

TSC can be diagnosed by molecular testing and/or meeting the clinical criteria. TSC has striking phenotypic variabilities, and molecular testing of the *TSC1* and *TSC2* genes yields a positive result for 75%-90% of TSC-affected individuals. Clinical diagnostic criteria become important when sequencing fails to identify a disease-causing variant in *TSC1* or *TSC2*. Clinical criteria are also relevant in those where genetic testing is not available. Furthermore, a subset of the TSC population does not meet diagnostic criteria through clinical diagnosis and is labeled as possible TSC.² In these clinical situations, the addition or modification of the diagnostic criteria is of value. The diagnostic criteria for TSC are updated every 5-10 years as new data accumulate in the literature.¹⁸ While the association of diffuse lipomatosis with TSC highlighted in these cases is rare, it is nonetheless present in a minority of cases. The association of lipomatous infiltration with TSC is a clinical observation that merits further investigation, including genetic confirmation of the fatty tissue sampling. Awareness of this association may not only encourage researcher to further examine, but also bring to light previously unreported cases that will improve diagnosis, surveillance, and management.

Conclusions

Currently, lipomas in TSC occur in different organ systems and appear as a component of angioliipoma. Given the case reports described in this paper and several other previously reported cases in the literature, diffuse lipomatosis may be associated with TSC more often than previously thought. This possible

association needs further assessment and consideration. This clinical finding could facilitate the diagnosis of TSC in some challenging cases, particularly young individuals, allowing earlier implementation of surveillance.

Declaration of Conflicting Interests

The author(s) declared no potential conflicts of interest with respect to the research, authorship, and/or publication of this article.

Funding

The author(s) received no financial support for the research, authorship and/or publication of this article.

Ethical Approval

Not applicable, because this article does not contain any studies with human or animal subjects.

Informed Consent

Not applicable, because this article does not contain any studies with human or animal subjects.

ORCID iD

Mohammed Ilyas  <https://orcid.org/0000-0002-2750-5194>

Trial Registration

Not applicable, because this article does not contain any clinical trials.

References

1. Krueger DA, Northrup H, Krueger DA, et al. Tuberous sclerosis complex surveillance and management: recommendations of the 2012 international tuberous sclerosis complex consensus conference. *Pediatr Neurol.* 2013;49(4):255-265.
2. Northrup H, Krueger DA, Roberds S, et al. Tuberous sclerosis complex diagnostic criteria update: recommendations of the

- 2012 international tuberous sclerosis complex consensus conference. *Pediatr Neurol.* 2013;49(4):243-254.
3. Sánchez-Estella J, Bordel-Gómez MT, Zamora-Martínez T. Presentation of 2 new cases of cutaneous angiomyolipomas and literature review. *Actas Dermosifiliogr.* 2009;100(9):808-812.
 4. Klein JA, Barr RJ. Diffuse lipomatosis and tuberous sclerosis. *Arch Dermatol.* 1986;122(11):1298-1302.
 5. Alcázar JD, Ramos R, Verdugo J. Lipomatosis difusa dorsal transtorácica en un paciente con esclerosis tuberosa familiar [Dorsal transthoracic diffuse lipomatosis in a patient with familial tuberous sclerosis]. *Arch Bronconeumol.* 1998;34(9):468-469.
 6. Mittal A, Vinay K, De D, Sinha A. Tuberous sclerosis complex and diffuse lipomatosis: case report of a rare association. *Indian Dermatol Online J.* 2018;9(1):37-39.
 7. Brea-García B, Cameselle-Teijeiro J, Couto-González I, Suárez AT, González-Alvarez E. Madelung's disease: comorbidities, fatty mass distribution, and response to treatment of 22 patients. *Aesthetic Plast Surg.* 2013;37(2):409-416.
 8. Christopher DM, Fletcher JA, Pancras CW, Hogendoom FM. *WHO Classification of Tumours of Soft Tissue and Bone.* International Agency for Research on Cancer; 2013.
 9. Fraga MF, Mello D, Jorge D, Perin LF, Helene A. Congenital infiltrating lipomatosis. *J Plast Reconstr Aesthet Surg.* 2009;62(12):e561-e564.
 10. Precone V, Barati S, Paolacci S, et al. Genetic syndromes with localized subcutaneous fat tissue accumulation. *Acta Biomed.* 2019;90(Suppl 10):90.
 11. Gupta P, Potti TA, Wuertzer SD, Lenchik L, Pacholke DA. Spectrum of fat-containing soft-tissue masses at MR imaging: the common, the uncommon, the characteristic, and the sometimes confusing. *Radiographics.* 2016;36(3):753-766.
 12. Tresoldi S, Munari A, Di Leo G, et al. Myocardial fatty foci in adult patients with tuberous sclerosis complex: association with gene mutation and multiorgan involvement. *Radiology.* 2015;277(2):398-405.
 13. Schneider-Monteiro ED, Lucon AM, de Figueiredo AA, Junior AJR, Arap S. Bilateral giant renal angiomyolipoma associated with hepatic lipoma in a patient with tuberous sclerosis. *Rev Hosp Clin Fac Med Sao Paulo.* 2003;58(2):103-108.
 14. Hirasaki S, Koide N, Ogawa H, Shinji T, Tsuji T. Tuberous sclerosis associated with multiple hepatic lipomatous tumors and hemorrhagic renal angiomyolipoma. *Intern Med.* 1999;38(4):345-348.
 15. Nathan N, Keppler-Noreuil KM, Moss J, Darling T. Mosaic disorders of the PI3 K/PTEN/AKT/TSC/mTORC1 signaling pathway. *Dermatol Clin.* 2017;35(1):51-60.
 16. Chakrabarti P, English T, Shi J, Smas CM, Kandror KV. Mammalian target of rapamycin Complex 1 suppresses lipolysis. Stimulates lipogenesis, and promotes fat storage. *Diabetes.* 2010;59(4):775-781.
 17. Hill CR, Theos A. What's new in genetic skin diseases. *Dermatol Clin.* 2019;37(2):229-239.
 18. Roach ES. Are diagnostic criteria for tuberous sclerosis still relevant? *Pediatr Neurol.* 2013;49(4):223-224.