

Glycogen Storage Disease Type Ia: Adult Presentation With Microcytic Anemia and Liver Adenomas

Wouter Moest,¹ Wendy van der Deure,¹ Ted Koster,¹ Marcela Spee-Dropková,² Linda Swart-Busscher,³ Robbert J. de Haas,⁴ and Terry G.J. Derks⁵

Glycogen storage disease type Ia (GSD Ia; OMIM #232200) is an ultra-rare inherited metabolic disorder caused by deficient glucose-6-phosphatase (G6Pase; EC 3.1.3.9) activity, which hydrolyzes glucose-6-phosphate (G6P), to produce glucose in the endoplasmic reticulum lumen in the final common pathway of glycogenolysis and gluconeogenesis. Classically, symptoms and signs in the first year of life include severe fasting intolerance, failure to thrive, and hepatomegaly, biochemically characterized by nonketotic hypoglycemia, fasting hyperlactidemia, hyperuricaemia, and hyperlipidaemia (Fig. 1),⁽¹⁾ but few milder phenotypes are described.⁽²⁾ Dietary management is the cornerstone of treatment aiming at maintenance of euglycemia, prevention of secondary metabolic perturbations, and long-term complications including the liver (hepatocellular adenomas and carcinomas).⁽¹⁾

Case Report

A 25-year-old woman presented with acute abdominal pain in the right upper quadrant and fever at the emergency department of a local hospital in January 2017. Laboratory tests displayed hypoglycemia (glucose 2.5 mmol/L), hyperlactatemia (lactate 9.1 mmol/L), and hyperlipidemia (triglycerides 10.6 mmol/L,

cholesterol 6.1 mmol/L), without urinary ketones. She was treated with an intravenous bolus of 100 mL of glucose 10%, subsequent 125-mL/h maintenance infusion of sodium chloride 0.45% and glucose 5.0%, and antibiotics under the working diagnosis of a sepsis with an abdominal focus. Symptoms recovered quickly, but glucose concentrations remained relatively low.

At that time, medical history revealed that she had been referred by the general practitioner in September 2016 because of fatigue, weight loss, nocturnal sweating, hypermenorrhea, and nose bleedings, associated with microcytic anemia (hemoglobin 4.5 mmol/L; mean corpuscular volume 59 fL). Abdominal imaging (December 2016) displayed hepatomegaly with multiple hepatocellular adenomas (Fig. 2A), based on which, the radiologist reported a suspicion of glycogen storage disease. After referral to the center of expertise, the working diagnosis of GSD Ia was established.

Our patient is the child of first-degree cousins of Moroccan ancestry and had hospital admissions in childhood due to various infections. Since 1993, our patient had suffered tiredness, for which she was followed by the local pediatrician. Between 2000 and 2006, she was evaluated by the pediatric immunologist and gastroenterologist because of failure to thrive, hepatomegaly, and persisting increase of erythrocyte sedimentation rate. She was growing at -2.5 SDs, below her target range, with delayed bone age, and

Abbreviations: G6P, glucose-6-phosphatase; G6Pase, glucose-6-phosphatase; GSD Ia, glycogen storage disease type Ia.

Received November 21, 2017; accepted February 21, 2018.

Copyright © 2018 The Authors. Hepatology published by Wiley Periodicals, Inc. on behalf of American Association for the Study of Liver Diseases. This is an open access article under the terms of the [Creative Commons Attribution-NonCommercial License](#), which permits use and distribution in any medium, provided the original work is properly cited, the use is non-commercial and no modifications or adaptations are made.

View this article online at wileyonlinelibrary.com.

DOI 10.1002/hep.29858

Potential conflict of interest: Nothing to report.

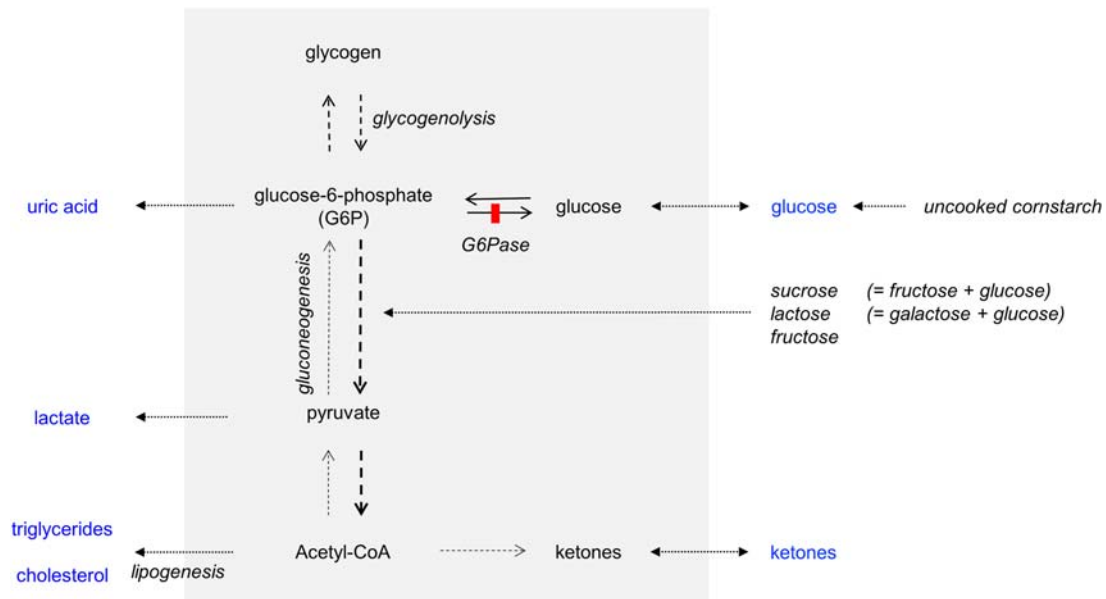


FIG. 1. The effect of liver (gray) G6Pase deficiency on major pathways of endogenous glucose production (glycogenolysis and gluconeogenesis), ketogenesis, and lipogenesis during fasting. This simplified scheme explains the biochemical phenotype of hypo- or non-ketotic hypoglycemia, hyperlactatecemia, hyperuricemia, and hyperlipidemia. Hepatomegaly is caused by storage of both glycogen and lipids. To compensate deficient endogenous glucose production, avoidance of fasting and regular meals are prescribed. Uncooked cornstarch is digested slowly and provides a steady release of exogenous glucose molecules, compared to simple sugars. To prevent nocturnal hypoglycemia, either cornstarch-enriched feedings every 3-4 hours (especially for infants, some adult GSD Ia patients may eventually need only one bedtime dose) are offered, or alternatively continuous gastric drip feeding. Because dietary fructose and galactose cannot be metabolized from G6P toward glucose, they contribute to the metabolic perturbation. Therefore, these dietary sugars are often restricted or avoided. Abbreviation: Acetyl-CoA, acetyl coenzyme A.

increased plasma uric acid concentrations were not recognized. She reported obvious signs of fasting intolerance; during the day, she frequently drank juices, and during the nights, she was hungry, sweating, and woke at least 1-2 times to eat or drink carbohydrate-containing substances. She got married in March 2016 and was working a full-time job as an elementary school teacher.

Dietary management was started with restrictions of sucrose, fructose, and lactose and frequent, small doses

of uncooked cornstarch, finally reaching 40 g every 4 hours, day and night. She was advised to discontinue her estrogen-containing oral contraceptive (that she had been using since March 2016) and to use alternative contraception. After 5 weeks, nocturnal cornstarch management was changed toward 120 g of extended-release cornstarch for 8 hours of sleep.

Regarding the liver adenomas, we aimed at a conservative, nonsurgical management and repeating liver imaging to evaluate the effect of the discontinuation

ARTICLE INFORMATION:

From the Departments of ¹Internal Medicine and ²Radiology, Groene Hart Hospital, Gouda, The Netherlands; Departments of ³Endocrinology, ⁴Radiology, Medical Imaging Center Groningen, and ⁵Section of Metabolic Diseases, Beatrix Children's Hospital, University of Groningen, University Medical Center Groningen, Groningen, The Netherlands.

ADDRESS CORRESPONDENCE AND REPRINT REQUESTS TO:

Terry G.J. Derks, M.D., Ph.D.
Section of Metabolic Diseases, Beatrix Children's Hospital,
University Medical Center Groningen, University of Groningen
P.O. Box 30 001

Groningen, 9700 RB, The Netherlands
E-mail: t.g.j.derks@umcg.nl
Tel: +31-50-3614147

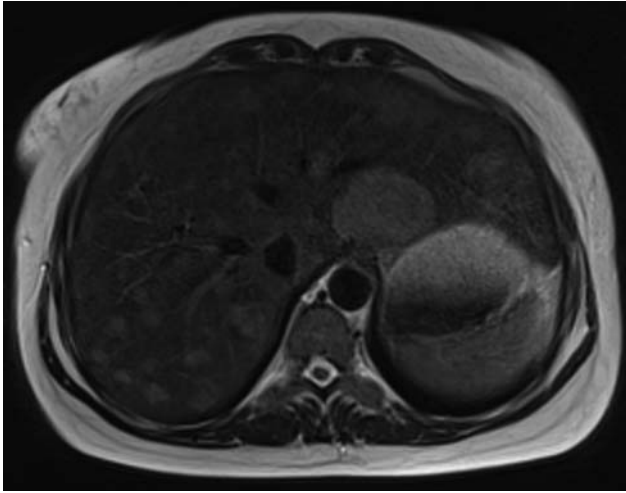


FIG. 2. Abdominal MRI image from our patient displaying hepatomegaly and multiple hepatocellular adenomas. On the T2-weighted image, many mildly hyperintense lesions are visible diffusely distributed in all liver segments, with a maximum diameter of 4.6 cm. The lesions showed arterial enhancement after administration of intravenous contrast material, persisting in the portal venous phase, consistent with hepatocellular adenomas (not shown). During the second trimester of her pregnancy, follow-up MRI in August 2017 displayed no significant changes compared to the initial MRI. After an uneventful pregnancy and Caesarian section in November 2017, follow-up MRI in February 2018 showed significant decrease in adenoma size, with the largest lesion measuring 4.1 cm (not shown). Based on the initial MRI and CT images of our patient, an interactive 3D model was created presenting the hepatomegaly, hepatocellular adenomas (in blue), and renomegaly in our patient (<https://skfb.ly/6uEvD>). Abbreviation: 3D, three-dimensional; CT, computed tomography; MRI, magnetic resonance imaging.

of oral contraceptive use and the start of dietary management. As reported,⁽³⁾ a significant decrease in adenoma sizes was observed in February 2018 (see legend Fig. 2). Meanwhile, Sanger sequencing of the *G6PC* gene revealed homozygosity for the c.1039C>T

(p.Gln347X) mutation, confirming our working hypothesis.

Discussion

After the classical textbook phenotype of monogenetic disorders, like GSD Ia, the complete clinical and biochemical spectrum is discovered. GSD Ia is an ultra-rare, but treatable, inherited metabolic disorder that can be diagnosed based on detailed history taking, physical examination, and standard laboratory investigations, even in relatively mildly presenting adult patients. Basic, but targeted, clinical testing is warranted to exclude GSD Ia in patients presenting atypical liver adenomas. Rapid diagnosis and proper dietary treatment are important to prevent symptomatic hypoglycemias, acute life-threatening metabolic perturbations, and chronic complications, related to liver adenomas and kidney disease.

Acknowledgment: The authors thank Anna Sieben (Institute for Medical Education, Faculty of Medical Sciences, University of Groningen), who created the interactive 3D-model for educational purposes.

REFERENCES

- 1) Bali DS, Chen YT, Austin S, Goldstein JL. Glycogen Storage Disease Type I. In: Pagon RA, Adam MP, Ardinger HH, Wallace SE, Amemiya A, Bean LJ, et al, eds. Seattle, WA: GeneReviews(R); 1993.
- 2) **Cassiman D**, Libbrecht L, **Verslype C**, Meersseman W, Troisi R, Zucman-Rossi J, et al. An adult male patient with multiple adenomas and a hepatocellular carcinoma: mild glycogen storage disease type Ia. *J Hepatol* 2010;53:213-217.
- 3) Beegle RD, Brown LM, Weinstein DA. Regression of hepatocellular adenomas with strict dietary therapy in patients with glycogen storage disease type I. *JIMD Rep* 2015;18:23-32.

Author names in bold designate shared co-first authorship.