



Minimal Incision Lower Augmentation Blepharoplasty: 3 Simple Steps to Facial Mid-Term Rejuvenation

Wilder Antonio Pérez Willis, MD; and Wilder Armin Pérez Soto, MD

Aesthetic Surgery Journal Open Forum 2022, 1–9

© 2022 The Aesthetic Society.

This is an Open Access article distributed under the terms of the Creative Commons Attribution-NonCommercial License (<https://creativecommons.org/licenses/by-nc/4.0/>), which permits non-commercial re-use, distribution, and reproduction in any medium, provided the original work is properly cited. For commercial re-use, please contact journals.permissions@oup.com <https://doi.org/10.1093/asjof/ojac029> www.asjopenforum.com

OXFORD
UNIVERSITY PRESS

Abstract

Background: The practice of removing skin and fatty tissue from the lower eyelid does not accommodate the different forms of facial aging. Therefore, techniques that encompass the recovery of facial volumes are common. Currently, when isolated lower blepharoplasty is performed, it does not take into account that mid-face rejuvenation is simultaneously possible. Furthermore, it is not always necessary to make incisions along the entire lash line, because this may be minimal in good candidates.

Objectives: This article presents a selection of patients who underwent augmentation lower blepharoplasty for the rejuvenation of the middle third of the face associated with the periorbital area, which is a modified traditional lower blepharoplasty technique performed with minimal incisions and fat grafting.

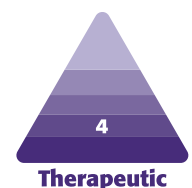
Methods: A retrospective study was conducted on 160 patients who underwent lower augmentation blepharoplasty performed by the authors from July 2017 to March 2021. The small incision utilized is approximately 15 to 18 mm and does not reach the ends or edges of the lower eyelid. The procedure is accompanied by fat grafting in the area of the middle third of the face. Finally, a Likert test was conducted to assess satisfaction.

Results: The patients presented a noticeable improvement, obtaining more attractive and youthful results from the middle third of the face. There were no major complications, and the patient outcomes were satisfactory.

Conclusions: Augmentation lower blepharoplasty with minimal incisions can be a useful alternative for selected patients who seek to jointly rejuvenate the middle third of the face.

Level of Evidence: 4

Editorial Decision date: March 17, 2022; online publish-ahead-of-print April 16, 2022.



The middle third of the face is a very important area in the aging process. In youth, it is characterized by being voluminous, with a natural cheek prominence or convexity reflecting the brightness of the lower eyelid, which is short and has a slight natural concavity. While the lower lid is considered part of the upper third of the face, its relationship and specifically the lid/cheek junction are an important part of the aging process. Disharmony here accentuates the aging process.

For this reason, it is very important to understand the changes that occur in the lower eyelid and the middle third of the face, such as excess skin, flaccidity of the lower

eyelid, laxity or hypertrophy of the *orbicularis oculi*, wrinkles, herniated fat that generates a bulge in 1 or all 3 fat bags, and subsidence of the orbital rim and the area of the nasojugal sulcus (tear through).¹⁻³

Drs Pérez Willis and Pérez Soto are plastic and reconstructive surgeons in private practice in Lima, Peru.

Corresponding Author:

Dr Wilder Antonio Pérez Willis, Av. San Borja Sur 526, San Borja, Lima 15021, Peru.

E-mail: wperezwillis@gmail.com; Instagram: [@dr.wilderperezwillis](https://www.instagram.com/dr.wilderperezwillis)

Table 1. Classification of Lacrimal Area Deformity According to the Hirmand System

Class	Clinical description
I	Patients have volume loss and limited medial to the canal. There patients may also have mild flattening that extends to the central cheek.
II	Patients with volume loss in the lateral orbital area and in addition to the medial orbit, and they may have moderate volume deficiency in the medial cheek and flattening of the upper central cheek.
III	Patients with a complete depression circumferentially along the internal, medial and lateral orbital rim.

One of the obvious signs related to aging is the deformity of the nasojugal sulcus. However, this deformation is not always related to aging, as genetic factors should be considered as well. Moreover, it should be noted that the formation of the groove is multifactorial (eg, loss of volume, herniation of orbital fat, skin laxity), indicating the nasojugal sulcus as a very dynamic area.⁴

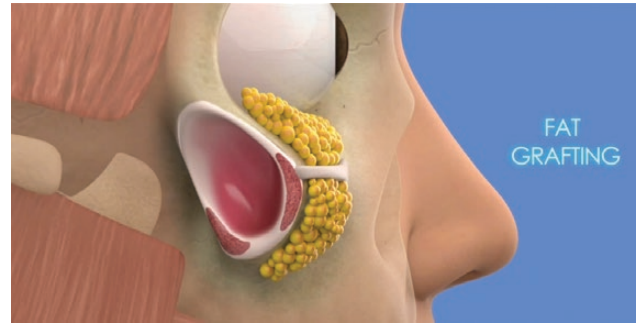
The aging of the lower lid and midface can be classified by the Hirmand system based on clinical evaluation (Table 1).⁴ This same table was used to select the patients in the present study. This article describes a more limited technique combined with fat grafting and discusses the results based on our experience with 160 patients who underwent augmentation lower blepharoplasty for the rejuvenation of the middle third of the face.

METHODS

A retrospective study of 160 patients, who underwent augmentation lower blepharoplasty with minimal incision focused on the middle third of the face, was carried out by the authors in a private clinic (Continental Clinic, Lima-Peru) from July 2017 to March 2021. Patient data, results (photographic study), and complications were recorded. Written consent was provided, and the patients agreed to the use and analysis of their data. The study adhered to the Declaration of Helsinki.

Patients between 28 to 58 years old with herniation of lower eyelid fatty packs and mild to moderate skin laxity were chosen, as they were classified as grades I to II based on the Hirmand classification only this ones were considered candidates for this procedure. Cases with severe laxities were excluded due to the need for incisions outside the external canthus or other types of surgeries.

The procedure was performed under local anesthesia with intravenous sedation. For educational purposes, the process was divided into 3 stages based on the operative times (Video).



Video. Watch now at <http://academic.oup.com/asjopenforum/article-lookup/doi/10.1093/asjof/ojac029>

Step 1: Fat Harvesting and Processing

Adipose tissues preferably in the periumbilical areas, abdominal flanks, and inner thigh were marked before surgery while the patient was standing. Such areas were preferred due to the high amount of adipose derived mesenchymal stem cells which could improve the permanence and reduce reabsorption of the fat tissue.^{5,6}

A modified Klein solution was first prepared with the following: 500 mL of physiological serum, 10 mL of 2% lidocaine, adrenaline (1: 100,000), and 10 mL of bicarbonate. A lower dose of lidocaine was used to reduce the toxicity of adipose-derived mesenchymal cells and mitigate impairment in the retention process.⁷ To obtain the adipose tissue, a 2.1-mm-diameter cannula with sharp 1-mm holes (Tulip Medical, San Diego, CA) was used, because these small holes allow the fat graft to have smaller and finer particles and would facilitate placement in the recipient area. This helps us to increase the fat retention process, which is known as microfat.⁸ Moreover, the reabsorption of adipose tissue is inversely proportional to the size of the implanted tissue.⁵

After extracting the adipose tissue, we centrifuged the adipose tissue at a speed of 500 or 2000 rpm for 10 min, and the tissue was then transferred to 1-cc Luer Lock syringes (Tulip Medical, San Diego, CA).

Step 2: Lower Blepharoplasty With Minimal Incision

A central incision measuring approximately 15 to 18 mm (Figure 1) is made and is used to access periobital fat. A skin muscle flap is designed centrally. Following the removal of fat, a small amount of skin is removed.

Step 3: Fat Grafting

Fat grafting was performed and included the midface as well as the nasolabial fold and cheek in some patients. Placement of the fat graft was done using 1-cc Luer lock type syringes with the support of blunt

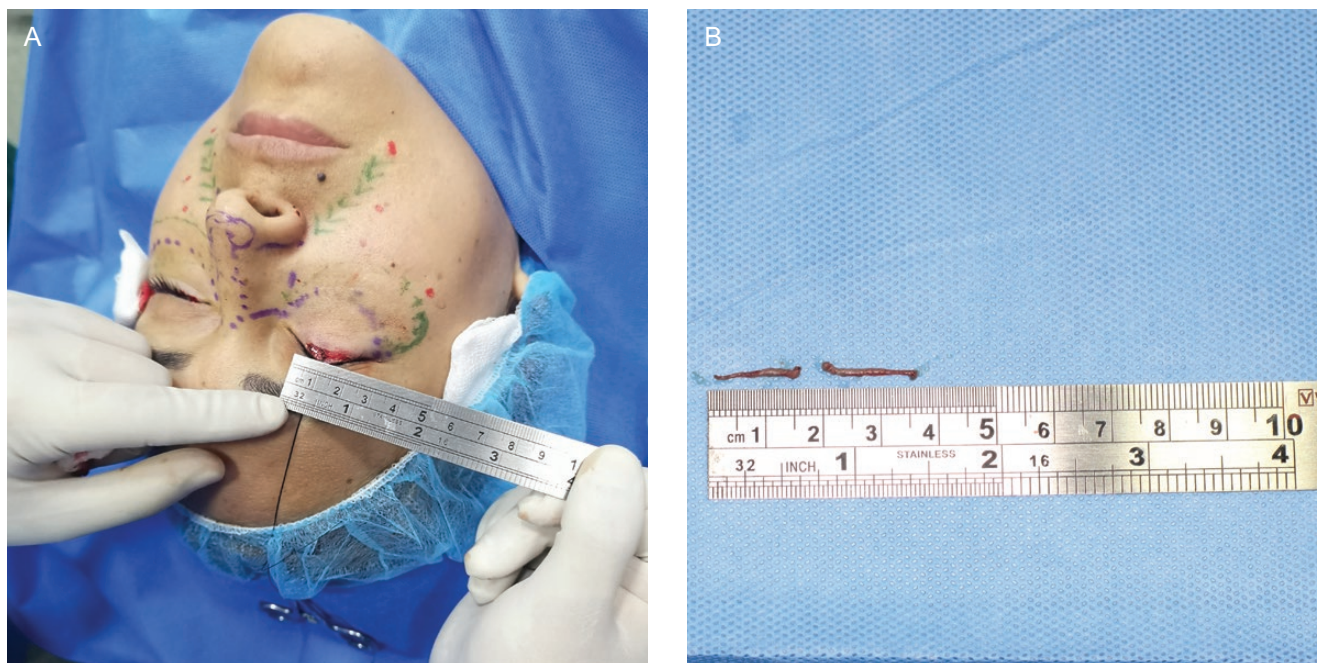


Figure 1. (A) A 40-year-old female patient during the surgical procedure where minimal incision is observed. Note that the incision does not occupy any of the edges of the lower eyelid and is associated with its measurement, which in this case measures approximately 17 mm. Similarly, the typical preoperative marking of inferior augmentation blepharoplasty is observed. (B) A small portion of skin tissue is removed, with an approximate length of 15-17 mm in extension.

microcannulas which have a 0.7-, 0.9-, and 1.2-mm hole in the periorbital and nasojugal area, in the malar area, and in the nasolabial fold, respectively. The plane and shape varied according to the area and patient needs. In the nasojugal and periorbital areas, grafting was performed in the supra-periosteal plane. In the zygomatic arch and malar areas, grafting was performed in the supra-periosteal plane and in the plane of the superficial aponeurotic muscular system. Lastly, in the area of the nasolabial fold, grafting was performed in the superficial and deep planes.

An upper blepharoplasty was also performed in some patients based on the indication. Follow-up of the patients was performed at 10 days, 1 month, 2 months, 3 months, and 6 months postoperatively. A Likert test measured patient satisfaction focusing on the periorbital area, nasolabial fold improvement, and scar appearance.

RESULTS

Augmentation lower blepharoplasty with minimal incision was performed in 160 patients. About 12.5% were males (20 patients) and 87.5% were females (140 patients), with an average age of 42 years (29-56 years). All surgeries were primary, including 37 patients (23%) who underwent simultaneous upper blepharoplasty and 130 patients (81%) who decided to place the adipose tissue in the nasolabial fold and malar area. Laser lipolysis was additionally performed on the neck and facial contours of 10 patients (6%). In total,

160 patients (100%) had hematomas and edema in the operated area, 10 patients (6%) had transitory tearing, 4 patients (2.5%) had poor positioning of the grafted fatty tissue, and 2 patients (1%) had transitory conjunctival effusions. None of the patients presented with other complications such as palpebral retraction, nerve injury, infections, and ectropion.

Photographs were taken for all patients preoperatively and at 1 and 6 months postoperatively. The average fat grafting for each side was 8 mm (full mid-term grafting) (Figure 2). The Likert test results (5 points) were as follows: none were very unsatisfied, 1 was unsatisfied, 5 were neutral, 35 were satisfied, and 119 were very satisfied.

DISCUSSION

Aging is known to be due to a series of complex processes, including the modification of the shape and volume of the facial skeleton, which changes how the facial structure is supported and in what way the face will age (Figure 3).⁹⁻¹³ The reabsorption of adipose tissue and changes in the skin have been described during the aging process. Gonzalez-Ulloa and Flores described these changes approximately 50 years ago, and they continue being studied to this day.¹⁴ Among these studies, Rohrich et al were able to identify a deep medial fat compartment, which is located superficial to the periosteum of the maxilla bone, postulating that the progressive loss of this compartment leads to pseudoptosis and determines

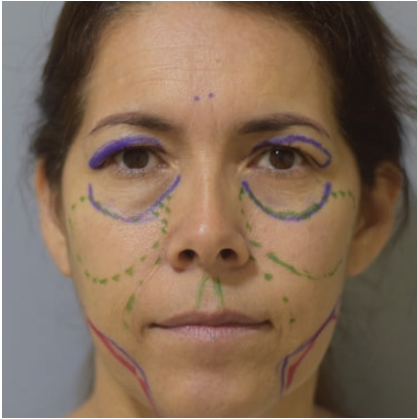

Figure 2. A 44-year-old female patient with typical preoperative markings. It is observed that upper blepharoplasty and augmentation lower blepharoplasty with minimal incision, which we intend to rejuvenate the middle third of the face, will be performed. The areas where the fatty tissue will be placed are observed with a green coloration. In addition, it is intended to perform a lipolysis laser (NdYAG: 1444 nm, Accusculpt, Lutronic corporation) in the double chin area and facial contouring.

the formation of the nasolabial fold (Figure 4).^{14,15} In this study, we proposed that wide resections of skin tissue and incision extensions beyond the external canthus are not necessary in many cases, because we observed that the removal of skin from the lower eyelid is an important part of the surgery. However, the recovery of the volume of the middle face results in a greater vitality for the rejuvenation of this area. Therefore, avoiding extensive skin removal in this area to reduce associated complications will achieve a better result of volumization than that in resection. This is the rationale behind our modification of the classic incision of transcutaneous lower blepharoplasty using a minimal incision that covers only the medial portion without reaching the extremities of both edges.

Traditional blepharoplasty can be complicated by some cases that have been deemed as unsightly, presenting subsidence of the lower periorbital area, atrophy of the *orbicularis* muscle, and poor positioning of the lower eyelid (Figure 5).¹⁶⁻¹⁸ Currently, lower blepharoplasty tends to be more conservative, as it preserves, repositions, and may even graft the fatty tissue. In contrast, the addition of volumization in this procedure has been

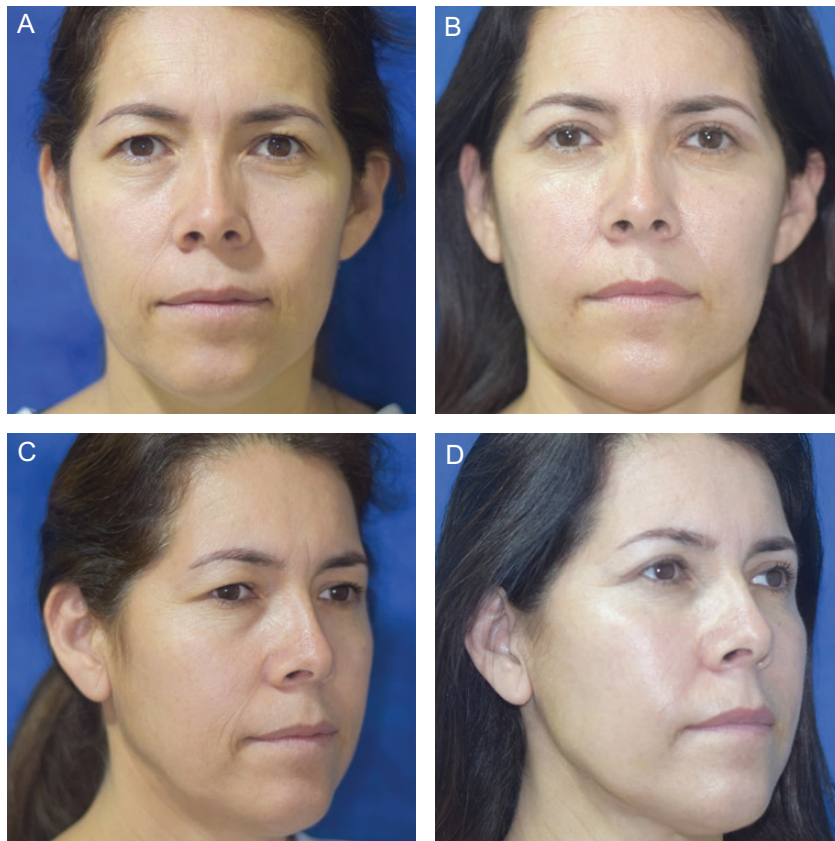

Figure 3. (A, C) The preoperative photographic shots of the 44-year-old female patient shown in Figure 2. A herniation of the fatty packs of the lower eyelids is observed in the middle third, as well as a deformity of the nasojugal sulcus. Furthermore, the loss of brightness and convexity of the cheek is appreciated, accompanied by a marked nasogenian sulcus. An excess of the skin in the upper eyelid with a loss of definition of the mandibular area can also be observed. (B, D) The patient is shown 4 months postoperatively, showing no herniated fatty packages associated with a young and bright appearance of the cheek, recovery of its natural convexity, and improvement of the nasogenian folds.

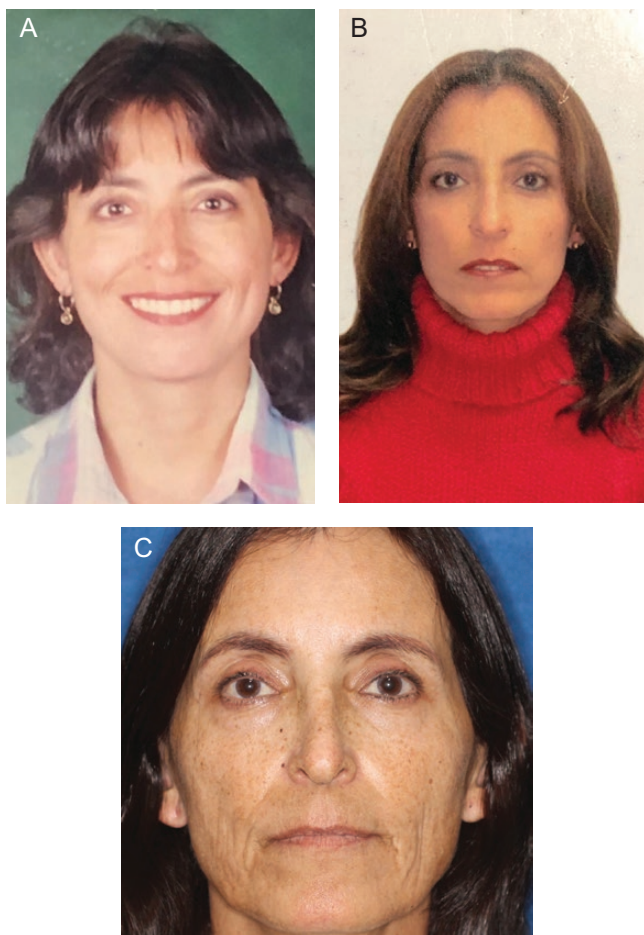

Figure 4. A timeline of a female patient's facial skin. (A) The patient at 33 years old, (B) at 42 years old, and (C) at 54 years old. Note the changes that arise in the middle third, showing a decrease in volume at the level of the cheekbones and loss of brightness. Likewise, marked deformation of the nasojugal sulcus is observed, which is accompanied by a herniation of the lower fat pads. Furthermore, there is an increase in the length of the lip filter and its flattening, with the loss of the white line of the lip and deformation of the cupid's bow. The formation of new expression lines is seen, as well as pigmentations at the epidermal level.

coined as “augmentation blepharoplasty” by Tonnard et al. This was described in 2 surgical steps: the resection of the fatty compartments with skin resection and the addition of fatty tissue. This technique is based on the maximum preservation of the already existing fatty tissues, thereby correcting the loss of volume of the eyelids and periorbital area through the placement of a fatty graft in the form of microfat, which is conservative in excessive skin removal.^{8,12,18}

Lower blepharoplasty techniques have transitioned to more conservative procedures. Volumizing the deep fatty tissue in the cheeks increases the anterior projection, reduces the nasolabial fold, and corrects the V deformity

by giving a more youthful and convex appearance to the cheek.¹² Thus, by combining lower blepharoplasty with the fat grafting, it is possible to rejuvenate the lower lid and soften the lid/cheek junction as well as the midface (Figure 6).^{12,18}

In classic transcutaneous lower lid blepharoplasty, the fat is removed from the medial, central, and lateral compartments, with or without suspension of the *orbicularis* muscle utilizing a full-length incision. If this incision extends beyond the orbital rim, it can result in a lateral scar that can take months to resolve in certain phototypes of patients.^{16,19,20} Although the traditional techniques of transcutaneous lower blepharoplasty present good results, they also could cause complications in a few cases—malposition is the most common from the first to sixth week postoperatively. Malposition of the lower lid can vary from excessive scleral show to ectropion, accounting for approximately 1% of malposition cases.²¹ One of the most frequent causes of malposition is excessive removal of skin tissue due to a poor decision by the surgeon. Given this, we proposed that, in many cases, excessive removal of the fatty packages at a young age alters the facial aging process, thereby leading to premature aging. Therefore, our goal was to remove the herniated fatty packages clearly, as it is always accompanied by a restitution of fat on the lower lid and midfacial term.

Like Tonnard et al, our technique relies on volume replacement as a key component for rejuvenation, particularly in Hirmand type-I and type-II patients. In contrast, Hirmand III patients have more laxity and they are not good candidates for this minimal incision, and the predictability of transferred fat without a facial procedure is not ideal and may result in the malposition of the grafted fatty tissue (Figures 7, 8).

We considered that the transcutaneous method is the best option for 2 reasons. First, a minimum amount of skin has to be removed to observe a better result. If we do not remove the skin, a certain laxity of skin tissue would be left in the area. Second, it allows you to see the exact specification of the herniated fatty packages. However, this is a personal opinion, and it is possible that a transconjunctival approach with skin pinch and grafting might be a viable alternative. This was described in a 5-step technique by Rohrich et al; however, we consider that, in the cases already explained, only 3 steps are required. It is not necessary to do a canthopexy or *orbicularis* retainment ligament release.²² Further studies are needed to validate this. Nevertheless, it must always be remembered that modern techniques are more conservative in terms of removing fat tissues.

Using the Likert test, our study found a mean satisfaction of 4.63 with the majority of the patients being satisfied and very satisfied with their results. However, one patient was unsatisfied, because she expected an improvement in the small wrinkles around the lower eyelid.

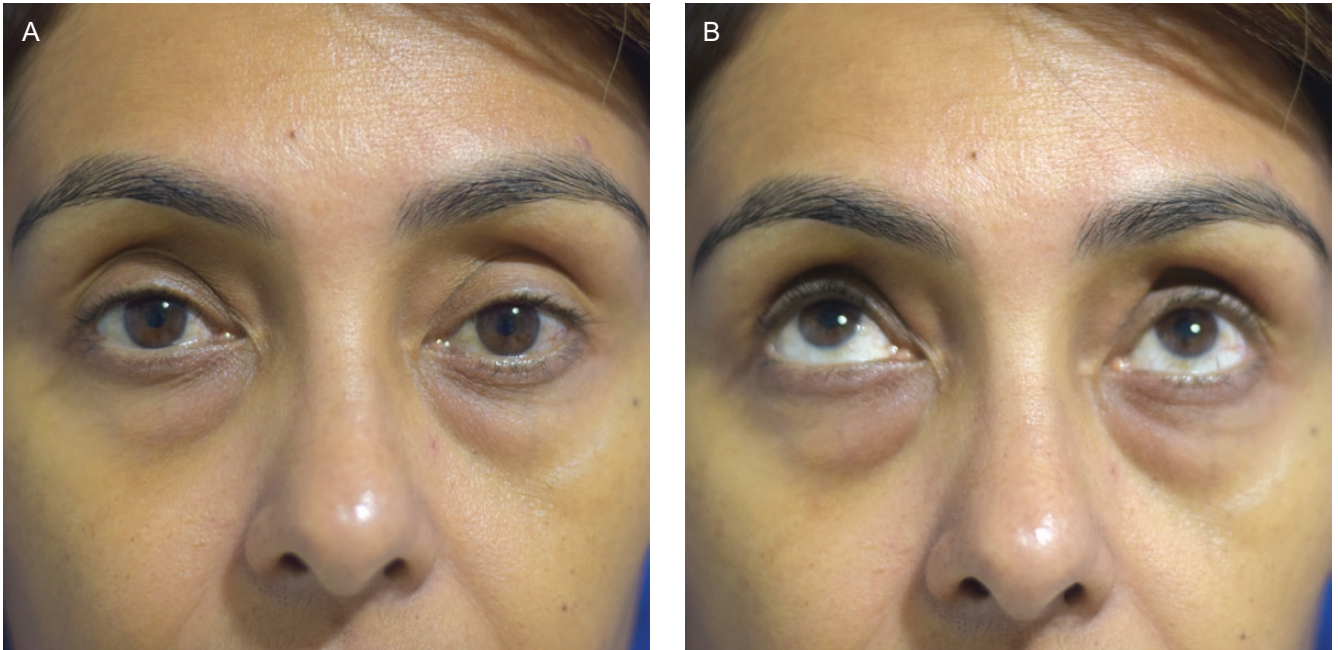


Figure 5. (A) A 42-year-old female patient with a classic deformity of the nasojugal sulcus accompanied by a slight loss of volume of the middle third associated with dark circles in the area. The classification is Hirmand II. (B) The defects are pronounced when the patient looks up.

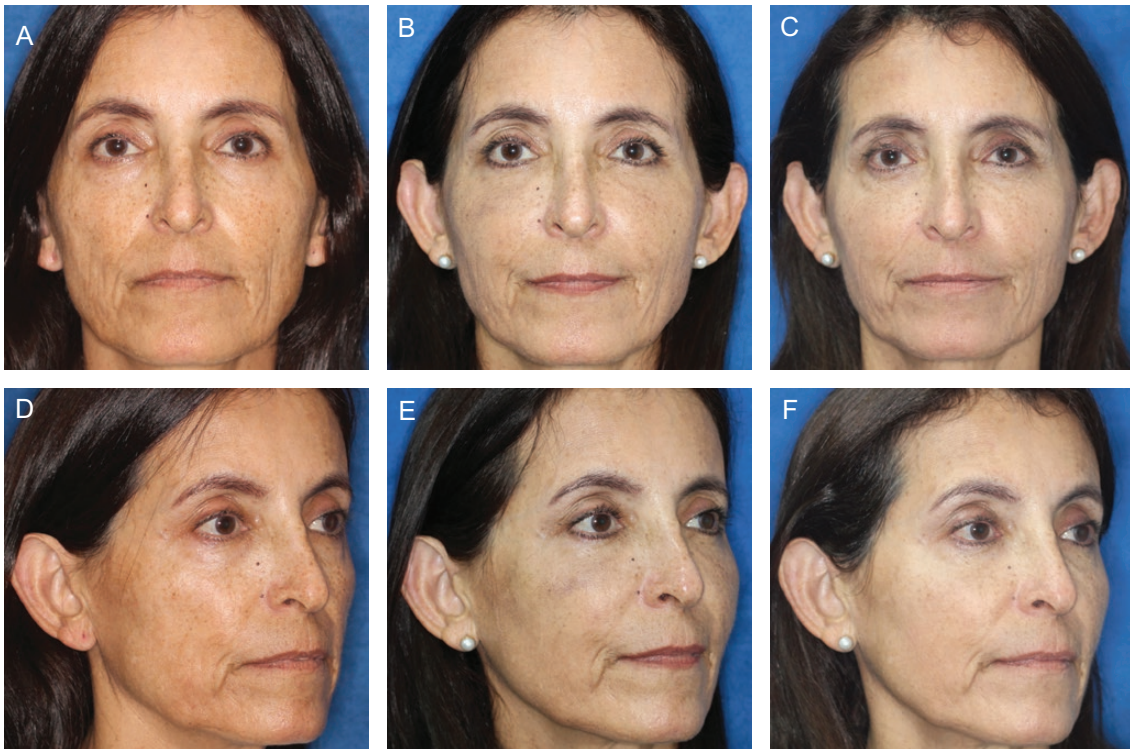

Figure 6. The 54-year-old female patient shown in [Figure 4](#) underwent augmentation lower blepharoplasty with minimal incision, in which we sought to give volume to the middle third of the face. (A, D) Preoperative photographs, wherein herniation of the lower fat bundles and evident loss of volume of the middle third are observed, with a decrease in the convexity and luminosity of the cheeks. This is an obvious skin damage that manifests with wrinkles and dehydrated skin. It is worth mentioning that 25 cc of fatty tissue was placed on each side. (B, E) The patient is seen 3 months postoperatively, and notable changes in the middle third are observed. (C, F) 6 months postoperative photographs, where we can see the great changes.

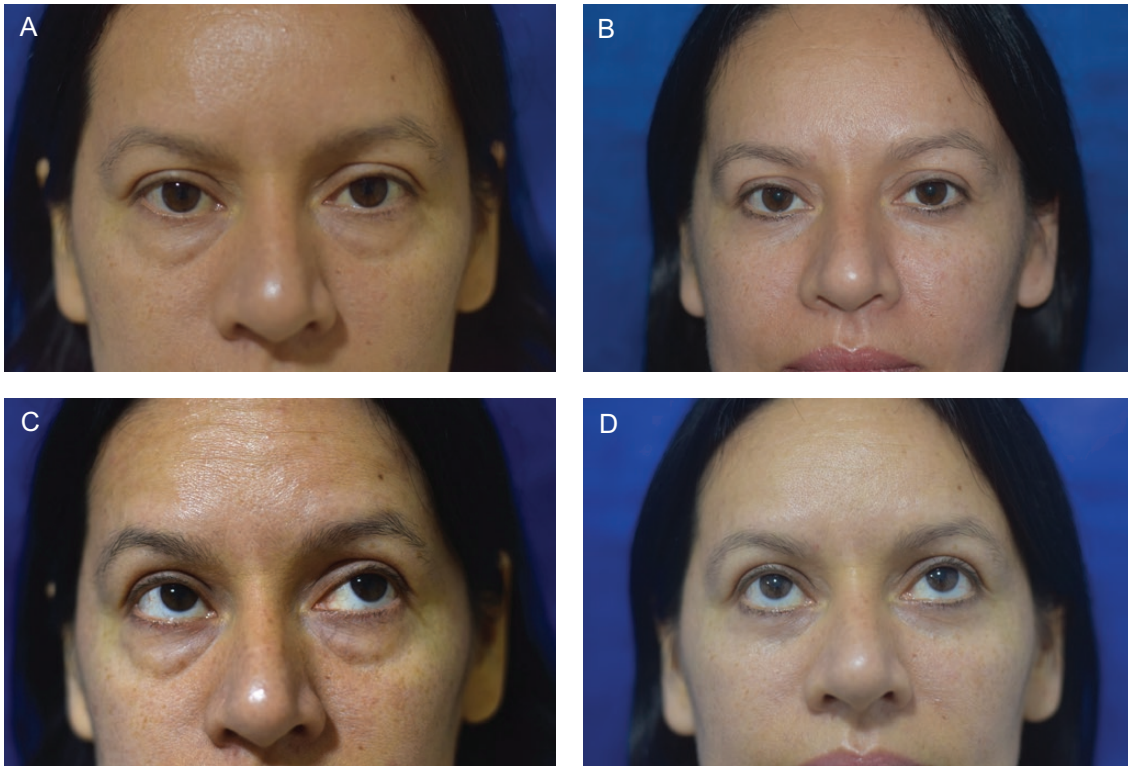


Figure 7. This is a 38-year-old female patient who underwent augmentation blepharoplasty. (A, C) Preoperative photographs of show nasojugal sulcus deformation classified as Hirmand II. This deformity is even more appreciated when the patient looks up with a fixed gaze. (B, D) Postoperative photographs at 4 months show the recovery of the youthful appearance of the orbital rim and the mid-face.

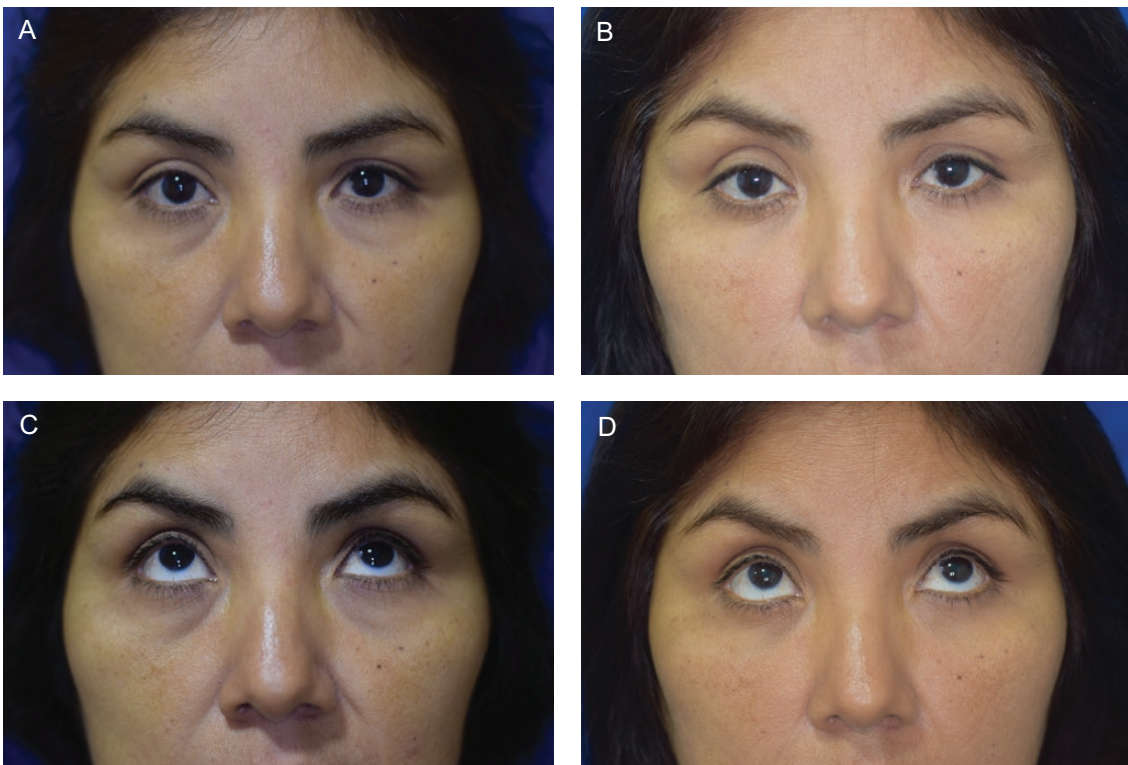


Figure 8. This is a 44-year-old female patient who underwent augmentation blepharoplasty. (A,C) Herniation of the fatty packages with nasojugal sulcus deformation classified as Hirmand II is observed preoperatively. This deformity is more pronounced when the patient looks up. (B, D) In the photographs below taken 4 months postoperatively, an evident improvement of the area is appreciated, without any presence of depression or “cadaverization” of the face.

This study was limited by a lack of control for comparison such as the transconjunctival approach with fat grafting. As such, we suggest a new study to investigate this comparison. In addition, further studies with more patients and comparisons with other techniques are also needed to validate these findings.

CONCLUSIONS

For many years, the classic algorithm for the treatment of the lower eyelids was based on the partial or total removal of the skin tissue, fat bags, and muscle. In 2003, the “augmentation blepharoplasty” technique was described, which was based on the lipoinjection of the periorbital area. This technique differed from the classic treatments of the nasojugal sulcus and is accompanied by lipografting in the form of microfat. In the present study, we found that augmentation blepharoplasty can be performed with minimal incision in selected patients, which is widely effective and efficient, preventing unwanted surgical complications and conservatively removing the skin and fatty tissue. Furthermore, the modified incision, which is based on the conventional method, is more conservative and safer for surgeons who are still on the learning curve.

We obtained great satisfaction from our patients due to the rejuvenation of the midface. Seeing that the deformity of the nasojugal sulcus was accompanied in the majority of cases by alterations in the middle third of the face, the treatment of these 2 areas should be considered as a whole, making it imperative to achieve significant changes and good results. Therefore, augmentation blepharoplasty with minimal incision is a safe, reliable, and easy alternative, resulting in great satisfaction in rejuvenating the nasojugal sulcus and the middle third of the face.

Acknowledgments

Dr. Perez-Willis would like to thank Dr. P. Tonnard and Dr. A. Verpaele for their guidance and mentorship.

Disclosures

The authors declared no potential conflicts of interest with respect to the research, authorship, and publication of this article.

Funding

The authors received no financial support for the research, authorship, and publication of this article.

REFERENCES

1. Hoefflin SM. *The Beautiful Face: The First Mathematical Definition, Classification, and Creation of True Facial Beauty*. Steven M. Hoefflin, MD; 2002.
2. Coleman SR. *Structural Fat Grafting*. Quality Medical Publishing; 2004: xx–xxiv.
3. Codner MA, McCord CD. Periorbital and Eye Lid Anatomy. In: Raton Jr B, eds. *Eyelid and Periorbital Surgery*, 1st ed. CRC Press; 2016:23–24.
4. Hirmand H. Anatomy and nonsurgical correction of the tear trough deformity. *Plast Reconstr Surg*. 2010;125(2):699–708. doi: [10.1097/PRS.0b013e3181c82f90](https://doi.org/10.1097/PRS.0b013e3181c82f90)
5. Lin JY, Wang C, Pu LL. Can we standardize the techniques for fat grafting? *Clin Plast Surg*. 2015;42(2):199–208. doi: [10.1016/j.cps.2014.12.005](https://doi.org/10.1016/j.cps.2014.12.005)
6. Padoin AV, Braga-Silva J, Martins P, et al. Sources of processed lipoaspirate cells: influence of donor site on cell concentration. *Plast Reconstr Surg*. 2008;122(2):614–618. doi: [10.1097/PRS.0b013e31817d5476](https://doi.org/10.1097/PRS.0b013e31817d5476)
7. Keck M, Zeyda M, Gollinger K, et al. Local anesthetics have a major impact on viability of preadipocytes and their differentiation into adipocytes. *Plast Reconstr Surg*. 2010;126(5):1500–1505. doi: [10.1097/PRS.0b013e3181ef8beb](https://doi.org/10.1097/PRS.0b013e3181ef8beb)
8. Tonnard PL, Verpaele AM, Zeltzer AA. Augmentation blepharoplasty: a review of 500 consecutive patients. *Aesthet Surg J*. 2013;33(3):341–352. doi: [10.1177/1090820X13478966](https://doi.org/10.1177/1090820X13478966)
9. Shaw RB, Jr, Katzel EB, Koltz PF, et al. Aging of the facial skeleton: aesthetic implications and rejuvenation strategies. *Plast Reconstr Surg*. 2011;127(1):374–383. doi: [10.1097/PRS.0b013e3181f95b2d](https://doi.org/10.1097/PRS.0b013e3181f95b2d)
10. Kahn DM, Shaw RB. Overview of current thoughts on facial volume and aging. *Facial Plast Surg*. 2010;26(5):350–355. doi: [10.1055/s-0030-1265024](https://doi.org/10.1055/s-0030-1265024)
11. Mendelson BC, Jacobson SR. Surgical anatomy of the midcheek: facial layers, spaces, and the midcheek segments. *Clin Plast Surg*. 2008;35(3):395–393. doi: [10.1016/j.cps.2008.02.003](https://doi.org/10.1016/j.cps.2008.02.003)
12. Coleman SR. [Facial augmentation with structural fat grafting](https://doi.org/10.1016/j.cps.2006.09.002). *Clin Plast Surg*. 2006;33(4):567–577. doi: [10.1016/j.cps.2006.09.002](https://doi.org/10.1016/j.cps.2006.09.002)
13. Sharad J. Dermal fillers for the treatment of tear trough deformity: a review of anatomy, treatment techniques, and their outcomes. *J Cutan Aesthet Surg*. 2012;5(4):229–238. doi: [10.4103/0974-2077.104910](https://doi.org/10.4103/0974-2077.104910)
14. Gonzalez-Ulloa M, Flores ES. Senility of the face—basic study to understand its causes and effects. *Plast Reconstr Surg*. 1965;36:239–246. doi: [10.1097/00006534-196508000-00013](https://doi.org/10.1097/00006534-196508000-00013)
15. Rohrich RJ, Pessa JE, Ristow B. The youthful cheek and the deep medial fat compartment. *Plast Reconstr Surg*. 2008;121(6):2107–2112. doi: [10.1097/PRS.0b013e31817123c6](https://doi.org/10.1097/PRS.0b013e31817123c6)
16. Pacella SJ, Codner MA. Minor complications after blepharoplasty: dry eyes, chemosis, granulomas, ptosis, and scleral show. *Plast Reconstr Surg*. 2010;125(2):709–718. doi: [10.1097/PRS.0b013e3181c830c7](https://doi.org/10.1097/PRS.0b013e3181c830c7)
17. Lelli GJ Jr, Lisman RD. Blepharoplasty complications. *Plast Reconstr Surg*. 2010;125(3):1007–1017. doi: [10.1097/PRS.0b013e3181ce17e8](https://doi.org/10.1097/PRS.0b013e3181ce17e8).
18. Zoumalan CI, Roostaeian J. Simplifying blepharoplasty. *Plast Reconstr Surg*. 2016;137(1):196e–213e. doi: [10.1097/PRS.0000000000001906](https://doi.org/10.1097/PRS.0000000000001906)
19. Katzen LB. The history of cosmetic blepharoplasty. *Adv Ophthalmic Plast Reconstr Surg*. 1986;5:89–96.

20. Baylis HI, Long JA, Groth MJ. Transconjunctival lower eyelid blepharoplasty. Technique and complications. *Ophthalmology*. 1989;96(7):1027-1032. doi: [10.1016/s0161-6420\(89\)32787-4](https://doi.org/10.1016/s0161-6420(89)32787-4)
21. McGraw BL, Adamson PA. Postblepharoplasty ectropion. Prevention and management. *Arch Otolaryngol Head Neck Surg*. 1991;117(8):852-856. doi: [10.1001/archotol.1991.01870200046006](https://doi.org/10.1001/archotol.1991.01870200046006)
22. Rodrich RJ, Ashkam G. The five-step lower blepharoplasty: blending the eyelid-cheek junction. *Plast Reconstr Surg*. 2011;128(3):775-783. doi: [10.1097/PRS.0b013e3182121618](https://doi.org/10.1097/PRS.0b013e3182121618)