

Unilateral medial rectus muscle recession combined lateral rectus muscle marginal myotomy for the treatment of Duane's retraction syndrome: A promising surgical procedure

Alireza Zandi, Arman Amirkhani, Mohsen Pourazizi

Department of Ophthalmology, Isfahan Eye Research Center, Isfahan University of Medical Sciences, Isfahan, Iran

Background: Duane's retraction syndrome is a congenital eye movement anomaly with narrowing of the palpebral fissure and globe retraction on attempted adduction. There are several surgical approaches to treat the narrowing of the palpebral fissure. The purpose of the present study was to evaluate the efficacy of unilateral medial rectus recession (MRR) muscle combined lateral rectus (LR) muscle marginal myotomy (MM) with unilateral MRR alone in the management of narrowing of the palpebral fissure of patients with Type 1 Duane's retraction syndrome (DRS). **Materials and Methods:** Twenty-eight patients with unilateral DRS Type 1 were randomly divided into two groups (14 eyes of 14 patients in each group). Age ≥ 5 years with DRS Type 1 with < 20 prism diopters in primary position who were candidates for surgery were consecutively enrolled in this randomized controlled trial. Patients were divided into treatment groups to receive unilateral MR recession with simultaneous MM group or with unilateral MR recession alone. The amount of deviation in primary position, abnormal head position, palpebral fissure width (PFW), and up/down shoot was evaluated before and 3 months after the surgery. This study was registered at the Iranian Registry of Clinical Trials under the registration code IRCT20131229015975N3. **Results:** PFW increased within MRR/MM group at the end of the study (8.86 ± 1.51) compared with the baseline (7.79 ± 1.48) ($P < 0.001$). In contrast, in the MRR/MM group, PFW did not increase statistically significantly within the MRR group at the end of the study (8.14 ± 1.35) compared with the baseline (8.07 ± 1.38) ($P = 0.67$). Mean \pm standard deviation of PFW (mm) in MRR/MM group after surgery (8.86 ± 1.51) was statistically significantly higher than that in the MRR group (8.14 ± 1.35), ($P = 0.002$). **Conclusion:** The results of our study demonstrate PFW significantly increased after unilateral MRR muscle combined LR muscle MM.

Key words: Duane's retraction syndrome, esotropia, eyelids, myotomy, strabismus

How to cite this article: Zandi A, Amirkhani A, Pourazizi M. Unilateral medial rectus muscle recession combined lateral rectus muscle marginal myotomy for the treatment of Duane's retraction syndrome: A promising surgical procedure. *J Res Med Sci* 2020;25:54.

INTRODUCTION

Duane's retraction syndrome (DRS), also known as Stilling-Türk-Duane syndrome, is a congenital eye movement anomaly, characterized by variable horizontal duction deficits, with narrowing of the palpebral fissure and globe retraction on attempted adduction, occasionally accompanied by upshoot or downshoot.^[1-3]

The exact mechanism of DRS is unknown but can be explained by a spectrum of mechanical, innervational,

neurologic, and genetic abnormalities. According to Huber, Type 1 DRS classification is the most common form of DRS with an early presentation.^[1,2] The complications associated with DRS such as amblyopia, ocular motility problem, abnormal head posture, upshoot, downshoot, and muscle under action can be prevented with accurate and on-time diagnosis and proper surgical management.^[4]

Although the management of DRS is a challenge and there is no standard guideline for the treatment of strabismus in these patients,^[1-5] horizontal rectus

Access this article online

Quick Response Code:



Website:

www.jmsjournal.net

DOI:

10.4103/jrms.JRMS_836_19

This is an open access journal, and articles are distributed under the terms of the Creative Commons Attribution-NonCommercial-ShareAlike 4.0 License, which allows others to remix, tweak, and build upon the work non-commercially, as long as appropriate credit is given and the new creations are licensed under the identical terms.

For reprints contact: reprints@medknow.com

Address for correspondence: Dr. Arman Amirkhani, Department of Ophthalmology, Isfahan Eye Research Center, Isfahan University of Medical Sciences, Isfahan, Iran. E-mail: armanamirkhani@yahoo.com

Submitted: 12-Nov-2019; **Revised:** 07-Jan-2020; **Accepted:** 04-Feb-2020; **Published:** 22-May-2020

muscle recession is recognized as the main treatment for this disorder.^[6,7]

Different surgical approaches for horizontal rectus surgery to treat DRS have been described, including ipsilateral medial rectus recession (MRR), symmetric or asymmetric bilateral MRR, ipsilateral MRR and contralateral MR posterior fixation suture, ipsilateral MRR, and lateral rectus (LR) resection.^[4]

Although most surgical techniques focused on MR surgery, the treatment corrects the primary position deviation without a significant improvement in movement limitations and globe retraction.^[8] Abnormal LR function and innervation in DRS, leading to cocontraction with the MRs on attempted adduction can create globe retraction, narrowing palpebral fissure, and overelevation or overdepression in adduction.^[9,10] Any procedure that would remove, release, or weaken the tight LR would eliminate the globe retraction and overelevation or overdepression in adduction.^[11,12]

One of the surgical options proposed for weakening and decreasing the function of LR is marginal myotomy (MM), also known as Z myotomy.^[13,14] The double MM of LR results in a Z configuration, which lengthens the muscle while retaining its arc of contact to the sclera;^[13] therefore, MM of the LR muscle can be used as a corrective procedure of esotropia and abnormal head position (AHP) in DRS Type I. The purpose of the present study was to evaluate the efficacy of unilateral MRR combined LR muscle MM to the management of narrowing of the palpebral fissure of patients with Type 1 DRS.

MATERIALS AND METHODS

Design and study participants

Twenty-eight eyes from 28 patients with DRS Type I were consecutively enrolled in this randomized controlled trial. The protocol of the study was approved by the Regional Bioethics Committee affiliated to the Isfahan University of Medical Sciences, Isfahan, Iran. All the important harmful effects or unintended effects related to the surgery as well as the novelty of the surgical technique was explained to the patients. Before initiation of the study, all patients or parents gave signed informed consent. This study was registered in the Iranian Registry of Clinical Trials (#IRCT20131229015975N3).

The inclusion criteria were patients with DRS Type I and age ≥ 5 years with < 20 prism diopters (PD) in the primary position. The indication for surgery was made on an individual basis, and the criteria were eye misalignment in the primary position < 20 PD, noticeable abnormal head turn, globe retraction, and significant upshoot or downshoot.^[15]

The exclusion criteria were mechanical causes of acquired retraction syndrome included trauma,^[11] neurogenic causes of acquired retraction syndrome,^[11] problematic conditions (e.g., diabetes mellitus, pregnancy, and breastfeeding period), and other types of DRS.

Sampling, randomization, and blinding

The sample size has been determined by assuming equal variances in the two groups in the level of 5%, and the power of 80%, which was determined 14 for each group. Patients were assigned to treatment groups using the random number generator software (Random Allocation Software; M. Saghaei, Isfahan, Iran) to receive unilateral MRR with simultaneous MM group or unilateral MRR group [Figure 1]. Allocation concealment was done by principal investigator using sealed opaque envelopes before the interventions. Patients were blinded to the received treatment and the one who assessed the outcome was blinded to performed operations as well.

Surgical procedure

In both groups, patients underwent ipsilateral standard MRR, described previously in a description of the recession and resection technique.

The MM was performed in four steps:^[14]

1. Limbal conjunctival incision and undermined conjunctiva and Tenon's capsule

An 8-mm limbal incision was made with scissors and carried back radially for 5 mm above and below the LR muscle. Tenon's capsule was grasped below the muscle edge and undermined to expose the sclera.

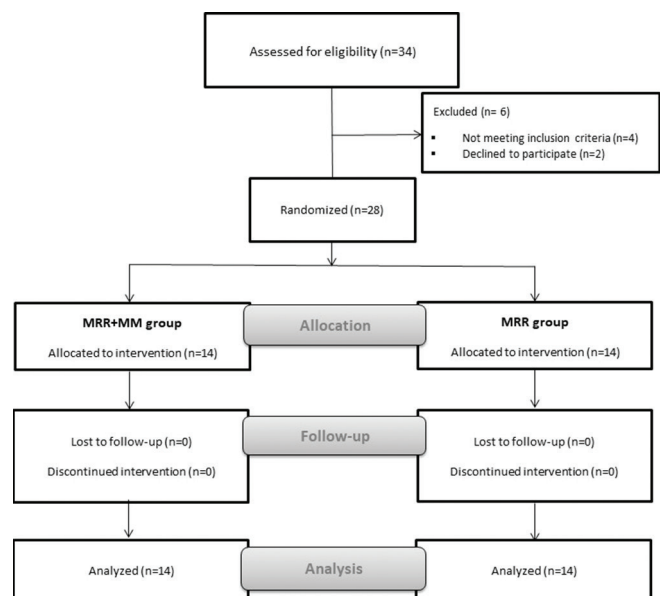


Figure 1: CONSORT flow diagram: Medial rectus recession with marginal myotomy versus medial rectus recession alone groups for the treatment Duane's retraction syndrome

2. Holding LR using resection clamp and crushing using hemostats on either side of the resection clamp [Figure 2] A muscle hook was passed through the opening area and underneath the LR until the tip of the hook was seen through Tenon's capsule, and then conjunctiva and Tenon's capsule with its "check ligaments" were separated from the LR by dissecting with sharp scissors.

3. LR cutting from above, next to globe, and from below at the distal site

A resection clamp was placed across the muscle about 4 mm from its insertion [Figure 3]. An anterior hemostat was placed 1 or 2 mm behind the insertion, and the posterior hemostat was placed 2 mm behind the anterior one for about 20 s or more.

When the hemostats were removed, the avascular crush line was cut from above, next to the globe, and from below, on the distal side with sharp scissors [Figure 2]. Each incision was passed at least two-thirds the width of the muscle.

4. Closure of the conjunctiva

Conjunctiva flat was drawn against the limbus from above and below and was closed using a continuous 8-0 vicryl suture.

Clinical evaluation and follow-up

The primary outcome measure was the difference in the palpebral fissure width (PFW), and the secondary outcome measures included the difference in the amount of deviation in primary position, degree of AHP, existence of globe retraction, and amount of up/downshoot in two groups.

AHP was estimated qualitatively with the patient viewing the last line of optotypes at 6 m.^[15] Motility examination was performed with prism and alternate cover tests.

Study visits were undertaken at baseline (visit 1: preoperative), day 7 (visit 2: complete reepithelialization), and month 3 (visit 3: postoperatively). In cases with complication-related surgery, patients were instructed to return for more follow-up examination.

Statistical analysis

Data were analyzed using the SPSS software (version 22 for Windows; SPSS Inc., Chicago, IL, USA). Variables are expressed as a mean \pm standard deviation (SD). The data were compared (baseline and after the procedure) by the independent sample *t*-test and ANCOVA test for changes in PFW and Fisher exact test for changes in the number of patients with AHP and up/downshoot. Within-group analysis, after intervention was done using the paired sample *t*-test and McNemar's test. Furthermore, risk ratio (RR) and 95% confidence intervals (95% CIs) were reported for the binary outcomes.

RESULTS

Data were distributed normally (Kolmogorov–Smirnov test, $P > 0.05$), with no outlier and all assumptions were followed without any violation (Levene's test, $P > 0.05$).

The present study had two groups each with 14 eyes from 14 patients who underwent strabismus surgery. A total of 28 cases were successfully treated and completed the course of the study. The mean \pm SD age was 18.3 ± 12.0 and 18.4 ± 11.3 years in the MRR/MM group and MRR group, respectively ($P > 0.05$). All patients had unilateral recession [Table 1]. There was no statistically significant baseline difference between the two groups in terms of PFW ($P > 0.05$), AHP ($P > 0.05$) and up/downshoot ($P > 0.05$). The difference in preoperative ocular deviation in the primary position of gaze was not statistically significant in

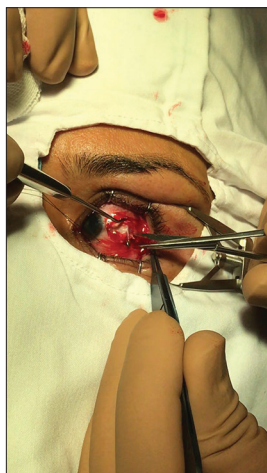

Figure 2: Marginal myotomy of the lateral rectus. A resection clamp is placed across the muscle about 4 mm from its insertion

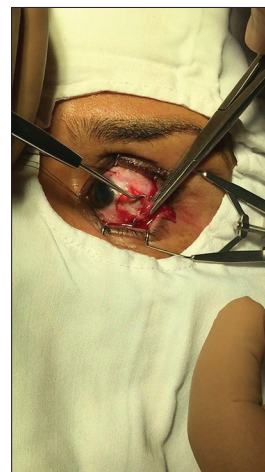


Figure 3: Marginal myotomy of the lateral rectus. Following the use of a resection clamp, an avascular crush line developed, when the hemostats were removed the avascular crush line cut partially

both groups at baseline ($P > 0.05$). The range of MR muscle recession was 5–8 mm in both groups.

Between-group analysis after intervention

The mean deviation of enrolled eye after the surgery was <8 PD in the MRR group and MRR/MM group that means all participants did not have eso/exotropia. Mean \pm SD of PFW (mm) in MRR/MM group after the surgery, 8.86 ± 1.51 , was significantly higher than that in MRR group, 8.14 ± 1.35 , ($P = 0.002$) [Table 2]. There were no significant differences between the groups after intervention on the number of patients with AHP ($P = 0.50$) and up/downshoot abnormality ($P = 0.14$) [Table 3].

Within-group analysis after intervention

Table 2 shows the difference in PFW (mm) within both groups at baseline and after the surgery.

PFW (mm) \pm SD increased within MRR/MM group at the end of the study (8.86 ± 1.51) compared with the baseline (7.79 ± 1.48) ($P < 0.001$). Besides, in the MRR/MM group, PFW (mm) \pm SD did not increase significantly within the MRR group at the end of the study (8.14 ± 1.35) compared with the baseline (8.07 ± 1.38) ($P = 0.67$) [Table 2].

There was a significant decrease in the number of patients with AHP at baseline than after the surgery within both groups (MRR/MM group: $P = 0.001$ and MRR group: $P = 0.004$; RR = 12 95% CI: 1.79–80.29) [Table 3]. Although the number of patients with up/downshoot decreased after surgery compared with the baseline within both groups, these decreases were not statistically significant in both groups (MRR/MM group: $P = 0.50$ and MRR group: $P = 0.25$; RR = 1.16 95% CI: 0.94–1.44).

In this study, no major ocular complications or side effects were noted regarding the surgical procedure and medications in both groups.

DISCUSSION

The results of our study demonstrated PFW significantly increased after unilateral MRR combined LR muscle MM. Overall, the aim of all strabismus surgery in DRS is usually based on the correction of primary position deviation, abnormal head posture, and globe retraction. Globe retraction and narrowing of the palpebral fissure can be corrected with recessions of the cocontracting muscles.^[9,10] In the pathophysiology of DRS, it is believed that DRS results from maldevelopment of motor neurons in the abducens nucleus and aberrant innervation of the LR muscle including the absence of the abducens motor neurons and ipsilateral cranial nerve VI and partial innervation of the LR muscle by branches from the cranial

Table 1: Characteristics of patients with Duane's retraction syndrome Type I enrolled in the study

Characteristics	MRR group (n=14)	MRR/MM group (n=14)
Age (years)		
Mean \pm SD	18.4 \pm 11.3	18.3 \pm 12.0
Range	6-38	6-53
Gender, n (%)		
Male	2 (12.5)	6 (42.9)
Female	12 (87.5)	8 (57.1)

MRR=Medial rectus recession; MM=Marginal myotomy; SD=Standard deviation

Table 2: Palpebral fissure width in both groups before and after the intervention

Variables	Time	Mean \pm SD		P
		MRR group	MRR/MM group	
PFW (mm)	Before	8.07 \pm 1.38	7.79 \pm 1.48	0.60*
	After	8.14 \pm 1.35	8.86 \pm 1.51	0.002**
	P	0.67***	<0.001***	-

*Independent samples t-test; **ANCOVA test; ***Paired samples t-test. MRR=Medial rectus recession; MM=Marginal myotomy; SD=Standard deviation; PFW=Palpebral fissure width

Table 3: Abnormal head position and up/downshoot in both groups before and after intervention

Variables	Time	MRR group,	MRR/MM group,	P*
		n (%)	n (%)	
AHP	Before	10 (71.4)	13 (92.9)	0.16
	After	1 (7.1)	2 (14.3)	0.50
	P**	0.004	0.001	-
Up/downshoot	Before	5 (35.7)	2 (14.3)	0.19
	After	2 (14.3)	0	0.14
	P**	0.25	0.50	-

*Fisher's exact test; **McNemar test. AHP=Abnormal head position; MRR=Medial rectus recession; MM=Marginal myotomy

nerve III. Furthermore, fibrosis of the LR or MR muscles suggests a primary myopathic etiology.^[5] As a result of these misinnervations, simultaneous activation of the MR and LR muscles supporting cocontraction of these two horizontal muscles was the cause of the globe retraction and narrowing palpebral fissure.^[1,16]

Although in cases of DRS Type I various surgical procedures may be considered, any procedure used that weakens the function of LR can be considered to improve the narrowing of the palpebral fissure and globe retraction; in our study, PFW increased after MM.^[17]

Several surgical options have been described in the literature for surgical correction in patients with DRS.^[18] In the present study, AHP decrease after the surgery within both groups.

Unilateral MR recession is commonly practiced in DRS Type I and can correct up to 20 PD of esotropia and improve primary position deviation.^[16] Various authors believe that performing MRR more than 6 mm or recessions of the

contralateral MR may lead to a severe cocontraction of the LR muscle and induce glob retraction and narrowed palpebral fissure.^[1,16] Clinical and *in vitro* biomechanical efficacies of MM or Z myotomy on the weakening of extraocular muscle have been evaluated on the basis of surgical outcomes.^[13,19-21]

Shin *et al.* reported on the *in vitro* biomechanical effect of MM. It was concluded that MM progressively reduces the force transmission for <60% of the surgical dose, with no further reduction due to the viscoelastic biomechanical characterization of MM.^[19] Therefore, Shin *et al.* hypothesized that Z myotomy exceeding 50% from each margin would maximally weaken EOM biomechanics that is compatible with our clinical study.^[19]

In cases with significant globe retraction and narrowing of the palpebral fissure, along with MR as an initial procedure, LR may have to be weakening as a second-stage procedure, if necessary.

To the best of our knowledge, our study is the first study of DRS Type I by the combination of MRR with MM that demonstrates the effectiveness of the combination on the improvement of palpebral fissure narrowing and glob retraction.

Our findings, however, need to be interpreted in light of our study limitations. First, the population of the study was of Persian ancestry; hence, our results would not be directly extrapolated to other populations. Second, a larger sample size might improve the results with more accuracy. We only screened our patients for 3 months and it may be necessary to follow the patients for a longer time to detect the accurate effects and also probable complications. Prospective multicenter studies with larger sample size and longer time follow-up would have better statistical power and accuracy to compare the treatments.

CONCLUSION

Our study demonstrated PFW significantly increased after unilateral MRR combined LR muscle MM. Thus, in DRS Type I, MM may be considered a secondary procedure combined with MR recessions when the primary position deviation is <20 PD.

Acknowledgments

This work was supported by a research grant from the research deputy of Isfahan University of Medical Sciences (Project NO.: 396503).

Financial support and sponsorship

This study was sponsored by the Isfahan University of Medical Sciences, Isfahan, Iran.

Conflicts of interest

There are no conflicts of interest.

REFERENCES

1. Kekunnaya R, Negalur M. Duane retraction syndrome: Causes, effects and management strategies. *Clin Ophthalmol* 2017;11:1917-30.
2. Yüksel D, Orban de Xivry JJ, Lefèvre P. Review of the major findings about Duane retraction syndrome (DRS) leading to an updated form of classification. *Vision Res* 2010;50:2334-47.
3. Gunduz A, Ozsoy E, Ulucan PB. Duane retraction syndrome: Clinical features and a case group-specific surgical approach. *Semin Ophthalmol* 2019;34:52-8.
4. Akbari MR, Manouchehri V, Mirmohammadsadeghi A. Surgical treatment of Duane retraction syndrome. *J Curr Ophthalmol* 2017;29:248-57.
5. Doyle JJ, Hunter DG. Transposition procedures in Duane retraction syndrome. *J AAPOS* 2019;23:5-14.
6. Mezaad-Koursh D, Leshno A, Klein A, Stolovich C. The efficacy of bilateral lateral rectus recession according to secondary deviation measurements in unilateral exotropic Duane retraction syndrome. *J Pediatr Ophthalmol Strabismus* 2018;55:47-52.
7. Farvardin M, Rad AH, Ashrafzadeh A. Results of bilateral medial rectus muscle recession in unilateral esotropic Duane syndrome. *J AAPOS* 2009;13:339-42.
8. Barbe ME, Scott WE, Kutschke PJ. A simplified approach to the treatment of Duane's syndrome. *Br J Ophthalmol* 2004;88:131-8.
9. Gaur N, Sharma P. Management of Duane retraction syndrome: A simplified approach. *Indian J Ophthalmol* 2019;67:16-22.
10. Whitman MC, Engle EC. Ocular congenital cranial dysinnervation disorders (CCDDs): Insights into axon growth and guidance. *Hum Mol Genet* 2017;26:R37-R44.
11. Velez FG, Velez G, Hendler K, Pineles SL. Isolated y-splitting and recession of the lateral rectus muscle in patients with exo-duane syndrome. *Strabismus* 2012;20:109-14.
12. Sukhija J, Kaur S, Singh U. Isolated lateral rectus recession with Y splitting versus anchoring of the lateral rectus muscle in patients with exotropic Duane syndrome. *J AAPOS* 2014;18:147-50.
13. de Faber JT, von Noorden GK. Medial rectus muscle marginal myotomies for persistent esotropia. *Am J Ophthalmol* 1991;112:702-5.
14. Helveston EM, Cofield DD. Indications for marginal myotomy and technique. *Am J Ophthalmol* 1970;70:574-8.
15. Merino P, Merino M, Gómez De Liaño P, Blanco N. Horizontal rectus surgery in Duane syndrome. *Eur J Ophthalmol* 2012;22:125-30.
16. Kraft SP. A surgical approach for Duane syndrome. *J Pediatr Ophthalmol Strabismus* 1988;25:119-30.
17. Kekunnaya R, Velez FG, Pineles SL. Outcomes in patients with esotropic duane retraction syndrome and a partially accommodative component. *Indian J Ophthalmol* 2013;61:701-4.
18. Andrews CV, Hunter DG, Engle EC. Duane Syndrome. In: Pagon RA, Adam MP, Ardinger HH, Wallace SE, Amemiya A, Bean LJH, *et al.*, editors. *GeneReviews*(R). Seattle, WA: University of Washington; 1993.
19. Shin A, Yoo L, Demer JL. Biomechanics of superior oblique Z-tenotomy. *J AAPOS* 2013;17:612-7.
20. Lee SY, Cho HK, Kim HK, Lee YC. The effect of inferior oblique muscle Z myotomy in patients with inferior oblique overaction. *J Pediatr Ophthalmol Strabismus* 2010;47:366-72.
21. Mellott ML, Scott WE, Ganser GL, Keech RV. Marginal myotomy of the minimally overacting inferior oblique muscle in asymmetric bilateral superior oblique palsies. *J AAPOS* 2002;6:216-20.