







ORIGINAL RESEARCH

Mastoid obliteration and external auditory canal reconstruction with silicone block in canal wall down mastoidectomy

Mohammad Famarzi MD^{1,2}  | Reza Kaboodkhani MD^{1,2}  |
Ali Famarzi MD^{2,3}  | Sareh Roosta MSc, MA²  |
Mohammadjavad Erfanizadeh MD¹  | Milad Hosseinialhashemi MD^{1,3} 

¹Department of Otorhinolaryngology – Head & Neck surgery, Shiraz University of Medical Sciences, Shiraz, Iran

²Otolaryngology Research Center, Shiraz University of Medical Sciences, Shiraz, Iran

³Student Research Committee, Shiraz University of Medical Sciences, Shiraz, Iran

Correspondence

Reza Kaboodkhani, Otolaryngology Research Center, Khalili Hospital, Shiraz University Medical Sciences, P.O. Box: 71348-14336, Shiraz, Iran.
Email: kaboodkhani@gmail.com

Abstract

Objective: To prevent cavity problems in canal wall down mastoidectomy, silicone block for mastoid obliteration was used.

Methods: In this retrospective cohort study, 39 patients (21 males and 18 females) underwent canal wall down mastoidectomy and mastoid obliteration using silicone block. We evaluated the postoperative outcome, the time until epithelialization of the cavity, graft success rate, and the hearing outcome.

Results: The time until complete epithelialization of the mastoid cavity was 35.5 ± 5.4 days. We had a graft success rate of 100% during the follow-ups. The postoperative evaluation revealed 36 dry ears (92.3%) patients without any cavity problems. However, one ear developed granulation tissue, and two ears had partially exposed silicone block, which required revision mastoidectomy. Regarding hearing outcomes, a complication such as deaf ear was not reported.

Conclusion: Silicone block is safe and suitable for mastoid obliteration and external auditory canal reconstruction in canal wall down mastoidectomy.

Level of Evidence: 4.

KEYWORDS

canal wall down mastoidectomy, chronic otitis media, epithelialization, mastoid obliteration, silicone block

1 | INTRODUCTION

The canal wall down mastoidectomy (CWDM) is a common procedure for patients suffering from chronic otitis media with extensive cholesteatoma. In the classic CWDM, large denuded and non-epithelialized mastoid cavity can lead to mastoid cavity problems, such as foul-smelling discharge, crusty debris, and formation of granulation

tissues that require life-long postoperative care. Literature review shows that the rate of cavity problems is 20-60%.^{1,2}

The CWDM and mastoid obliteration can improve the patients' quality of life and reduced postoperative visits, and cavity problems. Using different materials for mastoid obliteration has resulted in controversies in the field of otology. Generally, two kinds of material are used to obliterate the mastoid cavity, natural or synthetic.

This is an open access article under the terms of the Creative Commons Attribution-NonCommercial-NoDerivs License, which permits use and distribution in any medium, provided the original work is properly cited, the use is non-commercial and no modifications or adaptations are made.

© 2021 The Authors. *Laryngoscope Investigative Otolaryngology* published by Wiley Periodicals LLC on behalf of The Triological Society.

Examples of natural materials are autologous tissue,³ temporalis fascia as a free soft tissue graft, local muscle flap,^{4,5} cartilage graft,⁴ autologous bone,⁶ amniotic membrane graft,⁷ and bone pate plate.⁸ Examples of synthetic materials are hydroxyapatite,⁹ bioactive glass material,¹⁰ composite multifracted osteoplastic flap,¹¹ and silicone block.¹² To the best of our knowledge, only a study by Cho et al, 2012 attempted to use silicone block for the obliteration of the mastoid cavity. In the mentioned retrospective study, a combination of silicone block, bone pate, and muscle flap was used on 20 patients, of which 17 patients were suffering from chronic otitis media with cholesteatoma.¹²

Hence, we became intrigued to apply silicone blocks after reading the aforementioned article. The data on whether or not silicone block is beneficial for the obliteration of mastoid is still inadequate. Therefore, we took the initiative to investigate its application with slight modification amongst patients who had to undergo canal wall down mastoidectomy. In this retrospective study, we aim to report the efficacy of this method for mastoid obliteration and reconstruction of the external auditory canal in the CWDM.

2 | MATERIALS AND METHODS

2.1 | Design and settings

The local Ethics Committee of Shiraz University of Medical Sciences approved this retrospective study protocol (IR.SUMS.MED.REC.1398.294). All procedures were conducted by the first author (M. F.) at Dastgheib hospital, a tertiary center in the field of otology in southern Iran, affiliated with Shiraz University of Medical Sciences, and Dena Private Hospital, Shiraz, Iran. The study was executed from August 2015 to September 2020.

2.2 | participants

We included all patients suffering from chronic otitis media with cholesteatoma. They were all scheduled for primary or revision CWDM. Exclusion criteria were as follows: suffering from any other underlying medical problems, such as diabetes, asthma, cardiovascular diseases, coagulation disorders, chronic liver or renal diseases, and basic metabolic disorder. In addition to that, we excluded all smokers and patients with follow-up less than 24 months. Informed consent was obtained from all individual participants included in the study.

2.3 | surgical procedure

The surgical procedure was a combination of the modified version by Cho et al¹² and our previous method, which is described in detail in another article.⁷ In brief, our surgical procedure consisted of CWDM with obliteration of mastoid and the reconstruction of the external auditory canal (EAC). After the postauricular incision, the anteriorly-

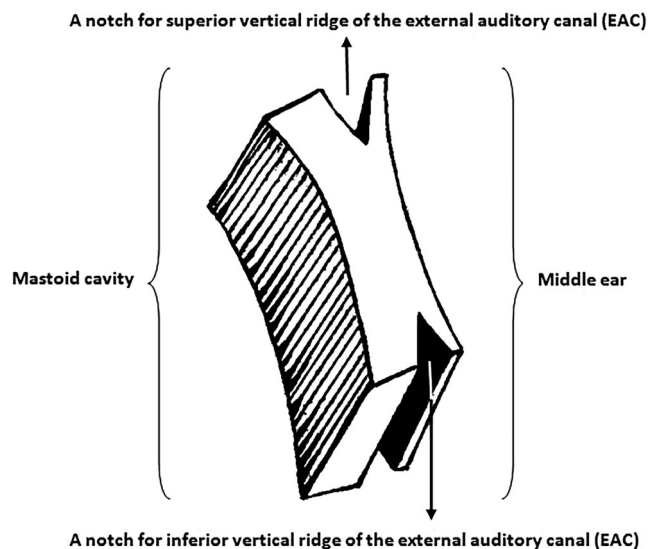


FIGURE 1 A butterfly silicone block

based musculoperiosteal flap was elevated, and the auricle retracted anteriorly. A Koerner's flap was designed to preserve the lateral posterior canal wall skin as much as possible. During CWDM, two vertical ridges in the postero-superior and postero-inferior portions of the EAC were kept intact to assist the vertical structure by supporting the newly reconstructed EAC (Figure 1 and Figure 2: I-IV). After eradicating the pathology in the middle ear and the mastoid cavity, a silastic sheet was inserted into the middle ear cavity, and temporalis fascia was used as the underlay graft, and then obliteration of the mastoid was performed. A butterfly shape silicone (Hansbiomed Co., Daejeon, Korea) was designed, using a No.15 blade (Figure 2: V-VI, Video S1). To have a better view of the middle ear cavity, the anterior butterfly wings (forewing) were made thinner than the posterior wings (hindwing) (Figure 1 and Figure 2: V-VI, Figure 3, Video S1). Then, the preserved supportive vertical ridges of the EAC were fitted into the gap of the anterior and posterior wings, where the base of the anterior silicone block was positioned on the facial ridge, which was then superiorly positioned over the lateral canal and tegmen (Figures 2 and 3). In the small mastoid cavities, usually, one piece of butterfly shape silicone block (10-15 mm in length, 3-7 mm in width, 10 mm in height) is sufficient to provide adequate bulkage, but in the large mastoid cavities, additional smaller piecemeal silicone blocks are placed in the posterior face of the new silicone EAC. Anteriorly, a large temporalis fascia graft was placed in the medial to remove any remnant of the tympanic membrane by covering the facial ridge, which was gently placed posteriorly to completely cover the anterior aspect of silicone. On the other hand, in the revision cases, if temporalis fascia was not adequate, compressed post-auricular soft tissue was used to cover the silicone block. To cover the mastoid cavity, the anteriorly based musculoperiosteal flap was returned into its original anatomic position by Vicryl 3-0. After the closure of the post-auricular wound, preserved lateral posterior EAC skin was placed on the newly modified canal wall to cover the temporalis fascia (Figure 2). Finally, the meatus was

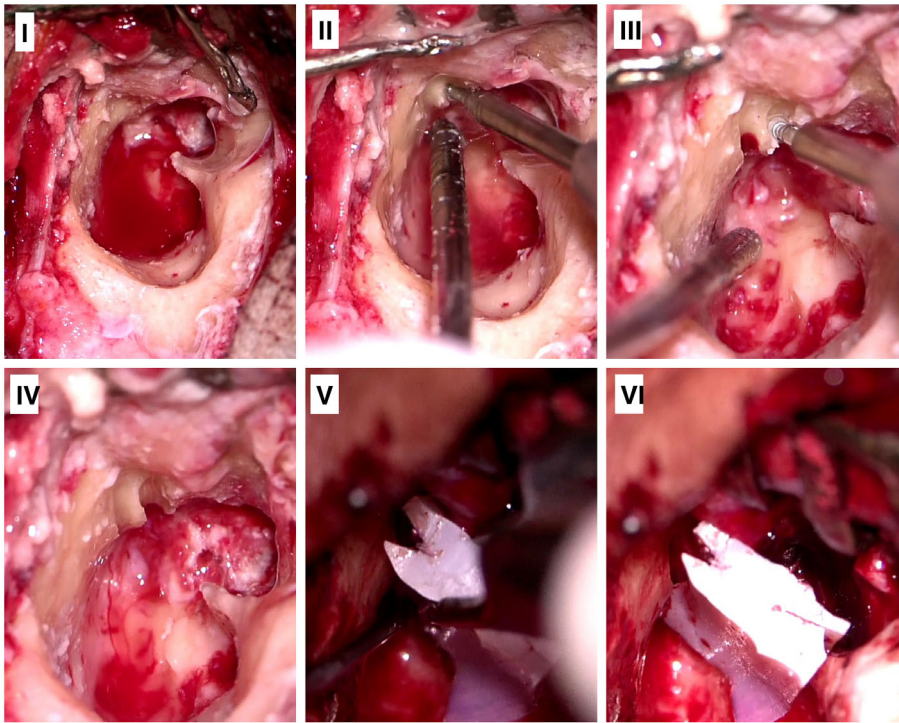


FIGURE 2 The process of silicone block insertion. I-IV: the creation of the lower and upper bony ridges; V-VI: insertion of the butterfly silicone block

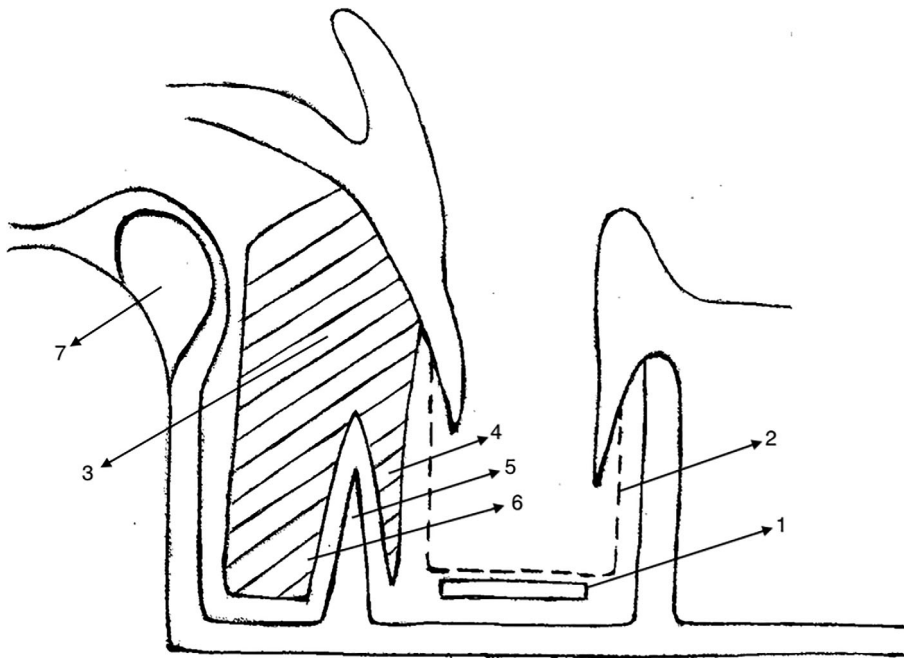


FIGURE 3 Axial view of the mastoid cavity, silicone block was covered by large temporalis fascia. 1. Silastic sheet, 2. Temporalis fascia, 3. Silicone block, 4. Anterior wing, 5. Bony ridge, 6. Posterior wing, 7. Sigmoid sinus

packed with Gelfoam and a gauze pack impregnated with ophthalmic tetracycline ointment. In all cases, nearly normal contour EAC was achievable; hence, meatoplasty was not required.

2.4 | Main outcome measures

After a week, to assess the patient's condition, the tetracycline gauze was removed, using microscopic otoscopy. Three weeks after the

operation, a microscopic otoscopy was performed. The follow-up interval was subjected to granulation tissue formation. If it had formed, patients were evaluated once a fortnight, and if not, they were checked every 2, 4, 6, and 12 months within the first year and once a year thereafter. If granulation tissue was detected, chemical cautery was performed, using 5% trichloroacetic acid. The average completion time for mastoid cavity epithelialization was set as our primary outcome. The development of granulation tissue, graft success rate, and pre-post-operative hearing outcomes was considered secondary.

Hearing results were evaluated using pure tone auditory analysis at 0.5, 1, 2, and 4 kHz frequencies. Since the 3-kHz frequency is not routinely measured in our center, instead the mean of 2- and 4-kHz frequencies were considered. In addition, the pre-post-operative bone conduction (BC), air conduction (AC), speech discrimination score (SDS), air-bone gaps (ABG), and speech reception thresholds (SRT) were evaluated. In this study, we considered one-week preoperative and 6-month postoperative audiogram for evaluation.

2.5 | Statistical analysis

Statistical analyses were performed via IBM SPSS Statistics for Windows, version 22 (IBM Corp., Armonk, New York). To compare pre-post-operative hearing results, Paired t test or Wilcoxon test was

TABLE 1 Pre- and post-operative hearing variables

	Pre-operative	Post-operative	Improvement	P-value
AC ^a (dB)	46.4 (14.8) ^b	48.3 (14.9)	-2.0 (15.8)	0.437
BC ^a (dB)	11.7 (11.9)	11.3 (11.0)	0.3 (8.0)	0.936
ABG ^a (dB)	34.7 (10.8)	37.0 (9.6)	-2.3 (14.2)	0.313
SRT (dB)	45.0 (13.9)	46.4 (15.2)	-1.4 (15.6)	0.577
SDS (%)	94.7 (8.8)	94.7 (6.7)	-0.1 (9.6)	0.537

Abbreviations: ABG, air-bone gap; AC, air conduction; BC, bone conduction; SDS, speech discrimination score; SRT, speech reception threshold.

^aFrequency of 0.5-3 kHz.

^bValues are mean (SD).

utilized. P values less than .05 were considered to be statistically significant.

3 | RESULTS

Forty-two ears belonging to 42 patients underwent CWDM to obliterate mastoid, using silicone block. In total, due to insufficient follow-up, three patients were excluded. Finally, 39 patients, including 21 males (53.8%) and 18 females (46.2%), were investigated. The average age of patients was 32.18 ± 16.42 (4-62 years old). Follow up period ranged anywhere from 35-82 months (mean ± SD: 60.7 ± 19.8).

The type of operation was primary for 32 (82.1%) ears and revision for 7 (17.9%) ears. Type of tympanic membrane graft consisted of temporalis fascia in 30.8% (12 ears), cartilage graft in 64.1% (25 ears), and post-auricular soft tissue in 5.1% (2 ears). Regarding intra-operative pathology; 37 ears were affected with cholesteatoma (94.9%), and one ear developed granulation tissue (2.6%). Intra-operative status of malleus was normal in 7 ears (17.9%) and absent or necrotic in 32 ears (82.1%). Incus was either unnoticeable or necrotic in all 39 ears (100%). Eighteen ears (46.2%) had normal stapes, and 21 ears (53.8%) had absent or necrotic superstructure of stapes. Generally, all ears had an abnormal ossicular chain.

There were no significant differences between pre- and post-operative hearing parameters, as shown in Table 1 and Figure 4. There was no incident of post-operative deafness. It should be stated that although the scattergram (Figure 4) shows hearing reduction amongst SDS in the two boxes of the right quadrants, post-operative SDS in all ears was within 80-100% range.

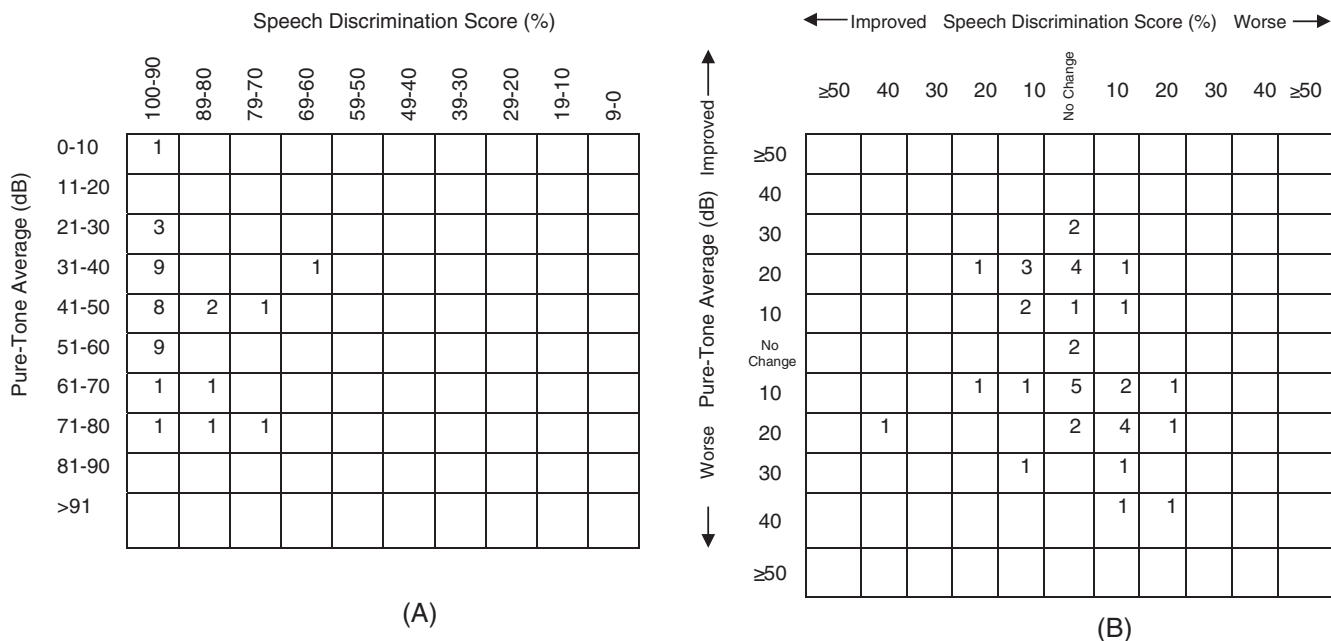


FIGURE 4 Pre-operative (A) and post-operative (B) scattergram of hearing outcomes, pure-tone average: average of air conduction thresholds in frequencies of 0.5, 1, 2, and 3 kHz

TABLE 2 Pre- and post-operative hearing variables of patients underwent second stage ossiculoplasty

Type of ossiculoplasty	Audiometric parameters	Pre-operative	Post-operative	Improvement	P-value
TORP (n = 13)	AC ^a (dB)	48.2 (9.3) ^b	37.8 (10.6)	10.3 (13.9)	0.034
	BC ^a (dB)	8.9 (3.7)	12.3 (5.1)	-3.4 (2.9)	0.008
	ABG ^a (dB)	39.2 (8.5)	25.5 (9.6)	13.7 (13.4)	0.006
	SRT(dB)	49.6 (8.5)	38.8 (10.4)	10.8 (12.2)	0.013
	SDS (%)	94.1 (4.2)	95.4 (6.1)	-1.2 (5.5)	0.414
PORP (n = 8)	AC ^a (dB)	44.6 (10.7)	29.4 (11.7)	15.2 (15.5)	0.025
	BC ^a (dB)	10.6 (4.8)	6.5 (5.5)	4.1 (7.0)	0.141
	ABG ^a (dB)	34.0 (10.4)	22.9 (7.3)	11.0 (11.2)	0.042
	SRT(dB)	47.6 (9.4)	35.0 (11.5)	12.6 (14.5)	0.002
	SDS (%)	98.5 (3.0)	98.5 (4.2)	0.0 (5.7)	1.000

Abbreviations: ABG, air-bone gap; AC, air conduction; BC, bone conduction; PORP, partial ossicular replacement prosthesis; SDS, speech discrimination score; SRT, speech reception threshold; TORP, total ossicular replacement prosthesis.

^aFrequency of 0.5-3 kHz.

^bValues are mean (SD).

TABLE 3 The comparison of the outcomes between amniotic membrane, temporalis fascia, and silicone block groups

Parameters	Amniotic membrane ⁽¹⁾ (N = 75) (Faramarzi et al ⁷)	Temporalis fascia ⁽²⁾ (N = 73) (Faramarzi et al ⁷)	Silicone block ⁽³⁾ (N = 39) (current study)	P-value (1 vs 2)	P-value (3 vs 2)	P-value (1 vs 3)
Duration of complete epithelialization of the cavity (day)	41.4 (7.7) ^b	59.2 (9.1)	35.5 (5.4)	<0.0001	<0.0001	<0.0001
Granulation tissue formation	4 (5.3%)	12 (16.4%)	1 (2.6%)	0.035	0.032	0.659
Graft success rate	70 (93.3%)	67 (91.8%)	39 (100%)	0.763	0.005	0.013
Preoperative AC ^a (dB)	42.5 (12.2)	45.4 (14.3)	46.4 (14.8)			
Postoperative AC (dB)	39.9 (13.5)	43.1 (17.4)	48.3 (14.9)			
Gain (dB)	2.6 (13.1)	2.3 (15.7)	-2.0 (15.8)	0.900	0.171	0.101
Preoperative BC ^a (dB)	7.8 (10.2)	10.1 (7.5)	11.7 (11.9)			
Postoperative BC (dB)	11.3 (8.9)	12.5 (10.7)	11.3 (11.0)			
Gain (dB)	3.5 (9.0)	2.4 (9.2)	0.3 (8.0)	0.463	0.232	0.064
Preoperative ABG ^a (dB)	34.7 (12.2)	35.3 (12.7)	34.7 (10.8)			
Postoperative ABG (dB)	28.6 (14.2)	30.7 (13.1)	37.0 (9.6)			
Gain (dB)	6.1 (14.5)	4.6 (12.4)	-2.3 (14.2)	0.500	0.009	0.004
Preoperative SRT (dB)	41.7 (14.3)	44.7 (16.1)	45.0 (13.9)			
Postoperative SRT (dB)	38.6 (17.8)	43.7 (18.2)	46.4 (15.2)			
Gain (dB)	3.1 (17.1)	1.0 (17.9)	-1.4 (15.6)	0.467	0.482	0.173
Preoperative SDS (%)	93 (12.2)	91.9 (17.2)	94.7 (8.8)			
Postoperative SDS (%)	95.1 (16.4)	91.5 (13.6)	94.7 (6.7)			
Gain (%)	2.1 (13.5)	0.4 (14.1)	-0.1 (9.6)	0.455	0.843	0.367

Abbreviations: AC, air conduction; ABG, air-bone gap; BC, bone conduction; SDS, speech discrimination score; SRT, speech reception threshold.

^aFrequency of 0.5-3 kHz.

^bValues are mean (SD).

During the research period, 21 patients underwent second stage ossiculoplasty; 13 patients underwent total ossicular replacement prosthesis (TORP), and eight patients underwent partial ossicular replacement prosthesis (PORP). As Table 2 shows, AC, ABG, and SRT had improved

significantly after operation in each TORP and PORP surgery. Although BC increased significantly after operation in TORP surgery, the increase was not clinically significant. There were no significant differences between pre- and post-operative BC in PORP surgery and between pre-

and post-operative SDS in TORP or PORP surgery. Concerning recurrent or residual cholesteatoma, we found no cholesteatoma.

The time until complete epithelialization of the cavity was 35.5 ± 5.4 days. During the follow-up, the graft success rate was 100%. In total, 36(92.3%) ears had no cavity problems; however, one ear (2.6%) suffered from granulation tissue, and two patients (5.1%) had partial exposure, but no extrusion of silicone blocks in the mastoid cavity; hence, no revision mastoidectomy was required.

4 | DISCUSSION

Our study revealed that mastoid obliteration with silicone block is a relatively simple, time-saving and useful method. The initial results are encouraging, acceptable, and appear to be durable. The time until epithelialization of the cavity in our study was similar to previous studies that had reported 25 to 90 days post-operation for complete epithelialization.^{5,7,13}

Since ossiculoplasty is generally done for the primary or secondary stage operation, Yung categorized the causes of failure as; prosthesis, surgeon, and middle ear status, such as inflammation and infection.¹⁴ To obtain a better hearing outcome, the tympanic membrane must be intact without any sign of middle ear inflammation.¹⁵ As shown in scattergram (Figure 4), postoperatively we found lower AC values, indicating extensive cholesteatoma and necrotic ossicles that must be removed. Since the indication of primary canal wall down mastoidectomy was due to extensive cholesteatoma; hence, we favored ossicular reconstruction in the next stage, which is routine for ears with normal middle ear mucosa and intact tympanic membrane. In this situation, we found that a thin skin-covered silicone block as posterior EAC, can be easily incised and elevate tympanomeatal flap using a round knife. There was no risk of poor healing in the second-stage tympanomeatal incision overlying a silicone block, and during the research period, we performed ossicular chain reconstruction in second-stage ossiculoplasty on 21 patients, and we were able to elevate tympanomeatal flap over silicone block as posterior EAC. As mentioned in the results section, hearing outcomes were generally satisfactory, and no cholesteatoma were found in cases that had undergone second-stage ossiculoplasty. The findings for the second stage ossiculoplasty are in line with other studies that routinely performed ossicular chain reconstruction without using silicone block.¹⁶

We believe that due to insufficient bulk of flaps, especially in large mastoid cavities, silicone block can be a promising alternative musculoperiosteal flaps. However, it should be noted that, in few cases, partial exposure of silicone block was detected, and the reason for this could be inadequate soft tissue coverage, for example, small temporalis fascia. Hence, we believe that the alternative solution to this problem is to utilize long temporalis fascia or even use post-auricular soft tissue as accessory graft material. From another perspective, partial exposure of silicone block can be prevented by sufficiently covering the anterior aspect of the silicone block, using small pieces of cartilage.

The main goal of mastoid obliteration and reconstruction of the EAC in various techniques is to promote healing in the mastoid cavity,

preserve the natural contour of the EAC, and prevent cavity problems. Hence, many studies evaluated the advantages and disadvantages of using different materials in the obliteration of mastoids by considering complications, ease of application, and cost. The average cost for each silicon block is \$ 6.15 USD per patient. In addition, utilizing natural materials, such as bone pate/chips, Palva flap, or a combination of cartilage graft, muscular flap, and amniotic membrane graft was also reported in several studies.^{7,17} Another modification in the use of a posterior canal wall osteoplastic flap in which, the posterior segment of the EAC is temporarily removed and then the segment is reimplanted into its bed with or without further fixation, such as bone cement or using microplate osteosynthesis.¹⁸⁻²² Of note, biological material has a lower chance of infection, but there are some disadvantages, including atrophy, resorption, curvature, difficulty in fashioning, and donor site morbidity. On the other hand, the advantages of synthetic materials include no atrophy or resorption, or donor site morbidity. But the risk of infection and exposure is much higher when utilizing alloplastic materials. In addition, this material might not be readily available in some developing countries.²³

Examples of synthetic materials are bioactive glass (BAG) S53P4, hydroxyapatite, and silicone blocks. Hydroxyapatite (HA) was investigated for mastoid obliteration. Geerse et al investigated 122 ears for mastoid obliterated with HA, and postoperatively reported 98% of the ears were free of cholesteatoma and 93% were dry.⁹ Yanagihara et al in a retrospective study assessed middle ear aeration after total mastoid obliteration, using bone pate and hydroxyapatite, and postoperatively reported no residual cholesteatoma or complication. They concluded that mastoid obliteration is a safe procedure that can facilitate aeration of the tympanic cavity.²⁴ In contrast, Park et al reported a high rate of graft failure (20%) and overall complications (26.7%) in ears obliterated with HA.²⁵ BAG S53P4 is another type of synthetic material for the obliteration of mastoids. Ezzat et al in a retrospective observational study reported that from 40 ears with the CWDM with mastoid obliteration by BAG, 15% of the ears had otorrhea and 10% had cholesteatoma recidivism or recurrence.²⁶ In another study, Mestdagh et al evaluated the use of BAG S53P4 granules for mastoid obliteration. Of the 67 ears, 96% were dry and 6% had cholesteatoma recidivism or recurrence.¹⁰ Silicone is another type of synthetic material, used for mastoid obliteration. Cho et al evaluated the usefulness of silicone blocks as graft material for the obliteration of mastoid cavity to prevent problematic mastoid cavities after CWDM. However, they did not report the condition of the ossicular chain, but they achieved a graft success rate of 95% with significant improvement in ABG and AC. It should be noted that the main difference between our work and Cho et al, study is that they obliterated the epitympanic cavity with piecemeal cartilage, but we believe that the anterior-superior wing of butterfly shape silicone is sufficient for the obliteration of epitympanic cavity. Furthermore, they used fibrin glue for bone pate coverage of the silicone blocks,¹² but we covered the silicone blocks with the anterior-based musculoperiosteal flap by suturing it into its original anatomic position.

To have a better understanding of the advantages and disadvantages of this technique, we compared our findings with our own

two historical control groups from our previous researches, including amniotic membrane and temporalis fascia from 2012 to 2017 in Table 3.⁷ There were no significant differences in audiometric variables, except ABG gain, which was better in both amniotic membrane and temporalis fascia groups in comparison to the silicone block group. In the current study, ABG mean gain had significantly improved after second-stage ossiculoplasty (Table 2). Furthermore, the duration of complete epithelialization of the cavity in the silicone block group was significantly shorter than the amniotic membrane and temporalis fascia groups (Table 3). The graft success rate in the silicone block group was significantly higher, and the incidence of granulation tissue in the silicone block group was comparable to the amniotic membrane group, but it was less than temporalis fascia group (Table 3). There was no report on the recurrence of cholesteatoma in any of the groups during the research period. Since both studies were conducted in the same center and all procedures were performed by the same single surgeon, there is a low risk of bias in this comparison.

A strength of our study was that all procedures were performed by a single surgeon, so the difference in the level of expertise can be excluded. Of note, our study has a limitation, which is its retrospective nature. Hence, we recommend a future randomized clinical trial to compare this method with other routine methods for the obliteration of the mastoid cavity. Moreover, because otomicroscopic examination is not a suitable method for detecting the recurrence of cholesteatoma after the obliteration of the mastoid cavity; hence, second-look surgery or diffusion-weighted MRI is suggested to look for post-operative recurrence or residual cholesteatoma.

5 | CONCLUSION

In brief, the availability and affordability of silicone block suggest its usefulness for mastoid obliteration and external auditory canal reconstruction in the CWDM in patients suffering from extensive chronic otitis media.

ACKNOWLEDGMENTS

The authors wish to thank Mr. H. Argasi at HR Publication for his invaluable assistance in editing this manuscript. The present article was extracted from the thesis presented for obtaining the specialty of otolaryngology degree by Mohammadjavad Erfanzadeh, MD.

CONFLICT OF INTEREST

The authors have no funding, financial relationships, or conflicts of interest to disclose.

AUTHOR CONTRIBUTIONS

Drs Mohammad Faramarzi, Kaboodkhani had full access to all of the data in the study and take responsibility for the integrity of the data and the accuracy of the data analysis. Conceptualization: Mohammad Faramarzi; Methodology: Mohammad Faramarzi, Reza Kaboodkhani, Mohammadjavad

Erfanzadeh; Performing the surgical operations: Mohammad Faramarzi; Formal analysis and investigation: Sareh Roosta; Writing—original draft preparation: Ali Faramarzi, Milad Hosseinalhashemi, Sareh Roosta; Writing—review and editing: Mohammad Faramarzi, Ali Faramarzi, Milad Hosseinalhashemi, Sareh Roosta; Resources: Mohammad Faramarzi, Reza Kaboodkhani, Mohammadjavad Erfanzadeh, Ali Faramarzi, Milad Hosseinalhashemi; Supervision: Mohammad Faramarzi, Reza Kaboodkhani. All authors commented on previous versions of the manuscript. All authors read and approved the final manuscript.

ETHICS APPROVAL

The local Ethics Committee of Shiraz University of Medical Sciences approved the research protocol of this retrospective study (IR.SUMS.MED.REC.1398.294).

INFORMED CONSENT

Informed consent was obtained from all individual participants included in the study.

ORCID

Mohammad Faramarzi  <https://orcid.org/0000-0002-6903-3252>

Reza Kaboodkhani  <https://orcid.org/0000-0002-2754-2884>

Ali Faramarzi  <https://orcid.org/0000-0003-4814-1729>

Sareh Roosta  <https://orcid.org/0000-0002-3927-0812>

Mohammadjavad Erfanzadeh  <https://orcid.org/0000-0002-2180-2745>

Milad Hosseinalhashemi  <https://orcid.org/0000-0002-2761-1317>

BIBLIOGRAPHY

1. Mills RP. Surgical management of the discharging mastoid cavity. *J Laryngol Otol Suppl.* 1988;16:1-6.
2. Youngs R. The histopathology of mastoidectomy cavities, with particular reference to persistent disease leading to chronic otorrhoea. *Clin Otolaryngol Allied Sci.* 1992;17(6):505-510. <https://doi.org/10.1111/j.1365-2273.1992.tb01706.x>
3. Weiss NM, Bächinger D, Botzen J, Großmann W, Mlynski R. Mastoid cavity obliteration leads to a clinically significant improvement in health-related quality of life. *European Archives of Oto-Rhino-Laryngology.* 2020;277(6):1637-1643. <https://doi.org/10.1007/s00405-020-05881-4>
4. Lee HJ, Chao JR, Yeon YK, et al. Canal reconstruction and mastoid obliteration using floating cartilages and musculoperiosteal flaps. *Laryngoscope.* 2017;127(5):1153-1160. <https://doi.org/10.1002/lary.26235>
5. Kaur N, Sharma DK, Singh J. Comparative evaluation of mastoid cavity obliteration by vascularised temporalis myofascial flap and deep temporal fascial-periosteal flap in canal wall down mastoidectomy. *J Clin Diagn Res.* 2016;10(12):MC08-MC11. <https://doi.org/10.7860/JCDR/2016/21490.9121>
6. Alves RD, Cabral Junior F, Fonseca ACO, Bento RF. Mastoid obliteration with autologous bone in mastoidectomy canal wall down surgery: a literature overview. *Int Arch Otorhinolaryngol.* 2016;20(1):76-83. <https://doi.org/10.1055/s-0035-1563382>
7. Faramarzi M, Kaboodkhani R, Roosta S, Azarpira N, Shishegar M, Bahrani-fard H. Application of amniotic membrane for covering mastoid cavity in canal wall down mastoidectomy. *Laryngoscope.* 2019; 129(6):1453-1457. <https://doi.org/10.1002/lary.27638>
8. Komori M, Yanagihara N, Hyodo J, Minoda R, Hinohira Y. Five-year postoperative outcomes of modified staged canal wall up

- tympaanoplasty for primary acquired cholesteatoma. *European Archives of Oto-Rhino-Laryngology*. 2018;275(3):691-698. <https://doi.org/10.1007/s00405-018-4863-1>
9. Geerse S, Bost TJM, Allagul S, de Wolf MJF, Ebbens FA, van Spronsen E. Hearing and hearing rehabilitation after obliteration of troublesome mastoid cavities. *European Archives of Oto-Rhino-Laryngology*. 2020;277(12):3307-3313. <https://doi.org/10.1007/s00405-020-06041-4>
 10. de Veij Mestdagh PD, Colnot DR, Borggreven PA, Orelia CC, Quak JJ. Mastoid obliteration with S53P4 bioactive glass in cholesteatoma surgery. *Acta Oto-Laryngologica*. 2017;137(7):690-694. <https://doi.org/10.1080/00016489.2017.1279346>
 11. Uçar C. Canal wall reconstruction and mastoid obliteration with composite multi-fractured osteoperiosteal flap. *European Archives of Oto-Rhino-Laryngology*. 2006;263(12):1082-1086. <https://doi.org/10.1007/s00405-006-0164-1>
 12. Cho SW, Cho Y-B, Cho H-H. Mastoid obliteration with silicone blocks after canal wall down mastoidectomy. *Clin Exp Otorhinolaryngol*. 2012;5(1):23-27. <https://doi.org/10.3342/ceo.2012.5.1.23>
 13. Haginomori S-I, Nonaka R, Takenaka H, Ueda K. Canal wall-down tympanoplasty with soft-wall reconstruction using the pedicled temporoparietal fascial flap: technique and preliminary results. *Ann Otol Rhinol Laryngol*. 2008;117(10):719-726. <https://doi.org/10.1177/000348940811701002>
 14. Yung M, Smith P. Titanium versus nontitanium ossicular prostheses—a randomized controlled study of the medium-term outcome. *Otology & Neurotology*. 2010;31(5):752-758. <https://doi.org/10.1097/mao.0b013e3181de4937>
 15. Wiet RJ, Wiet RM. Experience-driven ossiculoplasty. *Operative Techniques in Otolaryngology-Head and Neck Surgery*. 2010;21(3):211-216. <https://doi.org/10.1016/j.otot.2010.05.001>
 16. Faramarzi M, Tale M, Khosravaniardakani S, Roosta S, Faramarzi A. Comparison of titanium versus polycyl as partial ossicular replacement prosthesis: a randomized clinical trial. *Iran J Otorhinolaryngol*. 2021;33(3):143-149. <https://doi.org/10.22038/ijorl.2021.52321.2775>
 17. Ghiasi S. Mastoid cavity obliteration with combined palva flap and bone pâté. *Iran J Otorhinolaryngol*. 2015;27(78):23-28.
 18. Van der Gucht K, Van Rompaey V, Vanderveken O, Van de Heyning P, Claes J. Temporary removal of the posterior bony canal wall with reconstruction using microplate osteosynthesis in cholesteatoma surgery: a case series and description of the technique. *European Archives of Oto-Rhino-Laryngology*. 2013. <https://doi.org/10.1007/s00405-013-2601-2>
 19. Feldmann H. Osteoplastic approach in chronic otitis media by means of a microsurgical reciprocating saw. *Clin Otolaryngol Allied Sci*. 1978; 3(4):515-520. <https://doi.org/10.1111/j.1365-2273.1978.tb00744.x>
 20. Lapidot A, Brandow EC. A method for preserving the posterior canal wall and bridge in the surgery for cholesteatoma: Preliminary report. *Acta Oto-Laryngologica*. 1966;62(1-6):88-92. <https://doi.org/10.3109/00016486609119553>
 21. McElveen JTJ, Chung ATA. Reversible canal wall down mastoidectomy for acquired cholesteatomas: preliminary results. *Laryngoscope*. 2003;113(6): 1027-1033. <https://doi.org/10.1097/00005537-200306000-00020>
 22. Schnee IM. Tympanoplasty: a modification in technique. *Arch Otolaryngol*. 1963;77:87-91. <https://doi.org/10.1001/archotol.1963.00750010091014>
 23. Ridenour JS, Poe DS, Roberson DW. Complications with hydroxyapatite cement in mastoid cavity obliteration. *Otolaryngology-Head and Neck Surgery*. 2008;139(5):641-645. <https://doi.org/10.1016/j.otohns.2008.07.020>
 24. Yanagihara N, Komori M, Hinohira Y. Total mastoid obliteration in staged canal-up tympanoplasty for cholesteatoma facilitates tympanic aeration. *Otol Neurotol Off Publ Am Otol Soc Am Neurotol Soc [and] Eur Acad Otol Neurotol*. 2009;30(6):766-770. <https://doi.org/10.1097/MAO.0b013e3181b23698>
 25. Result of Mastoid Obliteration According to the Graft Materials: Autogenous Bone, Allogeneic Bone, Hydroxylapatite. <https://www.advancedotology.org/en/result-of-mastoid-obliteration-according-to-the-graft-materials-autogenous-bone-allogeneic-bone-hydroxylapatite-13580>. Accessed 27 Dec 2020.
 26. Ezzat AEM, Eid MI. Evaluation of using Bioglass® in obliteration of mastoid cavity. *Curr Sci Int*. 2014;3(2):87-94.

SUPPORTING INFORMATION

Additional supporting information may be found in the online version of the article at the publisher's website.

How to cite this article: Faramarzi M, Kaboodkhani R, Faramarzi A, Roosta S, Erfanzadeh M, Hosseinalhashemi M. Mastoid obliteration and external auditory canal reconstruction with silicone block in canal wall down mastoidectomy. *Laryngoscope Investigative Otolaryngology*. 2021;6(5):1188-1195. doi:10.1002/lio2.672