


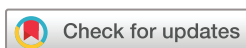Thrombotic and immunological phenomena following COVID-19 vaccination: experience from a case series

Chathurika Lakmini Dandeniya ¹, Theekshana Kavinda Premathilake²

To cite: Dandeniya CL, Premathilake TK. Thrombotic and immunological phenomena following COVID-19 vaccination: experience from a case series. *RMD Open* 2023;**9**:e002841. doi:10.1136/rmdopen-2022-002841

► Additional supplemental material is published online only. To view, please visit the journal online (<http://dx.doi.org/10.1136/rmdopen-2022-002841>).

Accepted 31 January 2023



© Author(s) (or their employer(s)) 2023. Re-use permitted under CC BY-NC. No commercial re-use. See rights and permissions. Published by BMJ.

¹Senior Lecturer and Consultant Rheumatologist, Department of Medicine, Faculty of Medicine, University of Peradeniya, Peradeniya, Sri Lanka

²Temporary Lecturer, Department of Medicine, University of Peradeniya, Peradeniya, Sri Lanka

Correspondence to

Dr Chathurika Lakmini Dandeniya;
chathurika.dandeniya@med.pdn.ac.lk

Vaccination has undoubtedly reduced COVID-19-related mortality globally.¹ However, being a new vaccine with limited clinical trial experience, postmarketing data are important to establish safety and side effect profile. Thrombotic and autoimmune phenomena have been reported globally following vaccination.² A multi-centre study in Sri Lanka failed to identify any significant adverse events following AZD1222 (ChAdOx1) first dose in Sri Lanka.³ However, we present our experience with a case series identifying serious thrombotic and autoimmune complications following different types of COVID-19 vaccination in Sri Lanka.

We collected data from patients who presented to Teaching Hospital Peradeniya with thrombotic and/or immunological phenomena following COVID-19 vaccination from September 2021 to March 2022. Being a tertiary care hospital affiliated to a national university, the referred patients were from across the country. A causal relationship was assumed in patients in whom the symptoms appeared within 6 weeks of vaccination, without similar symptoms preceding the vaccination. Active COVID-19 infection was excluded in all patients with thrombotic complications and in all patients requiring hospital admission due to other symptoms. In patients presenting to outpatient rheumatology services, five had tested negative for COVID-19 infection around the time of symptom onset while the others did not display symptoms of infection around this time prompting testing according to national policy.

Of a total of 24 patients with their age ranging from 19 to 78 years, 18 were females. All had received at least one of the five types of COVID-19 vaccine used in

Sri Lanka at the time (BNT162b2, mRNA-1273, BBIBP-CorV, Gam-COVID-Vac and AZD1222 (ChAdOx1)) while four had received cross-vaccination. Eight patients (33.3%) mentioned stepwise progression of symptoms with booster doses. One patient died while the remaining 23 patients recovered with varying degrees of disability. Details of patients are presented in [table 1](#). Further details of all clinical cases can be accessed in online supplemental table 1.

The first patient with digital thrombosis was managed with apixaban and intravenous prostacyclin. However, the thrombosis progressed and later she developed thromboembolic pulmonary hypertension despite being on apixaban. Occult malignancy was considered but excluded. She succumbed to severe right heart failure 6 months later. Subsequent patients with digital thrombosis were tried on bosentan which was effective with rapid halt of progression of ischaemia and pain relief. All patients with inflammatory arthritis needed disease-modifying antirheumatic drugs due to failure of inducing sustained remission with steroids and non-steroidal anti-inflammatory drugs. All patients with immunological phenomena needed varying regimens of immunosuppression. Only two achieved complete remission with a short course of steroids while all others needed longer courses of immunosuppression.

Despite being rare, COVID-19 vaccination can be associated with unusual autoimmune and thrombotic phenomena which may intensify with repeated vaccination. For thrombotic complications, prostacyclin is of dubious efficacy while bosentan is effective. The majority needed sustained strong immunosuppression customised to the individual patient.

Table 1 The observed clinical phenomena and outcomes

Clinical syndrome	Patients (n)	Treatment	Outcome
Distal digital thrombosis	3	Prostacyclin in one case. Bosentan in other cases. Oral prednisolone in all patients with 3 months of anticoagulation.	Prostacyclin was ineffective for halting progress of ischaemia while bosentan was very effective. The one on prostacyclin later developed thromboembolic pulmonary hypertension despite apixaban and died from complications.
Cerebral vasculitis: imbalance and cognitive deficit	2	Intravenous methylprednisolone in both. Intravenous immunoglobulin induction with azathioprine maintenance in one patient and intravenous cyclophosphamide induction with MMF maintenance in the other.	Full recovery to baseline with no new lesions on follow-up MRI.
De novo inflammatory arthritis: seropositive rheumatoid arthritis (n=2), peripheral spondyloarthritis (n=6)	8	All patients relapsed on stopping initial prednisolone or NSAIDs with persistent symptoms beyond 3 months, needing DMARDs.	All achieved remission.
Worsening of previously diagnosed autoimmune rheumatological conditions: SLE (n=2), rheumatoid arthritis (n=2), peripheral spondyloarthritis (n=1)	5	4 out of 5 were in long-term remission with good drug compliance. One patient with SLE had active disease with intermittent flares but in remission for 7 months preceding vaccination. All patients needed escalation of immunosuppression.	All achieved remission.
Cutaneous vasculitis with inflammatory oligoarthritis (positive ANA)	1	Leflunomide (intolerance of methotrexate).	Achieved remission.
Isolated cutaneous vasculitis	1	Prolonged course of tapering prednisolone 0.5 mg/kg/day.	Achieved remission.
Severe autoimmune haemolytic anaemia with positive ANA	1	Intravenous methylprednisolone effective but relapse on oral prednisolone. Remission induction with rituximab. Maintenance with hydroxychloroquine.	Achieved remission.
Unusual cognitive symptoms with positive ANA: dissociation and paraesthesia	1	Moderate-dose prednisolone tapered over 3 weeks.	Achieved remission without sequela.
RS3PO-like picture	1	Prednisolone, methotrexate, leflunomide.	Unable to completely stop steroids. Remission with 2 DMARDs and prednisolone 5 mg every other day.
Complex picture of digital ischaemia, cutaneous vasculitis and mucosal ulceration	1	Prednisolone, warfarin, bosentan.	CMV serology negative. Digital ischaemia stopped progression rapidly with bosentan. Remission with cessation of all medications after 1 year of treatment. Lost 4 digits.

ANA, antinuclear antibody; CMV, cytomegalovirus; DMARDs, disease-modifying antirheumatic drugs; MMF, mycophenolate mofetil; NSAIDs, non-steroidal anti-inflammatory drugs; RS3PO, remitting seronegative symmetrical synovitis with pitting oedema; SLE, systemic lupus erythematosus.

The findings of this observational study have to be interpreted within the limitations of the inability to completely rule out asymptomatic COVID-19 infection as a potential cause in all the cases (done in some cases only), inability to rule out preceding undiagnosed autoimmune disease or occult malignancy, consideration of the contribution from comorbidities and the possibility of natural flares of baseline rheumatological disease.

Acknowledgements The authors gratefully acknowledge the patients and their families for kindly consenting for their data to be collected and shared with the scientific community, and the staff of Teaching Hospital Peradeniya, Sri Lanka, including the vascular surgical team for their unwavering support in the diagnosis and management of these patients.

Contributors CLD is the first author. She diagnosed and managed all the patients in the case series and collected the data with patient consent. She read, edited and approved the final manuscript. TKP helped in arranging the follow-up of patients, completing data and writing the draft version of the manuscript.

Funding The authors have not declared a specific grant for this research from any funding agency in the public, commercial or not-for-profit sectors.

Competing interests None declared.

Patient consent for publication Obtained.

Ethics approval This study involves human participants but this is a case series instead of a planned and executed study. Data were collected from patients with their written consent as and when they presented with these unusual and rare manifestations. Therefore, ethics approval was not sought prior to starting data collection and it was not practically possible. Participants gave informed consent to participate in the study before taking part.

Provenance and peer review Not commissioned; externally peer reviewed.

Supplemental material This content has been supplied by the author(s). It has not been vetted by BMJ Publishing Group Limited (BMJ) and may not have been peer-reviewed. Any opinions or recommendations discussed are solely those of the author(s) and are not endorsed by BMJ. BMJ disclaims all liability and responsibility arising from any reliance placed on the content. Where the content includes any translated material, BMJ does not warrant the accuracy and reliability of the translations (including but not limited to local regulations, clinical guidelines, terminology, drug names and drug dosages), and is not responsible for any error and/or omissions arising from translation and adaptation or otherwise.

Open access This is an open access article distributed in accordance with the Creative Commons Attribution Non Commercial (CC BY-NC 4.0) license, which permits others to distribute, remix, adapt, build upon this work non-commercially, and license their derivative works on different terms, provided the original work is properly cited, appropriate credit is given, any changes made indicated, and the use is non-commercial. See: <http://creativecommons.org/licenses/by-nc/4.0/>.

ORCID iD

Chathurika Lakmini Dandeniya <http://orcid.org/0000-0001-8857-1366>

REFERENCES

- 1 Suthar AB, Wang J, Seffren V, *et al*. Public health impact of covid-19 vaccines in the US: observational study. *BMJ* 2022;377:e069317.
- 2 Elrashdy F, Tambuwala MM, Hassan SS, *et al*. Autoimmunity roots of the thrombotic events after COVID-19 vaccination. *Autoimmun Rev* 2021;20:102941.
- 3 Manilgama SR, Hettiarachchi NM, Jayasinghe KI, *et al*. Prevalence of covishield COVID-19 vaccine (chadox1 ncov-19) adverse effects among health care workers in sri lanka. *Int J Infect Dis* 2022;116:S61.