

Submitted:
13.10.2022
Accepted:
31.01.2023
Published:
28.04.2023

The usefulness of transabdominal ultrasound elastography in *Helicobacter pylori* gastritis in children

Ulas Emre Akbulut¹, Ishak Abdurrahman Isik¹, Atike Atalay¹, Mehmet Burak Özkan²

¹ University of Health Sciences, Antalya Education and Research Hospital, Department of Pediatric Gastroenterology, Hepatology and Nutrition, University of Health Sciences, Antalya Education and Research Hospital, Antalya, Turkey

² Department of Pediatric Radiology, University of Health Sciences, Antalya Education and Research Hospital, Antalya, Turkey

Corresponding author: Ulas Emre Akbulut; e-mail: ulasemre@hotmail.com

DOI: 10.15557/JoU.2023.0012

Keywords

children;
endoscopy;
ultrasound elastography;
Helicobacter pylori

Abstract

Background: *Helicobacter pylori* can colonize the submucosal layer as well as the mucosa in the stomach. Inflammation and erosions cause both mucosal and submucosal thickening in patients with *Helicobacter pylori* gastritis. Elastography is a method for measuring the elasticity and hardness of tissues by visualization of their response to the applied force. Hard tissues respond to applied compression differently compared to soft tissues. Hard tissues displace as a whole without deforming as opposed to soft tissues. In this study, we investigated the diagnostic performance of transabdominal ultrasound elastography in detecting *Helicobacter pylori* gastritis in children. **Methods:** Nineteen children (group 1) with *Helicobacter pylori* gastritis, 33 children (group 2) with *Helicobacter pylori* (-) gastritis and 37 healthy children (group 3) were included the study. These groups were compared in terms of their strain index values. Ultrasonographic examinations were performed with a single transducer at 1.8–6.2 MHz frequency range. **Results:** Both group 1 and 2 had significantly higher strain index values compared to the control group (2.7, 2.2 and 1.4 respectively). Additionally, the mean strain index value was significantly higher in group 1 compared to group 2. **Conclusion:** Transabdominal ultrasound elastography has diagnostic value in differentiating *Helicobacter pylori* (+) gastritis from *Helicobacter pylori* (-) gastritis as well as in the diagnosis of gastritis in children.

Introduction

Helicobacter pylori (*H. pylori*) infection is very common, affecting about 50% of the worldwide population⁽¹⁾. In developed countries, low prevalence of *H. pylori* has been observed among children. Nevertheless, infection rates are still high in some regions due to low socioeconomic status and poor health conditions⁽²⁾. *H. pylori* infection has a different clinical course in children from that in adults. Studies conducted in different centers found no difference in the symptoms presented by children with *H. pylori* (+) and *H. pylori* (-) dyspepsia^(3–7). Therefore, new methods have been developed to detect *H. pylori* infection over time. Positive tissue culture or rapid urease test with positive histology is the gold diagnostic standard⁽²⁾. However, endoscopy, which is an invasive procedure, is needed to obtain these results.

Helicobacter pylori can colonize the submucosal layer as well as the mucosa in the stomach. Inflammation and erosions cause both mucosal and submucosal thickening in patients with *H. pylori* gastritis. As a result of studies based on this data it was documented that patients with *H. pylori* infection presented with gastric wall thickening detectable by ultrasonography⁽⁸⁾.

Elastography is a method for visualization of elasticity and hardness of tissues by evaluating their response to an applied force⁽⁹⁾. Hard tissues respond differently to compression compared to soft tissues. Hard tissues displace as a whole without deforming as opposed to soft tissues. For this reason, hard tissues have strain values lower than those of soft tissues⁽¹⁰⁾. Strain index is calculated by dividing the strain value of the tissue by that of the surrounding structure. As expected, less compressible and less deformable hard tissues have higher strain index values. Strain elastography, an inexpensive and

non-invasive new visualization method increases the usefulness of ultrasonography in different situations^(11–15).

Inflammation and erosion caused by *H. pylori* infection can alter gastric wall elasticity. An analysis of these changes using transabdominal ultrasound elastography (US-EG) may provide clinical benefits. In this study, we have assessed the diagnostic performance of transabdominal US-EG in children with *H. pylori* gastritis.

Methods

Study design and patients

Between March 2020 and January 2021, 19 children (group 1) with *H. pylori* (+) gastritis detected by endoscopy in our pediatric gastroenterology clinic serving as a tertiary center, and 33 children (group 2) with *H. pylori* (-) gastritis were included the study. In addition, 37 age and sex-matched healthy children (group 3) without any complaints were included as the control group. Children with previously known diseases thought to affect the intestinal wall (celiac disease, inflammatory bowel disease) or hepatitis were excluded. The study was conducted after obtaining the approval of the local ethics committee in accordance with the Declaration of Helsinki (decision no: 2020-12/9). Written informed consent was obtained from all patients and healthy controls as well as their parents before inclusion in the study.

All endoscopic investigations were performed by a pediatric endoscopists (U.E.A., I.A.I. and A.A.) in the endoscopy unit, using the EG-530WR (Fuji Film, Tokyo, Japan). Peptic ulcer and erosion observed during endoscopy were defined as gross pathological findings. Decreased or increased vascularity or hyperemia were defined as nonspecific findings and not considered pathological⁽¹⁶⁾. Two biopsies were taken from the corpus and antrum and put in a container filled with 10% formalin and sent to the pathology department. All examinations were performed by experienced pathologists blinded to patient’s clinical and endoscopic findings. The specimens were hematoxylin and eosin-stained. The Sidney Scoring System was used to evaluate the histopathological findings⁽¹⁷⁾. The severity of the inflammation was determined as mild, moderate, or severe, depending on the intensity of plasma cells and lymphocytes in the lamina propria. Mild inflammation was not considered pathological. Positive rapid urease test and detection of *H. pylori* at gastric biopsy were defined as *H. pylori* infection.

Strain elastography

Ultrasonographic examinations were performed with the Hitachi ultrasound system with a single transducer at 1.8–6.2 MHz frequency range. All ultrasonographic examinations were performed by the same pediatric radiologist blinded to the patients’ clinical information, including 2-D examinations. All examinations were performed by a radiologist with more than ten years of experience in pediatric ultrasonography. All examinations were performed after eight-hour fasting, in the supine position. Five strain measurements were obtained from the stomach wall, via a subxiphoid approach during suspended respiration.

A 2 cm × 2 cm strain color map (elastogram) and a 0.5 cm manually placed round region of interest (ROI) were used. The ROI was

placed in areas of optimal color fill. The depth of measurement was calculated automatically by the ultrasound device.

A single pediatric radiologist (M.B.O) experienced in US-EG reviewed all measurements, and good-quality strain measurements were recorded for further analysis.

Statistical analysis

Data are presented as means, standard deviations, or ranges as appropriate. For comparison between two groups, Student’s t-test was used for variables exhibiting normal distribution, and the Mann-Whitney U-test for those not distributed normally. In the case of more than two groups, the ANOVA test was used for variables exhibiting normal distribution, and the Kruskal-Wallis test for those not exhibiting normal distribution. The chi-square test was used to compare categorical variables. P-values less than 0.05 were considered statistically significant. The data were evaluated with SPSS 18.0 (SPSS Inc. Chicago, IL, USA) statistical software.

Univariate regression analysis and multivariate regression analysis were used to analyze factors related to the strain index as determined by US-EG. These analyzes were performed to evaluate relationships between the strain index and factors that may have influenced *H. pylori* gastritis: age (≥12 years old), gender and body mass index (≥85th percentile). Areas under receiver operating characteristic curves (AUROCs) were determined for the strain index as determined by US-EG for *H. pylori* gastritis diagnostic ability. The optimal cut-off values were determined from AUROC curve analysis and the Youden J index and its associated criterion values were chosen.

Results

A total of 35 (39.3%) patients were males, their age and weight were between 8–18 years (median 14 years) and 22–74 kg (median 47 kg), respectively. The groups were statistically similar in terms of age, gender, and weight (Tab. 1).

The mean strain index values were 2.7 in *H. pylori* (+) gastritis group (group 1), 2.2 in *H. pylori* (-) gastritis group (group 2), and 1.4 in the control group (Fig. 1). Both group 1 and group 2 had significantly higher strain index values compared to the control group. Addition-

Tab. 1. Comparison of demographic findings and anthropometric measurements in the groups

	Group 1 (n = 19)	Group 2 (n = 33)	Group 3 (n = 37)	p value	
Age, years	13.8 ± 3.0	13.6 ± 2.7	12.5 ± 2.9	0.166	
Gender, n (%)	Male	6 (31.6)	14 (42.4)	15 (40.5)	0.728
	Female	13 (68.4)	19 (57.6)	22 (59.5)	
Weight, kg	50.6 ± 16.8	49.6 ± 14.5	42.8 ± 15.7	0.101	
Body mass index, kg/m ²	21.1 ± 2.4	20.5 ± 2.0	19.4 ± 2.3	0.215	
Values are expressed as mean ± standard deviation or number (%) Calculated for the comparisons between the three groups by using ANOVA for continuous variables. p-value, compared with control, group 1 and group 2					

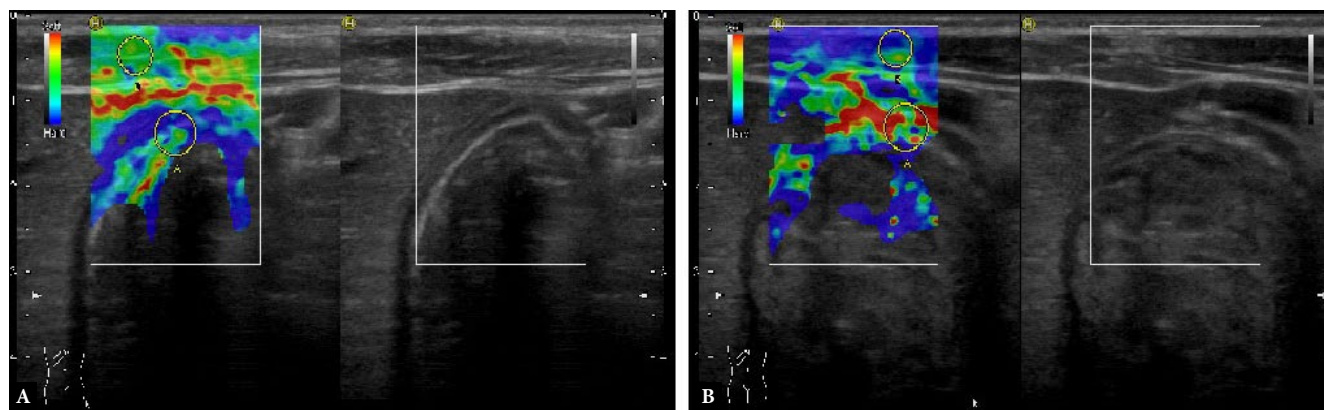


Fig. 1. A. A seven year-old boy suffering from *H. pylori* infection underwent strain elastography examination. The strain values obtained from the thickened gastric wall were compared with the stomach surface of the neighboring muscle tissue which was accepted normal. B. Strain value measurement in a healthy 5-year-old volunteer boy. After clinical examination, the patient's gastric wall was scanned using B-mode sonography and after no thickening has been shown, the color map was obtained and the region of interest was measured. The value was 0.24, which corresponded to normal limits in the healthy volunteer group

ally, group 1 had a significantly higher mean strain index value than group 2 (Fig. 2).

Strain index determined by US-EG was not correlated with body mass index, gender or age (Tab. 2). AUC was calculated to evaluate its utility in diagnosing gastritis using the strain index determined by US-EG. A value of 0.873 was determined as a good AUC. When a 1.6 cut-off point was taken, its sensitivity in diagnosing gastritis was 90.4%, its specificity was 65%, and its accuracy was 73.9% (Fig. 3). In addition, the ability of strain index to diagnose *H. pylori* gastritis among gastritis patients was also calculated. AUC was estimated at 0.720. When a cut off value of 2.0 was taken, the diagnostic sensitivity, specificity and accuracy were 84.2%, 54.5 and 68.1%, respectively (Fig. 4).

Discussion

In this study, we investigated the benefits of transabdominal US-EG using strain index in the diagnosis of gastritis in children. Our findings revealed significantly higher mean strain index in children with gastritis compared to healthy controls. In addition, the strain index was also significantly higher in children with *H. pylori* (+) gastritis than those with *H. pylori* (-) gastritis. In conclusion, transabdominal US-EG is a fast, reliable and non-invasive method that can be applied to detect gastritis in children with and without *H. pylori* infection.

The North American Society for Pediatric Gastroenterology, Hepatology and Nutrition (NASPGHAN) and the European Society for Pediatric Gastroenterology Hepatology and Nutrition (ESPGHAN) recommend the use of biopsy-based testing based on positive culture or

histopathology for the initial diagnosis of *H. pylori* gastritis⁽³⁾. However, endoscopy is a relatively expensive and invasive procedure and is not practical in a clinical setting. In addition, side effects can be seen due to sedation used during the procedure. Some other diagnostic methods are used to determine the presence of *H. pylori* infection. Repeat testing after treatment is also important to confirm *H. pylori* eradication.

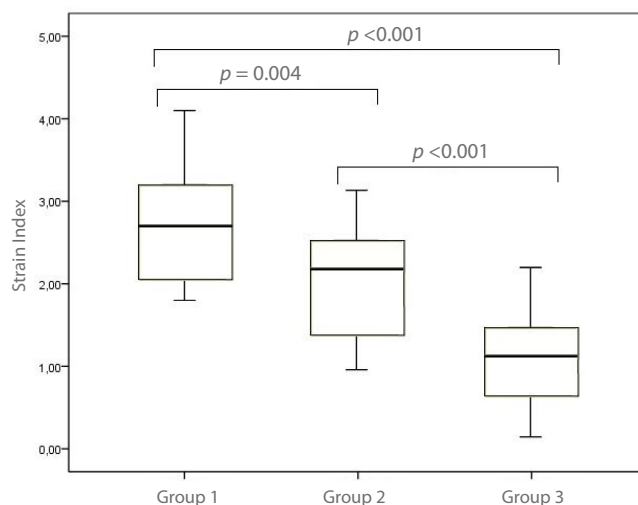


Fig. 2. Comparison of the strain index by transabdominal ultrasound elastography in the groups. The strain index values in *H. pylori* gastritis, non *H. pylori* gastritis and control groups were 2.7 (1.8–4.1), 2.2 (1.3–3.2) and 1.4 (0.4–2.4), respectively

Tab. 2. Univariate and multivariate analyses of factors related to SI by US-EG

	Median SI by US-EG		Univariate		Multivariate	
			OR (95% CI)	p value	OR (95% CI)	p value
Age (<12: ≥12, 35:54)	1.9	2.1	1.325 (0.363–2.846)	0,390	1.479(0.591–1.437)	0.541
Gender (M:F, 35:54)	2.0	1.9	1.021 (0.764–1.482)	0.649	1.039 (0.351–1.971)	0.713
BMI (≤85th percentile: ≥85th percentile, 67:22)	2.1	2.0	1.879 (0.526–2.135)	0.435	1.504 (0.434–1.628)	0.616

OR – odds ratio; SI – strain index; US-EG – ultrasound elastography; BMI – body mass index

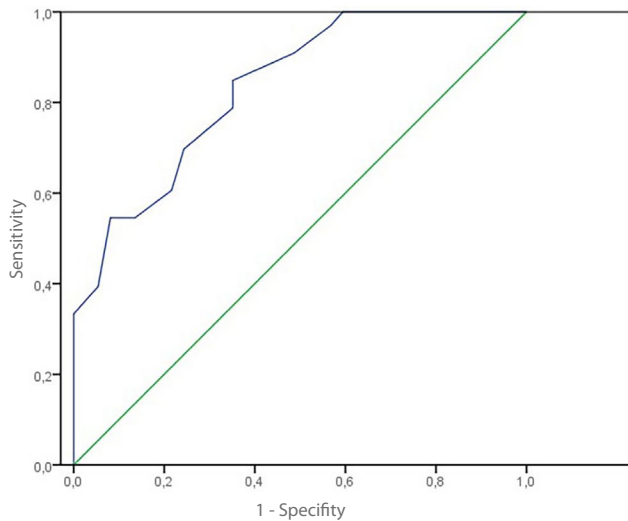


Fig. 3. Diagnosis of gastritis using the strain index as determined by transabdominal ultrasound elastography

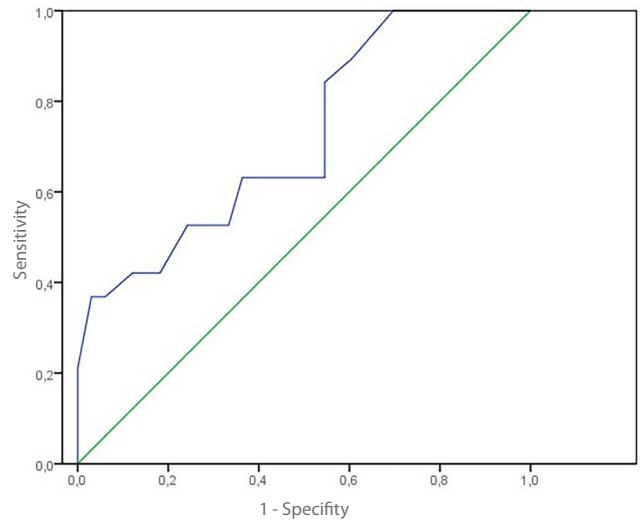


Fig. 4. Diagnosis of *H. pylori* gastritis using the strain index as determined by transabdominal ultrasound elastography in patients with gastritis

Tests may be done using a stool sample, through a breath test and by an upper endoscopy exam. Stool antigen test is the most common stool test to detect *H. pylori*. It screens for proteins (antigens) associated with *H. pylori* infection in the stool. Stool polymerase chain reaction (PCR) can be used to detect *H. pylori* infection in stool. The test can also identify mutations that may be resistant to antibiotics used to treat *H. pylori*. However, this test is more expensive than a stool antigen test and may not be available at all medical centers. During a breath test, known as the urea breath test, a pill, liquid or pudding containing tagged carbon molecules is ingested. In the case of *H. pylori* infection, carbon is released when the solution comes in contact with *H. pylori* in the stomach. Because the body absorbs the carbon, it is released when the patient breathes out. The patient exhales into a special bag to measure the release of carbon. A special device detects carbon molecules. This test can be used for adults and cooperative children over 6 years old. Ultrasonography is a fast, inexpensive and non-invasive imaging method used for abdominal examination. A complete elastography examination can be done within a few minutes after ultrasonography. US-EG differs from other anatomical imaging techniques because tissue contrast is achieved through differences in mechanical stiffness. Differences in the elastic properties of pathological vs normal tissues constitute the basis of the elastographic approach, especially for the detection of malignant lesions. Strain index is a semi-quantitative parameter used in clinical practice for both focal breast and thyroid pathologies. However, elastography is also suitable for evaluating the general elasticity of tissue and can therefore be used for imaging gastrointestinal diseases. In animal studies, it has been shown that intestinal wall stiffness can be accurately measured by strain elastography⁽¹⁸⁾. After surgical resection in mice with stricture due to Crohn's disease, a correlation was found between direct measurement of intestinal wall stiffness and elastography values⁽¹⁹⁾. Human studies also show that the involved parts of the intestine have a higher strain than normal ones in both elastography and direct measurements⁽²⁰⁻²²⁾. Strain index has given very good results, especially in fibrosis^(23,24). However, the inability to fully visualize the small intestines and their peristaltic movements make elastography difficult. The stomach is a more superficially located organ compared to the intestines and has less peristaltic movements, so it can be viewed more easily. In addition, the stomach wall thickness is greater than the small intestine wall thickness.

Before spreading to other parts of the stomach, *H. pylori* first involves the antrum⁽²⁵⁾. *H. pylori* colonizes the deep layers of mucosa and submucosa and causes chronic gastritis and mucosal atrophy. Chronic inflammation and hyperacidity also spread to the muscularis mucosa and cause thickening of this layer^(26,27). It has been shown that there is typically transmural gastric wall thickening in gastritis, which improves with appropriate treatment. In addition, more thickening has been detected in the antral wall and mucosal layer in patients with *H. pylori* gastritis vs *H. pylori* (-) gastritis⁽⁸⁾. In our study, based on changes in gastric wall elasticity, the diagnostic sensitivity and accuracy of transabdominal US-EG in gastritis using the strain index was 90.4% and 65.0%, respectively. In addition, sensitivity and accuracy in differentiating *H. pylori* (+) gastritis from *H. pylori* (-) gastritis were 84.2% and 54.5%, respectively. These results show that elastography, which only takes a few minutes, is a convenient and reliable method.

There is no other study investigating the efficacy of transabdominal US-EG for *H. pylori* gastritis either in children or in adults. For this reason, our study is original and unique. The main strongest aspect of the study is that it provides direct comparison between US-EG and histopathological findings in patients with gastritis. In our study, we determined some criteria to define the reference standard. Pre-selected criteria are very important in determining the reference standard as an incorrect or incomplete reference standard will significantly affect diagnostic accuracy. In our study, strain rate values were obtained for the first time by calculating the ratio between the tension of the tissue surrounding the stomach and the gastric wall.

There are two major limitations of the study. There was a relatively small number of patients and the study was limited to the pediatric population. Further studies with larger sample size are needed to enhance the accuracy of the cut-off value of strain ratio in the diagnosis of *H. pylori* (+) and (-) gastritis. Second, US-EG is an operator-dependent process and therefore may be affected by the experience of the person performing it. In our study, elastography was performed by a pediatric radiologist with more than 10 years of experience.

Conclusion

In conclusion, our study has shown that transabdominal US-EG has diagnostic value in detecting gastritis and differentiating *H. pylori* (+) gastritis from *H. pylori* (-) gastritis in children. US-EG is a non-invasive, real-time, inexpensive and well-tolerated technique. It may have diagnostic significance in pediatric patients with gastritis and prevent unnecessary interventions. However, the data from this study can serve as baseline information. New studies in larger patient groups should be performed to assess the efficacy of US-EG in detecting *H. pylori* gastritis.

Conflict of interest

The authors do not report any financial or personal connections with other persons or organizations which might negatively affect the contents of this publication and/or claim authorship rights to this publication.

Author contributions

Original concept of study: UEA. Writing of manuscript: UEA, IAI, MBO. Analysis and interpretation of data: UEA, AA, MBO. Final acceptance of manuscript: UEA. Collection, recording and/or compilation of data: UEA, IAI, AA, MBO. Critical review of manuscript: IAI, AA, MBO.

References

- Hooi JKY, Lai WY, Ng WK, Ng WK, Suen MMY, Underwood FE *et al.*: Global prevalence of *Helicobacter pylori* infection: systematic review and meta-analysis. *Gastroenterology* 2017; 153(2): 420–429. doi: 10.1053/j.gastro.2017.04.022.
- Miśak Z, Hojsak I, Homan M: Review: *Helicobacter pylori* in pediatrics. *Helicobacter* 2019; 24 Suppl 1: e12639. doi: 10.1111/hel.12639.
- Jones NL, Koletzko S, Goodman K, Bontems P, Cadranel S, Casswall T *et al.*: Joint ESPGHAN/NASPGHAN Guidelines for the management of *Helicobacter pylori* in children and adolescents (update 2016). *J Pediatr Gastroenterol Nutr* 2017; 64(6): 991–1003. doi: 10.1097/mpg.0000000000001594.
- Ünlüsoy Aksu A, Yılmaz G, Eğritaş Gürkan Ö, Sari S, Dalgıç B: The effect of *Helicobacter pylori* eradication on functional dyspepsia in Turkish children. *Helicobacter* 2018; 23(4): e12497. doi: 10.1111/hel.12497.
- Szafarska-Poplawska A, Soroczyńska-Wrzeszcz A: Prevalence of *Helicobacter pylori* infection among junior high school students in Grudziadz, Poland. *Helicobacter* 2019; 24(1): e12552. doi: 10.1111/hel.12552.
- Aguilar-Luis MA, Palacios-Cuervo F, Espinal-Reyes F, Calderón-Rivera A, Levy-Blitchein S, Palomares-Reyes C *et al.*: Highly clarithromycin-resistant *Helicobacter pylori* infection in asymptomatic children from a rural community of Cajamarca-Peru. *BMC Res Notes* 2018; 11(1): 809. doi: 10.1186/s13104-018-3919-z.
- Chobot A, Porębska J, Krzywicka A, Żabka A, Bąk-Drabik K, Pieniżek W *et al.*: No association between *Helicobacter pylori* infection and gastrointestinal complaints in a large cohort of symptomatic children. *Acta Paediatr* 2019; 108(8): 1535–1540. doi: 10.1111/apa.14721.
- Cakmakci E, Ucan B, Colak B, Cinar HG: Novel sonographic clues for diagnosis of antral gastritis and *Helicobacter pylori* infection: a clinical study. *J Ultrasound Med* 2014; 33(9): 1605–1610. doi: 10.7863/ultra.33.9.1605.
- Arslan H, Akdemir Z, Yavuz A, Gökçal F, Parlakgümüş C, İslamoglu N *et al.*: Efficacy of strain elastography in diagnosis and staging of acute appendicitis in pediatric patients. *Med Sci Monit* 2018; 24: 855–862. doi: 10.12659/msm.905927.
- Kapoor A, Kapoor A, Mahajan G: Real-time elastography in acute appendicitis. *J Ultrasound Med* 2010; 29(6): 871–877. doi: 10.7863/jum.2010.29.6.871.
- Suhara H, Hirooka Y, Kawashima H, Ohno E, Ishikawa T, Nakamura M *et al.*: Transabdominal ultrasound elastography of the esophagogastric junction predicts reflux esophagitis. *J Med Ultrason* 2019; 46(1): 99–104. doi: 10.1007/s10396-018-0890-1.
- Nakamura K, Shiina T, Sakurai M, Anokido K, Endo T, Tsunoda H *et al.*: JSUM ultrasound elastography practice guidelines: breast. *J Med Ultrasonics* 2013; 40: 359–391. doi: 10.1007/s10396-013-0457-0.
- Lyshchik A, Higashi T, Asato R, Tanaka S, Ito J, Mai JJ *et al.*: Thyroid gland tumor diagnosis at US elastography. *Radiology* 2005; 237: 202–211. doi: 10.1148/radiol.2363041248.
- Kudo M, Shiina T, Moriyasu F, Iijima H, Tateshi R, Yada N *et al.*: JSUM ultrasound elastography practice guidelines: liver. *J Med Ultrasonics* 2013; 40: 325–357. doi: 10.1007/s10396-013-0460-5.
- Uchida H, Hirooka Y, Itoh Y, Kawashima H, Hara K, Nonogaki K *et al.*: Feasibility of tissue elastography using transcutaneous ultrasonography for the diagnosis of pancreatic diseases. *Pancreas* 2009; 38: 17–22. doi: 10.1097/mpa.0b013e318184db78.
- Akbulut UE, Emeksiz HC, Kocak FG, Livaoglu A: Diagnostic yield of esophago-gastroduodenoscopy in children with chronic abdominal pain. *Arch Med Sci* 2018; 14(1): 74–80. doi: 10.5114/aoms.2017.67675.
- Dixon MF, Genta RM, Yardley JH, Correa P: Classification and grading of gastritis. The updated Sydney System. International Workshop on the Histopathology of Gastritis, Houston 1994. *Am J Surg Pathol* 1996; 20: 1161–1181. doi: 10.1097/00000478-199610000-00001.
- Kim K, Johnson LA, Jia C, Joyce JC, Rangwalla S, Higgins PDR *et al.*: Noninvasive ultrasound elasticity imaging (UEI) of Crohn's disease: animal model. *Ultrasound Med Biol* 2008; 34: 902–912. doi: 10.1016/j.ultrasmedbio.2007.11.020.
- Stidham RW, Xu J, Johnson LA, Kim K, Moons DS, McKenna BJ *et al.*: Ultrasound elasticity imaging for detecting intestinal fibrosis and inflammation in rats and humans with Crohn's disease. *Gastroenterology* 2011; 141: 819–826. doi: 10.1053/j.gastro.2011.07.027.
- Baumgart DC, Muller HP, Grittner U, Metzke D, Fischer A, Guckelberger O *et al.*: US-based real-time elastography for the detection of fibrotic gut tissue in patients with stricturing Crohn disease. *Radiology* 2015; 275: 889–899. doi: 10.1148/radiol.14141929.
- Fufezan O, Asavoai C, Tamas A, Farcau D, Serban D: Bowel elastography – a pilot study for developing an elastographic scoring system to evaluate disease activity in pediatric Crohn's disease. *Med Ultrason* 2015; 17: 422–430. doi: 10.11152/mu.2013.2066.174.bwe.
- Pescatori LC, Mauri G, Savarino E, Pastorelli L, Vecchi M, Sconfienza LM: Bowel sonoelastography in patients with Crohn's disease: a systematic review. *Ultrasound Med Biol* 2018; 44: 297–302. doi: 10.1016/j.ultrasmedbio.2017.10.004.
- Giannetti A, Matergi M, Biscontri M, Tedone F, Falconi L, Franci L: Real-time elastography in Crohn's disease: feasibility in daily clinical practice. *J Ultrasound* 2017; 20: 147–155. doi: 10.1007/s40477-017-0243-8.
- Fraquelli M, Branchi F, Cribiu FM, Orlando S, Casazza G, Magarotto A *et al.*: The role of ultrasound elasticity imaging in predicting ileal fibrosis in Crohn's disease patients. *Inflamm Bowel Dis* 2015; 21: 2605–2612. doi: 10.1097/mib.0000000000000536.
- Nomura H, Miyake K, Kashiwagi S, Sugiyama T, Asaka M: A short-term eradication therapy for *Helicobacter pylori* acute gastritis. *J Gastroenterol Hepatol* 2000; 15: 1377–1381. doi: 10.1046/j.1440-1746.2000.02228.x.
- Bouvet L, Mazoit JX, Chassard D, Allaouchiche B, Boselli E, Benhamou D: Clinical assessment of the ultrasonographic measurement of antral area for estimating preoperative gastric content and volume. *Anesthesiology* 2011; 114: 1086–1092. doi: 10.1097/aln.0b013e31820dec48.
- Insko EK, Levine MS, Birnbaum BA, Jacobs JE: Benign and malignant lesions of the stomach: evaluation of CT criteria for differentiation. *Radiology* 2003; 228: 166–171. doi: 10.1148/radiol.2281020623.