



## CASE REPORT

# A Case of Paraneoplastic Pemphigus as a Preceding Manifestation of Underlying Follicular Lymphoma Treated with R-CHOP

Minsu Kim, Ji Yun Lee<sup>1</sup>, Soo-Chan Kim<sup>2</sup>, Jung-Im Na

Departments of Dermatology and <sup>1</sup>Internal Medicine, Seoul National University Bundang Hospital, Seongnam,

<sup>2</sup>Department of Dermatology and Cutaneous Biology Research Institute, Yonsei University College of Medicine, Seoul, Korea

Paraneoplastic pemphigus is a rare, life-threatening disorder associated with an underlying neoplasm, which presents with painful stomatitis and polymorphous skin lesions. Successful diagnosis of paraneoplastic pemphigus can lead to the diagnosis and treatment of the underlying malignancy. However, involvement of the respiratory system is typically unresponsive to treatment. Herein, we report the case of a 44-year-old female diagnosed with paraneoplastic pemphigus with underlying follicular lymphoma treated with a chemotherapy regimen including rituximab. Her skin lesions and underlying lymphoma responded to treatment, but bronchiolitis obliterans continued to progress and resulted in fatal respiratory failure. (*Ann Dermatol* 33(3) 271~274, 2021)

## -Keywords-

Bronchiolitis obliterans, Follicular lymphoma, Paraneoplastic pemphigus, Rituximab

Received November 26, 2019, Revised January 2, 2020, Accepted for publication January 9, 2020

**Corresponding author:** Jung-Im Na, Department of Dermatology, Seoul National University Bundang Hospital, 82 Gumi-ro 173beon-gil, Bundang-gu, Seongnam 13620, Korea. Tel: 82-31-787-7314, Fax: 82-31-787-4058, E-mail: jina1@snu.ac.kr  
ORCID: <https://orcid.org/0000-0002-5717-2490>

This is an Open Access article distributed under the terms of the Creative Commons Attribution Non-Commercial License (<http://creativecommons.org/licenses/by-nc/4.0>) which permits unrestricted non-commercial use, distribution, and reproduction in any medium, provided the original work is properly cited.

Copyright © The Korean Dermatological Association and The Korean Society for Investigative Dermatology

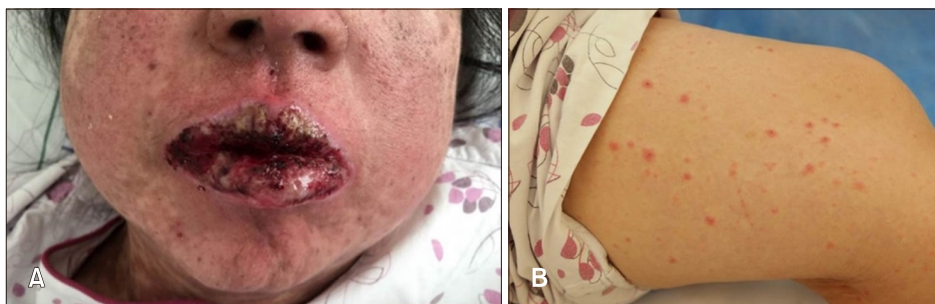## INTRODUCTION

Paraneoplastic pemphigus (PNP) is an autoimmune bullous disorder associated with an underlying neoplasm. The pathogenesis of PNP involves the production of autoantibodies against desmoglein and plakin proteins<sup>1</sup>. PNP is commonly misdiagnosed because it presents with various clinical manifestations and often resembles other cutaneous diseases. The histopathologic findings of PNP are also nonspecific and include interface dermatitis and lichenoid dermatitis. The detection of autoantibodies against plakin proteins using indirect immunofluorescence (IIF) or immunoblot shows high sensitivity and specificity for the diagnosis of PNP<sup>2</sup>.

There is no standardized treatment guideline for PNP. Systemic steroids are typically used as the first-line treatment, and rituximab could be considered as a secondary treatment option. Although treatment of the underlying neoplasm does not always lead to the treatment of PNP, the prognosis of PNP is determined by the nature of the underlying neoplasm<sup>1</sup>. PNP has a high mortality rate, and bronchiolitis obliterans (BO), which results from the involvement of the respiratory system, is a common cause of death.

## CASE REPORT

A 44-year-old female visited the emergency room due to a painful oral ulcer, which had developed 6 weeks prior. She had previously been diagnosed with aphthous stomatitis in the otolaryngology department and received systemic steroid treatment, but the oral lesion gradually progressed. She also complained of an erythematous maculopapular rash covering her whole body and conjunc-

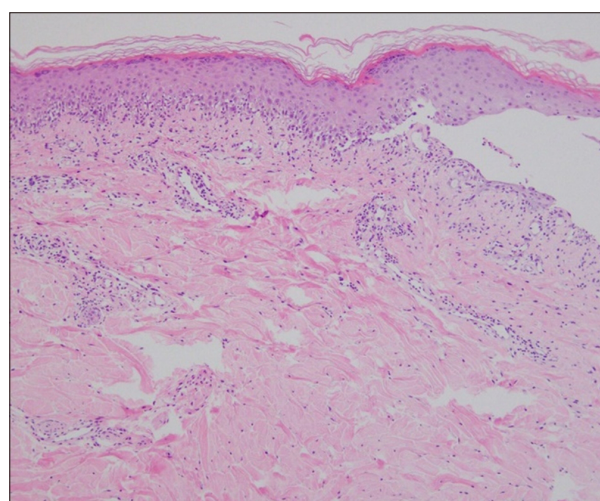


**Fig. 1.** Clinical images taken on the initial visit. Painful stomatitis (A) and a maculopapular eruption covering the whole body (B).

tival injection accompanied by fever, diarrhea, and weight loss (Fig. 1). The maculopapular eruption rapidly progressed to ulcerative patches, especially on her palms. She denied any medication history. Leukocytosis and eosinophilia were noted, but all other laboratory tests were within the normal ranges. Stevens-Johnson syndrome (SJS) with mucosal involvement was suspected, so she admitted to the internal medicine department for systemic steroid treatment.

The skin lesion slightly improved after 1.5 mg/kg of methylprednisolone therapy, but the stomatitis was unresponsive. The skin rashes recurred when the dose of methylprednisolone was reduced to below 1 mg/kg, and did not respond to cyclosporine or azathioprine. A skin biopsy was performed for further evaluation, and it showed interface dermatitis and subepidermal blister formation with basal vacuolization. Dyskeratotic cells were detected in the basal layer (Fig. 2). Direct immunofluorescence (DIF) was performed twice, and showed a negative result and linear deposits of C3 at the dermoepidermal junction, respectively. Antibodies against desmoglein 1 and 3 were not detected by enzyme-linked immunosorbent assay. IIF was conducted, and immunoglobulin G deposition was detected on the normal human skin, mouse bladder epithelium and mouse lung epithelium (Fig. 3). A diagnosis of PNP was made based on the IIF results.

Chest and abdomen computed tomography were performed to detect the underlying neoplasm, and enlargement of the axillary, supraclavicular, and retroperitoneal lymph nodes was observed. Surgical excisional biopsy of the right inguinal lymph node was consistent with follicular lymphoma. Due to bone marrow involvement, the patient was diagnosed with stage IV follicular lymphoma. The patient received chemotherapy including rituximab, cyclophosphamide, doxorubicin, vincristine, and prednisolone. Complete remission of the lymphoma was achieved after six cycles of chemotherapy, confirmed by positron emission tomography. The stomatitis and skin rash were also dramatically improved and well-maintained with low-dose steroid therapy (5 mg/day) for 8 months (Fig. 4).



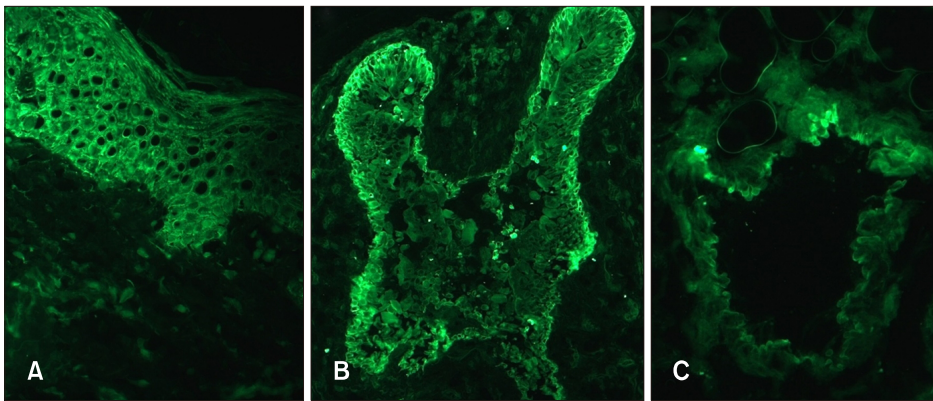
**Fig. 2.** Histopathological examination showed subepidermal blister formation with interface dermatitis. Dyskeratotic cells were present in the basal layer and vacuolization was observed (H&E,  $\times 100$ ).

However, the patient developed BO and invasive pulmonary aspergillosis, and died from respiratory failure 20 months after the initial manifestation of PNP.

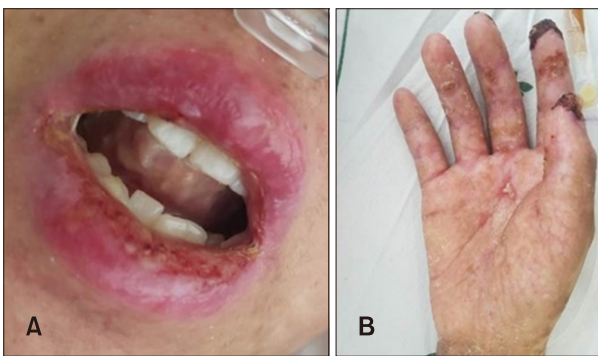## DISCUSSION

Anhalt et al.<sup>3</sup> first described PNP as a rare autoimmune blistering disease characterized by painful stomatitis and a polymorphous cutaneous eruption accompanied by the production of autoantibodies. The associated neoplasms are mainly lymphoproliferative disorders. In contrast to other autoimmune blistering diseases, PNP-associated autoantibodies invade not only stratified squamous epithelium but also other types of epithelium including the transitional epithelium of the bladder. When IIF is performed, these autoantibodies react with rat bladder epithelium, so this diagnostic test can be used to distinguish PNP from other blistering diseases.

The diagnosis of PNP is challenging due to its rare prevalence and various cutaneous manifestations. Given its



**Fig. 3.** Indirect immunofluorescence showed positive results on (A) normal human skin (1:10), (B) mouse bladder epithelium (1:40), and (C) mouse lung epithelium (1:10).



**Fig. 4.** The stomatitis (A) and skin eruption (B) entered clinical remission after rituximab treatment.

mucosal involvement, PNP is frequently misdiagnosed as Stevens-Johnson syndrome/toxic epidermal necrolysis (SJS/TEN). Although the prevalence of SJS/TEN-like PNP is lower than that of SJS/TEN, its mortality is much higher<sup>4</sup>. In some cases, PNP is diagnosed before the detection of an underlying malignancy, so early diagnostic work-up of the underlying neoplasm is necessary for treatment. Therefore, the differential diagnosis of SJS and SJS/TEN-like PNP is important, and PNP should be considered in patients with an atypical clinical course of SJS/TEN.

Anhalt et al.<sup>3</sup> proposed five diagnostic criteria for PNP, including immunoglobulin G or complement deposition in the intercellular spaces of the epidermis or basement membrane zone, which can be detected using DIF. Our patient showed a negative DIF result, which prevented an earlier diagnosis. DIF shows a sensitivity lower than 50% in the diagnosis of PNP, and PNP is known to have a higher false negative rate than other types of pemphigus<sup>1,4</sup>. In contrast, IIF on rat bladder has high sensitivity and specificity in the diagnosis of PNP<sup>2</sup>. Therefore, if PNP is suspected, the presence of autoantibodies in the patient's serum should be evaluated.

The prognosis of PNP is highly associated with the nature

of the underlying neoplasm. If the underlying tumor is benign or localized, PNP shows good prognosis and early resection of the tumor can lead to a good outcome<sup>5</sup>. However, treatment of the underlying neoplasm does not always lead to the improvement of PNP<sup>1</sup>. Systemic steroids are typically used as the first-line treatment for PNP. Recently, several cases of PNP successfully treated with rituximab have been reported<sup>6-8</sup>. Rituximab is thought to act by depleting CD20-expressing B cells that produce autoantibodies<sup>9</sup>.

Our patient exhibited clinical remission of the underlying follicular lymphoma and cutaneous, mucosal involvement of PNP after rituximab treatment. However even after remission, BO progressed and the patient died from respiratory failure. The exact mechanism underlying respiratory tract involvement remains unclear. Autoantibodies may react with plakin proteins on the respiratory epithelium, and destruction of the bronchial epithelium may lead to irreversible airway obstruction<sup>1</sup>. BO is resistant to conventional treatment for PNP, and lung transplantation is considered the only effective treatment. A previous case report demonstrated that rituximab unsuccessfully treated BO, though evidence for the effectiveness of rituximab against PNP-related BO is still lacking<sup>7</sup>. In this case, although rituximab successfully treated PNP and the underlying neoplasm, it was ineffective against BO. To the best of our knowledge, this is the first report to discuss the effectiveness of rituximab against PNP and PNP-related BO in a Korean patient. Our case emphasizes the necessity of close monitoring and respiratory support even after PNP enters clinical remission.

In conclusion, PNP should be suspected in patients presenting with refractory stomatitis with a polymorphous cutaneous eruption, and corresponding diagnostic tests should be performed. Rituximab could be an effective treatment option for PNP, but physicians should be aware of the development of BO.

## ACKNOWLEDGMENT

---

We received the patient's consent form about publishing all photographic materials. We thank the patient for granting permission to publish this information.

## CONFLICTS OF INTEREST

---

The authors have nothing to disclose.

## FUNDING SOURCE

---

None.

## DATA SHARING STATEMENT

---

Research data are not shared.

## ORCID

---

Minsu Kim, <https://orcid.org/0000-0003-0590-7894>

Ji Yun Lee, <https://orcid.org/0000-0002-5835-7219>

Soo-Chan Kim, <https://orcid.org/0000-0002-2327-4755>

Jung-Im Na, <https://orcid.org/0000-0002-5717-2490>

## REFERENCES

---

1. Anhalt GJ. Paraneoplastic pemphigus. *J Invest Dermatol Symp Proc* 2004;9:29-33.
2. Joly P, Richard C, Gilbert D, Courville P, Chosidow O, Roujeau JC, et al. Sensitivity and specificity of clinical, histologic, and immunologic features in the diagnosis of paraneoplastic pemphigus. *J Am Acad Dermatol* 2000;43:619-626.
3. Anhalt GJ, Kim SC, Stanley JR, Korman NJ, Jabs DA, Kory M, et al. Paraneoplastic pemphigus. An autoimmune mucocutaneous disease associated with neoplasia. *N Engl J Med* 1990;323:1729-1735.
4. McLarney RM, Valdes-Rodriguez RH, Isaza-Gonzalez G, Miller JH, Hsu S, Motaparthy K. Paraneoplastic pemphigus mimicking toxic epidermal necrolysis: an underdiagnosed entity? *JAAD Case Rep* 2017;4:67-71.
5. Zhu X, Zhang B. Paraneoplastic pemphigus. *J Dermatol* 2007;34:503-511.
6. Heizmann M, Itin P, Wernli M, Borradori L, Bargetzi MJ. Successful treatment of paraneoplastic pemphigus in follicular NHL with rituximab: report of a case and review of treatment for paraneoplastic pemphigus in NHL and CLL. *Am J Hematol* 2001;66:142-144.
7. Hirano T, Higuchi Y, Yuki H, Hirata S, Nosaka K, Ishii N, et al. Rituximab monotherapy and rituximab-containing chemotherapy were effective for paraneoplastic pemphigus accompanying follicular lymphoma, but not for subsequent bronchiolitis obliterans. *J Clin Exp Hematop* 2015;55:83-88.
8. Aoi J, Makino K, Sakai K, Masuguchi S, Fukushima S, Jinnin M, et al. Case of paraneoplastic pemphigus with follicular lymphoma treated with rituximab. *J Dermatol* 2013;40:285-286.
9. Schmidt E, Bröcker EB, Goebeler M. Rituximab in treatment-resistant autoimmune blistering skin disorders. *Clin Rev Allergy Immunol* 2008;34:56-64.