

Immediate effects of Kinesio Taping on the movement of the hyoid bone and epiglottis during swallowing by stroke patients with dysphagia

SEO YOON HEO¹⁾, KYEONG MI KIM^{2)*}

¹⁾ Department of Rehabilitation Science, Graduate School of Inje University, Republic of Korea

²⁾ Department of Occupational Therapy, College of Biomedical Science and Engineering, Inje University: 197 Inje-ro, Gimhae-si, Gyeongsangnam-do 621-749, Republic of Korea

Abstract. [Purpose] The purpose of this study was to identify the effects of Kinesio Taping (KT) on the swallowing function of stroke patients. [Subjects and Methods] Twenty-two stroke patients were randomly assigned to two groups; an experimental group which received KT, and a control group which received no taping intervention. Two-dimensional kinematic analysis was used to determine the displacement of the hyoid bone and the angular variation of the epiglottis using human anatomy-based coordinates. The functional dysphagia scale (FDS) was determined by a videofluoroscopic study (VFSS). [Results] The experimental group presented statistically significant improvements in kinematic changes of the vertical excursion of the hyoid bone and epiglottal rotation. [Conclusion] Clinical use of KT for dysphagia patients should be considered as a treatment approach. In future research, more subjects and more diverse patterns should be studied to accumulate further evidence.

Key words: Kinesio Taping, Stroke, Dysphagia

(This article was submitted Jun. 23, 2015, and was accepted Jul. 31, 2015)

INTRODUCTION

Stroke-induced dysphagia mostly causes pneumonia or dehydration and these symptoms can lead to other severe complications, or even death^{1, 2)}. Stroke patients with dysphagia have been treated with high priority within stroke care, and many kinds of interventions for dysphagia have been studied³⁾. Sensory stimulation, thermotherapy, position change techniques, bio-feedback, maneuvers, neuromuscular electrical stimulation therapy, and surgical approaches are being used as the preferred methods for dysphagia interventions⁴⁾.

Most studies have identified deficiencies in dysphagia treatments, with the exception of neuromuscular electrical stimulation therapy⁵⁾. However, neuromuscular electrical stimulation therapy (TENS) remains controversial, due to the fact that the muscular effect could be just a reflex triggered by electric stimulation⁶⁾. TENS has many contraindications and there is still insufficient evidence of use⁷⁾. Practitioners have been demonstrating other evidence-based treatments which have no side effects and are safe for treating dysphagia, but conventional methods continue to be used⁸⁾.

Kinesio Taping (KT) is a well-known clinical procedure

which is widely used to treat various neuromuscular symptoms. In according to Kase et al.⁹⁾, KT allows more efficient blood circulation, lymph absorption and joint fixation. A previous study showed that KT application with proper tension could reduce pain, and improve the range of motion (ROM) and proprioception¹⁰⁾. In spite of these advantages, no clinical trials using KT have yet been performed with stroke patients suffering from dysphagia. It is important to the adequate therapeutic method in novel clinical uses.

The main focus of this study was to conduct a kinematic analysis of the effects of KT on the movement of the hyoid bone and the epiglottis of stroke patients with dysphagia. The authors also used the functional dysphagia scale (FDS) to evaluate the effect of KT in a real swallowing situation.

SUBJECTS AND METHODS

Twenty-two subjects diagnosed as having dysphagia due to stroke participated in this study. The patients were hospitalized in a rehabilitation ward and were scheduled for videofluoroscopic study (VFSS) every month. The subjects were 13 males (mean age, 59.0 years; range, 54–78 years) and 9 females (mean age, 61.0 years; range, 51–73 years). The subjects were hemorrhagic (8 patients) and infarction (14 patients), and the duration of onset (month) was within 3 months for all of the subjects. When the patients entered the VFSS room, they were randomly allocated for radiographic inspection with KT or without KT (NKT) by drawing lots. If a patients chose KT, he or she was treated with KT and then VFSS was conducted. The taping was applied to the external laryngeal muscles (digastric posterior bellies, mylohyoid and

*Corresponding author. Kyeong Mi Kim (E-mail: kmik321@inje.ac.kr)

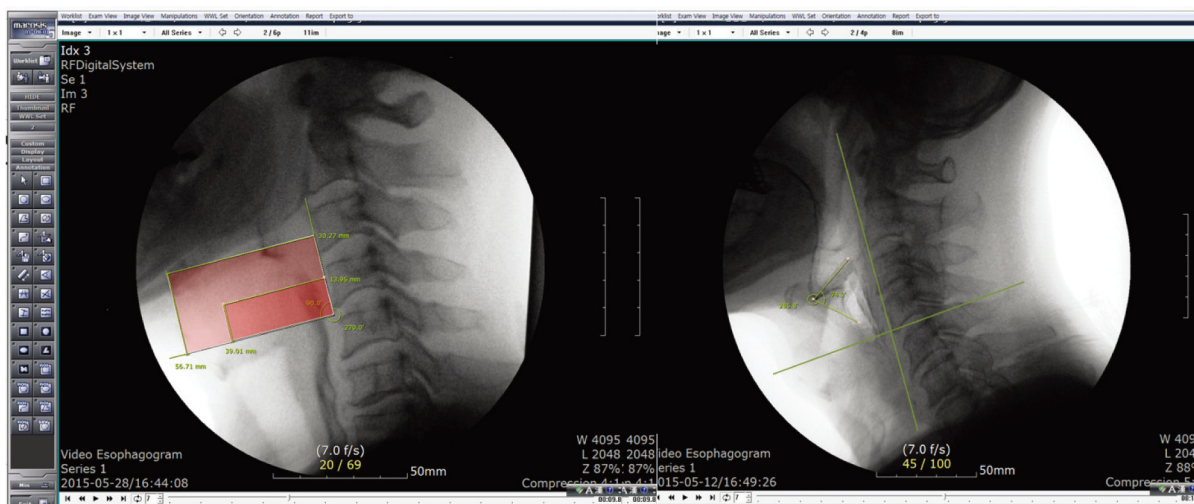


Fig. 1. Digital kinematic analysis of the hyoid bone (left) and the epiglottis (right) through control frame of the X, Y-coordinates.

Table 1. Comparison of the swallowing functions of the KT and NKT groups

	KT group (n=22)	NKT group (n=22)
Horizontal excursion of the hyoid bone (cm)	2.01 ± 0.68	1.83 ± 0.61
Vertical excursion of the hyoid bone (cm)	2.50 ± 0.73	2.06 ± 0.64*
Rotation of the epiglottis (°)	51.00 ± 17.80	41.00 ± 20.16*
FDS	25.72 ± 10.03	26.72 ± 10.45

KT: Kinesio Taping; NKT: No Kinesio Taping; FDS: Functional Dysphagia Scale. Values are presented as the mean and standard deviation. * denotes significant difference, $p < 0.05$

geniohyoid), the sternocleidomastoid (SCM) and the upper trapezius. VFSS also conducted in the same manner for the NKT subjects. The tension of KT was set at 50% (available tension is 100%)¹¹ and 20 cm × 5 cm strips of Kinsiotape KT 545 (Visiocare s.r.l., Vedano al Lambro, Monza-Brianza, Italy) were applied to the neck and chin to affect the active range of motion (AROM)¹².

Kinematic analysis of the movement of the hyoid bone and the angular variation of the epiglottis was performed using Marosis M-view 5.4 (Fig. 1). The movement of the hyoid bone was measured in both horizontal and vertical sections in the two consecutive frames (frame for X, Y-coordinates; the upper left corner of the square is the hyoid bone; the line indicates the epiglottis on the right of the image)¹³. FDS was calculated for the overall result. The FDS consist of 11 items and its maximum score is 100 points. A lower score means a higher level of performance in the spectrum of lip closure, bolus formation, residue in the oral cavity, oral transit time, triggering of pharyngeal swallow, laryngeal elevation and epiglottal closure, nasal penetration, residue in the valleculae, residue in the pyriform sinuses, coating of pharyngeal wall after swallow, and pharyngeal transit time.

All of the subjects agreed to participate in the study and they provided their written informed consent receiving sufficient explanation of the experimental procedures in accordance with the ethical principles of the Declaration of Helsinki.

Data analysis was performed using IBM SPSS Statistics

20. The Wilcoxon Signed-Rank test was used to compare the values of the KT and NKT subjects. The level of statistical significance was chosen as 0.05 for all analyses.

RESULTS

The differences in the variation of the displacement of the hyoid bone, the angular variation of the epiglottis, and FDS are shown in Table 1. The KT group showed improvements in the vertical excursion of the hyoid bone and rotation of the epiglottis, the differences were statistically significant ($p < 0.05$). Changes in the horizontal movement and FDS were observed in the clinical assessment and analysis but the differences were not statistically significant ($p > 0.05$).

DISCUSSION

Swallowing problems are mostly induced by dysfunction of the esophageal structures such as the hyoid bone, suprahyoid muscle and infrahyoid muscle¹⁴. Kinematic analysis using VFSS has the advantage of presenting the mechanical changes of the laryngopharynx, and VFSS studies of dysphagia have been published.

Therapeutic methods have been used to change the external laryngeal muscles (digastric posterior bellies, mylohyoid, stylohyoid, geniohyoid), SCM, and the upper trapezius, though changes in head and neck position are also used as many researchers agree that anatomical changes are impor-

tant factors in swallowing function¹⁵). From the perspective of this mechanical change concept, the hypothesis of this study was that KT would affect the active range of motion (AROM)¹⁶.

Worthy of close attention in this study is that results could be the first trial of using KT for treating stroke patients with dysphagia. The KT has already been investigated by many studies. Related to this study, there is a published material that KT facilitates, provides, supports, and gives stability to muscles and joints without restricting the body's range of motion¹⁷), and has positive physiological effects on the skin, lymphatic, circulatory system, fascia, muscles, ligaments, tendons, and joints¹⁸). Researchers have reported that usage of KT increases the functional abilities and manual muscle testing scores of stroke patients¹⁹).

This study attempt to precisely analyze the movement of the hyoid bone and the angular variation of the epiglottis, but some possible deviation in the sampling distribution (± 0.1 – 0.8 mm) could exist. This might be eccentric basic error range of magnification during VFSS. The C2–C4 (cervical 2, cervical 4) plane as a standard coordinate to analyze the displacement of the hyoid bone and the angular variation of the epiglottis following the method of a recent study²⁰).

Future research should be performed with larger subject numbers and modification of the taping techniques. The kinematic analysis of the hyoid bone and the epiglottis should continue to be used as it is the optimal method for determining the effects of dysphagia therapy approaches. Therefore, future studies should examine not only clinical evaluation tools but also kinematic analysis using VFSS. With more evidence, KT for dysphagia patients should be considered a possible treatment approach.

REFERENCES

- Smithard DG, Smeeton NC, Wolfe CD: Long-term outcome after stroke: does dysphagia matter? *Age Ageing*, 2007, 36: 90–94 [Medline] [CrossRef].
- Langdon PC, Lee AH, Binns CW: Dysphagia in acute ischaemic stroke: severity, recovery and relationship to stroke subtype. *J Clin Neurosci*, 2007, 14: 630–634 [Medline] [CrossRef].
- DePippo KL, Holas MA, Reding MJ, et al.: Dysphagia therapy following stroke: a controlled trial. *Neurology*, 1994, 44: 1655–1660 [Medline] [CrossRef].
- Martino R, Foley N, Bhogal S, et al.: Dysphagia after stroke: incidence, diagnosis, and pulmonary complications. *Stroke*, 2005, 36: 2756–2763 [Medline] [CrossRef].
- Blumenfeld L, Hahn Y, Lepage A, et al.: Transcutaneous electrical stimulation versus traditional dysphagia therapy: a nonconcurrent cohort study. *Otolaryngol Head Neck Surg*, 2006, 135: 754–757 [Medline] [CrossRef].
- Ludlow CL, Humbert I, Saxon K, et al.: Effects of surface electrical stimulation both at rest and during swallowing in chronic pharyngeal Dysphagia. *Dysphagia*, 2007, 22: 1–10 [Medline] [CrossRef].
- Carnaby-Mann GD, Crary MA: Examining the evidence on neuromuscular electrical stimulation for swallowing: a meta-analysis. *Arch Otolaryngol Head Neck Surg*, 2007, 133: 564–571 [Medline] [CrossRef].
- Jeong H, Seo HG, Han TR, et al.: Kinematic changes in swallowing after surgical removal of anterior cervical osteophyte causing Dysphagia: a case series. *Ann Rehabil Med*, 2014, 38: 865–870 [Medline] [CrossRef].
- Kase K: *Clinical Therapeutic Applications of the Kinesio Taping Method*. Albuquerque: Kinesio Taping Association, 2003, pp 14–16.
- Cho HY, Kim EH, Kim J, et al.: Kinesio taping improves pain, range of motion, and proprioception in older patients with knee osteoarthritis: a randomized controlled trial. *Am J Phys Med Rehabil*, 2015, 94: 192–200 [Medline] [CrossRef].
- Thelen MD, Dauber JA, Stoneman PD: The clinical efficacy of kinesio tape for shoulder pain: a randomized, double-blinded, clinical trial. *J Orthop Sports Phys Ther*, 2008, 38: 389–395 [Medline] [CrossRef].
- Ayuse T, Ayuse T, Ishitobi S, et al.: Effect of reclining and chin-tuck position on the coordination between respiration and swallowing. *J Oral Rehabil*, 2006, 33: 402–408 [Medline] [CrossRef].
- Kim Y, McCullough GH: Maximal hyoid excursion in poststroke patients. *Dysphagia*, 2010, 25: 20–25 [Medline] [CrossRef].
- Paik NJ, Kim SJ, Lee HJ, et al.: Movement of the hyoid bone and the epiglottis during swallowing in patients with dysphagia from different etiologies. *J Electromyogr Kinesiol*, 2008, 18: 329–335 [Medline] [CrossRef].
- Baylow HE, Goldfarb R, Taveira CH, et al.: Accuracy of clinical judgment of the chin-down posture for dysphagia during the clinical/bedside assessment as corroborated by videofluoroscopy in adults with acute stroke. *Dysphagia*, 2009, 24: 423–433 [Medline] [CrossRef].
- Bae Y: Change the myofascial pain and range of motion of the temporomandibular joint following kinesio taping of latent myofascial trigger points in the sternocleidomastoid muscle. *J Phys Ther Sci*, 2014, 26: 1321–1324 [Medline] [CrossRef].
- Lee JH, Yoo WG, Lee KS: Effects of head-neck rotation and kinesio taping of the flexor muscles on dominant-hand grip strength. *J Phys Ther Sci*, 2010, 22: 285–289 [CrossRef].
- Zübeyir S, Nilüfer K, Burcu C, et al.: The effect of kinesiology taping on respiratory muscle strength. *J Phys Ther Sci*, 2012, 24: 241–244 [CrossRef].
- Lee BH, Lee HR, Kim KM, et al.: Effects of spiral taping applied to the neck and ankle on the body balance index. *J Phys Ther Sci*, 2015, 27: 79–82 [Medline] [CrossRef].
- Nakane A, Tohara H, Ouchi Y, et al.: Videofluoroscopic kinesiologic analysis of swallowing: defining a standard plane. *J Med Dent Sci*, 2006, 53: 7–15 [Medline].