

Pain Relief Following Sternotomy in Conventional Cardiac Surgery: A Review of Non Neuraxial Regional Nerve Blocks

Abstract

Acute post-operative pain following sternotomy in cardiac surgery should be adequately managed so as to avoid adverse hemodynamic consequences and pulmonary complications. In the era of fast tracking, adequate and efficient technique of post-operative analgesia enables early extubation, mobilization and discharge from intensive care unit. Due to increasing expertise in ultrasound guided blocks there is a recent surge in trial of bilateral nerve blocks for pain relief following sternotomy. The aim of this article was to review non-neuraxial regional blocks for analgesia following sternotomy in cardiac surgery. Due to the paucity of similar studies and heterogeneity, the assessment of bias, systematic review or pooled analysis/meta-analysis was not feasible. A total of 17 articles were found to be directly related to the performance of non-neuraxial regional nerve blocks across all study designs. Due to scarcity of literature, comments cannot be made on the superiority of these blocks over each other. However, most of the reviewed techniques were found to be equally efficacious or better than conventional and established techniques.

Keywords: Analgesia, cardiac surgery, fascial blocks, pain relief, regional nerve blocks, sternotomy

Introduction

Acute post-operative pain following sternotomy in cardiac surgery should be adequately managed so as to avoid adverse hemodynamic consequences and pulmonary complications. In the era of fast tracking, adequate, and efficient technique of post-operative analgesia enables early extubation, mobilization, and discharge from intensive care unit. Pharmacologic therapy either in the form parenteral opioids or non-steroidal anti-inflammatory drugs (NSAID) have been the mainstay of analgesic therapy for postoperative pain management in cardiac surgery. However, these often don't match the quality of analgesia offered by regional anesthesia. Thoracic epidural was the initial mode of regional analgesia introduced in cardiac surgery practice. Thoracic epidural has shown to produce excellent analgesia and reduce systemic analgesic requirement. The risk of epidural hematoma formation in the background of heparinization on cardiopulmonary bypass has dissuaded most cardiac anesthesiologist from using it on regular basis. In the last decade various regional blocks have been tried as an

alternative to thoracic epidural for pain relief in the cardiothoracic surgical practice. However, these techniques have been mostly studied in patients undergoing thoracotomy, minimally invasive and robotic cardiac surgery. Due to increasing expertise in ultrasound guided blocks there is a recent surge in trial of bilateral nerve blocks for pain relief following sternotomy. The aim of the article is to review the non-neuraxial regional nerve blocks used for pain relief following sternotomy.

Materials and Methods

The research questions for initiating the review was "What are the non-neuraxial regional techniques (nerve blocks) for adult patients undergoing cardiac surgery via sternotomy and their analgesic efficacy? The PICOS (Participants, intervention, comparisons outcomes and study design) format was followed for this review as per PRISMA (Preferred Reporting Items for Systematic Reviews and Meta-Analyses) format. The included components are mentioned below.

Participants

Studies that included adult patients undergoing cardiac surgery via conventional midline sternotomy.

How to cite this article: Kar P, Ramachandran G. Pain relief following sternotomy in conventional cardiac surgery: A review of non-neuraxial regional nerve blocks. *Ann Card Anaesth* 2020;23:200-8.

**Prachi Kar,
Gopinath
Ramachandran**

*Department of Anesthesia
and Intensive Care, Nizams
Institute of Medical Sciences,
Hyderabad, Telangana, India*

Submitted: 18-Dec-2018
Revised: 20-May-2019
Accepted: 25-Jun-2019
Published: 07-Apr-2020

Address for correspondence:

*Dr. Prachi Kar,
Department of Anesthesia
and Intensive Care, Nizams
Institute of Medical Sciences,
Hyderabad - 500 082,
Telangana, India.
E-mail: prachikar@yahoo.co.in*

Access this article online

Website: www.annals.in

DOI: 10.4103/aca.ACA_241_18

Quick Response Code:



This is an open access journal, and articles are distributed under the terms of the Creative Commons Attribution-NonCommercial-ShareAlike 4.0 License, which allows others to remix, tweak, and build upon the work non-commercially, as long as appropriate credit is given and the new creations are licensed under the identical terms.

For reprints contact: reprints@medknow.com

Intervention

Interventions that included non-neuraxial regional nerve block techniques for pain relief in sternotomy following cardiac surgery.

Comparisons

It included comparison of non-neuraxial regional nerve blocks with any other mode of analgesia.

Outcomes

Primary outcomes were pain scores and analgesic efficacy.

Study designs

This review included prospective, retrospective, randomized, nonrandomized, blinded, non-blinded, observational, and cohort studies.

For the purpose of this review, PubMed (www.ncbi.nlm.nih.gov) was searched for relevant articles using following mesh terms: “post-operative pain” OR “pain relief”, OR “analgesics”, OR “analgesia”, OR “nerve block”, OR “regional block”, OR “regional anesthesia”, OR “sternotomy”, OR “cardiac surgery”. The retrieved titles and abstracts were manually screened for assessing the suitability for inclusion into the review. The references of assessed articles were also searched manually for finding any missed articles of interest. Only articles in English were considered for the review. The full text of all selected articles was obtained. Due to heterogeneity of the studies and the paucity of similar studies, the assessment of bias, systematic review or pooled analysis was not feasible. Hence, we report the quasi-systematic review of non-neuraxial regional nerve block for sternotomy pain relief. Further, due to paucity of literature, both the authors agreed upon accepting correspondence and case reports for review.

Results

A total of 210 manuscript were identified after database search. Out of these only 17 studies were directly related to administration of non-neuraxial regional nerve blocks for pain relief in sternotomy. The details of the studies are mentioned in Table 1. The various blocks included in the review are paravertebral block, parasternal intercostal block, and fascial plane blocks (Pectoral nerve block and erector spinae block, pecto-intercostal fascial plane block, and transversus thoracic plane block).

Discussion

Since this review discusses on various regional techniques for sternotomy pain relief, we thought, it is essential to highlight on sensory innervation of chest wall for better understanding of our readers. The chest wall is mostly supplied by branches of intercostal (spinal) nerves. The ventral ramus of T1-T11 spinal nerves form the intercostal nerves. However, it is the anterior division of

2nd to 6th thoracic intercostal nerves that supply most of the anterior chest wall. The intercostal nerves lie within the neurovascular bundle situated in the intercostal groove of each rib. After reaching the angle of rib it divides to give the lateral cutaneous branch, a collateral muscular branch and the anterior cutaneous branch.^[1] The lateral cutaneous branch further divides into anterior and posterior branches. The anterior cutaneous branch divides into medial and lateral branch close to lateral border of sternum. All these nerves branch, penetrate the muscle, fascia, and collateralize along their course to provide the sensory innervation of whole of the chest wall. Various regional anesthetic techniques like paravertebral block, parasternal block, and more recently fascial plane blocks have been used for pain relief in sternotomy. They all target the spinal nerves or their branches in various planes.

Paravertebral block

Paravertebral block is a widely used technique in patients undergoing thoracotomy. Although its use was initially limited to unilateral surgeries, bilateral use has gained popularity in the last decade. However, its use for post sternotomy pain relief is still not widespread. In paravertebral block local anesthetic is injected adjacent to the thoracic vertebra where the spinal nerve emerges from the intervertebral foramina. The sympathetic and somatic outflow is blocked in multiple adjoining dermatomes by both caudal and rostral migration of anesthetic drug.^[2]

The thoracic paravertebral space (TPVS) is a wedge-shaped space on either side of the vertebral column, left being wider than right.^[3] Parietal pleura lines the space anterolaterally while the base is formed by posterolateral aspects of vertebral body, intervertebral discs, intervertebral foramen along with its contents. Superior costotransverse ligament forms the posterior border of the space [Figure 1a].^[4] The paravertebral space communicates laterally with intercostal space, medially with epidural space. It also connects to contralateral TPVS through prevertebral and epidural space. TPVS is filled with fat in which intercostal nerves and vessels, sympathetic chain and rami communicantes lie freely. The nerve fibers in this area are devoid of fascial covering and are thus highly sensitive to the effect of local anesthetics.^[5]

The classical landmark technique uses loss of resistance to air or saline for identification of the space. Although the block can be performed in lateral, sitting or prone position, sitting is often preferred due to concerns of patient comfort, and ease of identification of landmarks. Either multiple level single shot block or single level injection with catheter insertion can be performed. A 22G spinal needle or a 18G Tuohy needle (if catheter is to be placed) is inserted 2.5–3 cm lateral to spinous process at the appropriate dermatomal level, under strict aseptic conditions. The needle is advanced perpendicularly till

Table 1: Published articles on use of Non-neuraxial regional nerve blocks in conventional sternotomy

Author/year/ journal name	Type of study	Type of block	Sample size	Drugs used in intervention group	Comparator group	Main results	Other results
Canto M <i>et al</i> /2003 <i>Anaesthesia</i> ^[12]	Prospective observational study	Landmark guided Bilateral continuous paravertebral block (catheter at T3-T4)	111	0.2% ropivacaine, 0.2-0.25 ml/kg with fentanyl 2 mcg/ml (2 boluses, one before skin incision and another after CPB.) Postoperative infusion of 0.075% ropivacaine with fentanyl 0.5 mcg/kg at 0.15 ml/kg/h	nil	Good post-operative analgesia in study group	Hemodynamic stability and early extubation
Oliver JF <i>et al</i> /2007/ <i>Heart Surgery forum</i> ^[14]	Prospective cohort audit	Landmark guided bilateral single shot paravertebral block (T1-T7)	52	3ml of 0.5% bupivacaine at each level bilaterally.	Thoracic epidural	TEA had better analgesia as compared to single shot paravertebral block	None reported
Lockwood GG <i>et al</i> /2017/ <i>perfusion</i> ^[15]	Randomized double-blind study	Bilateral continuous Paravertebral block (catheter at T3-T4)	50	20-30ml 0.5% plain lidocaine bolus on each side. followed by 1 mg/kg/h of lidocaine in saline	Continuous infusion though sham subcutaneous catheter placed in paravertebral position	No difference in morphine consumption in both the groups	PONV and time at wind passage were comparable
El shora HA <i>et al</i> /2018/ <i>The thoracic and cardiovascular surgeon</i> ^[13]	Randomized control study	USG guided bilateral continuous paravertebral block (Catheter at T6-T7)	150	6 ml 0.125% bupivacaine with 1 mcg/kg fentanyl bolus followed by 6 ml/h on each side catheter	Thoracic epidural	Comparable analgesia in both Thoracic epidural and paravertebral group at 0,12,24,48 h after extubation	Shorter duration of ICU stays, lesser incidence of urinary retention and vomiting in paravertebral group
Mc Donald SB <i>et al</i> /2005/ <i>Anesthesia Analgesia</i> ^[16]	Randomized placebo controlled double blind study	Parasternal block	20	54 mL of 0.25% levobupivacaine with 1:400,000 epinephrine (2 ml in 2 nd to 6 th intercostal space, 12 ml on periosteum on either side, and 10 ml around drains	Placebo (Parasternal injection of saline)	lower Morphine requirement in study group but no difference in VAS score	Improved pulmonary function and oxygenation
Althea M. Barr/2007/ <i>Journal of cardiothoracic and vascular anesthesia</i> ^[19]	Randomized controlled, double blind study	Parasternal block	88	40 ml of 0.75% Ropivacaine, 4 ml in the 2 nd -6 th anterior intercostal spaces on either side	Placebo (Parasternal block with Saline)	Lower Extubation pain scores and lower PCA (morphine), paracetamol and codeine requirement in first 24 h in study group	Lower oxygen saturation (<95%) and more hypertensive episodes in saline group. Higher incidence of non-sternal wound chest pain in Ropivacaine group
Ozturk NK <i>et al</i> /2016/ <i>Pain Research and Management</i> ^[18]	Randomized double blind controlled study	Parasternal block	120	50ml of solution (25 ml levobupivacaine + 25 ml saline), 2ml in 2 nd -6 th anterior intercostal spaces on either side, 20 ml in periosteum and 10 ml on the chest tubes	Trans cutaneous electrical Nerve stimulation (TENS) and control group	Lower VAS scores at 4,5,6 7 and 8 h and lower PCA (morphine) requirements in block group	No difference in Time to extubation, ICU and hospital stay and Tramadol consumption

Contd...

Table 1: Contd...

Author/year/ journal name	Type of study	Type of block	Sample size	Drugs used in intervention group	Comparator group	Main results	Other results
Dogan Baki <i>E et al/2016/ Seminars in Cardiothoracic and Vascular Anaesthesia</i> ^[17]	Randomized study	Parasternal block	81	50 ml of solution (25 ml of levobupivacaine + 100mcg fentanyl + 23 ml saline). 2ml on 2nd-6th intercostal spaces on either side (total 20 ml), 20 ml on periosteum of sternum, and 10 ml around drain sites	Pharmacologic analgesia (Tramadol with PCA)	Reduced VAS Scores and Morphine requirements in study group	No effect on Chronic pain
Candice Y Lee <i>et al/2019/ Annals of Thoracic surgery</i> ^[20]	Randomized double-blind study	Parasternal block	79	50 ml (0.53% liposomal bupivacaine), 4 ml in 2 nd to 6 th intercostal space on each side, 10 ml over drain sites	Placebo (Parasternal injection of saline)	Lower overall pain scores in study group, but no difference in analgesic requirement	No difference in extubation time, ICU/Hospital stay and time to return of bowel movement
Kumar KN <i>et al/2018/ Annals of Cardiac anesthesia</i> ^[23]	Prospective Randomized	Ultrasound guided bilateral single shot Pectoral nerve block (both PECS-1 and PECS-2)	40	0.25% bupivacaine + 25 mcg dexmedetomidine- PECS-1 10ml, PECS 2-20ml, 5ml infiltration around mediastinal tubes	No block	Lesser VAS Scores and lesser rescue analgesic requirement in study group	Lesser duration of ventilation, higher peak expiratory flow rates in the block group
Tsui <i>et al/2018/ Journal of clinical anesthesia</i> ^[28]	Case report	USG guided bilateral continuous Erector spinae block	1 case	12ml of 0.5% Ropivacaine bolus followed by 10 ml 0.2% Ropivacaine every 90 min on either side	NA	Lower pain scores (median of 0-2/10)	Early extubation
PS nagaraja <i>et al/2018/ Annals of cardiac anesthesia</i> ^[30]	Randomized controlled trial	USG guided bilateral continuous Erector spinae block	50	0.25% plain bupivacaine 15ml bolus followed by 0.125% bupivacaine 0.1ml/kg/h	Thoracic epidural anesthesia	Comparable VAS scores between study and control groups both at rest and cough at 0,3,6 and 12 h but higher VAS scores at 24, 36 and 48 h in TEA group	Ventilation duration, Peak expiratory flow and ICU stay was comparable in both groups
Krishna SN <i>et/2019/ Journal of cardiovascular anesthesia</i> ^[29]	Randomized controlled single blind study	USG guided bilateral single shot Erector spinae plane block	106	Total 3mg/kg of 0.375% ropivacaine, 20-25ml injected on each side	Intra venous paracetamol and Tramadol	NRS scores were lower and duration of analgesia was longer in block group	Duration of mechanical ventilation, dose of rescue analgesic, opioid usage, length of ICU stays, time to oral intake, time to ambulation were lesser in ESP block group
Victor Liu <i>et al/2018/ Anaesthesia analgesia Practice</i> ^[33]	Case report	USG guided Single shot Pecto-intercostal fascial block	1 case	Ropivacaine (0.25%, 20 ml on left and 18 ml on right)	NA	Lower pain scores (1-3/100) and lower analgesic requirement	Not mentioned

Contd...

Table 1: Contd...

Author/year/ journal name	Type of study	Type of block	Sample size	Drugs used in intervention group	Comparator group	Main results	Other results
Ueshima H <i>et al</i> /2016/ journal of clinical anesthesia ^[35]	Correspondence	USG guided single shot Transverse thoracic muscle plane block	2 cases	Levobupivacaine 0.375% 40 ml (20 ml on each side)	NA	No additional analgesics required	Stable intraoperative vitals
Ueshima H/2017/Journal of clinical anesthesia ^[36]	Correspondence	USG guided Continuous Transverse thoracic muscle plane block	2 cases	Levobupivacaine 0.375% 40ml (20ml on each side followed by bilateral catheter insertion. (intermittent bolus and infusion of levobupivacaine 0.1% 10ml on each side and lockout time 30 min)	NA	no additional analgesics required	Stable intraoperative vitals
Fuji S <i>et al</i> /2019/ Regional anesthesia pain medicine	Original article	USG guided Single shot Transverse thoracic muscle plane block	17	Ropivacaine 0.3% (patients <75 kg) Or 0.5% (patients >75 kg) 40 ml (20 ml on each side)	No block	Lower pain scores in block group at 12 h (both rest and deep breathing). No difference at 24 h	High patient recruitment, adherence and satisfaction rates

USG=Ultrasonography, ICU=Intensive care unit, PONV=Post-operative nausea and vomiting, VAS=Visual analogue scale, PCA=Patient controlled analgesia, NRS=Numeric rating scale, NA=Not applicable

the transverse process is contacted. Then it is walked over the transverse process and advanced till a pop or loss of resistance to air or saline is felt [Figure 1b]. After a thorough negative aspiration local anesthetic is injected or a catheter is inserted 1–3 cm into the TPVS. The extent of spread of local anesthetic in the TPVS is not clear. Evidence suggests that 15–20 ml of 0.375%–0.5% bupivacaine produces effective sensory blockade over 4-5 dermatomes.^[4,6,7] More recently, ultrasound-guided TPVB blocks have been used, which have shown 100% success rate of the block.^[8-10]

The reported advantages of TPVB include a simplicity of technique, safety of performing in sedated and ventilated patients, lower amount of local anesthetic loss in intercostal drains as compared to intrapleural block, a low incidence of complications, facilitation of early mobilization, and early discharge.^[2,11] The feasibility, efficacy, and safety of landmark-guided TPVB in on pump cardiac surgery was first studied by Canto *et al.* in 111 patients (47 after induction of anesthesia and 64 in awake sitting position). They reported lower incidence of complication which included injury to blood vessel, pneumothorax, dura puncture, post-operative paraesthesia, persistent somnolence, and block failure.^[12] Another two studies compared paravertebral block with thoracic epidural anesthesia (TEA).^[13,14] While El shora *et al.* found comparable analgesia in both groups, Oliver and colleagues reported TEA to be superior.^[13,14] This difference may be

justified as due to lack of use of continuous infusion in the later. Further studies are required to support or refute these findings. In a randomized study comparing 50 patients undergoing CABG to either bilateral continuous TPVB or continuous subcutaneous infiltration of local anesthetic, near toxic levels of local anesthetic in blood were found without the benefit of better analgesia.^[15]

Parasternal intercostal block

The procedure of this block involves injection of local anesthetic solution bilaterally on the 2nd to 6th intercostal spaces just before placement of sternal wires.^[16-19] This is usually supplemented with infiltration of local anesthetic solution over the periosteum and infiltration around the chest tubes [Figure 2]. The intercostal injection blocks the anterior cutaneous branch which is the terminal portion of the main trunk of intercostal nerve. Of the available literature, 3 studies compared parasternal local anesthetic injection with placebo.^[16,19,20] One study compared parasternal block with pharmacologic analgesia and another with Trans cutaneous electric nerve stimulation (TENS).^[17,18] Lower pain scores, lower opioid consumption were reported by all authors except Mc Donald and colleagues who could not elicit superiority of pain control in the parasternal block group.^[16] Dogan *et al.* also reported a reduced intensive care unit (ICU) stay in patients receiving parasternal block. However other investigators either did not study this parameter or could not find any difference.

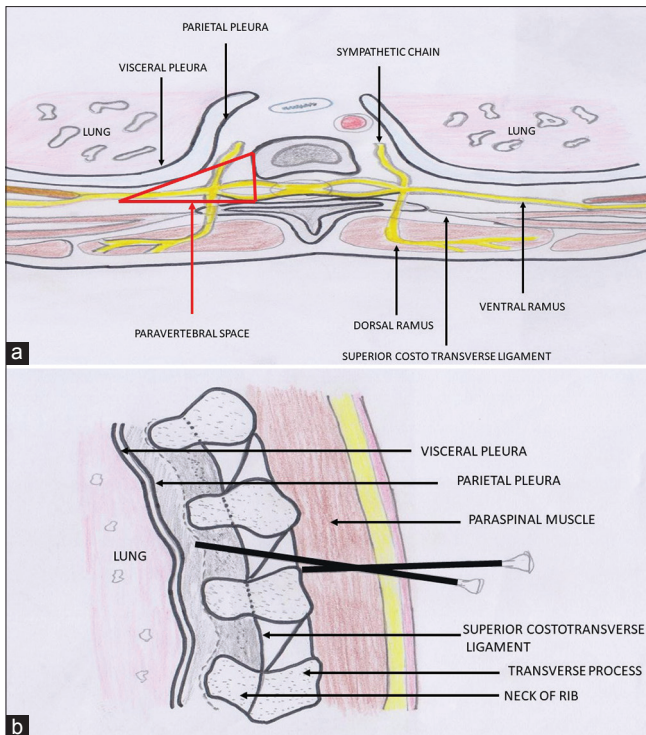


Figure 1: (a) Diagram illustrating the paravertebral space and its boundaries. (b) Sagittal section through paravertebral space showing needle walking over the transverse process and reaching paravertebral space after piercing superior costotransverse ligament (landmark technique)

The major drawback of these studies is the use of single shot parasternal block, which limits its efficacy only to first post-operative day. However, it may still prove helpful in fast tracking of patients by early extubation. Many surgeons are concerned about occurrence of wound complication with the infiltration of large volume of local anesthetic in parasternal block. However, studies have shown that there is no evidence of increased sternal wound infection or dehiscence in a 3-month follow up of patients receiving parasternal block in the perioperative period.^[19]

Fascial plane blocks

Various fascial plane blocks have been described for analgesia of anterior chest wall namely pectoralis nerve block, serratus anterior plane block, erector spinae block, Pecto-intercostal fascial plane block (PIFB), and transverse thoracic muscle plane block (TTP). Although these blocks have been well tested for perioperative analgesia in mastectomy, experience with these blocks for sternotomy pain relief is limited. The major hindrance to the use of these blocks for sternotomy pain relief is the requirement of performing bilateral blocks for optimal result. Very few randomized control trials have compared these fascial blocks with other established method of sternotomy pain relief and none comparing these blocks among themselves. The target nerves and planes of the fascial plane blocks used for sternotomy pain relief are described in Table 2.

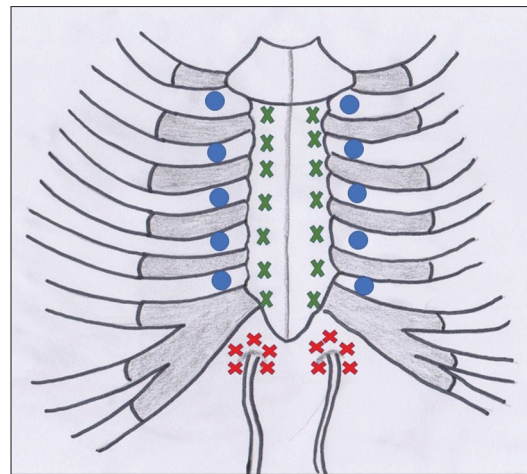


Figure 2: Diagram showing sites of injection in parasternal intercostal block. Blue circles denote injection in the parasternal region of 2nd to 6th intercostal space. Green x denote periosteal infiltration over sternum and red x denote infiltration around chest tubes

Pectoral Nerve block- It is a less invasive, effective, fascial plane block of the thoracic region initially described for breast surgeries.^[21,22] The anatomy of relevant muscles and nerves for pectoral nerve block is shown in Figure 3. The pectoral nerve blocks are mostly done under USG guidance and includes two injections namely PECS 1 and PECS 2. PECS 1 includes injection of drug between pectoralis major (PM) and pectoralis minor (Pm) at the level of 2nd and 3rd rib. It blocks medial pectoral (C8-T1) and lateral pectoral (C5-C7) nerves. PECS 2 includes injection of 20 ml drug between pectoralis minor and serratus anterior at the level of 3rd and 4th rib, in an infero-lateral direction from the PECS1 injection. It blocks intercostal nerves (T2-T6), thoraco dorsal nerve and long thoracic nerve of Bell. PECS 2 is especially useful for pain relief in extensive breast surgery. Bilateral blocks are used for pain relief in sternotomy. Karthik *et al.* used both PECS 1 and 2 blocks in their study and found improved outcomes in terms of analgesia and pulmonary function.^[23] However, the control group in this study did not receive any other block. Thus, it's relative efficacy as compared other modes of regional anesthesia is yet to be proven and further studies are required to reconfirm these findings.

Erector spinae plane (ESP) Block -ESP block is a novel thoracic myofascial plane block. This block is given by injecting local anesthetic into myofascial plane deep to erector spinae muscle at T5/T6 transverse process. The mechanism of analgesic action is believed to result from diffusion of local anesthetic anteriorly to block the ventral and dorsal rami of spinal nerves.^[24,25] The drug is known to spread both in cephalic and caudal directions. While using landmark-guided technique, a point 3 cm lateral to spinous process at T5/T6 level is selected and a needle is inserted perpendicularly from this point to hit the transverse process. After confirming negative

aspiration, 20 ml of local anesthetic is injected. While using USG-guided techniques, a long echogenic needle is inserted 3 cm lateral to T6 spinous process (corresponding to T5 transverse process) under ultrasound guidance until it lies in the plane below erector spinae. The needle traverses three muscles, Trapezius (uppermost), rhomboides major (middle), erector spinae (lowermost) before reaching the desired plane [Figure 4]. After confirming the plane by hydro-dissection a catheter can be placed for continuous infusion. A single injection into this plane gives a spread of analgesia from T2-T12 or L1.^[26] The major advantage of this block is that it produces an effect similar to thoracic paravertebral blockade without the potential danger of needle injuring pleura.^[27] As the sonographic targets in this block are easy to visualize and are away from neuraxis and major vascular structure, it can be easily performed in anticoagulated patients where TEA and PVB are contraindicated.^[26] A case report by Tsui *et al.* was the first literature to demonstrate the efficacy of ESP block in cardiac surgery.^[28] Krishna *et al.* compared single shot ESP block (with 0.375% ropivacaine just before induction) with intravenous analgesia (paracetamol and tramadol). The analgesic duration was limited (8.98 h) due

to lack continuous infusion and was a major drawback of the study.^[29] However, another study by Nagaraja *et al.* compared ESP block with continuous catheter infusion and TEA.^[30] This study found both blocks to be equally efficacious in the initial 12 h after extubation. However, VAS scores in TEA group were found significantly higher at 24, 36, and 48 h, but the mean values in both groups nevertheless remained in the mild pain range (VAS <4). Thus, the statistical difference may not have clinical consequences.

Pecto-intercostal- fascial plane block (PIFB)- Initially described by De la Torre in breast surgeries.^[31] Thereafter it was used for analgesia in sternal fracture.^[32] PIFB aims to block anterior cutaneous branch of the intercostal nerves. This block has only been performed under ultrasound guidance. With the patient in supine position, a high frequency linear ultrasound probe is placed 2 cm lateral to the lateral sternal border at 5th and 6th rib. On the surface plane subcutaneous tissue is identified. Pectoralis major muscle, Intercostal muscles and ribs are seen in intermediate plane and lung along with pleura are identified in deep plane. A 22G 80-mm echogenic

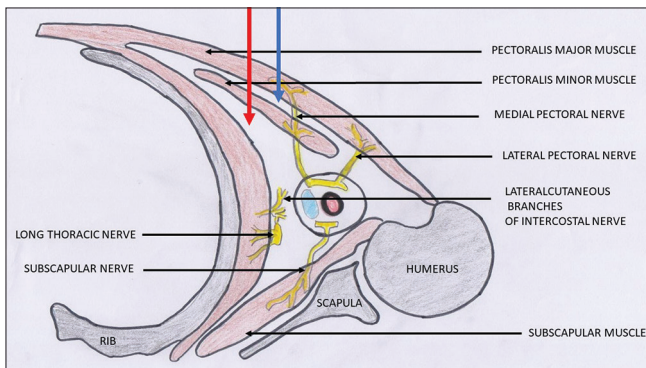


Figure 3: Illustration showing muscles and nerves relevant for pectoral nerve block. The blue and red arrows show the plane for deposition of local anaesthetic in pecs 1 and pecs 2 block, respectively

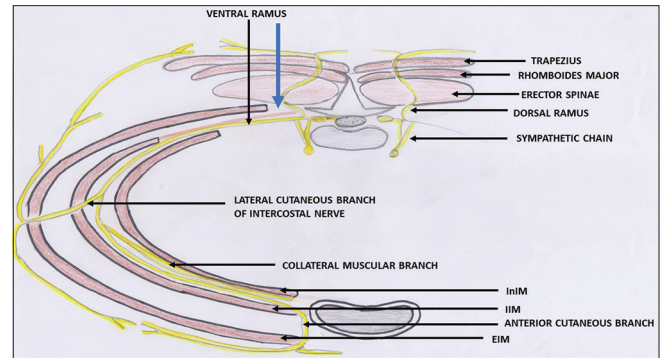


Figure 4: Diagram illustrating the intercostal nerve and its branches. Blue arrow shows the plane for local anesthetic injection in erector spinae block. EIM, external intercostal muscle; IIM, internal intercostal muscle; INIM, innermost intercostal muscle

Table 2: Shows the various fascial plane blocks described for analgesia in sternotomy

Name of the block	First described by	Target nerve	Target plane	Area covered
Pectoral Nerve block	Blanco	PECS 1-lateral and medial pectoral nerves	Between pectoralis major and minor	Anterior chest wall
Includes PECS 1 and PECS 2 (modified PECS 1) ^[21,22]	PECS 1-2011 PECS 2-2012	PECS 2 -Intercostal nerves (T2-T-6) long thoracic nerve of Bell, and thoracodorsal nerve.	Between pectoralis minor and serratus anterior	Anterior and lateral part of chest and axilla
Erector Spinae block ^[27]	Forrero 2016	Dorsal and ventral rami of spinal nerve roots	Deep to erector spinae muscle at the level of T6 transverse process	Anterior and posterior chest wall, axilla and medial aspect of upper arm.
Pecto-intercostal- fascial plane block (PIFB) ^[31]	De la Torre, 2014	Anterior cutaneous branches of intercostal nerve	Between pectoralis major and external intercostal muscle, on lateral side of sternal margin	Medial part of chest wall
Transverse thoracic muscle plane block ^[34]	Ueshima 2015	Multiple anterior cutaneous branches of Thoracic 2-6 segments	Between transverse thoracic muscle and intercostal muscle	Medial part of chest wall including internal mammary area

needle is inserted and advanced till it lies in the plane between pectoralis major and internal intercostal muscle. Some authors also describe deposition of drug between pectoralis major and external intercostal aponeurosis. Six to seven ml of drug is injected and hydro dissection of the plane is checked for. The needle is then repositioned in a cephalad direction to target each rib space till 1st and 2nd rib space. Alternatively, large amount of drug (40 ml of 0.125% bupivacaine) can be injected into pecto intercostal plane to cause hydro-dissection and a catheter can be placed for continuous infusion. The nerve anatomy relevant to PIFB and plane for drug deposition is shown in Figure 5a and b, respectively. In a case report authored by Victor Liu *et al.* immediate analgesia with improved haemodynamics and reduced analgesic requirement was reported in a patient who received PIFB for acute post-operative pain.^[33]

Transverse thoracic muscle plane block (TTP)- This block is performed under USG guidance by inserting a needle in the anterior 4th-5th rib interspace and placing it between transversus thoracic muscle and internal intercostal muscle [Figure 6]. After confirming the plane with hydro dissection, either single bolus injection of large volume local anesthetic (20 ml on either side of sternum) or a continuous infusion by catheter can be used for producing analgesia. It blocks the anterior branch of thoracic intercostal nerves (T2-6).^[34] Earlier case reports described both single shot and continuous catheter infusions for sternotomy pain relief and were found to be efficacious.^[35,36] Recently Fuji *et al.* conducted a pilot feasibility study randomizing the patients to receive either TTP block or standard care. The results revealed a high

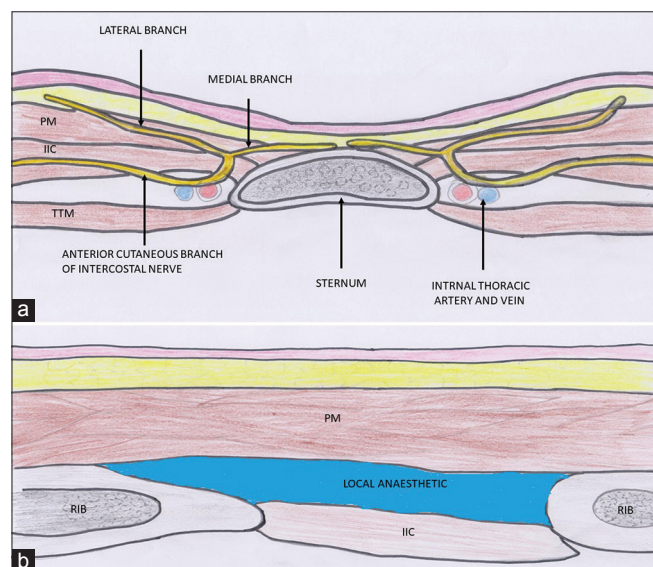


Figure 5: (a) Figure illustrating intercostal nerve anatomy in the parasternal region relevant for PIFB. PM, pectoralis major; IIM, internal intercostal muscle; TTM, transverse thoracic muscle. (b) Illustration showing drug deposition of drug between pectoralis major (PM) and internal intercostal muscle (IIM) during administration of Pecto-intercosto fascial block (PIFB)

patient recruitment, adherence, and satisfaction rate.^[37] A possible limitation of TTP block may be disruption of the plane during internal mammary artery (IMA) harvesting (because the IMA courses in this plane) leading to non-spread of injectate between the desired thoracic levels.^[38] Although known by different nomenclature, many of the above-mentioned blocks actually aim at anesthetizing anterior cutaneous branches. Literature in the recent past have also questioned the difference between these blocks.^[39]

Limitation- One of the major limitations of this review is inability to synthesize a quantitative result due to heterogeneity and paucity of literature. Further well designed, randomized control trials in homogenous cardiac surgery population comparing these regional blocks with established techniques or among themselves would be required to find the technique with maximum efficacy.

Conclusion

Because of the widespread availability of USG in the operating room and improving skills of anesthesiologist, there is a significant increase in the performance of regional blocks in the general anesthetic practice. However, literature pertaining to these blocks for sternotomy pain relief is still scarce and heterogenous. Although most regional methods in this review were found to be at par or even better than conventional methods of analgesia, the superiority of one method over other could not be proven due to diverse nature of the available studies. The main aim of this review was to bring together all the information in a systematically arranged fashion to facilitate decision making amongst anesthesiologists who wish to use these blocks in their clinical practice.

Acknowledgement

We would like to thank Master Nayan Saha for his contribution in preparing diagrams for the article.

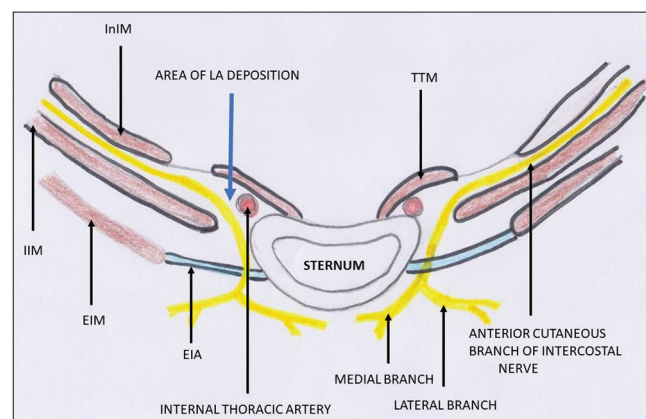


Figure 6: Illustration showing relevant nerve and muscle anatomy for TTP block. EIM, external intercostal muscle; IIM, internal intercostal muscle; INIM, innermost intercostal muscle; TTM, transverse thoracic muscle; EIA, external intercostal aponeurosis

Financial support and sponsorship

Nil.

Conflicts of interest

There are no conflicts of interest.

References

- Davies F, Gladstone RJ, Stibbe EP. The anatomy of the intercostal nerves. *J Anat* 1932;66:323-33.
- Karmakar MK. Thoracic paravertebral block. *Anesthesiology* 2001;95:771-80.
- Kittredge RD. Computed tomographic evaluation of the thoracic prevertebral and paravertebral spaces. *J Comput Tomogr* 1983;7:239-50.
- Eason MJ, Wyatt R. Paravertebral thoracic block—A reappraisal. *Anaesthesia* 1979;34:638-42.
- Nunn JF, Slavin G. Posterior intercostal nerve block for pain relief after cholecystectomy. Anatomical basis and efficacy. *Br J Anaesth* 1980;52:253-60.
- Pusch F, Freitag H, Weinstabl C, Obwegeser R, Huber E, Wildling E, *et al.* Single-injection paravertebral block compared to general anaesthesia in breast surgery. *Acta Anaesthesiol Scand* 1999;43:770-4.
- Cheema SP, Ilsley D, Richardson J, Sabanathan S. A thermographic study of paravertebral analgesia. *Anaesthesia* 1995;50:118-21.
- SC OR, Donnell BO, Cuffè T, Harmon DC, Fraher JP, Shorten G. Thoracic paravertebral block using real-time ultrasound guidance. *Anesth Analg* 2010;110:248-51.
- Bouzinac A, Delbos A, Mazieres M, Rontes O. Interest of ultrasound in the realization of thoracic paravertebral block in breast surgery. *Ann Fr Anesth Reanim* 2011;30:453-5.
- Abdallah FW, Brull R. Off side! A simple modification to the parasagittal in-plane approach for paravertebral block. *Reg Anesth Pain Med* 2014;39:240-2.
- Ganapathy S, Nielsen KC, Steele SM. Outcomes after paravertebral blocks. *Int Anesthesiol Clin* 2005;43:185-93.
- Canto M, Sanchez MJ, Casas MA, Bataller ML. Bilateral paravertebral blockade for conventional cardiac surgery. *Anaesthesia* 2003;58:365-70.
- El Shora HA, El Beleehy AA, Abdelwahab AA, Ali GA, Omran TE, Hassan EA, *et al.* Bilateral paravertebral block versus thoracic epidural analgesia for pain control post-cardiac surgery: A randomized controlled trial. *Thorac Cardiovasc Surg* 2018. doi: 10.1055/s-0038-1668496.
- Olivier JF, Bracco D, Nguyen P, Le N, Noiseux N, Hemmerling T. A novel approach for pain management in cardiac surgery via median sternotomy: Bilateral single-shot paravertebral blocks. *Heart Surg Forum* 2007;10:E357-62.
- Lockwood GG, Cabrerros L, Banach D, Punjabi PP. Continuous bilateral thoracic paravertebral blockade for analgesia after cardiac surgery: A randomised, controlled trial. *Perfusion* 2017;32:591-7.
- McDonald SB, Jacobsohn E, Kopacz DJ, Desphande S, Helman JD, Salinas F, *et al.* Parasternal block and local anesthetic infiltration with levobupivacaine after cardiac surgery with desflurane: The effect on postoperative pain, pulmonary function, and tracheal extubation times. *Anesth Analg* 2005;100:25-32.
- Dogan Baki E, Kavrut Ozturk N, Ayoglu RU, Emmiler M, Karsli B, Uzel H. Effects of parasternal block on acute and chronic pain in patients undergoing coronary artery surgery. *Semin Cardiothorac Vasc Anesth* 2016;20:205-12.
- Ozturk NK, Baki ED, Kavakli AS, Sahin AS, Ayoglu RU, Karaveli A, *et al.* Comparison of transcutaneous electrical nerve stimulation and parasternal block for postoperative pain management after cardiac surgery. *Pain Res Manag* 2016;2016:4261949.
- Barr AM, Tutungi E, Almeida AA. Parasternal intercostal block with ropivacaine for pain management after cardiac surgery: A double-blind, randomized, controlled trial. *J Cardiothorac Vasc Anesth* 2007;21:547-53.
- Lee CY, Robinson DA, Johnson CA Jr, Zhang Y, Wong J, Joshi DJ, *et al.* A randomized controlled trial of liposomal bupivacaine parasternal intercostal block for sternotomy. *Ann Thorac Surg* 2019;107:128-34.
- Blanco R. The 'pecs block': A novel technique for providing analgesia after breast surgery. *Anaesthesia* 2011;66:847-8.
- Blanco R, Fajardo M, Parras Maldonado T. Ultrasound description of Pecs II (modified Pecs I): A novel approach to breast surgery. *Rev Esp Anesthesiol Reanim* 2012;59:470-5.
- Kumar KN, Kalyane RN, Singh NG, Nagaraja PS, Krishna M, Babu B, *et al.* Efficacy of bilateral pectoralis nerve block for ultrafast tracking and postoperative pain management in cardiac surgery. *Ann Card Anaesth* 2018;21:333-8.
- Chin KJ, Adhikary S, Sarwani N, Forero M. The analgesic efficacy of pre-operative bilateral erector spinae plane (ESP) blocks in patients having ventral hernia repair. *Anaesthesia* 2017;72:452-60.
- Ivanusic J, Konishi Y, Barrington MJ. A Cadaveric study investigating the mechanism of action of erector spinae blockade. *Reg Anesth Pain Med* 2018;43:567-71.
- Leyva FM, Mendiola WE, Bonilla AJ, Cubillos J, Moreno DA, Chin KJ. Continuous erector spinae plane (ESP) block for postoperative analgesia after minimally invasive mitral valve surgery. *J Cardiothorac Vasc Anesth* 2018;32:2271-74.
- Forero M, Adhikary SD, Lopez H, Tsui C, Chin KJ. The erector spinae plane block: A novel analgesic technique in thoracic neuropathic pain. *Reg Anesth Pain Med* 2016;41:621-7.
- Tsui BCH, Navaratnam M, Boltz G, Maeda K, Caruso TJ. Bilateral automatized intermittent bolus erector spinae plane analgesic blocks for sternotomy in a cardiac patient who underwent cardiopulmonary bypass: A new era of cardiac regional anesthesia. *J Clin Anesth* 2018;48:9-10.
- Krishna SN, Chauhan S, Bhoi D, Kaushal B, Hasija S, Sangdup T, *et al.* Bilateral erector spinae plane block for acute post-surgical pain in adult cardiac surgical patients: A randomized controlled trial. *J Cardiothorac Vasc Anesth* 2019;33:368-75.
- Nagaraja PS, Ragavendran S, Singh NG, Asai O, Bhavya G, Manjunath N, *et al.* Comparison of continuous thoracic epidural analgesia with bilateral erector spinae plane block for perioperative pain management in cardiac surgery. *Ann Card Anaesth* 2018;21:323-77.
- de la Torre PA, Garcia PD, Alvarez SL, Miguel FJ, Perez MF. A novel ultrasound-guided block: A promising alternative for breast analgesia. *Aesthet Surg J* 2014;34:198-200.
- Raza I, Narayanan M, Venkataraju A, Ciocarlan A. Bilateral subpectoral interfascial plane catheters for analgesia for sternal fractures: A case report. *Reg Anesth Pain Med* 2016;41:607-9.
- Liu V, Mariano ER, Prabhakar C. Pecto-intercostal fascial block for acute poststernotomy pain: A case report. *A A Pract* 2018;101:319-22.
- Ueshima H, Kitamura A. Blocking of multiple anterior branches of intercostal nerves (Th2-6) using a transversus thoracic muscle plane block. *Reg Anesth Pain Med* 2015;40:388.
- Ueshima H, Hara E, Marui T, Otake H. The ultrasound-guided transversus thoracic muscle plane block is effective for the median sternotomy. *J Clin Anesth* 2016;29:83.
- Ueshima H, Otake H. Continuous transversus thoracic muscle plane block is effective for the median sternotomy. *J Clin Anesth* 2017;37:174.
- Fujii S, Roche M, Jones PM, Vissa D, Bainbridge D, Zhou JR. Transversus thoracis muscle plane block in cardiac surgery: A pilot feasibility study. *Reg Anesth Pain Med* 2019;44:556-60.
- Fujii S, Vissa D, Ganapathy S, Johnson M, Zhou J. Transversus thoracic muscle plane block on a cadaver with history of coronary artery bypass grafting. *Reg Anesth Pain Med* 2017;42:535-7.
- Del Buono R, Costa F, Agro FE. Parasternal, pecto-intercostal, pecs, and transverse thoracic muscle plane blocks: A rose by any other name would smell as sweet. *Reg Anesth Pain Med* 2016;41:791-2.