

Against the Odds: Massive Lumbar Intradural Disk Herniation in the Elderly

Berk Orakcioglu¹ Huy Philip Dao Trong¹ Christine Jungk¹ Andreas Unterberg¹

¹Department of Neurosurgery, University Hospital of Heidelberg, Heidelberg, Germany

Address for correspondence Berk Orakcioglu, MD, Department of Neurosurgery, University Hospital of Heidelberg, Im Neuenheimer Feld 400, 69120 Heidelberg, Germany (e-mail: berk.orakcioglu@med.uni-heidelberg.de).

Global Spine J 2015;5:e84–e87.

Abstract

Study Design Case report.

Objective Presentation of an unusual case of an elderly patient with massive intradural disk herniation at the L2–L3 level.

Methods Clinical and imaging data are presented after obtaining informed consent from the patient.

Results A 90-year-old man suffering from sudden-onset neurogenic bladder dysfunction and lower back pain but no further neurologic deficits initially presented with magnetic resonance imaging and laboratory values suggestive of an intraspinal infection. However, intraoperative inspection proved the unexpected finding of a large intradural lumbar disk herniation at the L2–L3 level.

Conclusions Lumbar soft disk herniation to the intradural space is a rare event and has never been described in a patient over the age of 75. This case of a 90-year-old man with acute-onset bladder dysfunction underlines the necessity to consider this as a differential diagnosis in the case of a newly diagnosed intradural mass.

Keywords

- ▶ lumbar disk herniation
- ▶ intradural

Introduction

Intradural lumbar disk herniation is rarely encountered in the clinical routine.^{1,2} Especially in the elderly population, isolated lumbar soft disk herniation is unlikely because chronic degenerative processes lower its likelihood. The reported mean ages for isolated lumbar disk herniations from large prospective cohorts range between 42 and 48 years.³ For this reason, intradural disk herniation is not primarily considered as a differential diagnosis once an intradural mass has been depicted on lumbar MRI. In even rarer instances, intradural disk herniations are related to trauma.^{4,5} Here, we report an unusual case of a 90-year-old man undergoing emergency surgical procedure because of acute-onset neurogenic bladder dysfunction due to an intradural mass at the L2–L3 level with suspected intradural infection. However, intraoperative inspection proved the presence of intradural soft disk herniation. To our knowledge, this is the first report of lumbar intradural disk herniation in a patient over the age of 75.^{1,6–16}

Case Report

A 90-year-old man with a 10-day history of lower back pain presented to our emergency department. A thorough physical examination revealed no sensorimotor deficits. However, an acute neurogenic bladder dysfunction was diagnosed with elevated creatinine levels (4.89 mg/dL; 0.5 to 1.2 mg/dL) and urea levels as high as 130 mg/dL (10.0 to 55.0 mg/dL). Furthermore, the serologic parameters were suggestive of an acute bacterial infection (C-reactive protein 100 mg/dL [<5 mg/dL], procalcitonin 9.81 ng/dL [<0.05 ng/dL]). This led to the assumption of an intraspinal infection with the absence of overt back pain, radicular sensorimotor deficits, or cauda equina symptoms other than neurogenic bladder dysfunction. In fact, emergency lumbar computed tomography (CT) scan and 3-T magnetic resonance imaging (MRI) images revealed a mass at L2–L3 protruding into the dural sac (▶ **Fig. 1**). On T2-weighted axial MRI images, the cauda equina was compressed by this mass (▶ **Fig. 2**). A “hawk-beak sign” as

received
April 10, 2014
accepted after revision
January 16, 2015
published online
February 27, 2015

DOI <http://dx.doi.org/10.1055/s-0035-1546952>.
ISSN 2192-5682.

© 2015 Georg Thieme Verlag KG
Stuttgart · New York

License terms



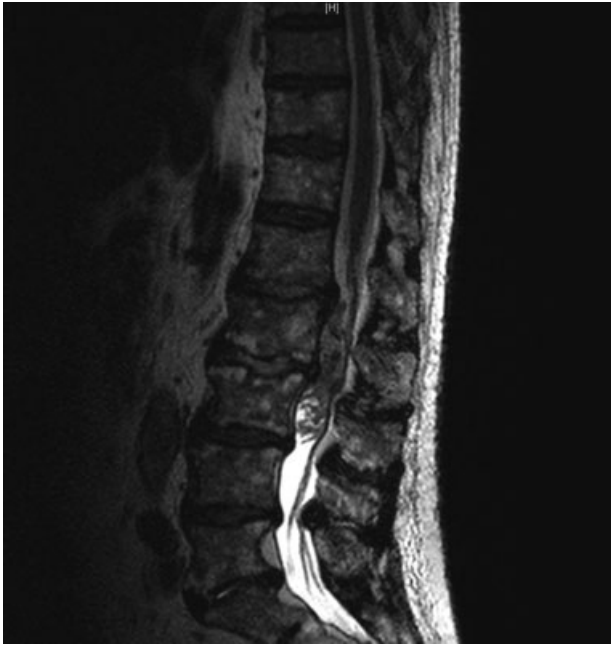

Fig. 1 Sagittal T2-weighted lumbar magnetic resonance image. A large mass of unclear origin was identified at the L2-L3 level.

described by others was not detected.¹ Application of gadolinium for contrast enhancement had to be avoided because of the patient's renal dysfunction. On CT scans, intraspinal and intervertebral gas was identified (→**Fig. 3**) and was attributed to a possible spinal infection by gas-forming bacteria.

Because of the patient's age, and to achieve maximum decompression of neural structures, a laminectomy over L2-L3 was performed by a posterior midline approach as an emergency procedure. As a first step, the dural sac was carefully mobilized medially from the left. Despite a thorough epidural inspection, no signs of infection or herniated disk were revealed; nevertheless, a standard nucleotomy was

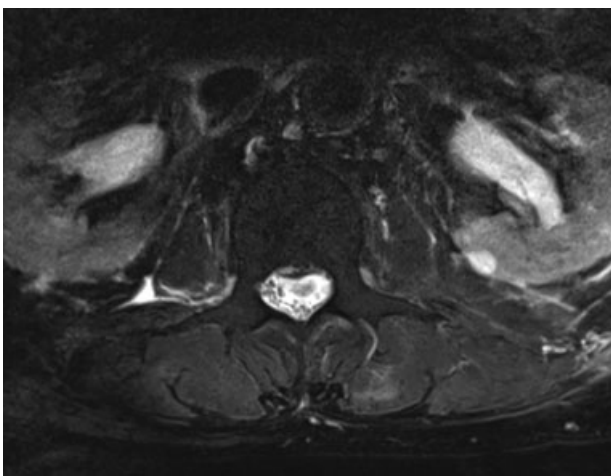


Fig. 2 Axial T2-weighted lumbar magnetic resonance image at the L2-L3 level. The cauda equina is highly compressed with the fascicles being pushed laterally and posteriorly by the mass.

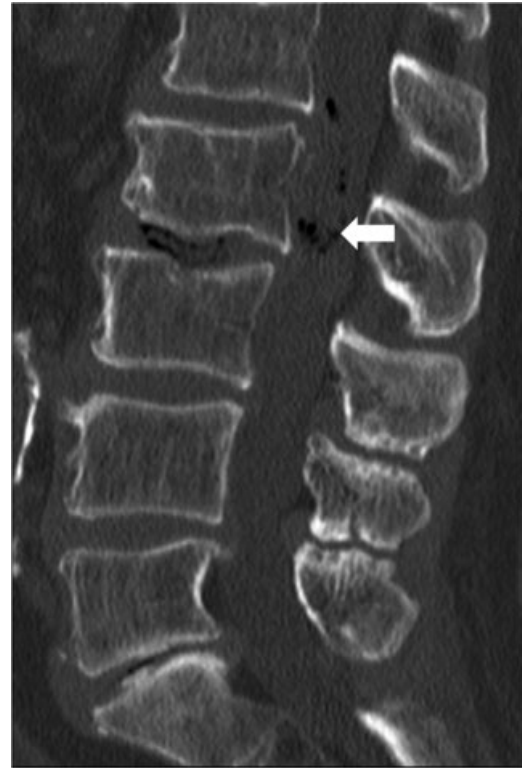

Fig. 3 Sagittal bone window of lumbar computed tomography scan. The vacuum phenomenon with evidence of intraspinal gas present at L2-L3 was initially attributed to gas-forming bacteria as spinal infection was suspected based on clinical presentation and pathologic laboratory values (arrow).

performed. At this point, the decision was made to open the dural sac via a midline incision for intradural inspection. As depicted in →**Figs. 4, 5, and 6**, the lumbar fascicles became visible immediately below the dural surface and, to our surprise, careful microsurgical dissection of the fascicles revealed a massive intradural disk herniation. After complete removal of all intradural soft disk material, a dural defect

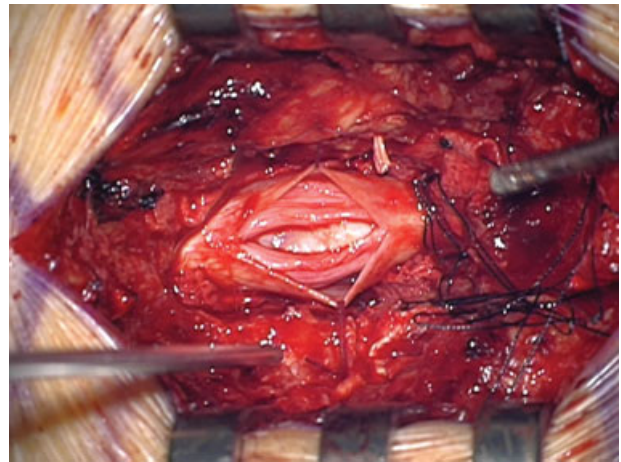


Fig. 4 Midline dural incision at the L2-L3 level. Dural edges are tied aside exposing the intradural mass that stretches the lumbar fascicles of the cauda equina. Note the discoloration of the exposed fascicles irritated by the local mass effect.

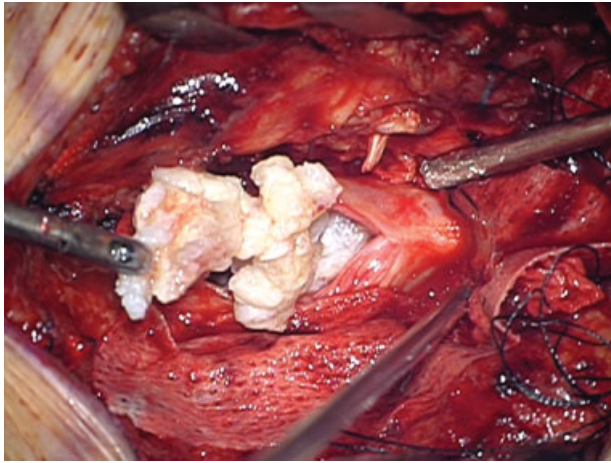


Fig. 5 Removal of the herniated soft disk fragments. No adhesions to neural or dural structures were observed so that the fragments could be freely removed.

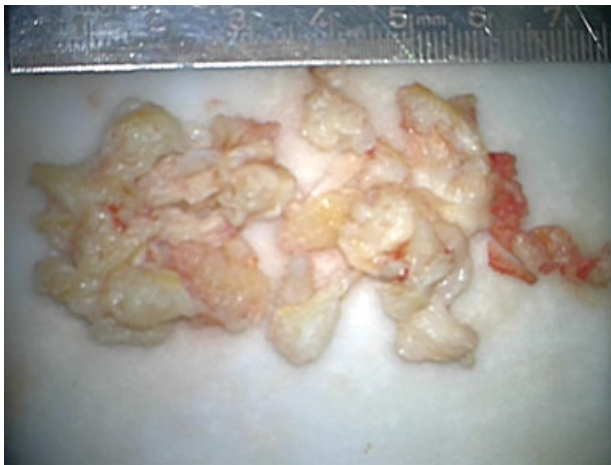

Fig. 6 Completely resected soft disk material.

exactly posterior to the L2–L3 disk space of ~1 cm length was identified and closed with resorbable sutures. There was no evidence of intradural infection, and postoperative histopathologic analysis confirmed the intraoperative finding of soft disk fragments.

After an uneventful postoperative course of 7 days, the patient was discharged to a rehabilitation unit. The neurogenic bladder dysfunction remained at discharge, but both his serologic infection and renal parameters declined rapidly without any specific treatment. At 6 months' follow-up, the patient was fully mobile without any sensorimotor deficit, but he had residual bladder dysfunction. Death occurred due to cardiac disease 1.5 years following surgery.

Discussion

In this report, we present a rare and unexpected case of intradural lumbar disk herniation in an elderly patient. Although clinical symptoms, CT scans, and MRI were not highly suspicious of an intraspinal infection, it was discussed

as the primary differential diagnosis because laboratory parameters were suggestive of a bacterial infection. Unexpectedly, the intraoperative findings demonstrated a massive intradural disk herniation.

In a small case series of nine patients presenting with intradural disk herniation reported by D'Andrea et al, the mean patient age was ~10 years higher than in their series of patients with extradural lumbar disk herniation.¹ This may suggest that higher age predisposes to intradural rather than extradural disk herniation, possibly due to the dural sheaths being worn out with progressive spinal degeneration. Others have reported cases of traumatic intradural disk rupture in younger patients as well.^{4,5} To our knowledge, so far no case of intradural disk herniation has been reported in a patient over the age of 75.^{1,6–16} This may well account to the fact that intradural disk herniation is a rare event in general with approximately 150 reported cases in the literature so far.² However, due to the ongoing demographic shift, more and more elderly patients will demand spinal surgery and, as our case report demonstrates, intradural disk herniation has to be considered as a differential diagnosis even in the aging population. As contrast media was not applied in our patient due to underlying renal dysfunction, we cannot state whether contrast-enhanced scans would have helped to improve the preoperative diagnostic reliability. In other reports, circular contrast enhancement is ascribed to intradural disk herniations.^{17,18} In retrospect, elevation of serologic infection parameters (C-reactive protein, procalcitonin) was attributable to accumulation due to the patient's renal dysfunction and declined rapidly after surgery without any specific antibiotic treatment. Noteworthy, the presence of intraspinal gas on the lumbar CT scans should alert the surgeon to further inspect the intradural space to exclude an intradural disk herniation especially when insufficient extradural disk material is found.^{7,8,15}

In our case, the implication for treatment decision remains low, as the clinical presentation with acute onset bladder dysfunction made emergency surgical intervention mandatory. It has been reported by other authors, however, that even intradurally herniated disk fragments may resolve over time without any operative intervention.¹⁹ As it is generally accepted in lumbar degenerative disk disease, it thus seems advisable to recommend surgery only in those cases with suspected intradural disk herniation in which progressive neurologic symptoms or radicular pain nonresponsive to conservative treatment are present.

Taken together, even though lumbar soft disk herniation to the intradural space is a rare event and has never been described in a patient over the age of 75, our case of a 90-year-old man with acute bladder dysfunction without further neurologic deficits underlines the necessity to consider this as a differential diagnosis.

Disclosures

Berk Orakcioglu, none
 Huy Philip Dao Trong, none
 Christine Jungk, none
 Andreas Unterberg, none

References

- 1 D'Andrea G, Trillò G, Roperto R, Celli P, Orlando ER, Ferrante L. Intradural lumbar disc herniations: the role of MRI in preoperative diagnosis and review of the literature. *Neurosurg Rev* 2004;27(2):75–80, discussion 81–82
- 2 Krajewski K, Regelsberger J. Intradural lumbar disc herniation associated with degenerative spine disease and rheumatoid arthritis. *Spine (Phila Pa 1976)* 2013;38(12):E763–E765
- 3 Golinvaux NS, Bohl DD, Basques BA, Yacob A, Grauer JN. Comparison of the lumbar disc herniation patients randomized in SPORT to 6,846 discectomy patients from NSQIP: demographics, perioperative variables, and complications correlate well. *Spine J* 2014; December 11 (Epub ahead of print)
- 4 Kobayashi K, Imagama S, Matsubara Y, et al. Intradural disc herniation: radiographic findings and surgical results with a literature review. *Clin Neurol Neurosurg* 2014;125:47–51
- 5 Jain SK, Sundar IV, Sharma V, Goel RS, Gupta R. Intradural disc herniation—a case report. *Turk Neurosurg* 2013;23(3):389–391
- 6 Singh PK, Shrivastava S, Dulani R, Banode P, Gupta S. Dorsal herniation of cauda equina due to sequestered intradural disc. *Asian Spine J* 2012;6(2):145–147
- 7 Hidalgo-Ovejero AM, García-Mata S, Gozzi-Vallejo S, Izco-Cabezón T, Martínez-Morentín J, Martínez-Grande M. Intradural disc herniation and epidural gas: something more than a casual association? *Spine (Phila Pa 1976)* 2004;29(20):E463–E467
- 8 Anda S, Dale LG, Vassal J. Intradural disc herniation with vacuum phenomenon: CT diagnosis. *Neuroradiology* 1987;29(4):407
- 9 Epstein NE, Syrquin MS, Epstein JA, Decker RE. Intradural disc herniations in the cervical, thoracic, and lumbar spine: report of three cases and review of the literature. *J Spinal Disord* 1990;3(4):396–403
- 10 Jenkins LE, Bowman M, Cotler HB, Gildenberg PL. Intradural herniation of a lumbar intervertebral disc. *J Spinal Disord* 1989;2(3):196–200
- 11 De Palma L. Intradural lumbar disc hernia. Report of two cases. *Ital J Orthop Traumatol* 1976;2(3):421–428
- 12 Kataoka O, Nishibayashi Y, Sho T. Intradural lumbar disc herniation. Report of three cases with a review of the literature. *Spine (Phila Pa 1976)* 1989;14(5):529–533
- 13 Mailleux R, Redant C, Milbouw G. MR diagnosis of transdural disc herniation causing cauda equine syndrome. *JBR-BTR* 2006;89(6):303–305
- 14 Sasaji T, Horaguchi K, Yamada N, Iwai K. The specific sagittal magnetic resonance imaging of intradural extra-arachnoid lumbar disc herniation. *Case Rep Med* 2012;2012:383451
- 15 Reina EG, Calonge ER, Heriot RP. Transdural lumbar disc herniation. *Spine (Phila Pa 1976)* 1994;19(5):617–619
- 16 Choi JY, Lee WS, Sung KH. Intradural lumbar disc herniation—is it predictable preoperatively? A report of two cases. *Spine J* 2007;7(1):111–117
- 17 Whittaker CK, Bernhardt M. Magnetic resonance imaging shows gadolinium enhancement of intradural herniated disc. *Spine (Phila Pa 1976)* 1994;19(13):1505–1507
- 18 Snow RD, Williams JP, Weber ED, Richardson PH. Enhancing transdural lumbar disk herniation. *Clin Imaging* 1995;19(1):12–16
- 19 Borota L, Jonasson P, Agolli A. Spontaneous resorption of intradural lumbar disc fragments. *Spine J* 2008;8(2):397–403