

OPEN

# Dermoid Cyst of Nasal Tip and Nasal Septum

He Zhao, MD, Zhiwei Cao, PhD, and Zhaowei Gu, PhD

**Abstract:** Dermoid cyst is a congenital and benign disease with most occur on the head and neck. It is rarely that occur on the nasal tip and nasal septum at same time and rarely repair of using nasal septum mucosa. The authors treated a child with dermoid cyst in the nasal tip and septum. Only the dermoid cyst at the tip of the nose caused the change of appearance. Dermoid cyst of nasal septum did not cause any clinical symptoms. She underwent excision of the dermoid cyst at the tip of the nose and endoscopic surgery for the dermoid cyst in the nasal septum and used the nasal septum mucosa for repair at the same time. After 6 months of recovery, the appearance of the nasal tip recovered well without obvious scar, the nasal septum area recovered well, and the local stoma was unobstructed without recurrence. The authors found that this kind of nasal septal cyst with no clinical symptoms can achieve good therapeutic effect through endoscopic surgery and repair of using nasal septum mucosa, with less damage, rapid recovery, and good prognosis.

**Key Words:** Case report, dermoid cyst, nasal tip mass, surgery

Dermoid cyst is a congenital disease, but not all of them are diagnosed at birth, often located in the subcutaneous, occasionally seen in submucosal or internal organs. Cysts may contain different components, such as teeth, nails, and cartilage like or bone like structures. Dermoid cyst is a benign and often occur on the head and neck, but it is very difficult to find 2 isolated dermoid cysts at the same time.<sup>1-4</sup> We present a child with dermoid cyst of nasal tip and nasal septum without communication, she accepted the endoscopic

From the Department of Otolaryngology Head and Neck Surgery, Shengjing Hospital of China Medical University, Shenyang, China. Received September 21, 2021.

Accepted for publication September 29, 2021.

Address correspondence and reprint requests to Zhaowei Gu, PhD, Department of Otolaryngology Head and Neck Surgery, Shengjing Hospital of China Medical University, No. 36, Sanhao Street, Heping District, Shenyang 110004, Liaoning, China; E-mail: zwgu@cmu.edu.cn

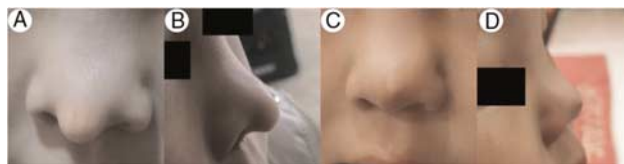
The authors report no conflicts of interest.

This is an open-access article distributed under the terms of the Creative Commons Attribution-Non Commercial-No Derivatives License 4.0 (CCBY-NC-ND), where it is permissible to download and share the work provided it is properly cited. The work cannot be changed in any way or used commercially without permission from the journal. Supplemental digital contents are available for this article. Direct URL citations appear in the printed text and are provided in the HTML and PDF versions of this article on the journal's Web site ([www.jcraniofacialsurgery.com](http://www.jcraniofacialsurgery.com)).

Copyright © 2021 The Author(s). Published by Wolters Kluwer Health, Inc. on behalf of Mutaz B. Habal, MD

ISSN: 1049-2275

DOI: 10.1097/SCS.00000000000008281



**FIGURE 1.** Photos of nose before and after operation. (A) and (B) are preoperative pictures of the face. (C) and (D) are postoperative pictures of the face.

surgery of nasal septum and surgical resection of the dermoid cyst through the skin of nasal tip.

## CLINICAL PRESENTATION

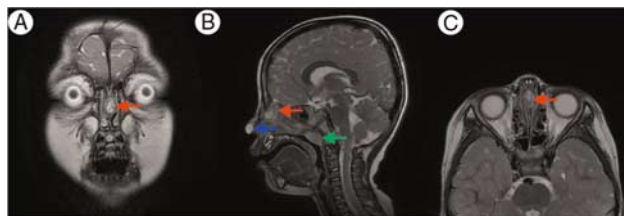
Chief complaint: painless nasal tip mass was found for half a year.

Current medical history: a 6-year-old girl was admitted to the hospital with the chief complaint of finding nasal tip tumor for half a year. Half a year ago, the family members of the patient accidentally found a white tumor on the nasal tip of the child, about the size of a small grain of rice, without tenderness, which was not treated; in the past half a year, it grew gradually, now about the size of a peanut seed, and during this period, it broke repeatedly and flowed out of the white content; now the patient was admitted to the hospital for the removal of the nasal tip tumor. After admission, perfect magnetic resonance imaging (MRI) examination showed nasal tip tumor, considering skin itching cyst, middle and upper nasal septum tumor, considering cystic possibility.

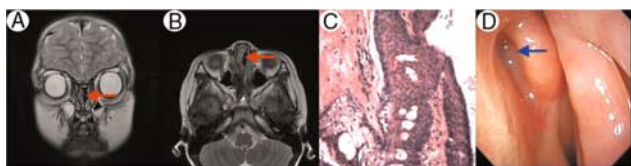
Past history: full term, natural birth, and healthy.

Special physical examination: nose shape is right, septum is not biased, double inferior turbinate is not big, bilateral nasal cavity is unobstructed, spherical protrusion can be seen at the tip of the nose, about 1.5 \* 1.5 cm, smooth surface, no swelling and tenderness (Fig. 1A-B).

Imaging examination: computed tomography (CT) showed oval like soft tissue density shadow beside nasal septum with clear boundary. Round soft tissue shadow was seen in the subcutaneous part of the nasal tip with unclear boundary. Adenoid hypertrophy of nasopharynx. MRI examination showed: T1 sequence: irregular soft tissue signal shadow was found in nasal septum, about 15 × 10 mm, showing low signal, no connection with abnormal signal shadow of nasal tip, close connection with skull base, no cerebrospinal fluid communication. Nodular shadow was found in subcutaneous soft tissue of nasal tip, about 9 mm. Low signal. T2 sequence: soft tissue signal shadow was seen in nasal septum, showing moderate signal. Subcutaneous soft tissue shadow of nasal tip showed high signal. Adenoid hypertrophy of nasopharynx (Fig. 2A-C).



**FIGURE 2.** Images of T2 sequences in MRI before operation. The red arrow is the dermoid cyst of nasal septum. The blue arrow is a dermoid cyst at the tip of the nose. The green arrow is the hypertrophic adenoid tissue. MRI, magnetic resonance imaging.



**FIGURE 3.** Images of T2 sequences in MRI, pathology, and nasal endoscopy after operation. The red arrows in (A) and (B) are the postoperative changes of nasal septal dermoid cyst. (C) is the pathological image taken with an optical microscope a 100-times magnification. (D) is the picture of nasal endoscopy at half a year after operation. The blue arrow is the nasal septum dermoid cyst stoma and surgical site. MRI, magnetic resonance imaging.

**Pathological examination:** the content of the resected cystic masses in the nasal septum and nasal tip was a little keratinization and no structure. Microscopically, the fibrous capsule wall was lined with squamous epithelium, and skin appendages were seen. The final diagnosis of nasal septum and nasal tip dermoid cyst (Fig. 3C).

**Operation process:** on April 23, 2020, the patient received endoscopic excision of septal dermoid cyst, endoscopic adenoidectomy and nasal tip tumor under general anesthesia. After the skin disinfection and sterile sheet, the smooth tumor at the tip of the nose was seen. The skin was cut, the tumor was separated, the boundary was clear, the tumor was resected and sent to pathology, electrocoagulation was used to stop bleeding, the redundant skin was resected, the subcutaneous skin was sutured with absorbable hemostatic suture, and the skin was sutured with cosmetic suture. Under nasal endoscopy, the swelling of both sides of the anterior and upper part of the septum was observed. Hemostatic water was injected under the mucosa. The mucosa was cut to separate the septum mucosa from the cartilage and the vertical plate of the ethmoid bone. The vertical plate of the ethmoid bone bulged to both sides. The left bone was removed. The tumor was white. The tumor was removed and sent to pathology. The tumor and capsule were removed along the boundary of the tumor and sent to pathology. After ablation, the nasal septum mucosa was cut to cover the skull base wound, and the gelatin sponge was used to fill the wound (Supplemental Digital Content, Video 1, <http://links.lww.com/SCS/D432>). Under nasal endoscopy, adenoid hypertrophy was found to block the posterior nostril, and the hypertrophic adenoid was removed by plasma.

**Follow up and reexamination:** the suture of nasal tip was removed 1 week after operation, and nasal endoscopy and enhanced MRI were reexamined half a year after operation. The shape of the nasal tip recovered well (Fig. 1C-D), the upper part of the left nasal septum was covered with mucosa, and the nasopharynx was smooth (Fig. 3D). MRI showed no abnormal signal shadow in the nasal septum and no abnormal signal shadow in the nasal tip (Fig. 3A-B).

## DISCUSSION

Dermoid cyst is a kind of benign hamartoma, which often occurs in the skin of head and neck in infants or child, but sometimes may occur in adults with no obvious familial inheritance.<sup>5,6</sup> The etiology of dermoid cyst is still unclear. At present, the most widely accepted theory is embryonic origin, which is caused by abnormal development. The study found that the incidence of dermoid cyst was not related to age and gender.<sup>3,4,7</sup>

Dermoid cyst pathology showed that the cyst was unilocular, with thick wall, similar to complete, or incomplete skin structure. The innermost layer is cuticle, and the other layers are granular layer, spinous cell layer, basal layer, and dermis. In the dermis, there are hair follicles, sebaceous glands, eccrine glands, and

apocrine sweat glands. Keratinizing, stratified squamous epithelial lining, intraluminal keratin, sebum, epithelial debris, hair, and viscous fluid could be seen in the capsule.<sup>8,9</sup>

Dermoid cysts mostly occur in the head and neck, its clinical manifestations are painless growth of the mass, often accompanied by infection and ulceration, because of the different parts of the disease, the clinical symptoms are also different. CT examination showed soft tissue signal, no specific change. MRI showed that most of them were cystic masses with mixed internal signals. Two dermoid cysts were found in this case. A mass in the upper part of the nasal septum was found on examination because the cyst on the tip of the nose continued to grow and affected the appearance. The mass in the nasal septum did not cause any symptoms or nasal deformation. The usual dermoid cyst in the middle line of the nose causes the deformation of the nasal skin and is rarely found without any symptoms. In the imaging examination of our reported case, MRI examination clearly showed that there was no communication between the 2 masses, and there was no communication between the nasal septum mass and the intracranial. There were mixed signals in the 2 masses. CT and MRI play an important role in the diagnosis of dermoid cyst with or without communication with intracranial.<sup>10-12</sup>

Dermoid cysts generally grow slowly. If there is no continuous growth, it can be observed. Otherwise, it should be removed as soon as possible and sent for histopathological examination. Complete resection of the entire cyst wall is the best treatment. If the cyst is closely connected with important structures, the cyst wall may not be completely removed by surgery, which may lead to recurrence. If the dermoid cyst is repeatedly infected, it may lead to intracranial infection, abscess, and even death.<sup>13</sup> If nasal dermoid cysts with intracranial extension, suggest a nasal midline incision with a nasal bone osteotomy, pericranial flap, and keyhole-type craniotomy.<sup>14</sup> If the shape changes greatly, it is feasible to carry out plastic surgery such as nasal fat filling, and the effect is good.<sup>15</sup>

In our case, the nasal septum dermoid cysts with no communication and no appearance change, so she accepted the complete resection through nasal septum by using nasal endoscopy with less bleeding. Because the dermoid cyst is closely connected with the skull base and we find the local bone defect of the skull base during recess through the nasal septum, so we chose to use the nasal septum mucosa to reinforce the local bone defect of the skull base. Nasal septum dermoid cysts with no connection with intracranial and no abnormal appearance should accept operation of nasal endoscopy. For the dermoid cyst with intracranial expansion, nasal endoscopic surgery can also be used to the resection of mass and repair the skull base.<sup>16</sup>

The prognosis of dermoid cysts is relatively good, most of which are only affected by skin scars on the body surface, which are acceptable. For patients with intracranial extension or communication, multidisciplinary joint treatment and surgery have good prognosis and low recurrence rate.<sup>17</sup> After 6 months of recovery, the appearance of the nasal tip recovered well without obvious scar, the nasal septum area recovered well, and the local stoma was unobstructed without recurrence. But longer follow-up is necessary.

## CONCLUSIONS

Dermoid cysts in the nasal tip and septum are rare. In this case, the nasal septal dermoid cyst did not cause any clinical symptoms and found through image examination. It was found that this kind of nasal septal cyst with no clinical symptoms can achieve good therapeutic effect through endoscopic surgery, with less damage, rapid recovery, and good prognosis through repaired by nasal septum mucosa.

## REFERENCES

1. Julapalli MR, Cohen BA, Hollier LH, et al. Congenital, ill-defined, yellowish plaque: the nasal dermoid. *Pediatr Dermatol* 2006;23:556–559
2. Nakajima K, Korekawa A, Nakano H, et al. Subcutaneous dermoid cysts on the eyebrow and neck. *Pediatr Dermatol* 2019;36:999–1001
3. Orozco-Covarrubias L, Lara-Carpio R, Saez-De-Ocariz M, et al. Dermoid cysts: a report of 75 pediatric patients. *Pediatr Dermatol* 2013;30:706–711
4. Prior A, Anania P, Pacetti M, et al. Dermoid and epidermoid cysts of scalp: case series of 234 consecutive patients. *World Neurosurg* 2018;120:119–124
5. Chu EA, Ishii LE. Adult nasal dermoid sinus cyst. *Ear Nose Throat J* 2010;89:E12–E15
6. Saarinen I, Karppinen A, Saarinen P, et al. Inheritance of nasal dermoid sinus cyst and evidence for association with third ventricle colloid cyst. *Childs Nerv Syst* 2012;28:117–120
7. Pratt LW. Midline cysts of the nasal dorsum: embryologic origin and treatment. *Laryngoscope* 1965;75:968–980
8. Reissis D, Pfaff MJ, Patel A, et al. Craniofacial dermoid cysts: histological analysis and inter-site comparison. *Yale J Biol Med* 2014;87:349–357
9. Sorenson EP, Powel JE, Rozzelle CJ, et al. Scalp dermoids: a review of their anatomy, diagnosis, and treatment. *Childs Nerv Syst* 2013;29:375–380
10. Blake WE, Chow CW, Holmes AD, et al. Nasal dermoid sinus cysts: a retrospective review and discussion of investigation and management. *Ann Plast Surg* 2006;57:535–540
11. Zerris VA, Annino D, Heilman CB. Nasofrontal dermoid sinus cyst: report of two cases. *Neurosurgery* 2002;51:811–814
12. Dizon M, Ozturk A, Redett RJ, et al. Neuroimaging findings in a child with dumbbell-shaped frontosphenoidal dermoid cyst presenting as preseptal cellulitis. *Pediatr Radiol* 2009;39:850–853
13. Opsomer D, Allaeyts T, Alderweireldt AS, et al. Intracranial complications of midline nasal dermoid cysts. *Acta Chir Belg* 2019;119:125–128
14. Purnell CA, Skladman R, Alden TD, et al. Nasal dermoid cysts with intracranial extension: avoiding coronal incision through midline exposure and nasal bone osteotomy. *J Neurosurg Pediatr* 2020;25:298–304
15. Pierce CA, Konofaos P, Alvarez S, et al. Excision and fat grafting of nasal tip dermoid cysts through an open rhinoplasty approach. *J Craniofac Surg* 2016;27:e18–e20
16. Re M, Tarchini P, Macri G, et al. Endonasal endoscopic approach for intracranial nasal dermoid sinus cysts in children. *Int J Pediatr Otorhinolaryngol* 2012;76:1217–1222
17. Winterton RI, Wilks DJ, Chumas PD, et al. Surgical correction of midline nasal dermoid sinus cysts. *J Craniofac Surg* 2010;21:295–300

## Is It Really Safe to Discontinue Anticoagulant Treatment Before Ptosis Surgery From Serious Bleeding?

Kangmin Lee, MD,\*† and Minwook Chang, MD, PhD\*\*†

From the \*Department of Ophthalmology; and †Sensory Organ Research Center, Dongguk University Ilsan Hospital, Goyang, South Korea. Received October 2, 2021.

Accepted for publication October 4, 2021.

Address correspondence and reprint requests to Minwook Chang, MD, PhD, Dongguk University Ilsan Hospital, 27, Dongguk-ro, Ilsandong-gu, Goyang-si, Gyeonggi-do, South Korea; E-mail: mdjacob76@gmail.com

**Purpose:** To evaluate the effects of discontinuing anticoagulants (ACs)/antiplatelets (APs) preoperatively on surgery for blepharoptosis.

**Method:** A retrospective analysis included patients with acquired blepharoptosis who underwent surgical correction, and were followed for more than 1 month. Patients were classified into 2 groups depending on AC/AP treatment or otherwise. All patients taking AC/AP discontinued with the treatment 1 week prior to surgery in accordance with our clinical guidelines. Preoperative and postoperative marginal reflex distance 1 (MRD1) and ecchymosis grade were evaluated and compared.

**Results:** Group 1 (AC/AP treatment cessation) included 47 patients with 93 eyelids, and group 2 (control) included 51 patients with 98 eyelids. The preoperative MRD1 showed no significant difference between groups. Group 1 showed a significantly higher rate of severe ecchymosis (41.8 versus 22.4%,  $P = 0.004$ ) at 1 week of surgery as well as persistent ecchymosis (58.8 versus 7.3%,  $P = 0.000$ ) compared with group 2 postoperatively at 1 month. Postoperative MRD1 was significantly lower in group 1 at 1 week ( $P = 0.019$ ). However, the MRD1 and degree of improvement in lid height (postoperative MRD1 “preoperative MRD1) was not significantly different between the 2 groups ( $P = 0.499$ ,  $P = 0.058$ ) at 1 month postoperatively.

**Conclusions:** Postoperative ecchymosis was more severe in group 1 at 1 month after ptosis surgery even though the ACs/APs were discontinued. Surgeons should be careful about this before operation.

**The Synopsis:** Significant ecchymosis could occur even after discontinuation of antithrombotic agents in patients with a history of taking medication in ptosis surgery. Surgeons should be careful about this before operation.

**Key Words:** Anticoagulant, antiplatelet, blepharoptosis, ecchymosis

Blepharoptosis is a clinical condition characterized by drooping of 1 or both eyelids, which affects both the function and appearance of the eyes.<sup>1,2</sup> The surgical correction of blepharoptosis is difficult in that both functional and cosmetic aspects need to be considered. In addition, complications such as ecchymosis and edema, which may appear after ptosis surgery, are not easily predictable, which is a serious clinical concern. Also, ecchymosis and edema complicate the evaluation of potential over- or under-correction after surgery. Therefore,

This study followed the tenets of the Declaration of Helsinki and was approved by the Institutional Review Board of Dongguk University, Ilsan Hospital, Goyang, South Korea (IRB no. 2020-09-009).

Consent for publication is not applicable (no identifying patient data).

The informed consent required was waived because of the retrospective nature and the minimal risk of this study

This work was supported by the Dongguk University Research Fund of 2018.

The authors report no conflicts of interest.

Supplemental digital contents are available for this article. Direct URL citations appear in the printed text and are provided in the HTML and PDF versions of this article on the journal's Web site ([www.jcraniofacialsurgery.com](http://www.jcraniofacialsurgery.com)).

Copyright © 2022 by Mutaz B. Habal, MD

ISSN: 1049-2275

DOI: 10.1097/SCS.00000000000008302