

A Novel Plastic Surgical Technique for Treating Congenital Entropion in Asians

Takanori Iwayama, MD*
Kazunobu Hashikawa, MD, PhD*
Takeshi Fukumoto, MD, PhD†‡

Summary: Congenital entropion is an ocular condition involving malpositioning of the eyelid, which can result in ocular pain, conjunctival epiphora, or photophobia. Noninvasive treatment is effective in some cases; however, surgical treatment is indicated when keratitis and ocular irritating symptoms occur. There is no consensus regarding the most appropriate surgical technique. Moreover, some patients complain of changes in their appearance or unwanted incision scars after surgery. In particular, individuals with certain types of Asian heritage exhibit a lower eyelid morphology that differs from that of white individuals, caused by orbital fat locational difference. Subciliary muscle bulges cause swelling in the lower eyelid called Namidabuluro and are considered to create a youthful and beautiful appearance in Asians. Accordingly, some Asian individuals tend to be sensitive about changes to the appearance of the lower eyelid. To our knowledge, no report has yet described changes to Namidabukuro during congenital entropion repair in Asians. We describe a novel surgical technique for congenital entropion repair with the creation of cosmetically natural Namidabuluro in an East Asian cohort. The study included 8 lower eyelids of 4 Japanese female patients. Scarring was not noticeable in any of the 4 cases. Eversion of the cilia and the creation of cosmetically natural Namidabuluro were accomplished in all cases. There has been no case of recurrence yet. The novel surgical technique we developed enables not only the treatment of congenital entropion but also the creation of cosmetically acceptable Namidabuluro, resulting in increased patient satisfaction. (*Plast Reconstr Surg Glob Open* 2019;7:e2122; doi: 10.1097/GOX.0000000000002122; Published online 1 April 2019.)

INTRODUCTION

Congenital entropion is an ocular condition involving malpositioning of the eyelid, which causes foreign body sensation, ocular pain, conjunctival epiphora, or serious photophobia.¹⁻⁷ It is highly prevalent among Asian children, but some cases resolve with facial bone growth.^{1,3-7} The reported prevalence rate is >20% among 1- to 2-year-old children and decreases to 2% in 13- to 18-year-old children.⁵⁻⁷ The exact etiology of congenital entropion is unknown,^{1,5} but a possible cause is the failure of the

lower eyelid retractors to access the skin, thereby allowing the skin and orbicularis oculi to roll upward and push the cilia inward.^{1,3,4} An alternative etiology is excessive growth or hypertrophy of the orbicularis oculi or epicanthal folds, thereby causing inversion of the cilia.^{4,5} Palliative noninvasive treatment, such as depilation, is effective in some cases; however, curative surgical treatment is indicated when keratitis and ocular irritating symptoms occur.^{1,3,4,7} Although various surgical techniques are available, modifications of the Hotz procedure are usually performed.^{1,3-5,7} Correcting the lower eyelid retractors to the eyelid can cure congenital entropion.^{1,3} However, some patients complain of changes in appearance or unwanted postoperative scars. There is a desire to avoid changes in appearance and scar formation.^{4,5} In particular, individuals with certain types of Asian heritage exhibit a lower eyelid morphology that differs from that of white individuals.^{4,5,8} This morphologic difference can be explained by the difference in orbital fat location.⁸ Subciliary muscle bulges in the lower eyelid, called Namidabuluro, cause swelling along the lower eyelids and are considered to create a youthful and beautiful appearance in Asians.^{9,10} The creation of cosmetically natural Namidabuluro using non-

From the *Department of Plastic Surgery, Kobe University Hospital, Kobe, Japan; †Gene Expression and Regulation Program, The Wistar Institute, Philadelphia, Pa.; and ‡Division of Dermatology, Department of Internal Related, Kobe University Graduate School of Medicine, Kobe, Japan.

Received for publication August 13, 2018; accepted November 29, 2018.

Copyright © 2019 The Authors. Published by Wolters Kluwer Health, Inc. on behalf of The American Society of Plastic Surgeons. This is an open-access article distributed under the terms of the Creative Commons Attribution-Non Commercial-No Derivatives License 4.0 (CCBY-NC-ND), where it is permissible to download and share the work provided it is properly cited. The work cannot be changed in any way or used commercially without permission from the journal.

DOI: 10.1097/GOX.0000000000002122

Disclosure: The authors have no financial interest to declare in relation to the content of this article.

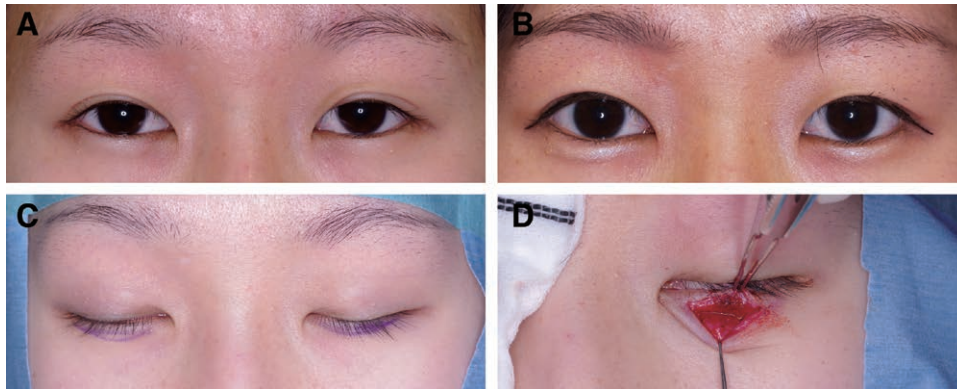


Fig. 1. Images of representative patient. Preoperative (A) and postoperative (B) images of an 18-year-old girl. C, Skin incision line. D, Intraoperative image showing the upper edge of the orbicularis oculi that was transected to expose the tarsus plate surface.

surgical (eg, hyaluronic acid filler injection) or surgical options is becoming popular among Asians.⁹ On the other hand, tear trough deformity can result in a fatigued and aged appearance, which has caused some patients to seek surgical treatments.^{9,10} Therefore, some Asian individuals tend to be sensitive about changes to the lower eyelid appearance.³⁻⁸ Although several reports describe cosmetic outcomes regarding the surgical treatment of congenital entropion, no reports have described changes to Namidabuluro.^{1-5,7} Here, we report a novel surgical technique that can not only provide complete treatment of congenital entropion but can also create cosmetically acceptable Namidabuluro.

CASE REPORTS

Between February 2013 and September 2017, 1 surgeon performed congenital entropion surgery on 4 patients. The study included 8 lower eyelids of 4 female patients (average age, 20.8 years; range, 18–26 years). They had been having slight foreign body sensation and ocular pain, which they had been resolving by deplicating the cilia by themselves. Figure 1 and Supplemental Digital Content 1 and 2 show the preoperative photographs of a patient with congenital entropion. An initial marking on the lower eyelid was performed according to the Hotz method. [See figure, Supplemental Digital Content 1, which displays preoperative (A) and postoperative (B) images of an 18-year-old girl. Skin incision line (C). Intraoperative image showing the upper edge of the orbicularis oculi that was transected to expose the tarsus plate surface (D). <http://links.lww.com/PRSGO/A980>.] [See figure, Supplemental Digital Content 2, which displays preoperative (A) and postoperative (B) images of a 21-year-old woman. <http://links.lww.com/PRSGO/A981>.]

Marks were made approximately 2 mm below the cilia (Fig. 1C and SDC 1C). Anesthesia was administered using 0.5% xylocaine with 0.001% epinephrine. Five minutes after anesthesia application, the lower eyelid was incised. The resection width was approximately 3 mm (Fig. 1C and SDC 1C). Only the upper edge of the orbicularis oculi was transected to expose the tarsus plate surface. The lower

eyelid retractors were reached, and the eyelid was forced outward by shortening the tarsus plate and the lower eyelid retractors by using 6-0 nylon sutures (Fig. 1D, and SDC 1D). After confirming that the cilia have been sufficiently everted, we closed the skin edge end-to-end using 6-0 nylon sutures. Scarring was not noticeable in any patient; eversion of the cilia and creation of cosmetically natural tear troughs were achieved. During follow-up, all patients reported being fully satisfied with the surgical outcomes. There has been no case of recurrence yet.

DISCUSSION

Although several procedures have been proposed for the treatment of congenital entropion, there is no established standard.¹⁻⁷ The main objective of the surgery for treating congenital entropion is to create an adhesion between the anterior lamella of the lower eyelid and the lower eyelid retractors, thereby exerting an everting force on the cilia.^{1,3} One of the most common problems with previous operative techniques is the change in the appearance of the lower eyelid with dents or depressed scars, caused by excising of the orbicularis oculi partially.¹⁻⁵ Our technique is a modified form of the Hotz procedure.^{1,2} Shortening the tarsus plate and the lower eyelid retraction is the same as in the Hotz procedure. A novel part of our technique is to overlap the orbicularis oculi without resection, which enables the creation of cosmetically natural subciliary bulges similar to Namidabuluro. Individuals with certain types of Asian heritage exhibit a lower eyelid morphology that differs from that of white individuals. Namidabuluro is becoming popular among Asians to conform to popular beauty standards.⁹ Accordingly, some Asian individuals tend to be sensitive about changes in the lower eyelid appearance.³⁻⁸ Moreover, Namidabuluro may be caused by several anatomic systems, which renders the creation of cosmetically natural Namidabuluro difficult.⁹ Our novel technique of overlapping the orbicularis oculi could enable definitive repair of congenital entropion and effective creation of natural Namidabuluro. We think that our technique might be used as Namidabuluro plasty. Because some patients may not desire the creation of Namidabu-

luro, it is important to select an appropriate procedure with due informed consent of the patient before surgery. We believe that our technique can be a useful option for some patients. Moreover, our technique does not require extensive experience, thereby indicating that our procedure is a simple and effective technique for all surgeons. In the current study, no complications occurred. As previous reports have documented a high recurrence rate of 7.7%–29%,^{3,5,7} long-term follow-up and an increased number of cases are required to evaluate childhood growth and facial bone maturation after this procedure. In the future, we must determine what level of overlapping the orbicularis oculi is sufficient to form natural Namidabuluro. In conclusion, the novel surgical technique we described can enable complete repair of congenital entropion with cosmetically natural Namidabuluro creation, resulting in improved patient satisfaction.

Takeshi Fukumoto, MD, PhD

Gene Expression and Regulation Program
The Wistar Institute
Philadelphia, PA 19104
Division of Dermatology
Department of Internal Related
Kobe University Graduate School of Medicine
7-5-1 Kusunoki-cho, Chuo-ku, Kobe 6500017, Japan
E-mail: fuku@med.kobe-u.ac.jp

REFERENCES

1. Kakizaki H, Selva D, Leibovitch I. Cilial entropion: surgical outcome with a new modification of the Hotz procedure. *Ophthalmology*. 2009;116:2224–2229.
2. Siegel RJ. Involitional entropion: a simple and stable repair. *Plast Reconstr Surg*. 1988;82:42–47.
3. Woo KI, Yi K, Kim YD. Surgical correction for lower lid epiblepharon in Asians. *Br J Ophthalmol*. 2000;84:1407–1410.
4. Chang M, Lee TS, Yoo E, et al. Surgical correction for lower lid epiblepharon using thermal contraction of the tarsus and lower lid retractor without lash rotating sutures. *Br J Ophthalmol*. 2011;95:1675–1678.
5. Nakauchi K, Mimura O. Fish-tail resection for treating congenital entropion in Asians. *Clin Ophthalmol*. 2012;6:831–836.
6. Noda S, Hayasaka S, Setogawa T. Epiblepharon with inverted eyelashes in Japanese children. I. Incidence and symptoms. *Br J Ophthalmol*. 1989;73:126–127.
7. Hayasaka S, Noda S, Setogawa T. Epiblepharon with inverted eyelashes in Japanese children. II. Surgical repairs. *Br J Ophthalmol*. 1989;73:128–130.
8. Carter SR, Seiff SR, Grant PE, et al. The Asian lower eyelid: a comparative anatomic study using high-resolution magnetic resonance imaging. *Ophthalmic Plast Reconstr Surg*. 1998;14:227–234.
9. Tsurukiri K, Iwanami M. The anatomy and clinical applications of “NAMIDABUKURO.” *J Jpn Soc Aesthetic Plast Surg*. 2005;27:166–172.
10. Goldberg RA, McCann JD, Fiaschetti D, et al. What causes eyelid bags? Analysis of 114 consecutive patients. *Plast Reconstr Surg*. 2005;115:1395–1402; discussion 1403.